TEXT-BOOK OF HISTOLOGY

BOHM, DAVIDOFF, HUBER

King's College Hospital
Medical School
(UNIVERSITY OF LONDON).

Presented by
the Executor of the late
Edward Worrell Carrington
M.A., M.B., B.Ch. (Oxon.)
University Entrance Scholar of the
Medical School, and House Surgeon.
Temporary Captain R.A.M.C.
Awarded the Military Cross, February 1915.
Killed while succouring the wounded
at the Front on September 27, 1915.

22101343934

Med
K7427

E. W. Carrington
Keble College
Oxford

Dec., 1908

KING'S COLLEGE HOSPITAL
LIBRARY
MEDICAL SCHOOL

CANCELLED

Digitized by the Internet Archive
in 2016

https://archive.org/details/b28105746

1605

KING'S COLLEGE HOSPITAL
LIBRARY
MEDICAL SCHOOL

A TEXT-BOOK

OF

HISTOLOGY

INCLUDING MICROSCOPIC TECHNIC

BY

A. A. BÖHM, M. D., and M. VON DAVIDOFF, M. D.

of the Anatomical Institute in Munich

Edited, with Extensive Additions to both Text and Illustrations

BY

G. CARL HUBER, M.D.

Professor of Histology and Embryology and Director of the Histological Laboratory
University of Michigan

Second Edition
Thoroughly Revised and Enlarged

WITH 377 ILLUSTRATIONS

PHILADELPHIA, NEW YORK, LONDON
W. B. SAUNDERS & COMPANY
1904

26685

CANCELLED

Set Up, Printed, and Copyrighted October, 1900. Reprinted July, 1901.
Revised, Reprinted, and Recopyrighted, August, 1904.

Copyright, 1904, by W. B. Saunders & Company.

Registered at Stationers' Hall, London, England.

WELLCOME INSTITUTE LIBRARY
Coll. welMOmec
Call No. QS504 1898 B671 3E2

WELLCOME INSTITUTE LIBRARY
Coll. welMOmec
Call No. QS

PRESS OF
W. B. SAUNDERS & COMPANY

TO THEIR TEACHER

PROFESSOR C. VON KUPFFER

THIS BOOK IS DEDICATED BY

THE GRATEFUL AUTHORS

EDITOR'S PREFACE TO THE SECOND EDITION.

The favorable reception accorded to the first American edition of Böhm and Davidoff's Text-book of Histology has justified the assumption expressed by the editor in his preface to the former edition, that an English translation of this work would meet with approval from American and English teachers and students.

In the preparation of this second American edition the editor has retained in general the same arrangement of the subject-matter as presented in the former edition. The revision of the text has given opportunity to take cognizance of the many contributions to our knowledge of the ultimate structure of tissues and organs and of their histogenesis which have appeared in recent years, and in doing so, many of the chapters, especially those dealing with general histology, have been subjected to extensive alterations. Recognition has also been given to the results obtained by the use of precise methods of plastic reproduction, methods which have been especially useful in giving clearer and more accurate conceptions of the form and relationship of anatomic structures, too small and too delicate to admit of disassociation by means of methods of maceration and teasing and too complicated to admit of full interpretation by means of sections. Maziarski's observations on the form and relationship of the ultimate divisions of the tubular systems of many of the more important glands have been embodied, also the results of numerous reconstructions made in the Histological Laboratory of the University of Michigan.

The text of this edition has been extended by some forty pages, and the illustrations have been increased from three hundred and fifty-one to three hundred and seventy-seven. Recognizing the fact that a text-book of Histology is a book which of necessity needs to be constantly used in the laboratory, and its size is, therefore, a matter of some importance, the editor seemed justified, in view of the fact that an increase in the number of text-pages seemed inevitable, to dispense in the present edition with the list of references to the literature (some twenty pages) which appeared in the former edition.

G. Carl Huber.

Laboratory of Histology and Embryology,
University of Michigan,
August, 1904.

EDITOR'S PREFACE TO THE FIRST EDITION.

THE "Text-book of Histology" by Böhm and v. Davidoff, as stated by the authors in the preface to the first edition, presents as fully as possible, from both the theoretic and technical standpoints, the subject-matter of the lectures and courses in histology given to students in the University of Munich. The authors further state that in the completion of their work they had the constant aid and advice of Professor von Kupffer, and had at their disposal the sections in the collection of the histologic laboratory in Munich, which were freely used in the selection and preparation of the illustrations accompanying the text.

The excellence of the text and illustrations of the German edition, attested by all familiar with the work, and the cordial reception which it has received from both students and investigators, justify the belief that an English translation will meet with approval from American and English teachers and students.

In the preparation of this American edition the editor has retained substantially all the subject-matter and illustrations of the second German edition, although certain minor changes in the arrangement of the text seemed desirable. Additions to the German text have been freely made. The sections on the Motor and Sensory Nerve-endings and on the Spinal and Sympathetic Ganglia have been greatly expanded, and the Innervation of Glands and Organs has been considered much more fully than in the original. Our knowledge of the normal function of tissues and organs is so dependent on a correct understanding of their innervation that this subject seemed deserving of fuller consideration than is generally given it in text-books of this scope. The glands with internal secretion have also been considered more fully than in the original text, their importance necessitating such treatment. More than one hundred illustrations, the majority of them from original drawings, have also been added. In making these and other minor additions the editor has striven to stamp his own work with the excellent features of the German text, and trusts that his endeavors may have added to the usefulness of the book.

The editor acknowledges with pleasure his indebtedness to Dr. Herbert H. Cushing for his excellent and accurate translation, and for suggestions received from him. The publishers, Messrs. Saunders & Company, have shown throughout the greatest interest in the work, and deserve the gratitude of the editor for their ready acquiescence in all suggestions made by him, for the excellent reproduction of his drawings, and for the suggestions made to him. The editor is particularly indebted to his able assistant, Dr. Lydia M. De Witt, for valuable assistance rendered, more especially in the tedious work of proof-correction, for which he expresses his sincere appreciation and gratitude.

G. CARL HUBER.

UNIVERSITY OF MICHIGAN, ANN ARBOR, MICH.

LIBRARY
MEDICAL SCHOOL

CONTENTS.

INTRODUCTION TO MICROSCOPIC TECHNIC.

PAGE

Microscope and Its Accessories 17
Microscopic Preparations 21
Methods of Maceration 22
Fixing Methods 23
Infiltration and Imbedding 27
Paraffin 27
Celloidin 30
Celloidin-Paraffin 32
Microtomes and Sectioning 32
Further Treatment of the Section 38
Fixation to the Slide and Removal of Paraffin 38
Staining 41
Section Staining 41
Staining in Bulk 46
Methods of Impregnation 47
Preparation of Permanent Specimens 52
Methods of Injection 53
Reconstruction by Means of Wax Plates 55

GENERAL HISTOLOGY.

I. THE CELL.

Cell-body 59
Nucleus 62
Nuclear and Cell-division 64
Mitosis or Karyokinesis (Indirect Cell-division) 64
Prophases 66
Metaphases 68
Anaphases 69
Telophases 70
Heterotypic Form of Mitosis 70
Amitosis 70
Process of Fertilization 71
Chromatolysis 74
Technic for the Cell 74

II. TISSUES.

Epithelial Tissues 80
Simple Epithelium 82
Simple Squamous Epithelium 82
Simple Cubic Epithelium 82
Simple Columnar Epithelium 83
Pseudostratified Columnar Epithelium 83
Stratified Epithelium 83
Stratified Squamous Epithelium 84
Transitional Epithelium 85
Stratified Columnar Epithelium 85

PAGE
Glandular Epithelium 87
Unicellular Glands 87
Multicellular Glands 88
General Consideration of the Structure and Classification of Glands . . . 88
Tubular Glands 89
Alveolar Glands 91
Remarks on the Process of Secretion 92
Neuro-epithelium 92
Mesothelium and Endothelium 92
Technic for Epithelial Tissues 94
Connective Tissues 96
Mucous Connective Tissue 100
Reticular Connective Tissue 100
Fibrous Connective Tissue 101
Adipose Tissue 107
Cartilage 108
Bone 112
Structure of Bone 112
Development of Bone 116
Technic for Connective Tissues 126
Muscular Tissues 134
Nonstriated Muscle-cells 134
Striped Muscle-fibers 136
Development of Voluntary Muscle-fibers 144
Cardiac Muscle 145
Technic for Muscular Tissue 147
Nervous Tissues 148
Nerve-cells or Ganglion Cells; Cell-bodies of Neurones 149
Nerve-fibers 157
Peripheral Nerve Terminations 162
Technic for Nervous Tissues 180

SPECIAL HISTOLOGY.

I. BLOOD AND BLOOD-FORMING ORGANS, HEART, BLOOD-VESSELS, AND LYMPH-VESSELS.

Blood and Lymph 186
Formation of Blood 186
Red Blood-corpuscles 187
White Blood-corpuscles 191
Blood Platelets—Thrombocytes 194
Behavior of Blood-cells in the Blood Current 196
Lymphoid Tissue, Lymph-nodules, and Lymph-glands 196
Spleen 202
Bone-marrow 207
Thymus Gland 210

II. CIRCULATORY SYSTEM.

Vascular System 213
Heart 213
Blood-vessels 216
Arteries 216
Veins 219
Capillaries 220
Anastomoses, Retia Mirabilia, and Sinuses 222
Lymphatic System 223
Lymph-vessels 223
Lymph-capillaries, Lymph-spaces, and Serous Cavities 224
Carotid Gland (Glandula Carotica, Glomus Caroticum) 225
Technic for Blood and Blood-forming Organs 226
Technic for Circulatory System 235

III. DIGESTIVE ORGANS.

PAGE
Oral Cavity . . . 235
Teeth . . . 238
Structure of the Adult Tooth . . . 238
Development of the Teeth . . . 243
Tongue . . . 247
Lingual Mucous Membrane and Its Papillæ . . . 247
Taste-buds . . . 249
Lymph-follicles of the Tongue (Folliculi Linguales) and the Tonsils . . . 251
Pharyngeal Tonsil . . . 251
Glands of the Oral Cavity . . . 253
Salivary Glands . . . 255
Parotid Gland (Serous Gland) . . . 255
Sublingual Gland (Mucous Gland) . . . 255
Submaxillary Gland (Mixed Gland) . . . 258
Small Glands of the Mouth . . . 259
Pharynx and Esophagus . . . 262
Stomach and Intestines . . . 264
General Structure of the Intestinal Mucous Membrane . . . 264
Stomach . . . 266
Small Intestine . . . 274
Large Intestine, Rectum, and Anus . . . 281
Blood, Lymph, and Nerve Supply of the Intestine . . . 283
Secretion of the Intestine and the Absorption of Fat . . . 288
Liver . . . 289
Pancreas . . . 298
Technic for Digestive Organs . . . 303

IV. ORGANS OF RESPIRATION.

Larynx . . . 309
Trachea . . . 310
Bronchi, their Branches, and the Bronchioles . . . 311
Terminal Divisions of Bronchi and Ultimate Air-spaces . . . 313
Thyroid Gland . . . 319
Parathyroid Glands . . . 321
Technic for Organs of Respiration . . . 322

V. GENITO-URINARY ORGANS.

Urinary Organs . . . 323
Kidney . . . 323
Pelvis of the Kidney, Ureter, and Bladder . . . 336
Suprarenal Glands . . . 339
Technic for Urinary Organs and Suprarenal Body . . . 342
Female Genital Organs . . . 344
Ovum . . . 344
Ovary . . . 344
Fallopian Tubes, Uterus, and Vagina . . . 354
Male Genital Organs . . . 361
Spermatozoon . . . 361
Testes . . . 362
Excretory Ducts . . . 367
Spermatogenesis . . . 372
Technic for Reproductive Organs . . . 378

VI. THE SKIN AND ITS APPENDAGES.

Skin (Cutis) . . . 379
Hair . . . 389
Nails . . . 394
Glands of the Skin . . . 396
Sweat-glands . . . 396
Sebaceous Glands . . . 398
Mammary Glands . . . 400
Technic for the Skin and Its Appendages . . . 403

VII. THE CENTRAL NERVOUS SYSTEM.

PAGE
Spinal Cord 406
Cerebellar Cortex 413
Cerebral Cortex 416
Olfactory Bulb 421
Epiphysis and Hypophysis 422
Ganglia 424
General Survey of the Relations of the Neurones to One Another in the Central Nervous System 431
Neuroglia 434
Membranes of the Central Nervous System 436
Blood-vessels of the Central Nervous System 439
Technic for Central Nervous System 440

VIII. EYE.

General Structure 446
Development of the Eye 446
Tunica Fibrosa Oculi 448
Sclera 448
Cornea 449
Vascular Tunic of the Eye 452
Choroid, Ciliary Body, and Iris 452
Internal or Nervous Tunic of the Eye 457
Pigment Layer 457
Retina 457
Region of the Optic Papilla 460
Region of the Macula Lutea 460
Ora Serrata, Pars Ciliaris Retinæ, and Pars Iridica Retinæ 461
Müller's Fibers of the Retina 462
Relations of the Elements of the Retina to One Another 462
Optic Nerve 464
Blood-vessels of the Optic Nerve and Retina 465
Vitreous Body 467
Crystalline Lens 467
Fetal Blood-vessels of the Eye 468
Interchange of Fluids in the Eyeball 469
Protective Organs of the Eye 469
Lids and Conjunctiva 469
Lacrimal Apparatus 473
Technic for the Eye 474

IX. ORGAN OF HEARING.

External Ear 476
Middle Ear 478
Internal Ear 480
Utriculus and Sacculus 482
Semicircular Canals 483
Cochlea 484
Organ of Corti 489
Development of the Labyrinth 496
Technic for Organ of Hearing 497

X. ORGAN OF SMELL.

Technic for Nasal Mucous Membrane 500

XI. GENERAL CONSIDERATIONS OF THE SPECIAL SENSE-ORGANS.

INDEX 501

LIBRARY

ILLUSTRATIONS.

FIG.		PAGE
1.	Microscope	18
2.	Diagram showing the principle of a compound microscope	20
3.	Box for imbedding tissues	28
4.	Laboratory microtome	33
5.	Minot automatic precision microtome	34
6.	Minot automatic rotary microtome	34
7.	Apparatus for cutting tissues frozen by carbon dioxid	37
8.	Movements in honing	38
9.	Apparatus for making wax plates, used in reconstruction by Born's method	56
10.	Diagram of cell (Huber)	59
11.	Cylindric ciliated cells from the primitive kidney of *Petromyzon planeri*	60
12–26.	Processes of mitotic cell- and nuclear division	65, 66
27–29.	Mitotic cell-division of fertilized whitefish eggs (Huber)	67
30.	Mitotic division of cells in testis of salamander (Benda and Guenther)	69
31–36.	Process of fertilization (Boveri)	72, 73
37.	Pigment cell from the skin of the head of a pike	77
38.	Isolated cells of squamous epithelium (Huber)	82
39.	Surface view of squamous epithelium from skin of a frog	82
40.	Simple columnar epithelium from the small intestine of man (Huber)	83
41.	Pseudostratified columnar epithelium	83
42.	Stratified pavement epithelium	84
43.	Cross-section of stratified squamous epithelium from esophagus of man (Huber)	84
44.	Isolated transitional epithelial cells from bladder of man (Huber)	85
45.	Cross-section of transitional epithelium from the bladder of a young child (Huber)	85
46.	Stratified columnar epithelium	86
47.	Ciliated cells from bronchus of dog	86
48.	Cross-section of stratified ciliated columnar epithelium from trachea of rabbit (Huber)	86
49.	Goblet cells from bronchus of dog	87
50.	Mucus-secreting cell (goblet cell) (Huber)	87
51.	Simple tubular glands	88
52.	Excretory ducts and lumina of the secretory portion of a compound tubular gland	89
53.	Lumina of the secreting portion of a reticulated tubular gland	89
54.	Glandular classification	90
55.	Mesothelium from pericardium of rabbit (Huber)	93
56.	Mesothelium from mesentary of rabbit (Huber)	93
57.	Mesothelium from peritoneum of frog	93
58.	Mesothelium covering posterior abdominal wall of frog (Huber)	94
59.	Endothelial cells from small artery of mesentery of rabbit (Huber)	94
60.	Mesenchymatous tissue from the subcutis of a duck embryo	97
61.	Development of the different types of connective tissue from the mesenchyma (Huber)	98
62.	White fibrils and bundles from teased preparation of a fresh tendon from tail of rat (Huber)	99
62½.	Elastic fibers from ligamentum nuchæ of ox	99
63.	Reticular fibers from a thin section of a lymph-gland (Huber)	101
64.	Reticular connective tissue from lymph-gland of man	102
65.	Areolar connective tissue from subcutaneous tissue of rat (Huber)	102
66.	Cell-spaces in the ground-substance of areolar connective tissue of young rat (Huber)	103
67.	Connective-tissue cells from pia mater of dog (Huber)	103
68.	Pigment cells found on the capsule of sympathetic ganglion of frog (Huber)	103
69.	Leucocyte of frog with pseudopodia	104
70.	Fibrous connective tissue from great omentum of rabbit	105

FIG. PAGE
71. Longitudinal section of tendon 106
72. Cross-section of secondary tendon bundle from tail of rat (Huber) 106
73. Tendon cells from tail of rat (Huber) 107
74. Cross-section of ligamentum nuchæ of ox (Huber) 107
75. Fat-cell 107
76. Hyaline cartilage 108
77. Section through cranial cartilage of squid 109
78. Insertion of the ligamentum teres into the head of the femur 110
79. Elastic cartilage from external ear of man 111
80. Longitudinal section through a lamellar system (v. Ebner) 113
81, 82. Lamellæ seen from the surface (v. Ebner) 113
83. Segment of a transversely ground section from the shaft of a long bone, showing lamellar system 114
84. Portion of a transversely ground disc from the shaft of a human femur . . . 115
85. Longitudinal section through a long bone of a lizard embryo 117
86. Longitudinal section of the proximal end of a long bone of a sheep embryo . 118
87. Longitudinal section through area of ossification from long bone of human embryo (Huber) 119
88. Longitudinal section through epiphysis of arm bone of sheep embryo 122
89. Section through the lower jaw of an embryo sheep 123
90. Cross-section of developing bone from leg of human embryo, showing endochondral and intramembranous bone development (Huber) 124
91. Cross-section of shaft (tibia of sheep) 125
92. Nonstriated muscle from the intestine of a cat 135
93. Cross-section of striated muscle-fibers 136
94. Muscle-fiber from ocular muscles of rabbit 136
95. Striated muscle-fiber of frog, showing sarcolemma (Huber) 137
96. Diagram of structure of fibrils of a striated muscle-fiber (Huber) 138
97. Diagram of transverse striation in the muscle of an anthropoid 138
98. Transverse section through the striated muscle-fiber of a rabbit 139
99. Striated muscle-fiber of man 140
100. Cross-section through the trapezius muscle of man 140
101. Branched, striated muscle-fiber from tongue of dog (Huber) 141
102. Cross-section of rectus abdominis of child, under low magnification (Huber) 142
103. Longitudinal section through the line of junction between muscle and tendon 142
104, 105. Longitudinal and cross-section of muscle-fibers from the human myocardium 143
106. Longitudinal section of heart-muscle (Huber) 146
107. Bipolar ganglion cell from the ganglion acusticum of a telecost 150
108. Chromatophile granules of a ganglion cell from the Gasserian ganglion of a telecost 151
109. Nerve-cell from the anterior horn of the spinal cord of an ox 151
110. Motor neurones from anterior horn of the spinal cord of new-born cat (Huber) 152
111. A nerve-cell with branched dendrites (Purkinje's cell), from cerebellar cortex of rabbit 152
112. Pyramidal cell from cerebral cortex of man 153
113. Nerve-cell from dendrites ending in claw-like telodendria 154
114. Ganglion cell with a T-shaped process 154
115. Ganglion cell from Gasserian ganglion of rabbit (Huber) 155
116. Ganglion cells from spinal ganglion of rabbit embryo 155
117. Neurone from inferior cervical sympathetic ganglion of rabbit (Huber) . . . 156
118. Longitudinal section of nerve-fiber 157
119. Transverse section through sciatic nerve of frog 158
120. Medullated nerve-fibers from rabbit 159
121. Remak's fibers from pneumogastric nerves of rabbit 159
122. Diagram to show composition of a peripheral nerve-trunk (Huber) 161
123. Cross-section through a peripheral nerve 161
124. Peripheral motor neurone (Huber) 163
125. Motor nerve-ending in voluntary muscle of rabbit (Huber–De Witt) 164
126–130. Motor endings in striated voluntary muscles 165
131. Motor nerve-ending in striated voluntary muscle of frog (Huber–De Witt) . . 166
132. Motor nerve-ending on heart muscle-cells of cat (Huber–De Witt) 166
133. Motor nerve-ending on involuntary nonstriated muscle-cell from intestine of cat (Huber–De Witt) 166

FIG.		PAGE
134.	Peripheral sensory neurone (Huber)	167
135.	Termination of sensory nerve-fibers in the mucosa and epithelium of urethra of cat (Huber)	168
136.	End-bulb of Krause from conjunctiva of man (Dogiel)	169
137.	Meissner's tactile corpuscle (Dogiel)	170
138.	Genital corpuscle from glans penis of man (Dogiel)	171
139.	Cylindric end-bulb of Krause from intermuscular fibrous tissue septum of cat (Huber)	172
140.	Vater-Pacinian corpuscle from the mesentery of a cat	173
141.	Pacinian corpuscles from the mesorectum of a kitten (Sala)	174
142.	Corpuscle of Herbst from bill of duck	175
143.	Intrafusal muscle-fiber from neuromuscular nerve end-organ of rabbit (Huber)	176
144.	Cross-section of a neuromuscular nerve end-organ from interosseous muscle of man (Huber)	176
145.	Neuromuscular nerve end-organ from plantar muscles of dog (Huber–De Witt)	177
146.	Neurotendinous nerve end-organ from rabbit (Huber–De Witt)	178
147.	Cross-section of neurotendinous nerve end-organ of rabbit (Huber–De Witt)	179
148.	Ranvier's crosses from sciatic nerve of rabbit	181
149.	Medullated nerve-fiber from sciatic nerve of frog	181
150.	Ganglion cell from anterior horn of spinal cord of calf	182
151.	Human red blood-cells	188
152.	Rouleau formation of human erythrocytes	188
153.	Hemin, or Teichmann's crystals, from blood stains on a cloth (Huber)	188
154.	Crenated human red blood-cells	188
155.	Red blood-corpuscles subjected to the action of water	188
156.	Red blood-corpuscles from various vertebrate animals	189
157.	White blood-corpuscles from normal blood of man	191
158.	Ehrlich's leucocytic granules	192
159.	Fibrin from laryngeal vessel of child (Huber)	195
160.	Solitary lymph-nodule from human colon	197
161.	Transverse section of human cervical lymph-gland, showing the general structure of a lymph-gland	198
162.	Section from human lymph-gland	199
163.	Section through the human spleen	203
164.	Lobule of the spleen (Mall)	205
165.	Cells containing pigment, blood-corpuscles, and hemic masses from spleen of dog	206
166.	Section through human spleen showing reticular fibrils	206
167.	Cover-glass preparation from bone-marrow of dog	208
168.	Section through human red bone-marrow	209
169.	Small lobule from thymus of child, well-developed cortex	211
170.	Hassall's corpuscle and a small portion of medullary substance from thymus of child ten days old (Huber)	211
171.	Cross-section of human carotid artery	217
172.	Section through human artery, one of the smaller of the medium-sized	217
173.	Precapillary vessels from mesentery of cat (Huber)	218
174.	Cross-section of human internal jugular vein	219
175.	Section of small human vein	220
176.	Endothelial cells of capillary and precapillary from mesentery of rabbit (Huber)	221
177.	Small artery from oral submucosa of cat with nerve-terminations	222
178.	Section of a cell-ball from glomus caroticum of man	225
179.	Thoma-Zeiss hemocytometer	232
180.	Section through lower lip of man	237
181.	Longitudinal section through a human tooth, showing lines of Retzius	239
182.	Portion of ground tooth from man, showing enamel and dentin	240
183.	Longitudinal section through human molar from the center of the enamel layer	241
184.	Cross-section of human tooth, showing cement and dentin	243
185.	Nerve termination in pulp of rabbit's molar (Huber)	244
186–189.	Four stages in the development of tooth in sheep embryo	245
190.	Portion of cross-section through developing tooth	246
191.	Fungiform papilla from human tongue (Huber)	247
192.	Cross-section of human tongue showing filiform papillæ	248
193.	Longitudinal section of foliate papilla of rabbit, showing taste-buds (Huber)	249
194.	Longitudinal section of a human circumvallate papilla	250

FIG. PAGE
195. Schematic representation of a taste-goblet (Hermann) 251
196, 197. Section through pharyngeal tonsil of man 252, 253
198. Section through salivary gland of rabbit, with injected blood-vessels 255
199. Model of a small portion of a sublingual gland of man 256
200. Section of human submaxillary gland 257
201. Section of parotid gland of man 257
202. Portion of a model of a salivary gland with mucus secretion 258
203. Alveoli from submaxillary gland of dog (Huber) 258
204. Model of a gland of v. Ebner, from a boy 260
205. Section of esophagus of a dog 263
206. Section of human esophagus, showing a cardiac gland with a dilated duct . . 264
207. Epithelium of human stomach, covering fold of mucosa between two gastric crypts 266
208. Vertical section through fundus of human stomach 267
209. Fundus glands from fundus of stomach of young dog (Huber) 267
210. Section through junction of human esophagus and cardia 268
211. Vertical section through human pylorus 270
212. Section of human pylorus 271
213. Section through fundus of human stomach in condition of hunger 272
214. Section through fundus of human stomach during digestion 272
215. Illustrations of models, made after Born's wax-plate reconstruction method, of glandular structures and duodenal villi of human intestine 273
216. Section through mucous membrane of human small intestine 275
217. Longitudinal section through summit of villus from human small intestine . . 276
218. Section through the junction of the human pylorus and duodenum 278
219. Section of solitary lymph-nodule from vermiform appendix of guinea-pig . . 279
220. Section through colon of man, showing glands of Lieberkühn 280
221. Transverse section of human vermiform appendix (Huber) 281
222. Solitary lymph-follicle from human colon 282
223. Section through fundus of injected cat's stomach 283
224. Schematic transverse section of human small intestine (Mall) 285
225. Portion of the plexus of Auerbach from stomach of cat (Huber) 286
226. Section of esophagus of cat showing nerve-terminations (Huber) 287
227. Section through liver of pig, showing chains of liver-cells 289
228. Section through injected liver of rabbit 290
229, 230. Human bile capillaries 291
231. Diagram of hepatic cord in transverse section 292
232. Section through the human liver, showing the beginning of bile-ducts . . . 292
233. Injected blood-vessels in liver lobule of rabbit 293
235. Reticulum of dog's liver 294
236. Connective tissue from liver of sturgeon, showing reticulum 295
237. Liver of rabbit, showing the so-called stellate cells of Kupffer (Huber) . . . 296
238. Section through liver lobule of dog, showing stellate cells 297
239. Transverse section through alveolus of frog's pancreas 299
240. Model of lobule of human pancreas 299
241, 242. Section through human pancreas 300, 301
243. Relation of three adjoining alveoli to excretory duct, illustrating origin of centro-acinal cells 302
244. Section of human pancreas, showing gland alveoli surrounding an area of Langerhans (Huber) 302
245. Vertical section through mucous membrane of human larynx 309
246. Longitudinal section of human trachea (Huber) 311
247. Transverse section through human bronchus 312
248, 249. Sections of cat's lungs 313
250. Internal surface of human respiratory bronchiole (Kölliker) 314
251. Inner surface of human alveolus, showing respiratory epithelium (Kölliker) . 315
252. Respiratory epithelium in amphibia 316
253. Scheme of lung lobules after Miller 317
254. Reconstruction in wax of a single atrium and air-sac with the alveoli (Miller) 317
255. Section of human lung, showing elastic fibers (Huber) 318
256. Section through injected rabbit's lung 318
257. Cross-section of thyroid gland of man (Huber) 319
258. Section from parathyroid of man (Huber) 321
259. Kidney of new-born infant 323
260. Isolated uriniferous tubules 324

FIG. PAGE
261. Median longitudinal section of adult human kidney 325
262. Section of cortical substance of human kidney 326
263. Section of proximal convoluted tubules from man 327
264. Epithelium from proximal convoluted tubule of guinea-pig, with surface and lateral views 328
265. Cortical portion of longitudinal section of kidney of child (Huber) 328
266. Section of medulla of human kidney 329
267 Longitudinal section through papilla of injected kidney 330
268. Section through junction of two lobules of kidney 331
269. Diagrammatic scheme of uriniferous tubules and blood-vessels of kidney . . 333
270. Direct anastomosis between an artery and vein in a column of Bertin of child 335
271. Section of lower part of human ureter 337
272. Transverse section of the wall of the human bladder, giving a general view of its structure 338
273. Section of suprarenal cortex of dog 340
274. Arrangement of intrinsic blood-vessels in cortex and medulla of dog's adrenal (Flint) 341
275. Section from ovary of adult dog (Waldeyer) 345
276. Section from ovary of young girl 346
277–280. Sections from cat's ovary 348
281. Transverse section through the cortex of a human ovary 349
282. Representation of behavior of the chromatin during the maturation of the ovum (Rückert) 351
283. Scheme of the development and maturation of an ascaris ovum (Boveri) . . 352
284. Section of oviduct of young woman 355
285. Section from uterus of young woman 357
286. Section of human vagina (Huber) 358
287. Section of human labia minora (Huber) 359
288. Diagram showing the characteristics of spermatozoa of vertebrates 361
289. Human spermatozoa 362
290. Longitudinal section through human testis and epididymis 363
291, 292. Sustentacular cells 364
293. Section of human testis (Huber) 365
294. Section through human vasa efferentia 366
295. Cross-section of vas epididymidis of human testis (Huber) 366
296. Section of dog's testis with injected blood-vessels 367
297. Cross-section of vas deferens near epididymis (human) (Huber) 368
298. Cross-section of wall of seminal vesicle (human) (Huber) 369
299. Section of prostrate gland of man (Huber) 369
300. Schematic diagram of spermatogenesis as it occurs in ascaris (Boveri) 373
301. Schematic diagram of section through convoluted seminiferous tubule of mammal (Hermann) 375
302. Section of convoluted tubule from rat's testicle 376
303. Under surface of the epidermis 380
304. Cross-section of skin of child with injected blood-vessels 381
305. Prickle cells from the stratum Malpighii of man 382
306. Cross-section of human epidermis 383
307. Cross-section of negro's skin 384
308. A reconstruction, showing the arrangement of the blood-vessels in the skin of the sole of the foot (Spaltcholz) 385
309. Nerves of epidermis and papillæ from ball of cat's foot 386
310, 311. Meissner's corpuscle from man 387
312. Grandry's corpuscles from duck's bill 388
313. Transverse section of human scalp 390
314. Longitudinal section of human hair and follicle 391
315. Cross-section of human hair with follicle 392
316. Longitudinal section of cat's hair and follicle, showing nerve-termination . . 393
317. Longitudinal section through human nail and its groove 394
318. Transverse section through human nail and its sulcus 395
319. Coiled portion of a sweat-gland from the plantar region of a man, reconstructed by Born's wax-plate method (Huber—Adamson) 396
320. Cross-section of coiled tubule of sweat-glands from human axilla 396
321. Tangential section through coiled tubule of sweat-glands from human axilla 397
322. Sebaceous gland with a portion of the hair follicle, reconstructed by Born's wax-plate method 398

FIG. PAGE
323. Section of alveoli from sebaceous gland of human scalp (Huber) 399
324. Model of small portion of a secreting mammary gland 400
325. Section of mammary gland of nullipara (Nagel) 401
326. Transverse section through human skin 404
327. Cross-sections of human spinal cord 407
328. Schematic diagram of spinal cord in cross-section (von Lenhossék) 409
329. Schematic cross-section of spinal cord (Ziehen) 410
330. Section through human cerebellar cortex vertical to the surface of the convolution 413
331. Schematic diagram of cerebellar cortex 414
332. Cell of Purkinje from human cerebellar cortex 415
333. Granular cell from the granular layer of the human cerebellar cortex 415
334. Vertical section of human cerebral cortex 418
335. Large pyramidal cell from human cerebral cortex 419
336. Schematic diagram of cerebral cortex 420
337. Olfactory bulb 422
338. Longitudinal section of spinal ganglion of cat (Huber) 424
339. Ganglion cell from the Gasserian ganglion of a rabbit (Huber) 425
340. Diagram showing the relations of the neurones of a spinal ganglion (Dogiel) 426
341. Neurone from inferior cervical sympathetic ganglion of a rabbit (Huber) . . 427
342. From section of semilunar ganglion of cat (Huber) 428
343. From section of stellate ganglion of dog (Huber) 429
344. From section of sympathetic ganglion of turtle (Huber) 430
345. From section of sympathetic ganglion of frog (Huber) 430
346. Schematic diagram of a sensorimotor reflex arc according to the modern neurone theory 431
347. Schematic diagram of a sensorimotor reflex cycle 432
348. Schematic diagram of the reflex tracts between a peripheral organ and the brain cortex 433
349. Neurogliar cells (Huber) 434
350. Neurogliar cells from cross-section of the white matter of the human spinal cord (Huber) 436
351. Section through injected cerebral cortex of rabbit 438
352. Schematic diagram of the eye (Leber and Flemming) 447
353. Section through the anterior portion of human cornea 449
354. Corneal spaces of dog 450
355. Section through the human choroid 452
356. Meridional section of the human ciliary body 454
357. Injected blood-vessels of the human choroid and iris 456
358. Section of the human retina 458
359. Section through point of entrance of human optic nerve 460
360. Section through human macula lutea and fovea centralis 461
361. Schematic diagram of the retina (Ramón y Cajal) 463
362. Injected blood vessels of the human retina 465
363. Injected blood-vessels of human macula lutea 466
364. Vertical section of upper eyelid of man 471
365. Meibomian or tarsal gland, reconstructed after Born's wax-plate method . . . 472
366. Schematic representation of the complete auditory apparatus (Schwalbe) . . 477
367. Cross-section of the Eustachian tube 479
368. Right bony labyrinth (Quain, after Sömmering) 480
369. Membranous labyrinth from five-month human embryo (Schwalbe, after Retzius) 481
370. Transverse section through an osseous and membranous semicircular canal of an adult human being 482
371. Vertical section through the anterior ampulla 484
372. Longitudinal section of the cochlea of a cat 486
373. Section through a turn of the osseous and membranous cochlear duct of the cochlea of guinea-pig 487
374. Organ of Corti (Retzius) 490
375. Surface of organ of Corti, with surrounding structures (Retzius) 493
376. Scheme of distribution of blood-vessels in labyrinth (Eichler) 495
377. Portion of transverse section of the olfactory region of man 499

KING'S COLLEGE HOSPITAL
LIBRARY
MEDICAL SCHOOL

INTRODUCTION TO MICROSCOPIC TECHNIC.

I. THE MICROSCOPE AND ITS ACCESSORIES.

A detailed description of the microscope and its accessory apparatus hardly lies within the scope of this book. If, notwithstanding, a few points be touched upon, it is done only that the beginner may have a working knowledge of the different parts of the instrument which he must use. A more intimate knowledge of the theory of the microscope may be acquired by studying such works as those of Dippel, A. Zimmermann, and Carpenter.

Histologic specimens are examined with the aid of the microscope, an instrument which magnifies the objects by means of its optic apparatus. For this purpose **simple microscopes,** consisting of one or more converging lenses or lens systems may be used, though they generally do not give sufficient magnification to be of much service in the study of histologic specimens; they give an erect image of the object observed. When greater magnification is desired, it is necessary to use a **compound microscope,** consisting generally of two or more lens systems, giving an enlarged, inverted, real image of the object observed. The lens system of a compound microscope may be changed according to the needs of the case, and thus a variation in the magnification of the object obtained. The rest of the instrument consists of a framework called the **stand,** the lower portion of which consists of a footplate or **base.** From the base rises the column or **pillar,** to which the other parts of the microscope are attached. From below upward come the movable mirror, the stage and substage with diaphragm and condenser, and the tube with pinion and fine adjustment. One side of the mirror is concave, and serves to concentrate the rays of light in the direction of a central opening in the stage. The other side is plane. If the objects are to be examined by direct illumination, and not by transmitted light, the mirror is so placed that the rays are reflected away from the opening in the stage.

The specimen to be examined is placed on the stage, over the central opening. If the light be too strong, the opening may be diminished in size by means of a **diaphragm.** In some instruments these diaphragms are placed in the opening of the stage, and consist of plates with different sized apertures. A better form is composed of one large disc containing several apertures of different sizes. This is fastened to the under surface of the stage in such a way that by revolving the disc the apertures may be brought one

after the other opposite the opening in the stage. A much better diaphragm, constructed on an entirely different principle, is the so-called **iris diaphragm.** Although its opening is not exactly circular, yet it has the advantage of being easily enlarged or contracted by manipulating a small handle controlling the metal plates sliding over one another.

The **tube,** which is contained in a close-fitting metal sheath, is attached to the upright of the microscope. In the simpler forms

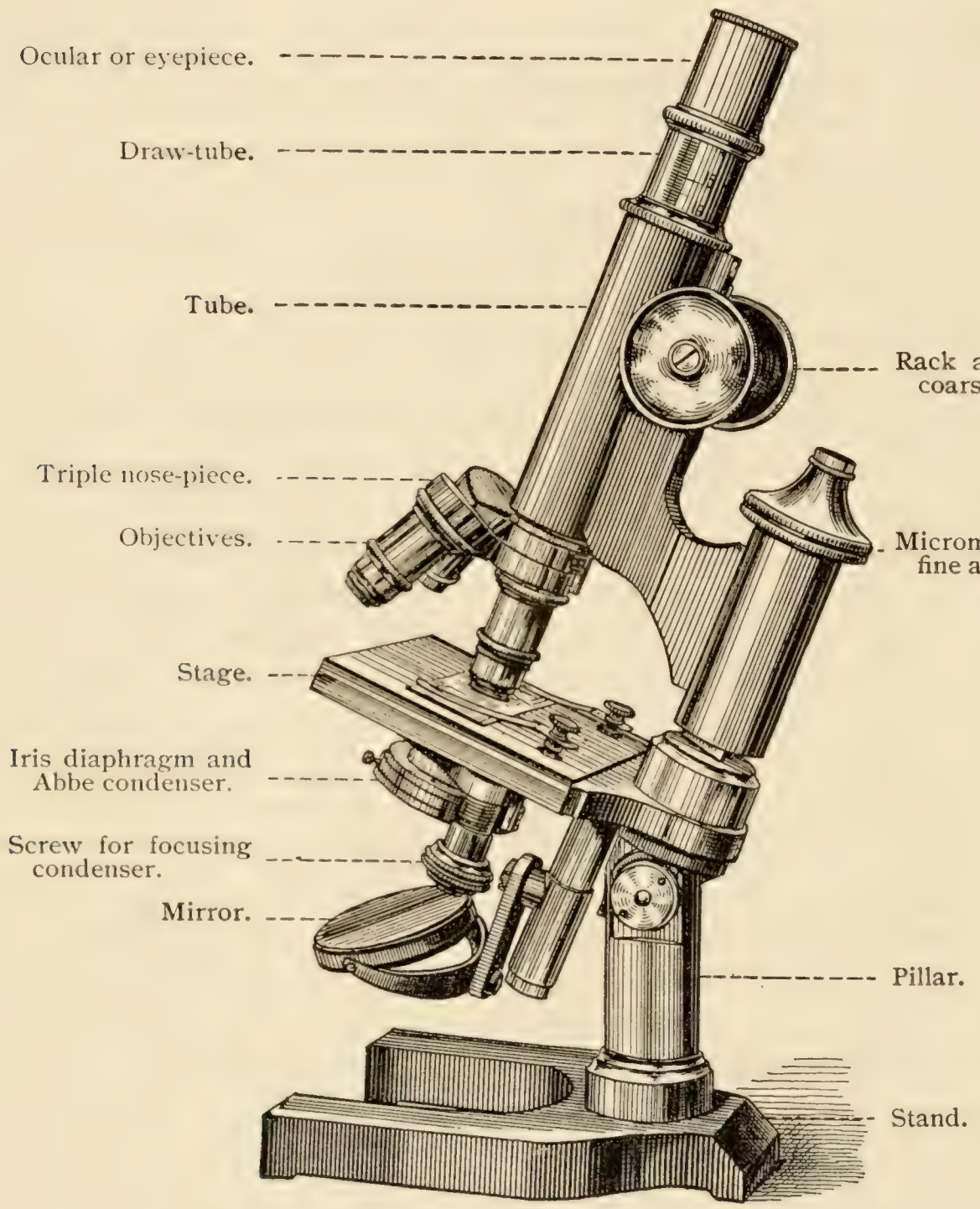

Fig. 1.—Microscope.

of microscopes the tube is raised, lowered, or twisted by hand. In more complicated instruments the upward and downward movements are accomplished by means of a rack and pinion—**coarse adjustment.** A micrometer screw—**fine adjustment**—situated at either the upper or the lower end of the upright, controls the fine adjustment. The tube possesses an upper and a lower opening, into which lenses may be laid and screwed. The **ocular,** into the ends of which lenses are inserted, fits into the upper opening. The

upper is called the *ocular lens*, the lower the *collective lens*. The **objective system,** which is a combination of several lenses or lens systems, the lowest and smallest of which is known as the *front lens*, is screwed into the lower opening of the tube.

All larger instruments possess several oculars and objectives, which together give different magnifications according to the combinations used. For most objects a magnification of 500 diameters is all that is required, but to obtain this and still have a clear and bright field the ordinary lenses are hardly sufficient. The greater the magnification, the darker is the field. To avoid this, illuminating mechanisms (**condensers,** Abbé's apparatus) have been constructed, by means of which the rays of light are concentrated and controlled. This arrangement is absolutely necessary for delicate work.

Even with the aid of such an apparatus the *dry objective systems* are not sufficient. With them the rays of light must pass through different media having various indices of refraction. The rays pass from the object through the cover-slip, and then through the air between the latter and the objective system. They are thus deflected in different directions—a defect which would be avoided if the rays were made to pass through a single medium. This latter condition may be practically brought about by placing between the objective and the cover-glass a drop of some fluid having about the same refractive index as the glass. The lens is then lowered into the fluid. As this invention has proved useful, so-called **immersion lenses** have been made during recent years. There are thus two kinds of lens systems—the dry and the immersion lenses. The latter are divided into two groups—lenses with water and those with oil immersion. As oil has a greater index of refraction than water, and one more nearly approaching that of glass, the oil-immersion lenses are at present the best objectives that we possess. Karl Zeiss, of Jena, and other microscope makers, have in late years made lenses from a special sort of glass which reduces to a minimum the chromatic and spheric aberration of the rays of light in their passage through the objective (**apochromatic lenses**).

The rays of light reflected from the mirror and passing through the object are refracted by the objective system in such a way that they are focused in a so-called *real image* at a point about half-way up the tube. This picture is an inverted one, the right side of the microscopic field being at the left of the real image, and the upper portion below. The picture is, in other words, rotated 180 degrees. By means of the ocular the real image is again magnified—*virtual image*—but no longer inverted, although to the eye of the microscopist the field actually appears inverted. To shut out the rays of light, which cause a diffused picture, diaphragms are sometimes introduced into the tube as well as into the ocular. (See Fig. 2.)

The objects to be examined are placed upon a glass plate

called a **slide.** Microscopic slides are of different sizes, and are usually oblong in shape. Those in most common use are three inches long and an inch wide. The object is covered by a very much smaller and thinner glass plate—the **cover-slip.** The whole preparation is then placed upon the stage in such a way that the cover-slip is upward and immediately beneath the end of the tube. The mirror of the microscope is now so adjusted as to concentrate the rays of light on the preparation, illuminating it as much as is necessary. By means of the rack and pinion, or coarse adjustment, the whole tube is now slowly lowered toward the cover-slip until the bare outlines of the object are dimly seen in the white field. From this point on, the micrometer screw, or fine adjustment, is used in bringing the front lens down to its proper focal distance from the preparation. The object is now seen to be clear and well defined. By turning the screw to the right or the left, different parts of the specimen are brought more clearly into view, this result being due to the fact that not all points in the preparation are in the same plane.

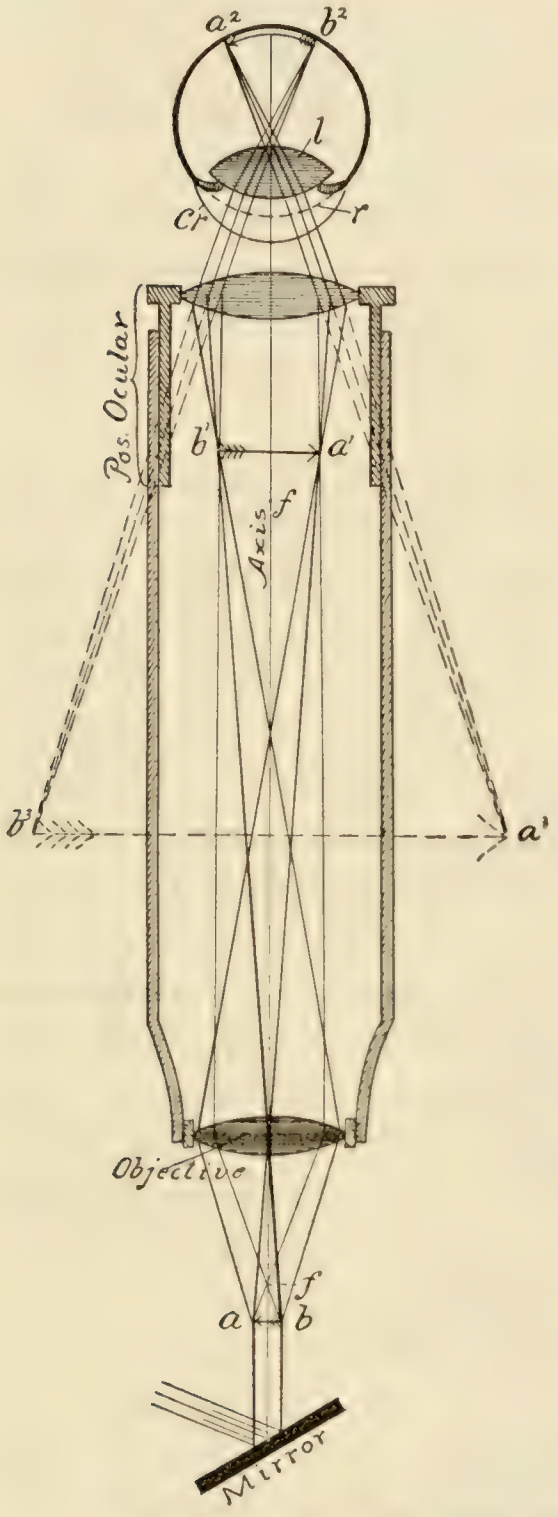

Fig. 2.—Diagram showing the principle of a compound microscope with the course of the rays from the object ($a\ b$) through the objective to the real image ($b^1\ a^1$), thence through the ocular and into the eye to the retinal image ($a^2\ b^2$), and the projection of the retinal image into the field of vision as the virtual image ($b^3\ a^3$).—(Fig 21, Gage, The Microscope, eighth edition.)

In studying objects it is always well to draw them, using a sharpened pencil and smooth paper. The beginner soon finds that with constant practice he can sketch the different parts of the field in nearly their proper relationship. This by no means easy work is facilitated by the use of a drawing apparatus called the **camera lucida.** The best of these is that devised by Abbé. It is fastened to the upper end of the tube, above the ocular. The apparatus is so made that both the preparation and the drawing surface are seen by the same eye. The microscopic field is seen directly, while the drawing surface is made visible by means of a mirror. When the apparatus is in place and the drawing commenced, it appears to the one sketching as if his pencil were moving over the preparation itself.

Outlines are reproduced on paper with great exactness both as to form and size; finer details must of course be sketched in free hand.

Every preparation should first be examined with a low power, and only after the student has studied the specimen as a whole and found instructive areas should the higher powers be used.

II. THE MICROSCOPIC PREPARATION.

In many cases the making of a microscopic preparation is a very simple procedure, especially when fresh objects are to be examined. A drop of blood, for instance, may simply be placed upon a slide, covered with a cover-slip, and examined. Other objects, as the mesentery, thin transparent nerves, detached epithelia, spermatozoa, etc., need no further preparation, but may be examined at once.

Portions of larger organs are often studied after having been **teased,** which may be done by means of two needles fastened in handles. If the objects be composed of fibers running in parallel directions, one needle is thrust into the substance to hold it in place, while the other is used to tear the fibers apart. This method is used in examining muscles, nerves, tendons, etc.

Some tissues are so constituted that they can only be investigated by means of **sections,** which permit a study of their elements and the relationship of the same to each other. In this method an ordinary razor, moistened in some fluid, may be employed. As a rule, it is not the size of the section, but the thinness, which is important. This latter is obtained only by practice. Every microscopist ought to become accustomed to making *free-hand sections* with the razor. It is the simplest of all methods, is very rapid, and is especially useful in the quick identification of a tissue. In cutting fresh so-called parenchymatous tissues, such as liver and kidney, an ordinary razor is not sufficient. Here a **double knife** is necessary. This consists of two blades, which are so placed one above the other that their distal ends touch, while their proximal ends are slightly separated. The distance of the blades from each other is regulated by a screw. If this be removed the knives may be separated for cleaning. In making sections, only those portions of the blades are of importance which are very close together but do not actually touch. Sections are cut by drawing the moistened instrument quickly through an organ, as, for instance, a fresh liver. As the organ is cut in two, a very thin section of the tissue remains between the blades. This is removed by taking out the screw and separating the blades in normal salt solution. Organs of a similar consistence can be frozen and then cut with an ordinary razor the blade of which has been cooled. Sometimes good results may be obtained by drying small pieces of tissue, as, for instance, tendon.

As sections or small pieces of fresh tissue would soon become dry when placed on the slide, they must be kept moist during examination. They are therefore **mounted** in so-called **indifferent fluids** (placed on the slide and immersed in a few drops of the indifferent fluid and covered with a cover-slip). These have the power of preserving living tissues for some time without change. Such fluids, for instance, are

the lymph, the aqueous humor, serous fluids, amniotic fluid, etc. Artificial indifferent fluids are much used and should always be kept in stock. Of this class, the following are useful:

1. Physiologic saline solution: A 0.75% solution of sodium chlorid in distilled water.

2. Schultze's iodized serum: A saturated solution of iodin or tincture of iodin in amniotic fluid.

3. Ranvier's solution of iodin and potassium iodid: A saturated solution of iodin in a 2% solution of potassium iodid.

4. Kronecker's fluid: Distilled water, 100 c.c.; sodium chlorid, 5 gm.; sodium carbonate, 0.06 gm.

5. Solution of Ripart and Petit: Copper chlorid, 0.3 gm.; copper acetate, 0.3 gm.; aqua camphoræ, 75 c.c.; distilled water, 75 c.c.; and glacial acetic acid, 1 c.c. After mixing, this solution is yellow, but clears up within a few hours, and should then be filtered.

The examination of fresh tissues comes far from revealing all the finer details of their structure. This is partly due to the fact that the indices of refraction of the different elements of the tissues are too nearly alike, in consequence of which the outlines are somewhat dimmed; and also, that changes occur, even during the most careful manipulation of the tissues, which result in pictures somewhat different from the normal. With many tissues and organs while yet fresh it is also somewhat difficult to obtain a separation of their constituent elements. It is therefore generally necessary to subject tissues or organs to special methods of treatment before they may be studied microscopically with any degree of profit. Certain of these methods, such as have proved by experience to possess reliability, shall receive consideration in the following pages.

METHODS OF MACERATION.

The reagents employed for the maceration of tissues have in general the property of softening or removing, partly or completely, certain constituents of the tissues, while they at the same time harden or fix other tissue elements. Generally the ground-substance or intercellular substance is softened or removed while the cellular or other constituents undergo fixation. Tissues thus treated when subjected to teasing, crushing, shaking, or brushing with a camel's-hair brush, are readily broken up into their constituent elements, giving useful and instructive preparations.

1. Alcohol, 30% (Ranvier). Dilute one volume of alcohol (95%) with two volumes of distilled water. Small pieces of tissue are macerated in this solution in twenty-four hours to forty-eight hours. It is often advantageous to fix the pieces thus macerated for about an hour in $\frac{1}{2}$% to 1% osmic acid. Useful for macerating epithelia.

2. Dilute solutions of chromic acid, $\frac{1}{5}$% to $\frac{1}{10}$%. Small pieces of tissue remain in this solution one to several days. Useful for macerating epithelia.

3. Concentrated aqueous solution of caustic potash. Small pieces of tissue are macerated in fifteen minutes to an hour. They are then transferred to a saturated aqueous solution of acetate

of potassium, which interrupts the action of the macerating fluid. Useful for macerating epithelia and involuntary and heart muscle.

4. Hydrochloric acid, 20% to 30% aqueous solution. Macerates small pieces of tissue in twelve to twenty-four hours. The pieces are then thoroughly washed in water. Useful for isolating the uriniferous tubules and macerating glands.

5. Nitric acid, 10% to 20% aqueous solution or made up with normal salt solution. Macerates small pieces of tissue in twenty-four to forty-eight hours. Wash thoroughly in water. Useful for macerating involuntary and voluntary muscle.

6. J. B. MacCallum ("Contributions to Medical Science," Baltimore, 1900) recommends the following nitric acid mixture for isolating heart-muscle fibers of embryos and adults: Nitric acid, 1 part; glycerin, 2 parts; water, 2 parts. The hearts remain in this fluid from eight hours to three days, according to their size, and are then transferred to a 5% aqueous solution of glycerin. This method is especially useful for obtaining preparations showing the arrangement of the heart-muscle fibers.

7. Nitric acid and chlorate of potassium (Schulze). Powder the chlorate of potassium and add sufficient nitric acid to make a thin paste. Embed the tissue to be macerated in this paste, in which they remain from one to several hours. They are then washed in water. Useful for isolating the branched, voluntary muscle-fibers of the tongue of a frog.

8. Concentrated sulphuric acid. Useful for isolating the cornified cells of the epidermis, nails, and hair.

FIXING METHODS.

The fixing fluids most used for general purposes are the following:

Alcohol.—Alcohol is frequently used as a fixing fluid. It is at the same time a hardening fluid, as the water of the tissues is withdrawn and their albumin coagulated. Small or thin pieces are put immediately into absolute alcohol, in which they remain for from twelve to twenty-four hours. The period required for fixation may be greatly shortened by changing the absolute alcohol at the end of one or two hours. In the case of larger pieces, a successive immersion in gradually increasing strengths of alcohol (50%, 70%, 90%) is the method chosen. Pieces 1 c.c. in size remain for twenty-four hours in each grade of alcohol, larger pieces for a proportionately longer time. Alcohol used in this way is a hardening fluid rather than a fixing fluid.

Carnoy's Acetic-alcohol Mixture.—

Glacial acetic acid	1 part.
Absolute alcohol	3 parts.

Fixes very rapidly. Pieces of 1 centimeter in thickness are fixed in one-half hour to one hour. The after-treatment is with absolute alcohol, which should be renewed at the end of twenty-four hours.

Carnoy's Acetic Acid-alcohol-chloroform Mixture.—

Glacial acetic acid	1 part.
Chloroform	3 parts.
Absolute alcohol	6 "

Fixes very rapidly, even larger pieces in from one-half to one hour. The after-treatment is with absolute alcohol.

Osmic acid is a reagent that kills quickly, fixes protoplasm exceedingly well, but nuclei not so well, and colors certain tissues. Only small pieces can be fixed in this fluid, as it does not easily penetrate the tissues. It is ordinarily used in a ½% to 1% aqueous solution, the objects remaining immersed twenty-four hours. They are then washed in running water for the same length of time, after which they are transferred to 90% alcohol. Very small objects may be treated with osmic acid in the form of vapor (vaporization). This is done as follows: A very small quantity of osmic acid solution is put in a small dish. The object is then suspended by a thread in such a way that it does not come in contact with the fluid. The dish should be covered with a well-fitting lid.

Flemming's Solution.—A solution with a similar action, but fixing nuclear structures better than osmic acid, is the chromic-osmic-acetic acid solution of Flemming:

Osmic acid, 1% aqueous solution . .	10 parts.
Chromic acid, 1% aqueous solution . . .	25 "
Glacial acetic acid, 1% aqueous solution .	10 "
Distilled water	55 "

Small pieces are fixed in a small quantity of the fluid for at least twenty-four hours, sometimes for a longer period, extending even to weeks. They are then washed for twenty-four hours in running water and passed through 50%, 70%, and 80%, each twenty-four hours, into 90% alcohol.

Flemming also recommends a stronger solution, which is made as follows:

Osmic acid, 2% aqueous solution	4 parts.
Chromic acid, 1% aqueous solution . . .	15 "
Glacial acetic acid	1 part.

Fol's Solution.—Fol has recommended the following modification of Flemming's solution:

Osmic acid, 1% aqueous solution	2 parts.
Chromic acid, 1% aqueous solution . . .	25 "
Glacial acetic acid, 2% aqueous solution .	5 "
Distilled water	68 "

The after-treatment is the same as for Flemming's solution.

Hermann's Solution.—Very good results sometimes follow the use of the platinum-acetic-osmic acid solution of Hermann (89, 1). It is employed as is Flemming's solution:

Osmic acid, 2% aqueous solution	4 parts.
Platinum chlorid, 1% aqueous solution . .	15 "
Glacial acetic acid	1 part.

After fixing with this solution, Flemming's solution, or any other osmic mixture, the subsequent treatment with alcohol may be followed by crude pyroligneous acid. The objects are placed for from twelve to twenty-four hours in the latter and then again immersed in alcohol. The result is a peculiar coloring of the specimen which often makes subsequent staining (see below) unnecessary (Hermann).

Corrosive Sublimate.—An excellent fixing fluid is made by saturating distilled water or a physiologic saline solution (see p. 22) with

corrosive sublimate. Small pieces, about 0.5 cm. in diameter, are immersed in this fluid for from three to twenty-four hours, are then washed in running water for twenty-four hours, and then transferred into 70% alcohol. After twenty-four hours the tissues are placed in 80% for the same length of time, and then preserved in 90% alcohol. It often occurs that after changes in temperature crystals of sublimate are formed on the surface or in the interior of the object. For their removal a few drops of a solution of iodin and potassium iodid are added to the alcohol (P. Mayer). It is a matter of indifference whether the 70%, 80% or 90% alcohol is thus iodized. In the further treatment of the object, as well as in sectioning, any such crystals of sublimate will not be found to be a hindrance. Indeed, in the case of very delicate objects it is often more advantageous to undertake their removal *after* sectioning by adding iodin to the absolute alcohol then used.

Acetic Sublimate Solution.—This is an excellent fluid, and at present much used for embryonic tissues and for organs containing only a small quantity of connective tissue. To a saturated aqueous solution of sublimate, 5% to 10% of glacial acetic acid is added. After remaining two or three hours or more in this solution, the objects are transferred to 35% alcohol, after which they are passed through the higher grades of alcohol.

Picric Acid.—Small and medium-sized objects (up to 1 c.c.) are fixed in twenty-four hours in a saturated aqueous solution of picric acid (about 0.75%), although an immersion lasting for weeks is not detrimental, especially if the objects be of considerable size. The tissues are transferred to 70% or 80% alcohol, in which they remain until the alcohol is not colored by the picric acid. They are then preserved in 90% alcohol.

Instead of a pure solution of picric acid, the **picrosulphuric acid** of Kleinenberg or the **picric-nitric acid** of P. Mayer may be used. The first is made thus: 1 c.c. of concentrated sulphuric acid is added to 100 c.c. of a saturated aqueous picric acid solution. This is allowed to stand for twenty-four hours, then filtered, and diluted with double its volume of distilled water. The picric-nitric acid solution is made by adding 2 c.c. of pure nitric acid to 100 c.c. of a saturated picric acid solution. Filter after standing for twenty-four hours.

Rabl's Solutions.—C. Rabl (94) recommends the following mixtures, especially for embryos: (1) Concentrated aqueous solution of corrosive sublimate, 1 vol.; concentrated aqueous solution of picric acid, 1 vol.; distilled water, 2 vols. (2) 1 per cent. aqueous solution of platinum chlorid, 1 vol.; concentrated aqueous solution of corrosive sublimate, 1 vol.; distilled water, 2 vols. In both cases, after being washed twelve hours in water (in the first preferably in alcohol) the specimens are transferred to gradually increased strengths of alcohol.

Vom Rath's Solutions.—O. vom Rath (95) recommends, among others, the following two solutions: (1) **Picric-osmic-acetic acid solution.** Add to 1000 c.c. of a cold saturated picric acid solution 1 gm. of osmic acid, and after several hours 4 c.c. of glacial acetic acid. Objects are fixed, according to their size, in four, fourteen, and forty-eight hours, and then transferred to 75% alcohol. (2) **Picric-sublimate-osmic acid solution.** A mixture of 100 c.c. of a cold saturated aqueous picric acid solution with 100 c.c. of saturated sublimate solution is made, into which is poured 20 c.c. of a 2% osmic acid solu-

tion. 2 c.c. of glacial acetic acid may also be added. Tissues fixed by either of these fluids may be treated with pyroligneous acid or tannin. The crystals of sublimate must be removed by iodized alcohol.

Nitric Acid.—Small objects may be fixed in about six hours in 3% to 5% nitric acid (sp. gr. 1.4). A longer immersion is injurious, as certain nuclear structures are affected. After washing thoroughly in running water, the tissues are treated as usual with alcohols of increasing concentration.

Chromic acid is used in a ⅓% to 1% aqueous solution. Small pieces are fixed for twenty-four hours, larger ones for a longer time, even weeks. The quantity of the fixing fluid should be at least more than fifty times the volume of the tissues to be fixed. The objects are subsequently washed in running water and run through the ascending alcohols. This last should be done in the dark.

Two or 3 drops of formic acid may be advantageously added to each 100 c.c. of chromic acid solution (C. Rabl).

Müller's Fluid.—

Potassium bichromate	2 to 2.5 gm.
Sodium sulphate	1 "
Water	100 c.c.

With this solution it requires several weeks for proper fixation, and the process must be conducted in the dark. During the first few weeks the solution should be changed every few days, and later once a week. According to the results desired, the pieces are either washed out in running water and subsequently treated in the usual manner with alcohol, or they are placed directly in 70%, which is later replaced by 80 % and 90% alcohol. It is important that all these procedures should take place in the dark.

The use of **Erlicki's fluid** (potassium bichromate, 2½ gm.; cupric sulphate, 0.5 gm., and water, 100 c.c.) is quite similar to that of Müller's, except that it acts much more quickly. A temperature of 30° C. to 40° C. shortens the process in both cases considerably, Müller's fluid fixing in eight and Erlicki's in three days.

Tellyesnicky's Fluid.—This solution gives better nuclear fixation than Müller's fluid.

Potassium bichromate	3 gm.
Glacial acetic acid	5 c.c.
Water	100 "

Small pieces of tissue remain in this fluid for one or two days. Larger pieces may also be used, but require a longer period of fixation. Wash thoroughly in flowing water. Dehydrate in graded alcohol, beginning with 15%.

Zenker's Fluid.—

Potassium bichromate	2.5 gm.
Sodium sulphate	1 "
Corrosive sublimate	5 "
Glacial acetic acid	5 c.c.
Water	100 "

It is advisable to add the glacial acetic acid in proper proportion to the quantity of the solution to be used, and not to add it to the stock solution. The tissues are allowed to remain for from six to twenty-four hours in this

mixture, in which they float for a short time. They are then washed in running water for from twelve to twenty-four hours, and transferred to gradually concentrated alcohols. Crystals of sublimate which may be present are removed with iodized alcohol. Zenker's fluid penetrates easily, and fixes nuclear and protoplasmic structures equally well without decreasing the staining qualities of the elements.

Formalin (Formol).—Of recent years formalin, which is a 40% solution of the gas formaldehyd in water, has been much used as a fixing fluid. It is best employed in the form of a solution made by adding 10 parts of formalin to 90 parts of water or normal saline solution. Small pieces of tissue remain in this solution for from twelve to twenty-four hours, larger pieces or organs a number of days or weeks, and are then transferred to 90% alcohol.

Potassium Bichromate and Formalin.—

Potassium bichromate, 2% to 3% aqueous solution	90 parts.
Formalin	10 "

Tissues remain in this fluid from several days to several weeks, depending on their size. Wash thoroughly in water and dehydrate in alcohol. Useful for fixation of central nervous system.

We have attempted to give only the fixing and hardening fluids commonly employed for general purposes. There are numerous other fluids used for special purposes; these will be noticed under the headings of the corresponding tissues and organs.

INFILTRATION AND IMBEDDING.

Few tissues have a consistency, even after fixation, which enables them to be cut into sections thin enough to be studied under high magnification, without being especially prepared for this purpose. To admit of sectioning, it is generally necessary to imbed them in media which offer no resistance to the knife, while giving them firmness, and do not obscure the structure of the sections when cut, or which may be removed from the sections by methods which are not harmful to them. The media used for imbedding may be classed under two heads: (1) Such as are fluid when warm, and may in this state be caused to penetrate the tissue, and are solid when cold; (2) such as are fluid when in solution, and in this state will penetrate tissues, but which become solid on the evaporation of the solvent. The best example of the former class of substances is paraffin; and of the latter, celloidin (collodion or photoxylin).

1. PARAFFIN IMBEDDING.

In describing the method of paraffin infiltration and imbedding it is assumed that the tissues have been previously fixed and hardened and are in alcohol ready for further manipulation. From the hardened tissues small flat pieces are cut with a sharp knife or razor. If possible, they should be square, rectangular, or triangular in shape, their surfaces not exceeding ½ square inch, and their thickness from ⅛ to ¼ of an inch. Pieces of larger size may be imbedded, if desired, provided the requisite care be exercised. The pieces selected are placed in absolute alcohol, in which they remain until thoroughly dehydrated. From the latter they

can not be passed directly into paraffin, as alcohol dissolves only a small percentage of paraffin, and, consequently, the preparation would not be infiltrated with the imbedding mass. The pieces of tissue are therefore first placed in some fluid which mixes with absolute alcohol and at the same time dissolves the paraffin. There are many reagents which have this property, such as xylol, toluol, chloroform, and a number of oils (oil of turpentine, oil of cedar, oil of origanum, etc.). Of these xylol may be recommended for general use. In the xylol the tissues remain for from two to twelve hours, the time depending somewhat on the size of the pieces and on the density of the tissue. When thoroughly permeated by the xylol, they are transparent. From the xylol (toluol, chloroform, or oils) the tissues are placed in melted paraffin. Two kinds of paraffin are generally used, one having a melting point of 38° to 40° C.—soft paraffin—and another with a melting point of 50° to 58° C.—so-called hard paraffin. The paraffin should always be filtered before using. This is best done by using a hot-water filter. It is essential that melted paraffin have a constant temperature while the tissues are being infiltrated. This is attained by placing the receptacle containing the paraffin in a paraffin oven regulated by means of a thermostat to a temperature about two degrees above the melting point of the hard paraffin.

Fltered hard and soft paraffin may be kept in suitable glass beakers in respective compartments in the paraffin oven. After the tissues are thoroughly permeated with the xylol, this is poured off and melted soft paraffin added, and the dish replaced in the paraffin oven. In the soft paraffin the tissues remain from one to four hours, at the end of which time the soft paraffin is poured off and hard paraffin added, and the dish again placed in the oven. In the hard paraffin the tissues remain from two to twelve hours, depending on the size of the pieces. They are now ready to be imbedded. Two metallic L's are placed together on a glass or metal plate in such a way as to make a rectangular box. (Fig. 3.) This is filled with melted hard paraffin taken from the oven. Before the paraffin cools, the piece of tissue to be imbedded is taken from the hard paraffin in the oven and placed with one of its flat surfaces against one end of the box. If several pieces of tissue are to be imbedded, a piece may thus be placed in each end of the box. While transferring the tissues from the hard paraffin to the imbedding box they should be handled with forceps, the blades of which have been warmed in a flame. As soon as the paraffin in which the tissues are imbedded has cooled sufficiently to allow the formation of a film over the melted paraffin, the imbedding box is placed in a dish of cold water. This cools the paraffin quickly and prevents its becoming brittle. A stay of from five to ten minutes in the cold water hardens the paraffin so that the L's may be removed, and the paraffin block containing the imbedded tissue may be taken from the plate. It is well to place the paraffin block thus obtained back into the cold water for a short time, so that it may become hard all the way through. As the paraffin often adheres closely to the glass or metal plate and the L's, it is advisable to cover these parts with a very thin layer of glycerin before imbedding. There is then no difficulty in separating them from the paraffin block.

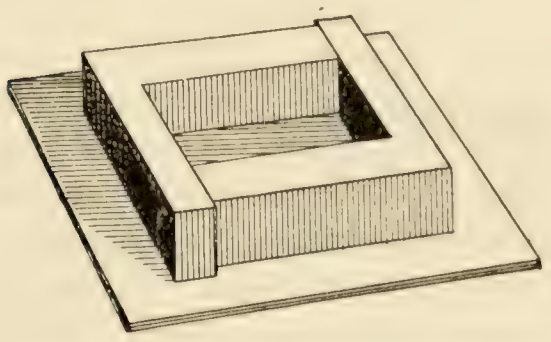

Fig. 3.—Box for imbedding tissues.

If a large number of small pieces of tissue are to be imbedded, it is often more convenient to imbed them in a small flat dish of suitable size. The dish to be used is covered on its inner surface with a thin layer of glycerin and partly filled with hard paraffin and the several pieces of tissue to be imbedded transferred to it and arranged on the bottom of the dish. As soon as a film forms over the paraffin the dish is placed carefully in cold water and the paraffin allowed to harden. The large piece of paraffin thus obtained may then be cut into several smaller pieces, each containing a piece of the imbedded tissue.

On transferring an object from one fluid into another, so-called *currents of diffusion* occur, which produce, especially in such tissues as contain cavities, shrinkage and tearing. This often results in totally changing the finer structure of the tissues. It is therefore necessary to proceed with greater caution than in the method above indicated. Mixtures containing different percentages of alcohol and the intermediate fluid (xylol, toluol, chloroform) may be prepared, and the object, according to its delicacy, passed through a greater or smaller number of such solutions. In ordinary cases a single mixture of alcohol and the intermediate fluid is sufficient, the object remaining in the solution for a length of time varying with its size before being passed into the pure intermediate fluid. This part of the treatment may of course be slowed or hastened according to the number of such mixtures, each succeeding one containing more and more of the intermediate fluid. After the object has been passed into the pure intermediate fluid it should be just as carefully passed into the infiltrating fluid. If paraffin is to be used and the object be delicate, the following method is advisable: The object is placed in a glass vessel half filled with the intermediate fluid, into which a few pieces of soft paraffin are dropped. The vessel is then covered and allowed to remain at the temperature of the room. When the paraffin is dissolved the cover is removed and the vessel placed in a paraffin oven kept at a temperature corresponding to the melting point of the paraffin. The volatile intermediate fluid evaporates gradually, and in a few hours the object is infiltrated with an almost pure soft paraffin. It may now be transferred into pure melted hard paraffin. In this the tissue remains for a longer or shorter time, according to its size.

It is often of advantage to infiltrate the tissues in a *partial vacuum*. In this way there is obtained a better infiltration of the tissues with the paraffin, and this seems to obtain a better consistency. Especially is this method to be recommended in imbedding larger embryos or tissue with cavities. A simple and convenient method is as follows: a glass bottle of suitable size is warmed and partly filled with melted hard paraffin and placed at one end of a copper plate, the other end of which is heated by a flame, care being taken to heat the copper plate only sufficiently to keep melted the paraffin in the bottle. The bottle is fitted with a rubber cork with two holes, into which have been inserted two L-shaped glass tubes, provided, the one with a short rubber tube, which is clamped, the other with a tube of sufficient length to reach to a Chapman water-pump. The tissues are placed in the paraffin, the bottle tightly corked, and the water-pump allowed to play for about half an hour, after which the tissues are imbedded in the paraffin used during this procedure.

High temperatures are, as a rule, injurious to tissues. This should always be borne in mind, and the student should aim to keep his specimens at the lowest possible temperature conducive to proper infiltration. If for any reason higher temperatures become necessary, the ex-

posure of the tissues to their action should be as brief as possible. The paraffins most used have a melting point of 40° to 60° C. The kind of paraffin used should depend upon the temperature of the room in which the sectioning is to be done. It is even well to have different mixtures of hard and soft paraffins at hand, so that, if the temperature of the room be low, tissues may be imbedded in a softer mixture, and vice versa.

The process of infiltrating and imbedding in paraffin is represented by the following diagram (instead of xylol, other intermediate fluids may be used):

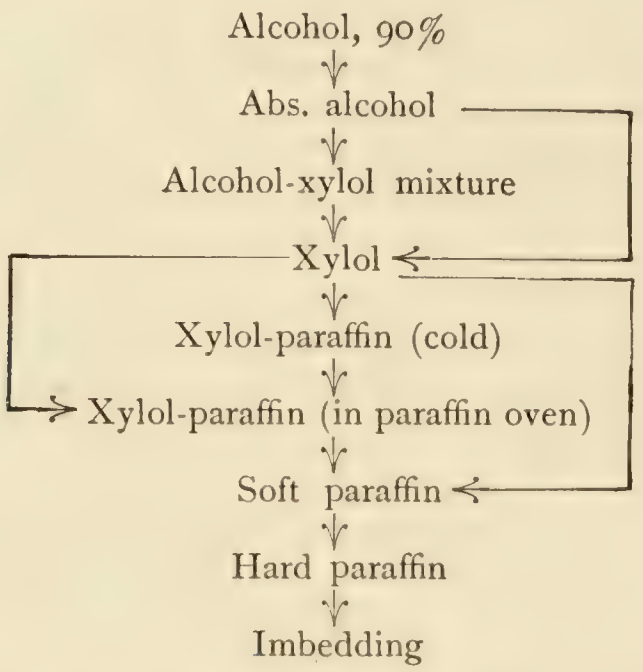

The size and density of the tissues must necessarily regulate the length of time necessary for their proper infiltration. It is therefore hardly possible to give any definite figures. In presenting the following table we have taken as a standard any tissue that has the general consistency of liver fixed in alcohol. The time is given in hours, and should in each case be regarded as a minimum. A longer stay in any one fluid will, under favorable circumstances, do no harm.

	Small Objects under 1 mm. in Diameter.	Middle-sized Objects up to 5 mm. in Diameter.	Large Objects up to 10 mm. in Diameter.	Very Large Objects, although not More than a Few cm. in Diameter.
Absolute alcohol . . .	2	6	24	For a longer or shorter time in the fluids, according to the size of the object.
Xylol	½	3	6	
From now on in paraffin oven:				
Soft paraffin	½	3	6	
Hard paraffin	1	3	6	

2. CELLOIDIN.

The best and most convenient celloidin to use in microscopic work is Schering's granular celloidin, put up in 1-ounce bottles. Of this a stock or thick solution is prepared by dissolving 6 gm. of the celloidin in 100 c.c. of equal parts of absolute alcohol and ether. Of this, when required, a thin solution is prepared by diluting a quantity of the stock solution with an equal quantity of the ether and alcohol solution.

The hardened tissues are cut into small pieces, which should not be much more than ⅛ of an inch in thickness and not have a surface area of more than ¾ of a square inch. Much larger pieces of tissue may be imbedded in celloidin. This is not advised, however, unless it is necessary to show the whole of the structure to be studied. The pieces to be imbedded are placed for twenty-four hours in absolute alcohol, and are then transferred for twenty-four hours to a mixture of equal parts of absolute alcohol and ether. Then they go into the thin celloidin solution, where they remain for from twenty-four hours to several days, depending on the size and density of the pieces to be imbedded. The pieces of tissue are then transferred to the thick celloidin solution, where they again remain for from twenty-four hours to several days. If it is desired to imbed large pieces, especially if these be of the medulla or brain, the stay in the celloidin solutions should be lengthened to several weeks. The hardening of the celloidin may now be obtained by one of several methods.

A sufficient quantity of the stock or thick celloidin solution to cover well the tissues to be imbedded is poured into a flat dish large enough to allow the pieces to be imbedded to be arranged on its bottom and leave a space of about ¼ of an inch between adjacent pieces. The dish is then covered, not too tightly, and set aside to allow the ether and alcohol to evaporate. In one or two days the celloidin is usually hard enough to cut into small blocks, each block containing a piece of the imbedded tissue. The blocks of celloidin are now further hardened by placing them in 80% alcohol. A stay of several hours in this alcohol is usually sufficient to give them the hardness required for section cutting. After the celloidin pieces have obtained the right degree of hardness they are to be stuck to small pieces of pine wood or vulcanized fiber so that they may be clamped into the microtome. This is done in the following way: A piece of celloidin containing a piece of tissue is trimmed with a sharp knife so that only a rim of celloidin about $\frac{1}{12}$ of an inch in thickness surrounds the piece of tissue. It is now placed for a few moments in the ether and alcohol solution. This is to soften the surfaces of the celloidin. One end of a small pine-wood or vulcanized-fiber block about one inch long, the cut end of which has a surface area slightly larger than the celloidin block, is dipped for a few moments into the ether and alcohol solution and then into the thick celloidin. The celloidin block is now taken from the ether and alcohol solution, dipped into the celloidin, and pressed against the end of the wooden or vulcanized-fiber block, which has been coated with the celloidin. The whole is now set aside for a little while to allow the celloidin to harden slightly, and is then placed in 80% alcohol. In the alcohol it may remain indefinitely; it may, however, be used for cutting as soon as it again becomes hard.

The piece of tissue to be imbedded may be mounted at once on pine-wood or vulcanized-fiber blocks from the thick celloidin solution by pouring a small amount of thick celloidin over one end of the block and placing the piece of tissue from the thick celloidin solution onto the layer of celloidin on the block. In three to four minutes a layer of the thick celloidin solution is poured over the piece of tissue and the end of the block. It may be necessary to do this several times if the piece of tissue is large or of irregular shape. The block is now set aside for about five minutes, and is then placed in 80% alcohol, where it remains until the celloidin is hard, or until it is desired to cut sections.

The tissues may be imbedded by pouring the thick celloidin, together with the objects, into a small box made of paper. The surface of the celloidin hardens in about an hour (preliminary hardening), after which the whole is transferred to 80% alcohol, in which the final hardening takes place. The paper is then removed, the block of celloidin trimmed to a convenient size and fastened on a block.

While being cut, celloidin preparations are kept moistened with 80% alcohol. Organs consisting of tissues of varying consistency, as well as very dense objects, can be cut with better results in celloidin than in paraffin. On the other hand, celloidin sections can never be cut as thin as paraffin sections, and the after-treatment (see below), fixation on the slide, etc., are much more complicated than in the case of paraffin sections.

The following is a diagram showing the process of infiltration and imbedding in celloidin.

90% alcohol
↓
Abs. alcohol
↓
Abs. alcohol and ether (in equal parts)
↓
Thin celloidin solution
↓
Thick celloidin solution
↓
Imbedding
↓
80% alcohol

3. CELLOIDIN-PARAFFIN.

To combine the advantages which infiltration in celloidin and in paraffin offer, a method of celloidin-paraffin infiltration is recommended. Preparations that have been imbedded in celloidin or photoxylin and hardened in 80% alcohol are placed for about twelve hours in 90% alcohol, from which they are transferred to a mixture of equal parts of oil of origanum and 90% alcohol. They are then immersed for a short time in pure origanum oil, then in a mixture of equal parts of origanum oil and xylol, and finally in pure xylol. From this point the regular method of infiltrating with paraffin is followed, care being taken that the pieces remain for as short a time as possible in the different fluids, in order that the celloidin may not become brittle.

Very thin sections may be obtained by painting the cut surface with a thin layer of a very dilute celloidin solution. This hardens and gives the tissue a greater consistency. This treatment is useful in the combined celloidin-paraffin method, as well as when paraffin alone is used.

THE MICROTOME AND SECTIONING.

Instruments known as microtomes have been devised in order that section cutting may be rendered as independent as possible of the skill of the individual, but more especially to obtain series of sections of uniform thickness. Their construction varies greatly. Some of these in-

struments, as the so-called **rocking** microtomes, are so specialized that they only cut paraffin objects when the knife is transversely placed. Others have a more general function, celloidin as well as paraffin objects being sectioned with the knife in any position. To the latter class belong the **sliding** microtomes.

In figure 4 is shown an instrument which may be recommended for general laboratory work. This instrument consists of a horizontal base which rests on the table, and a vertical plate (*a*), and a slide (*b*) which supports a block (*c*), to which is fastened a knife by means of a thumb-screw (*d*). On the other side of the vertical plate is a metal frame (*e*), into which are fastened the paraffin and celloidin blocks; this frame is attached to a slide (*f*), which may be elevated or lowered by a feed (*g*). This feed consists of a micrometer screw acting on the lower surface of the slide. The micrometer screw is provided with a milled head, divided into a definite number of parts which bear a definite rela-

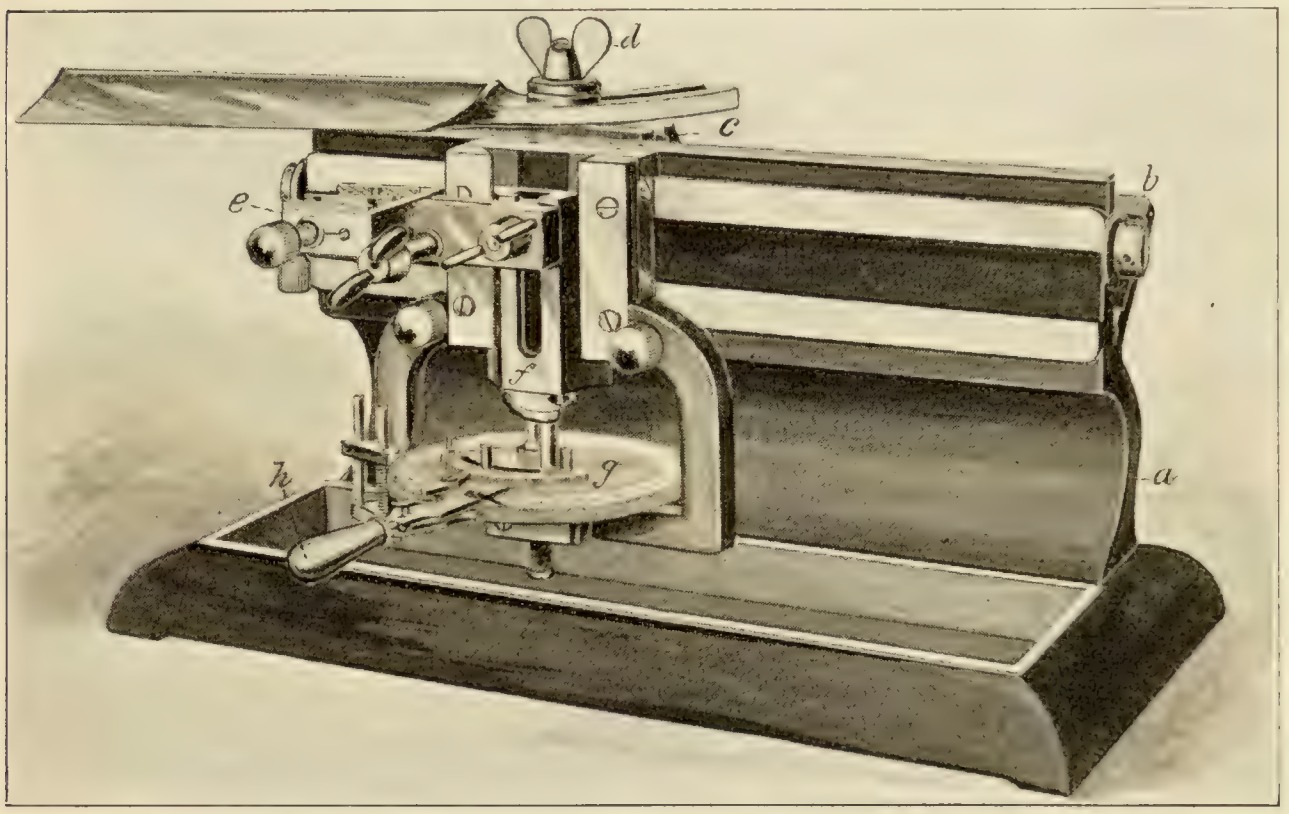

Fig. 4.—Laboratory microtome.

tion to the pitch of the micrometer screw. The instrument shown in the figure is further provided with a lever (*h*), which may be so adjusted as to move the milled head on the micrometer screw 1 or any given number of notches at each movement of the lever; and as each notch on the milled head has a value of 5 microns ($\frac{1}{5000}$ of an inch), every time the milled head is moved 1 notch (toward the manipulator) the slide carrying the clamp holding the tissue is elevated 5 microns; 2 notches would elevate the tissue 10 microns ($\frac{1}{2500}$ of an inch); 4 notches, 20 microns ($\frac{1}{1250}$ of an inch), etc. It is not essential to have a lever attached to the instrument as above described, although this is very convenient; if not present, the milled head is moved the desired number of notches with the hand.

Minot has recently devised two kinds of microtomes which deserve special mention, and are especially to be recommended for accurate work. One of these (see Fig. 5) is known as the "Precision Microtome." It consists of a square frame made of cast-iron, to which the knife is fastened.



Fig. 5.—Minot automatic precision microtome.



Fig. 6.—Minot automatic rotary microtome.

Beneath the frame which supports the knife are two horizontal ways, upon which runs the sliding carriage supporting an adjustable object-carrier. The object is raised by a micrometer screw, fed automatically by a large-toothed wheel attached to the bottom of the screw. Both paraffin and celloidin sections may be cut with this instrument. The other type of microtome is known as the "New Rotary Microtome." In this instrument (see Fig. 6) the knife is carried by two upright standards which can be adjusted as to their distance from the object. The object, which needs to be imbedded in paraffin, is fixed to an object-carrier, which may be adjusted to any plane, and which is fixed to a vertical carriage, held by adjustable gibs against the vertical ways, and which is raised or lowered by a crank, working in a slide, and attached to an axle turned by the wheel. The vertical carriage also carries the micrometer screw, to which is attached a toothed wheel; this is turned by a pawl which acts upon it. This instrument may be most highly recommended for the cutting of serial sections.

In cutting **paraffin sections** with the sliding microtome the knife is placed at an angle of about 35° to 40° to the horizontal plate of the microtome. Sections are cut more easily with the knife in this position than when the knife is placed at right angles to the microtome, as is often recommended, and it does not seem that the tissues suffer materially from distortion when they are cut with the knife at an angle, as is sometimes claimed.

Before fastening the paraffin blocks into the clamp on the microtome, preparatory to cutting sections, the paraffin is trimmed with a sharp knife from the end of the paraffin block until the tissue is nearly exposed, care being taken, however, to leave a flat surface. The top of the paraffin block is then beveled off on three sides to within a very short distance of the tissue. The fourth side, that which faces the knife when the block is clamped in the microtome, should be trimmed only to within about $\frac{1}{8}$ of an inch of the tissue. This edge of paraffin is made use of, as will be seen in a moment, for preventing the sections from curling while they are being cut. The paraffin block is now ready to be clamped in the microtome. This is done in such a way that the paraffin block just escapes the knife when drawn over it. A number of rather thick sections (20 to 40 microns) are cut by moving the micrometer screw from right to left 4 to 8 notches every time the knife has been drawn over the paraffin block and has been brought back again, until it is noticed that the knife touches all parts of the top of the paraffin block, or until the tissue is fairly exposed. (In this description reference is made to the simple laboratory microtome shown in Fig. 4.) The succeeding sections may now be kept. It may perhaps be well to state that it is better not to try to cut very thin sections at the beginning; sections 15 to 20 microns in thickness will answer very well. To begin with, then, the milled head of the micrometer screw is turned 4 notches from left to right, and the knife is drawn over the block with a steady, even pull, and without using undue pressure. Usually the sections will curl up as they are being severed from the paraffin block. This may very readily be prevented by holding the tip of a camel's-hair brush, which has been pointed by drawing it between the lips, against the edge of the section as soon as it begins to curl. A little practice will enable one to do this almost automatically. The sections are transferred to paper by means of the camel's-hair brush, which process is facilitated if the brush has been slightly moistened with saliva, as the section will then adhere lightly to the brush.

If the tissues are well imbedded and not too hard, and if the knife is sharp and properly adjusted, paraffin sections may be cut in such a way that each succeeding section adheres to the preceding one, so that actual ribbons of paraffin sections may be made. In order to do this, the knife should be at right angles to the microtome. The paraffin block should be trimmed in such a way that when clamped in the microtome ready for cutting sections, the surface of the paraffin block facing the knife should be exactly parallel to its edge, also to the opposite side of the block. In other words, 2 sides of the paraffin block should be parallel to each other and to the knife; then if the paraffin is of the right consistency, which must be ascertained by trying, the sections as they are cut will adhere to each other and form a ribbon. If the sections do not adhere to each other it is quite probable that the paraffin is a little too hard. This may often be remedied by holding an old knife or other metallic instrument which has been heated in a flame near the two parallel surfaces for a few moments. Care should be taken not to allow this instrument to touch the paraffin. This is a very convenient and rapid way of cutting paraffin sections. To facilitate the cutting of a paraffin possessing a relatively low melting point in a room with a high temperature, the cooled knife of Stoss may be used. This is so made that a stream of ice-water may be passed through a tube running through the entire length of the back of the blade. Paraffin sections may be cut in ribbons—serial sections—on an ordinary sliding microtome; for this purpose, however, the "automatic rotary microtome" of Minot is especially recommended.

Celloidin Sections.—Before fastening the block of wood or vulcanized fiber to which the celloidin blocks have been fixed in the clamp on the microtome, the celloidin should be trimmed with a sharp knife from the top of the block until the tissue is nearly exposed, care being taken to leave a flat surface. The sides of the celloidin block are then trimmed down, if necessary, to within about $\frac{1}{16}$ of an inch of the tissue. The block is now clamped in the microtome at such a level that it just escapes the knife when drawn over it. The knife is placed at an angle of about 45°, or at even a greater angle. During the process of cutting, the knife, as also the tissue, must be kept constantly moistened with 80% alcohol. This is perhaps most easily accomplished by taking up the 80% alcohol with a rather large camel's-hair brush and dipping this on the celloidin block and on the knife. A number of rather thick sections are cut until the knife touches the entire surface of the block or until the tissue is well exposed. The sections may now be kept. The block is raised 20 to 15 microns, and the knife, which should be well moistened with 80% alcohol, is drawn over the block with a steady pull, not with a jerk. The sections are transferred from the knife to distilled water. This is perhaps most conveniently done by placing the ball of one of the fingers of the left hand under the edge of the knife, in front of the section, and drawing the section down onto the finger with the camel's-hair brush. The finger is then dipped into the distilled water when the section floats off. If the sections can not be stained within a few hours after they are cut, they are best transferred to a dish containing 80% alcohol, in which they may be left until it is desired to stain them.

The sliding microtomes may be provided with an arrangement for freezing tissues—a so-called **freezing apparatus.** This consists of a metal plate on which the tissue is laid; an ether or rigolene atomizer plays upon its lower surface, cooling and finally freezing the object, which is then cut.

A drop of fluid (physiologic saline solution, water, etc.) is placed upon the knife, in which the section thaws out and spreads. A better and more rapid method of freezing tissues consists in the use of compressed carbon dioxid, as recommended by Mixter. Cylinders containing about twenty pounds of the liquid gas may be obtained from Bausch & Lomb, who also make a small microtome designed for this purpose. In figure 7 is shown the lower third of a cylinder for compressed carbon dioxid firmly fastened to a thick board, and connected by means of a short piece of strong rubber tubing with the freezing box of the microtome. The handle of the escape valve is from 8 to 10 inches long, so that the quantity of escaping gas may be readily controlled. The pieces of tissue are placed on the freezing box of the microtome and the escape valve slowly opened until a small quantity of the gas escapes. Small pieces of tissue are frozen in about thirty seconds to a minute; tissues taken from alcohol should be washed for a short time in running water before freezing. A strong razor may be used for cutting sections; or better, a well-sharpened blade of a carpenter's plane, as suggested by Mallory and Wright. Sections are transferred to distilled water or normal salt solution, and if fixed may be stained at once. Sections of fresh tissue should be taken from the normal salt solution and transferred to a fixing fluid.

Bardeen has devised a microtome to be used with compressed carbon dioxid, which presents many advantages. It admits of better control of the temperature of the freezing stage and there is less carbon dioxid wasted than with other instruments of this type. It freezes almost instantaneously, since the expanding carbon dioxid is caused to pass through a spiral passage contained in the freezing chamber. In this apparatus the microtome is attached to the steel cylinder containing the carbon dioxid.

It is impossible to cut thin sections with a knife that is not sharp, or with one that is nicked. A few directions as to **sharpening a microtome knife** may therefore not be out of place. For this purpose a good

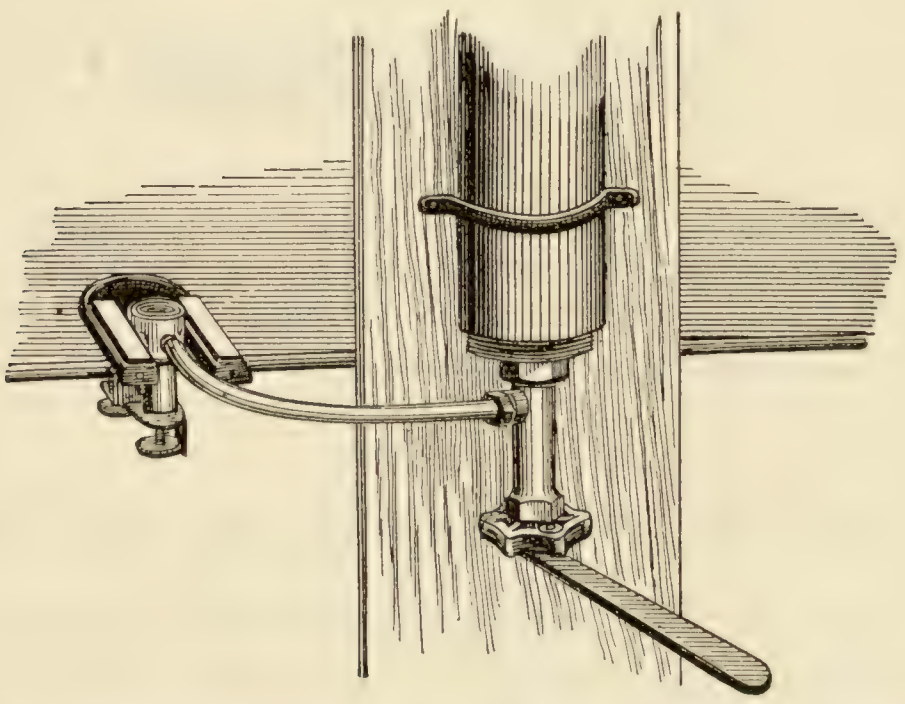

Fig. 7.—Apparatus for cutting tissues frozen by carbon dioxid.

Belgian hone is used, which should be moistened or lubricated with filtered kerosene oil or with soap as necessity demands. While sharpening the knife it is grasped with both hands—with one by the handle, with the

other by the end. The hone is placed on a table with one end directed toward the person sharpening. If the knife is very dull, it is ground for some time on the concave side only (all microtome knives are practically plane on one side and concave on the other), with the knife at right angles to the stone. It is carried from one end of the stone to the other, edge foremost, giving it at the same time a diagonal movement, so that with each sweep the entire edge is touched (see Fig. 8). In drawing back the knife, the edge is slightly raised. The knife is ground on the concave side until a fine thread (feather edge) appears along the entire edge. It is then ground on both sides, care being taken to keep the knife at right angles to the stone, to keep it flat, and to use practically no pressure. It is a good plan to turn the knife on its back when the end of the stone is reached. On the return stroke, the knife is again held at right angles to the stone, the same diagonal sweep is used (see Fig. 8), so that the whole edge of the knife is touched with each sweep. The grinding on both sides is continued until the thread above mentioned has disappeared. The knife should now be carefully cleaned and stropped, with the back of the knife drawn foremost. The strop should be flat and rest on a firm surface.

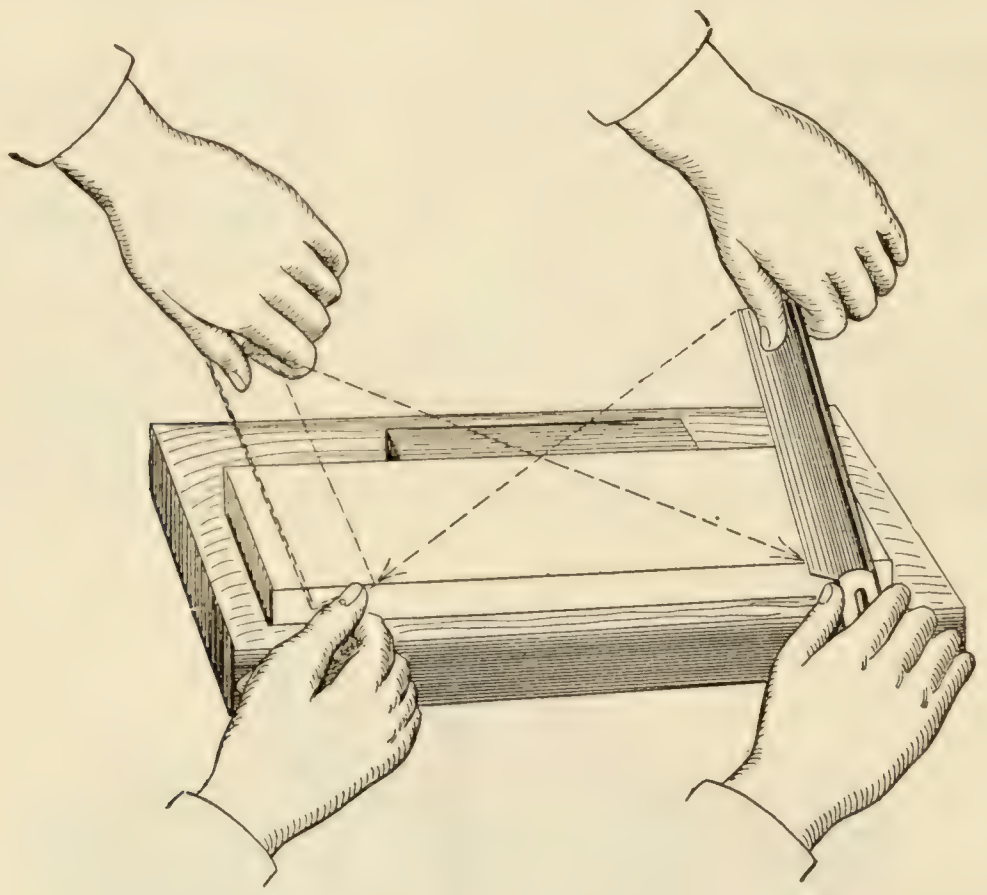

Fig. 8.—Diagram showing direction of the movements in honing.

THE FURTHER TREATMENT OF THE SECTION.

1. FIXATION TO THE SLIDE AND REMOVAL OF PARAFFIN.

Sections obtained by means of the microtome undergo further treatment either loose or, better, fixed to a slide or cover-glass, thus making further manipulation much easier.

The simplest, surest, and most convenient method of fixing paraffin sections to the slide is by means of the **glycerin-albumen** of P. Mayer (83.2). Egg-albumen is filtered and an equal volume of glycerin

added. To prevent decomposition of the fluid a little camphor or sodium salicylate is placed in the mixture. A drop of this fluid is smeared on the slide or cover-slip as evenly and thinly as possible. A section or a series of sections arranged in their proper sequence is then placed upon the slide so prepared. Any folds in the section are smoothed out with a brush, and the section or the whole series gently pressed down upon the glass. When the desired number of sections are on the slide or cover-slip, they are warmed over a small spirit or gas flame until the paraffin is melted. At the same time the albumen coagulates. The sections are now fixed, and are loosened from the glass only when agents are used which dissolve albumen, as, for instance, strong acids, alkalies, and certain staining fluids. If it is desired that a given space, say the size of a cover-slip, be filled up with sections as far as possible, an outline of the cover-slip to be used may be drawn upon a piece of paper and placed under the slide in the required position.

A second and in many respects better method is the fixation of the section with **distilled water** (Gaule). The paraffin sections are spread in proper sequence on a thin layer of water placed on the slide. There should be sufficient water to float the sections. The slide is then dried in a warm oven kept at 30° to 35° C., or gently heated by holding it at some distance from a spirit or gas flame (the paraffin should not melt). By this treatment the sections are entirely flattened out. The superfluous water is either drained off by tilting or drawn off with blotting-paper, the sections are definitely arranged with a brush, and the whole is placed for several hours in a warm oven at 30° to 35° C. The sections thus dried are exposed, over a flame, to a temperature higher than the melting point of the paraffin, and from now on can be subjected to almost any after-treatment. The slide or cover-slip should be thoroughly cleaned (preferably with alcohol and ether), as otherwise the water does not remain in a layer, but gathers in drops.

The advantage of this method lies in the fact that the evaporated water can have no possible influence on the subsequent staining of the sections, while albumen, especially if it be in a thick layer, is sometimes stained, thus diminishing the transparency of the preparation.

This method, although trustworthy for alcohol and sublimate preparations, often fails with objects that have been treated with osmic acid, chromic acid and its mixtures, nitric acid, and picrosulphuric acid. In such cases advantage may be taken of the so-called **Japanese method**, which is a combination of the above fixation methods. A little Mayer's albumen is placed on the slide and so spread about that hardly a trace of the substance can be seen. The slide is then put in a warm oven heated to 70° C. This temperature soon coagulates the albumen, after which the sections are fixed to the slide by the water method (Rainke, 95). The procedure can be varied by adding to the distilled water one drop of glycerin-albumen or gum arabic to every 30 c.c. of water (*vid.* also Nussbaum).

When a large number of paraffin sections are to be fixed to cover-slips, the following method may be recommended: A small porcelain evaporating dish is nearly filled with distilled water and placed on a stand which elevates it 6 to 8 inches from the table. A number of sections are placed on the water, which is then heated by means of a gas flame until the sections become perfectly flat, care being taken not to raise the temperature of the water sufficiently to melt the paraffin. Each

section is then taken up on a cover-slip coated with a very thin layer of Mayer's albumen fixative. During this procedure the cover-slips are held by forceps, and the sections are guided by means of a small camel's-hair brush. When all the sections have thus been placed on cover-slips they are placed for four to six hours in a warm oven maintained at 30° to 35° C.

Removal of Paraffin.—Before paraffin sections, either fixed or loose, are subjected to further manipulation, the paraffin surrounding the tissues must be removed. This may be done by means of several agents having a solvent action on paraffin, such as xylol, toluol, oil of turpentine, etc. After the paraffin has been dissolved, the sections are transferred to absolute alcohol and by this means prepared for further treatment with aqueous or weak alcoholic solutions.

Dextrin Method of fixing Paraffin Sections.—This method is to be recommended for class-room purposes where 30 to 50, or even more sections need to be stained at one time.

The following solutions are kept on hand:

Solution 1.:

A solution of equal parts of white sugar and boiling distilled water	300 c.c.
A solution of equal parts of distilled water and dextrin	100 "
Absolute alcohol	200 "

Mix the sugar and dextrin solutions in a mortar, and add very slowly, while constantly stirring, the absolute alcohol; filter through fine muslin. Keep in a wide-mouthed bottle through the cork of which there has been placed a broad camel's-hair brush.

Solution 2:

Photoxylin	10 gm.
Absolute alcohol	100 c.c.
Ether	500 "

The sections to be stained are cut and arranged on a clean piece of paper. A clean glass plate is coated with a thin layer of solution No. 1. The sections are arranged on this and pressed against the plate with the finger. The plate is now placed in a warm oven (temperature 40° C.), where it remains for several hours. The plate is then warmed over a flame until the paraffin of the sections begins to melt and is then placed in a tray containing xylol, where it remains until the paraffin is dissolved. It is then transferred to a tray containing 95% alcohol and the xylol removed. The plate is next taken from the tray and the alcohol drained off. The plate is now covered with a thin layer of solution No. 2, and set aside, at an angle, until the photoxylin dries. The plate is now placed in the staining fluid, in which, or in the water used in washing off the staining fluid, the thin layer of photoxylin, to which the sections adhere, separates from the plate. This thin film may now be treated as one section and carried on in this form through the several stages of staining and clearing until the process is completed. The individual sections are cut from the film with scissors.

Celloidin preparations can not be fixed to the slide with the same degree of certainty, although many sections may be treated at one time. The celloidin sections can be collected in their sequence on strips of paper by gently pressing such a strip, on the blade of a knife, onto the

section floating in the alcohol. The sections adhere to the paper, and in this way the entire surface of the strip may be covered by series of sections. To prevent the drying of the sections, a number of such strips are laid in rows on a layer of blotting-paper moistened with 70% alcohol. A glass plate of corresponding size is painted with very fluid celloidin. After the layer of celloidin is dry, the strips of paper are laid, one by one, on the glass plate, with sections downward, and the fingers gently passed over the reverse side. This process is continued until the entire surface of the glass is covered. On carefully raising the strips it is seen that the sections will adhere to the layer of celloidin. (To prevent drying, sections must be kept moistened with 70% alcohol.) After first drying the sections with blotting-paper, a second layer of very thin celloidin is painted on the surface of the glass plate. When this layer is also dry, the plate with its adherent sections is placed in water. Here the double layer of celloidin containing the sections is separated from the glass, and is ready for further manipulation. Before mounting, the sheet of celloidin is cut with scissors into convenient portions.

In the case of celloidin sections, if it be desirable to preserve the surrounding celloidin, care should be taken that the preparations should not come in contact with any agents dissolving celloidin. These latter are alcohols from 95% upward, ether, several ethereal oils, especially oil of cloves, but not the oils of origanum, cedar wood, lavender, etc.

2. STAINING.

It is in most cases necessary to stain tissues to bring clearly to view the tissue elements and their relation to each other. The purpose of staining is therefore to differentiate the tissue elements. The differential staining is due to the fact that certain parts of the tissue take up more stain than others. Staining of sections may be looked upon as a microchemic color reaction, and has therefore a value beyond the mere coloring of sections so that they may be seen more clearly.

Broadly speaking, stains used in microscopic work may be divided into basic stains, which show special affinity for the nuclei of cells and are therefore known as *nuclear stains*, and acid stains, which color more readily the protoplasm—*protoplasmic stains*. Certain stains, which we may know as *selective stains* (they may be either basic or acid), color one tissue element more vividly than others, or to the exclusion of others. Since the various tissue elements show affinity for different stains, preparations may be colored with more than one stain. Accordingly we have simple, double, triple, and multiple staining.

Certain stains are also especially adapted for staining in bulk or mass —that is, staining a piece of tissue before it is sectioned.

SECTION STAINING.

Carmin.—Aqueous Borax-carmin Solution.—8 gm. of borax and 2 gm. of carmin are ground together and added to 150 c.c. of water. After twenty-four hours the fluid is poured off and filtered. The sections, previously freed from paraffin and treated with alcohol, are placed in this fluid for several hours (as long as twelve), and then washed out in a solution of 0.5 to 1% hydrochloric acid in 70% alcohol. They are then transferred to 70% alcohol.

Alcoholic Borax-carmin Solution.—3 gm. of carmin and

4. gm. of borax are placed in 93 c.c. of water, after which 100 c.c. of 70% alcohol is added. The mixture is stirred, then allowed to settle, and later filtered. Sections are treated as in the aqueous borax-carmin solution.

Paracarmin is the carmin stain containing the most alcohol, and is therefore of great value.

Carminic acid	1	gm.
Aluminium chlorid	0.5	"
Calcium chlorid	4	"
Alcohol, 70%	100	c.c.

Paracarmin stains quickly, is not liable to overstain, and is therefore peculiarly adapted to the staining of large objects. Specimens are washed in 70% alcohol, with the addition of 0.5% aluminium chlorid or 2.5% glacial acetic acid in case of overstaining (P. Mayer, 92).

Czocor's Cochineal Solution.—7 gm. of powdered cochineal and 7 gm. of roasted alum are kept suspended in 100 c.c. of water by stirring while the mixture is boiled down to half its volume. After cooling it is filtered and a little carbolic acid added. This fluid stains quite rapidly and does not overstain. Before the sections are placed in alcohol they should be washed with distilled water, as otherwise the alum is precipitated on the section by the alcohol.

Partsch recommends the following solution of cochineal: Finely powdered cochineal is boiled for some time in a 5% aqueous solution of alum, and filtered on cooling, after which a trace of hydrochloric acid is added. It stains sections in two to five minutes.

Alum-carmin (Grenacher).—100 c.c. of a 3% to 5% solution of ordinary alum, or preferably ammonia-alum, are mixed with 0.5 gm. to 1 gm. of carmin, boiled for one-fourth of an hour, and after cooling filtered and enough distilled water added to replace that lost by evaporation. This fluid stains quickly but does not overstain. Wash the sections in water.

Hematoxylin.—Böhmer's Hematoxylin:

Hematoxylin crystals	1	gm.
Absolute alcohol	10	c.c.
Potassium alum	10	gm.
Distilled water	200	c.c.

Dissolve the hematoxylin crystals in the alcohol, and the alum in the distilled water. While constantly stirring, add the first solution to the second.

The whole is then left for about fourteen days in an open jar or dish protected from the dust, during which time the color changes from violet to blue. After filtering, the stain is ready for use. Sections, either loose or fixed to the slide or cover-slip, are placed in this solution, and after about half an hour are washed with water. If the nuclei are well stained the further treatment with alcohol may be commenced. Should the sections be overstained, a condition showing itself in the staining of the cell-protoplasm as well as the nuclei, the sections are then washed in an acid alcohol wash (six to ten drops of hydrochloric acid to 100 c.c. of 70% alcohol) until the blue color has changed to a reddish-brown and very little stain comes from the section—usually about one to two minutes. They are then washed in tap-water, and passed into distilled water before placing in alcohol.

Delafield's Hematoxylin:

Hematoxylin crystals	4 gm.
Absolute alcohol	25 c.c.
Ammonia alum, saturated aqueous solution	400 "
Alcohol, 95%	100 "
Glycerin	100 "

Dissolve hematoxylin crystals in absolute alcohol and add to the alum solution, after which place in an open vessel for four days, filter, and add the 95% alcohol and glycerin.

After a few days it is again filtered. This fluid is either used pure or diluted with distilled water. Staining is the same as with Böhmer's hematoxylin.

Friedländer's Glycerin-hematoxylin:

Hematoxylin crystals	2 gm.
Potassium alum	2 "
Absolute alcohol	100 c.c.
Distilled water	100 "
Glycerin	100 "

Dissolve the hematoxylin crystals in the absolute alcohol and the alum in the water; mix the two solutions and add the glycerin.

The mixture is filtered and exposed for several weeks to the air and light, until the odor of alcohol has disappeared, and then again filtered. It stains very quickly. Sections are afterward washed in water and are placed for a short time in acid alcohol if the nuclei are to be especially brought out.

Ehrlich's Hematoxylin:

Hematoxylin crystals		2 gm.
Absolute alcohol		60 c.c.
Glycerin	saturated with	60 "
Distilled water	ammonia alum	60 "
Glacial acetic acid		3 "

The solution is to be exposed to light for a long time. It is ready for use when it acquires a deep-red color.

Stain as above.

Hemalum (P. Mayer, 91).—1 gm. of hematein is dissolved by heating in 50 c.c. of absolute alcohol. This is poured into a solution of 50 gm. of alum in 1 liter of distilled water and the whole well stirred. A thymol crystal is added to prevent the growth of fungus. The advantages of hemalum are as follows: The stain may be used immediately after its preparation, it stains quickly, never overstains, especially when diluted with water, and penetrates deeply, making it useful for staining in bulk. After staining, sections or tissues are washed in distilled water.

Acid Hemalum.—To the above hemalum solution is added 2% of glacial acetic acid. Stains even more rapidly than hemalum, and gives excellent nuclear differentiation. Wash sections in tap-water.

Heidenhain's Iron Hematoxylin.—Good results, particularly in emphasizing certain structures of the cell (centrosome), are obtained by the use of M. Heidenhain's iron hematoxylin (92. 2). Tissues are fixed in saline sublimate solutions, alcohol, or Carnoy's fluid. Very thin sections (in case of amniota not over 4 μ) are fixed to the slide with water and put into a 2.5% aqueous solution of ammonium sulphate of iron for four to eight hours (not longer). After careful rinsing in water, the sections are brought into a solution of hematoxylin prepared as follows: Hematoxylin crystals 1 gm., absolute alcohol 10 c.c., and dis-

tilled water 90 c.c. This solution should remain in an open vessel for about four weeks, and, before using, should be diluted with an equal volume of distilled water. Staining takes place in twelve to twenty-four hours, after which the sections are rinsed in tap-water and again placed in a like solution of ammonium sulphate of iron, until black clouds cease to be given off from the sections. They are rinsed in distilled water, passed through alcohol into xylol, and mounted in balsam. Should a protoplasmic stain be desired, rubin in weak acid solution may be employed.

Coal-tar or **anilin stains.**—Ehrlich classifies all anilin stains as salts having basic or acid properties. The basic anilin stains, such as safranin, methylene-blue, methyl-green, gentian violet, methyl-violet, Bismarck brown, thionin, and toluidin-blue are nuclear stains, while the acid anilin stains, such as eosin, erythrosin, benzopurpurin, acid fuchsin, lichtgrün, aurantia, orange G, and nigrosin stain diffusely and are used as protoplasmic stains.

Safranin :

Safranin	1 gm.
Absolute alcohol	10 c.c.
Anilin water	90 "

Anilin water is prepared by shaking up 5 c.c. to 8 c.c. of anilin oil in 100 c.c. of distilled water and filtering through a wet filter. Dissolve the safranin in the anilin water and add the alcohol. Filter before using.

Stain sections of tissues fixed in Flemming's or Hermann's solutions for twenty-four hours, and decolorize with a weak solution of hydrochloric acid in absolute alcohol (1 : 1000). After a varying period of time (usually only a few minutes) all the tissue elements will be found to have become bleached, only the chromatin of the nucleus retaining the color.

Bismarck Brown.—A very convenient color to handle is Bismarck brown. Of this, 1 gm. is boiled in 100 c.c. of water, filtered, and ⅓ of its volume of absolute alcohol added. Bismarck brown stains quickly without overstaining, and is also a purely nuclear stain. Wash in absolute alcohol.

Methyl-green stains very quickly (minutes). 1 gm. is dissolved in 100 c.c. of distilled water to which 25 c.c. of absolute alcohol is added. Rinse sections in water, then place for a few minutes in 70% alcohol, transfer to absolute alcohol for a minute, etc.

Other so-called basic anilin stains can be used in a similar manner. Thionin or toluidin-blue in dilute aqueous solutions are especially useful. Nuclei appear blue and mucus red.

Double Staining.—When certain stains are used in mixtures or in succession, all portions of the section are not stained alike, but certain elements take up one stain, others another. This elective affinity of tissues is taken advantage of in *plural staining*. If two stains are employed, one speaks of *double staining*.

Picrocarmin of Ranvier.—Two solutions are prepared, a saturated aqueous solution of picric acid and a solution of carmin in ammonia. The second is added to the first to the point of saturation. The whole is evaporated to one-fifth of its volume and filtered after cooling. The solution thus obtained is again evaporated until the picrocarmin remains in the form of a powder. A 1% solution of the latter in distilled water is the fluid used for staining.

To stain with this solution, one or two drops are placed on the slide over the object and the whole put in a moist chamber for twenty-four hours. A cover-slip is then placed over the preparation, the picrocarmin drained off with a piece of blotting-paper, and a drop of formic-glycerin (1 : 100) brought under the cover-slip by irrigation. Proper differentiation takes place only after a few days, and the acid-glycerin may then be replaced by the pure glycerin. In objects fixed with osmic acid, the nuclei appear red, connective tissue pink, elastic fibers canary yellow, muscle tissue straw color, keratohyalin red, etc.

Weigert's Picrocarmin.—The preparation of Weigert's picrocarmin is somewhat simpler. 2 gm. of carmin are stirred in 4 c.c. of ammonia and allowed to remain standing in a well-corked bottle for twenty-four hours. This is mixed with 200 c.c. of a concentrated aqueous solution of picric acid to which a few drops of acetic acid are added after another twenty-four hours. The result is a slight precipitate that does not dissolve on stirring. Filter after twenty-four hours. Should the precipitate also pass through the filter, a little ammonia is added to dissolve it. Both picrocarmin solutions dissolve off sections fixed to the slide with albumen.

Carmin-bleu de Lyon (of Röse).—Sections or pieces of tissue are first stained with carmin (alum- or borax-carmin). Bleu de Lyon is dissolved in absolute alcohol and diluted with the latter until the solution is of a light bluish color. In this the sections or pieces of tissue are after-stained for twenty-four hours (developing bone stains, for instance, blue).

Picric acid is often used as a secondary stain, either in aqueous (saturated solution diluted 1 to 3 times in water) or in alcoholic solution (weak solutions in 70%, 80%, and absolute alcohol). Sections previously treated with carmin or hematoxylin are stained for two to five minutes, washed in water or alcohol, and transferred to absolute alcohol, etc. Sections stained in safranin can be exposed to the action of an alcoholic picric acid solution. A solution of picric acid in 70% alcohol may be used to wash sections stained in borax-carmin. This often gives a good double stain. Sections can also be first treated with picric acid and afterward stained with alum-carmin.

Hematoxylin.—Van Gieson's Acid fuchsin-picric acid Solution.—Stain in any one of the hematoxylin solutions and after rinsing sections in water counter-stain in the following:

Acid fuchsin, 1% aqueous solution	5 c.c.
Picric acid, saturated aqueous solution . .	100 "

Dilute with an equal quantity of distilled water before using. The hematoxylin stained sections remain in the solution for from one to two minutes, are then rinsed in water, dehydrated and cleared.

Hematoxylin-eosin.—Sections already stained in hematoxylin are placed for two to five minutes in a 1% to 2% aqueous solution of eosin or in a 1% solution of eosin in 60% alcohol. They are then washed in water until no more stain comes away, after which they remain for only a short time in absolute alcohol. In place of the eosin solution a 1% aqueous solution of benzopurpurin may be used or the following solution of erythrosin (Held):

Erythrosin	1 gm.
Distilled water	150 c.c.
Glacial acetic acid	3 drops.

Hematoxylin-safranin of Rabl (85).—Sections of preparations fixed with chromic-formic acid or with a solution of platinum chlorid are stained for a short time with Delafield's hematoxylin, then counterstained for twelve to twenty-four hours with safranin and washed with absolute alcohol until no more color is given off.

Biondi-Heidenhain Triple Stain.—Of the many triple stains in use we mention only the most important, the rubin S—orange G—methyl-green mixture of Ehrlich and Biondi, employed according to the modificaton of M. Heidenhain. The best results are obtained with objects fixed in saline sublimate solution. The three stains just mentioned are prepared in concentrated aqueous solutions. (In 100 c.c. of distilled water there are dissolved respectively about 20 gm. of rubin S, and 8 gm. of orange G and methyl-green.) These concentrated solutions are combined in the following proportions: rubin S 4, orange G 7, methyl-green 8. The stock solution thus obtained is diluted with 50 to 100 times its volume of distilled water before using. The sections should be as thin as possible and fixed to the slide by the water method. They remain for twenty-four hours in the stain, and are then rinsed in distilled water or in 90% alcohol or in such with the addition of a little acetic acid (1 to 2 drops to 50 c.c.). Before staining it is occasionally of advantage to treat the sections with acetic acid (2 : 1000) for one to two hours.

STAINING IN BULK.

Instead of staining in sections, entire objects can be stained before cutting. This method is in general much slower, and demands, therefore, special staining solutions, as, for instance:

Alcoholic Borax-carmin Solution.—Pieces ½ cm. in diameter remain in the stain at least twenty-four hours, are then decolorized for the same length of time in acid alcohol (0.5% to 1% hydrochloric acid in 70% alcohol), and after washing in 70% alcohol are transferred to 90% alcohol. Larger objects require a correspondingly longer time.

Paracarmin.—Treatment as in section staining; length of time according to size of object.

Alum-carmin of Grenacher.—This never overstains. Time of staining according to size of object. Wash in water, then transfer to 70% and 90% alcohol.

Hemalum, when diluted with water, is very useful for staining in bulk. After staining, objects should be washed with distilled water.

Böhmer's hematoxylin stains small pieces very sharply. Use the same as hemalum.

Hematoxylin staining according to R. Heidenhain's method is especially recommended for staining in bulk.

Stain objects fixed in alcohol or picric acid twenty-four hours in a 0.33% aqueous solution of hematoxylin; transfer for an equal length of time to a 0.5% aqueous solution of potassium chromate, changing often until the color ceases to run. Wash with water and pass into strong alcohol. This stain also colors the protoplasm, and is so powerful that very thin sections are an absolute condition to the clearness of the preparation.

If the objects have been fixed with picric acid and the latter has not been entirely washed out, staining in bulk by the above methods produces very striking differentiation.

Pieces of tissue stained in bulk may be infiltrated, imbedded, and cut according to the ordinary methods. Under these circumstances, section staining is not necessary unless a still further differentiation be desired.

In general, then, the treatment of the object is somewhat as follows: First, it is fixed in some one of the fixing fluids already described, then carefully washed, and in certain cases stained in bulk before infiltrating with paraffin or celloidin; or the staining may be postponed until the tissue has been cut. In the latter case, the sections are subjected to the stain either loose or fastened to the slide or cover-slip.

In all cases it is absolutely essential that the paraffin be entirely removed. After the sections have been stained and washed, they are transferred to absolute alcohol in case it be desired to mount them in some resinous medium. They may also be mounted in glycerin or acetate of potash, into which they may be passed directly from distilled water.

The method of staining tissues in sections or in bulk is shown in the following diagrams:

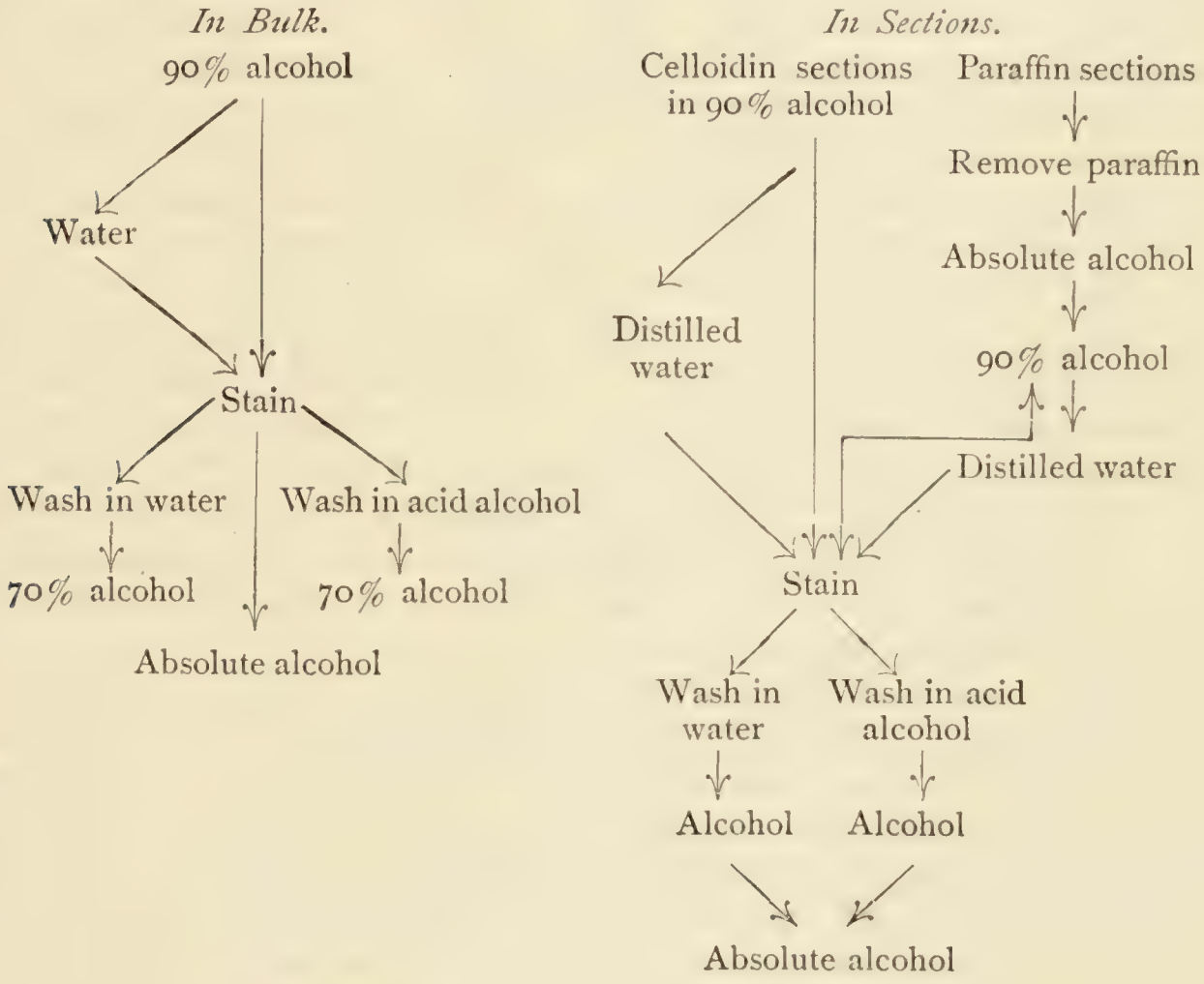

METHODS OF IMPREGNATION.

The impregnation methods differ from the staining methods in that in the latter the coloration is obtained by reagents in solution, while in the former the tissues are filled with fine particles which enter into combination with certain constituents of the tissue elements and are reduced in them.

Silver Nitrate Method.—This method was suggested by Krause; it was, however, brought to prominence by v. Recklinghausen. It is especially useful for staining the intercellular substances of epithelium, endothelium, and mesothelium and the ground-substance of connective

tissues. The method may be used on fresh tissues or on fixed tissues; the employment of fresh tissue is, however, more satisfactory. The tissues to be impregnated are spread in thin layers, and immersed in a 0.5% to 1% solution of silver nitrate for from ten to fifteen minutes; they are then rinsed in distilled water and placed in fresh distilled water or 70% alcohol or a 4% solution of formalin and exposed to direct sunlight, where they remain until they assume a brown color. The sunlight reduces the silver, in the form of fine particles which appear black on being examined with transmitted light. The preparations thus obtained may be examined in glycerin or dehydrated and mounted in balsam. (See methods of injection for staining the endothelial cells of blood and lymph vessels.)

Gold Chlorid Method.—In gold chlorid impregnation the cells and fibers of certain tissues are stained while the intercellular substances remain uncolored. The coloration is obtained by a reduction of the gold (either by sunlight or certain reagents—formic acid, acetic acid, citric acid, oxalic acid), in the form of very fine particles which impart to the tissues a purplish-red color. This method is especially useful for bringing to view the terminations of nerve-fibers, both motor and sensory; however, it may also be employed for staining other tissue elements. The method of gold impregnation was introduced by Cohnheim and was used by him in staining the nerve terminations in the cornea. It has received numerous modifications since its introduction. The following may be mentioned:

Cohnheim's Method.—Small pieces of muscle are placed in a 1% solution of gold chlorid acidulated by a trace of acetic acid. In this they become yellow (in from a few minutes to half an hour). They are then rinsed in distilled water, placed in water slightly acidulated with acetic acid, and kept in the dark. As a rule, the pieces will change in color, becoming yellowish-gray, grayish-violet, and finally red, from one to three days generally being required for this process. The parts best adapted to examination are those in the transitional stage of violet to red.

This procedure has been subjected to innumerable modifications; of these, the most used are: (1) The method of Löwit: Small pieces are placed in a solution of 1 vol. formic acid and 2 vols. distilled water until they have become transparent (ten minutes). They are then placed in a 1% solution of gold chlorid, in which they become yellow (one-quarter hour). They are now again placed in formic acid, in which they pass through the same color changes as above. Finally, they are washed and teased, or subsequently treated with alcohol and cut. (2) Kühne (86) acidifies with 0.5% solution of acetic acid (especially in the case of muscle), then treats the specimens with a 1% solution of gold chlorid, and reduces the gold with 20 to 25% formic acid dissolved in equal parts of water and glycerin. (3) Ranvier (89) acidifies with fresh lemon juice filtered through flannel, then treats with a 1% solution of gold chlorid (quarter of an hour or longer), and finally either places the specimen in water acidulated with acetic acid (1 drop to 30 c.c. water) and subjects it to light for one or two days, or reduces it in the dark, as in Löwit's method, in a solution of 1 vol. formic acid and 2 vols. water. (4) Gerlach uses the double chlorid of gold and potassium, but in weaker concentrations than a 1% solution, otherwise he continues as in the method of Cohnheim. (5) Golgi (94) also uses the same double chlorid, but acidifies with 0.5% arsenious acid, and then reduces in 1% arsenious acid in the sunlight.

Golgi's Chromsilver or Chromsublimate Method.—This method depends on the formation of a very fine precipitate, which forms in certain tissue elements or in preexisting space, when treated first with a solution of bichromate of potassium and secondarily with a solution of silver nitrate or bichlorid of mercury. The nature and precise location of this precipitate is not well understood. It is very probable, however, as Kallius suggests, that an albumin-chromsilver compound, of an unknown constitution, is formed in the cells and processes or in spaces filled with the precipitate. This method is especially useful in bringing to view the cellular elements of the nervous system, both central and peripheral; further, the end-ramifications of gland ducts, and now and then cell boundaries. Usually only a small percentage of the tissue elements or the spaces of any given tissue are colored. This may, however, be regarded as one of the advantages of the method, since it enables a clearer view of the parts colored. The precipitate appears black in transmitted light. It is necessary to state, however, that this method is very unreliable, and that failures are often met with, also that an amorphous precipitate is generally formed, both in and about the tissues, which in part at least destroys the usefulness of the preparations obtained.

Golgi's methods will perhaps be better understood if we first give a short historic sketch of their development.

In the year 1875 Golgi applied his method as follows: He fixed (olfactory bulb) in Müller's fluid, and increased the percentage of bichromate on changing the fluid (up to 4 %). Fixation lasted five or six weeks in summer and three or four months or more in winter. He then took out pieces of the tissue every four or five days and treated them experimentally with a 0.5% to 1% silver nitrate solution. In summer this process took about twenty-four hours, and in winter forty-eight hours, although a longer treatment was not found to be detrimental. This method must be regarded as very uncertain, since the length of time during which the specimens remain in Müller's fluid must be very closely calculated, as it depends largely upon the temperature of the medium. As soon as the silver reaction was established, the pieces were preserved either in the silver solution itself or in alcohol. The sections were finally washed in absolute alcohol, cleared with creosote, and mounted in Canada balsam. The impregnation disappeared in a short time. In the year 1885 Golgi made a further announcement regarding his method, recommending for fixation the pure bichromate of potassium, as well as Müller's fluid. Pieces of the brain and spinal cord (from 1 to 1.5 c.c. in size) from a freshly killed animal were used, and the reaction sometimes took place in from twenty-four to forty-eight hours after death. For fixing, potassium bichromate solution in gradually ascending strengths (1% to 5%) was employed, large amounts of the fluid being used and placed in well-sealed receptacles. The fluid was repeatedly changed, and camphor or salicylic acid was added in order to prevent the growth of fungi. Since it is difficult to determine exactly when fixation in potassium bichromate reaches the precise point favorable to subsequent treatment with nitrate of silver, because the process depends entirely upon the temperature and quantity of the fluid, it becomes necessary, after about six weeks' treatment with the bichromate, to experiment every eight days or so to see whether the silver nitrate gives good results. The strength of the latter should be about 0.66% and the quantity about 200 c.c. to a 1 c.c. object. At first a plentiful precipitate is thrown down, in which case the solution should be changed, and this probably repeated once more after a few hours. After twenty-four hours, at the most forty-eight hours, this process is usually completed, and the tissues may be sectioned. The sections must then be carefully dehydrated with absolute alcohol, cleared in creosote and mounted without a cover-glass in Canada balsam (the section is mounted on a cover-glass with Canada balsam, and the cover-slip then fastened over the opening of a perforated slide with the specimen downward).

In order to obtain a uniform penetration of the objects by the potassium bichromate, the latter may be first injected into the vessels. Golgi uses potassium bichromate-gelatin (2.5% of the salt, based on the amount of the softened gelatin; compare Golgi, 93). After the injection and cooling of the specimen the latter is cut in

small pieces and treated in the manner previously described. Instead of Müller's fluid, that of Erlicki may be used, the time of treatment being then shorter (from five to eight days).

The objects may also be treated with a potassium bichromate-osmic acid solution (2.5% solution of potassium bichromate, 8 vols.; 1% osmic acid, 2 vols.), the sections thus treated being ready for immersion in silver nitrate after two or three days. It is advisable to treat the objects with the potassium bichromate solution first, and then with the potassium bichromate-osmic mixture. By this method the specimens remain under the control of the investigator; they may be examined either at once, or after an interval varying between three or four and twenty-five to thirty days after immersion. If then one or several pieces of tissue are taken, at intervals of two, three, or four days, from the potassium bichromate solution and placed in the potassium bichromate-osmic acid mixture, and then in the silver nitrate solution, various combinations of the fluids result, and the investigator is usually rewarded with at least some sections giving most excellent results.

Another one of Golgi's methods consists in successive treatment with potassium bichromate and bichlorid of mercury. After remaining in the potassium bichromate for from three to four weeks (a longer period is allowable), the objects are placed in a 0.25% to 1% solution of corrosive sublimate. In the latter the specimens blacken much more slowly than in the silver nitrate solution—eight to ten days for smaller pieces; for larger ones, two months, and in some cases even longer. Before mounting the preparations in glycerin or Canada balsam they must be carefully washed; otherwise pin-shaped crystals form within the sections and distort the whole view. The metallic white of the preparation may be changed to black by placing the celloidin section in a photographer's toning solution consisting of: (*a*) sodium hyposulphite 175 gm., alum 20 gm., ammonium sulphocyanid 10 gm., sodium chlorid 40 gm., and water 1000 gm. (the mixture must stand for eight days and then be filtered); (*b*) a 1% gold chlorid solution. The specimen is placed for a few minutes in a solution composed of 60 c.c. of *a* and 7 c.c. of *b*, washed again in distilled water, dehydrated with alcohol, and mounted in Canada balsam. After toning and washing, the sections may still be stained.

Golgi's methods are extremely inconstant in their results. When successful, however, only a few elements are blackened each time, an advantage not to be underestimated; for if all nerves should stain equally well, discrimination between the various elements in the preparation would be very difficult. Neither are the same structures always impregnated; sometimes it is the ganglion cells and fibers, at other times the neurogliar cells, and occasionally only the vessels.

After the foregoing explanation of Golgi's methods as applied by himself, we shall append a description of these methods as modified and employed at the present time (Ramón y Cajal, Kölliker, von Lenhossék and others).

Golgi's methods are classified as the slow, the mixed, and the rapid.

The **slow method** requires a preliminary treatment. Pieces of tissue from 1 to 2 cm. in diameter are placed for from three to five weeks in a 2% potassium bichromate solution; they are then transferred for from twenty-four to forty-eight hours to a 0.75% silver nitrate solution, or for a much longer time to a 0.5% solution of corrosive sublimate.

In the **mixed method** the specimens are allowed to remain for four or five days in a 2% aqueous potassium bichromate solution; then for from twenty-four to thirty hours in a mixture consisting of 1% osmic acid 1 vol., and 2% potassium bichromate solution 4 vols. They are then treated with a 0.75% silver nitrate solution for one or two days.

When the **rapid method** is employed, the specimens are immediately placed in a mixture consisting of 1 vol. of 1% osmic acid and 4 vols. of a 3.5% potassium bichromate solution, and, finally, for one or two days in a 0.75% silver nitrate solution, to every 200 c.c. of which one drop of formic acid has been added.

When employing these methods, and more particularly the one last described (which seems to be the most efficient), the following conditions must be carefully observed: If possible, the material should be absolutely

fresh, the specimens must not exceed 3 or 4 mm. in thickness, and for every piece of tissue treated about 10 c.c. of the osmium-potassium bichromate mixture should be employed, the specimens remaining in the latter (in the dark) at a temperature of 25° C. for a length of time varying according to the result desired (two or three days for the neurogliar cells, from three to five days for the ganglion cells, and from five to seven days for the nerve-fibers of the spinal cord). The objects are now dried with blotting-paper or washed quickly in distilled water and then placed for two or three days in a 0.75% silver nitrate solution at room-temperature. In this they may remain for four or five days without damage, but not longer, as otherwise the precipitate becomes markedly granular (*vid.* v. Lenhossék, 92).

If Golgi's method be unsuccessful (this applies to all its modifications), the preparations may be transferred from the silver nitrate solution back into a potassium bichromate-osmic acid mixture containing less osmic acid, in which they remain several days, and are then again placed in the silver nitrate solution for from twenty-four to forty-eight hours. This procedure may even be repeated.

Cox obtains a precipitate in both cells and fibers by treating small pieces of the central nervous organs with a mixture composed of potassium bichromate 20 parts, 5% corrosive sublimate 20 parts, distilled water 30 to 40 parts, and 5% potassium chromate of strong alkaline reaction 16 parts. The specimens remain in this mixture from one to three months, according to the temperature, and are then further treated according to Golgi's method.

As the chrome-silver preparations are not permanent, and can not, therefore, be subsequently stained, Kallius has suggested that the chrome-silver precipitate be reduced to metallic silver by treatment with the "quintuple hydroquinon developer" (hydroquinon 5 gm., sodium sulphite 40 gm., potassium carbonate 75 gm., and distilled water 250 gm.). For this purpose 20 c.c. of the solution are diluted with 230 c.c. of distilled water; this mixture may be preserved in the dark for some time if desired. Before using this latter solution, it should be mixed with ⅓, or at the most ½, of its volume of absolute alcohol. The sections are placed in a watch-crystal containing some of the latter mixture until they turn black (a few minutes). As soon as the silver salt is completely reduced, the sections are placed for from ten to fifteen minutes in 70% alcohol, then for five minutes in a 20% solution of sodium hyposulphite and, finally, washed for some time in distilled water, after which they may be stained, and even treated with acid alcohol and potassium hydrate.

The following simple method for permanently mounting Golgi preparations under a cover-glass has been recommended by Huber.

After impregnation with chrome-silver the tissues are hastily dehydrated, imbedded in celloidin, and cut in sections varying from 25 μ to 100 μ in thickness. The sections are then dehydrated and placed for from ten to fifteen minutes in creosote, from which they are carried into xylol, where they remain another ten minutes. The sections are then removed to the slide. The xylol is then removed by pressing several layers of filter-paper over the section. On removing the filter-paper the sections are quickly covered by a large drop of xylol balsam and the slide is carefully heated over a flame for from three to five minutes. Be-

fore the balsam cools the preparation is covered with a large cover-glass, warmed by passing several times through the flame.

Kopsch (96) places specimens in a solution composed of 10 c.c. of formalin (40% formaldehyd) and 40 c.c. of a 3.5% solution of potassium bichromate. For objects 2 c.c. in size 50 c.c. of the fluid are employed; but if the specimens be large, the mixture must be changed in twelve hours. At the end of twenty-four hours this fluid is replaced by a fresh 3.5% potassium bichromate solution, and the specimens are then transferred to a 0.75% solution of silver nitrate (after two days, if the tissue be the liver or stomach; and after from three to six days, if retina or central nervous system). After this treatment the objects are carried over into 40% alcohol and, finally, into absolute alcohol, imbedded as rapidly as possible, and cut. The sections are mounted in balsam without a cover-glass.

PREPARATION OF PERMANENT SPECIMENS.

The resinous media used in the final mounting of preparations are Canada balsam and damar.

Canada Balsam.—Commercial Canada balsam is usually dissolved in turpentine; it should be slowly evaporated in a casserole and then dissolved in xylol, toluol, or chloroform, etc. The proper concentration of the solution is found with a little experience. A thick solution penetrates the interstices of the section with difficulty, and usually contains air-bubbles which often hide the best areas of the preparation, and can only be removed with difficulty by heating over a flame. Thin solutions, on the other hand, have also their disadvantages; they evaporate very quickly, and the empty space thus created between the cover-slip and slide must again be filled with Canada balsam. This is best done by dipping a glass rod into the solution and placing one drop at the edge of the cover-slip, whereupon the fluid spreads out between the cover-slip and slide as a result of capillary attraction. Canada balsam dries rather slowly, the rapidity of the process depending upon the temperature of the room. To dry quickly, the slides may be held for a few moments over a gas or alcohol flame, or they may be placed in a warm oven, where the preparations become so dry in twenty-four hours that they can be examined with an oil-immersion lens. The oil used for this purpose should be wiped away from the cover-slip after examination. This can only be done, without moving the cover-slip, when the balsam is thoroughly dry and holds the cover-slip firmly in place.

Damar.—Damar is dissolved preferably in equal parts of oil of turpentine and benzin. It has the advantage of not rendering the preparation as translucent as Canada balsam. Otherwise it is used as the latter.

Clearing Fluids.—Since alcohol does not mix with Canada balsam or damar, an intermediate or clearing fluid is used in transferring objects from the former into the latter. Xylol, toluol, carbol-xylol (xylol, 3 parts; carbolic acid, 1 part), oil of bergamot, oil of cloves, and oil of origanum are ordinarily used. The process is somewhat simpler where sections are fixed to the slide. Xylol is dropped onto the surface of the slide, or better, the whole preparation is placed for a few minutes in a vessel containing xylol until the diffusion currents have ceased (which may be seen with the naked eye). The slide is then taken out, tilted to allow the xylol to run off, wiped dry around the object with a cloth, and placed upon the

table with the specimen upward. A drop of Canada balsam is now placed on the section (usually on its left side), and a clean cover-slip grasped with a small forceps. It is then gently lowered in such a way that the Canada balsam spreads out evenly and no air-bubbles are imprisoned under the glass. When this is done the preparation is finished.

If one is dealing with loose sections, a spatula or section-lifter is very useful in transferring them from absolute alcohol into the clearing fluid—carbol-xylol or bergamot oil (xylol evaporates very rapidly)—and from this onto the slide. In doing this it is necessary that the section should lie well spread out on the section-lifter, wrinkles being removed with a needle or small camel's-hair brush. In sliding the section off the spatula (with a needle or brush) a small quantity of the clearing fluid is also brought onto the slide. This must be removed as far as possible by tilting or with blotting-paper. The section can now be mounted in Canada balsam as before. For esthetic and practical reasons the student should see that during the spreading of the drop of Canada balsam the section remains under the middle of the cover-slip. Should it float to the edge, it is best to raise the cover-slip and lower it into place again. The cover-slip should never be slid over the specimen.

Glycerin.—To mount in glycerin the sections are transferred from water to the slide, covered with a drop of glycerin and the cover-slip applied. This method is employed in mounting sections colored with a stain that would be injured by contact with alcohol, and where clearing is not especially necessary.

Farrant's Gum Glycerin.

In place of pure glycerin the following mixture may be used:

Glycerin	50 c.c.
Water	50 "
Gum-arabic (powder)	50 gm.
Arsenious acid	1 "

Dissolve the arsenious acid in water. Place the gum-arabic in a glass mortar and mix it with the water; then add the glycerin. Filter through a wet filter-paper or through fine muslin.

To preserve such preparations for any length of time the cover-glasses must be so fixed as to shut off the glycerin or acetate of potash from the air. For this purpose cements or varnishes are employed which are painted over the edges of the cover-slip. These masses adhere to the glass, harden, and fasten the cover-slip firmly to the slide, hermetically sealing the object. The best of these is probably Krönig's varnish, prepared as follows: 2 parts of wax are melted and 7 to 9 parts of colophonium stirred in, and the mass filtered hot. Before employing an oil-immersion lens it is advisable to paint the edge with an alcoholic solution of shellac.

METHODS OF INJECTION.

The process of injection consists in filling the blood- and lymph-vessels with colored masses in order to bring out clearly their relation to the neighboring tissue elements. The instruments required are a syringe of suitable size or a constant pressure apparatus and cannulas of various sizes. Serviceable and instructive injections of blood-vessels are readily made; good injections require skill, experience, and patience. Injection masses may be classed under two heads—cold injection masses and warm injection

masses. The vehicle of the latter is most generally gelatin. For injecting the blood-vessels either the cold or the warm masses may be employed, although the latter gives better results. The cold masses are to be used for injecting the lymphatic vessels. In injecting the blood-vessels it is well to wash out the vessels with warm normal salt solution before the injection mass is forced into the vessels. The following masses may be recommended:

Gelatin-carmin.—The first is a gelatin-carmin mass, and is prepared as follows: (1) 4 gm. of carmin are stirred into 8 c.c. of water and thoroughly ground. Into this a sufficient quantity of ammonia is poured to produce a dark cherry color and render the whole transparent. (2) 50 gm. of finest quality gelatin is placed in distilled water for twelve hours until well soaked. It is then pressed out by hand and melted at a temperature of 70° C. in a porcelain evaporating dish. The two solutions are now slowly mixed, the whole being constantly stirred until a complete and homogeneous mixture is obtained. To this mass is added, drop by drop, a 25% acetic acid solution until the color begins to change to a brick red and the mass becomes slightly opaque. This should be very carefully done, as a single drop too much may spoil the whole. During this procedure the substance should be kept at 70° C. and constantly stirred. The change in color indicates that the reaction of the mass has become neutral or even slightly acid (an ammoniac solution should not be used, since the stain diffuses through the wall of the vessel and colors the surrounding tissues); the whole is filtered through flannel while still warm. As this mass hardens on cooling it is injected warm. The instruments used are also warmed before the injection is begun.

Gelatin-Berlin Blue.—One part of oxalic acid is powdered in a mortar; to this is added one part of Berlin blue and 12 parts of water. Stir and rub until a solution is obtained. Prepare a gelatin vehicle as directed in the preceding paragraph; to 12 parts of the gelatin mass add slowly while stirring 12 parts of the Berlin blue solution. The whole is filtered through flannel while still warm.

Yellow Gelatin Mass (Hoyer).—Prepare a gelatin vehicle consisting of 1 part of gelatin and 4 parts of distilled water; a cold, saturated solution of bichromate of potassium and a cold, saturated solution of lead acetate. Take equal volumes of each. Add the bichromate of potassium solution to the gelatin and heat almost to boiling; then add slowly, while stirring, the lead acetate solution.

Carmin Mass, Cold (Kollmann).—One gm. of carmin is dissolved in a small quantity of ammonium hydrate and 20 c.c. of glycerin added. To another 20 c.c. of glycerin there is added 20 drops of hydrochloric acid and this added to the glycerin-carmin mixture while stirring.

Saturated aqueous solutions of Berlin blue or a Prussian blue may also be used for cold injections.

Injection masses already prepared are to be had in commerce. Besides those already mentioned, still others colored with China ink, etc., are in general use.

Small animals are injected as a whole by passing the cannula of a syringe into the left ventricle or aorta. In the case of large animals, or where very delicate injections are to be made, the cannula is inserted into one of the vessels of the respective organs. The proper ligation of the remaining vessels should not be omitted.

Organs injected with carmin are fixed in alcohol and should not be brought in contact with acids or alkalies. Such parts as are injected with Berlin blue are less sensitive in their after-treatment. Pieces or sections that have become pale regain their blue color in oil of cloves.

If objects or sections injected with Berlin blue be treated with a solution of palladium chlorid, the bluish color changes to a dark brown which afterward remains unchanged (Kupffer).

By means of the above injection methods other lumina can be filled, as, for instance, those of the glands. As a rule, these are only partially filled, since they end blindly, and their walls are less resistant and may be damaged by the pressure produced by the injection.

Silver Nitrate.—In thin membranes and sections the vessel-walls can be rendered distinct by silver-impregnation, which brings out the outlines of their endothelial cells. This may be done either by injecting the vessel with a 1% solution of silver nitrate, or, according to the process of Chrzonszczewsky, with a 0.25% solution of silver nitrate in gelatin. This method is of advantage, since, after hardening, the capillaries of the injected tissue appear slightly distended. Organs thus treated can be sectioned, but the endothelial mosaic of the vessels does not appear definitely until the sections have been exposed to sunlight.

The injecting of lymph-channels, lymph-vessels, and lymph-spaces is usually done by puncture. A pointed cannula is thrust into the tissue and the syringe emptied by a slight but constant pressure. The injected fluid spreads by means of the channels offering the least resistance. For this purpose it is best to employ aqueous solutions of Berlin blue or silver nitrate, as the thicker gelatin solutions cause tearing of the tissues.

Altman's Process.—To bring out the blood capillaries and the lymphatic channels, Altman's process (79), in which the vessels are injected with olive oil, is useful. The objects are then treated with osmic acid, sectioned by means of a freezing microtome and finally treated with eau de Javelle (a concentrated solution of hypochlorite of potassium). By this process all the tissues are eaten away, the casts of the blood-vessels remaining as a dark framework (corrosion). The manipulation of these preparations is extremely difficult on account of the brittleness of the oil casts. For lymph-channels Altman (*ibid.*) used the so-called oil-impregnation. Fresh pieces of tissues, thin lamellæ of organs, cornea, etc., are placed for five to eight days in a mixture containing olive oil 1 part, absolute alcohol ½ part, sulphuric ether ½ part (or castor oil 2, absolute alcohol 1, etc.). The pieces are then laid for several hours in water, where the externally adherent globules of oil are mechanically removed and those in the lymph-canalicular system are precipitated. The objects are now treated with osmic acid, cut by means of a freezing microtome, and corroded. In this case, the corrosive fluid (eau de Javelle) should be diluted two or three times.

RECONSTRUCTION BY MEANS OF WAX PLATES.

It is often impossible to obtain a clear conception of the form of minute anatomic structures, nor of their relations, by means of sections or by the methods of maceration and teasing. To obviate such difficulties methods of reconstruction have been devised, by means of which such structures may be reproduced in an enlarged form without losing their inherent morpho-

logic features. Of these methods, we shall here describe that suggested by Born (1876) and known as Born's method of reconstruction by wax plates. This method has found wide application in embryologic investigations, and has proved very valuable in ascertaining the form, relation, and metamorphosis of embryonic structures and organs. It has not been so extensively used in the study of the form of fully developed anatomic structures; it deserves, however, a fuller appreciation of its value as an aid in microscopic study. Necessary are serial sections, wax plates of desired thickness, and a drawing apparatus.

Serial Sections.—One of the requisites of wax plate reconstruction is a perfect series of sections of uniform thickness. The thickness of the sections should depend on the character and size of the object to be reconstructed and on the magnification necessary to give the model obtained such a size as to enable it to be readily manipulated. In the reconstruction of fully developed anatomic structures, such as parts of glands or entire glands, it is generally not possible to make an outline drawing of the parts to be reproduced. When this is possible, it forms the first step of the method.

Wax Plates.—Several methods have been suggested for obtaining wax plates of uniform and desired thickness. The instrument devised by

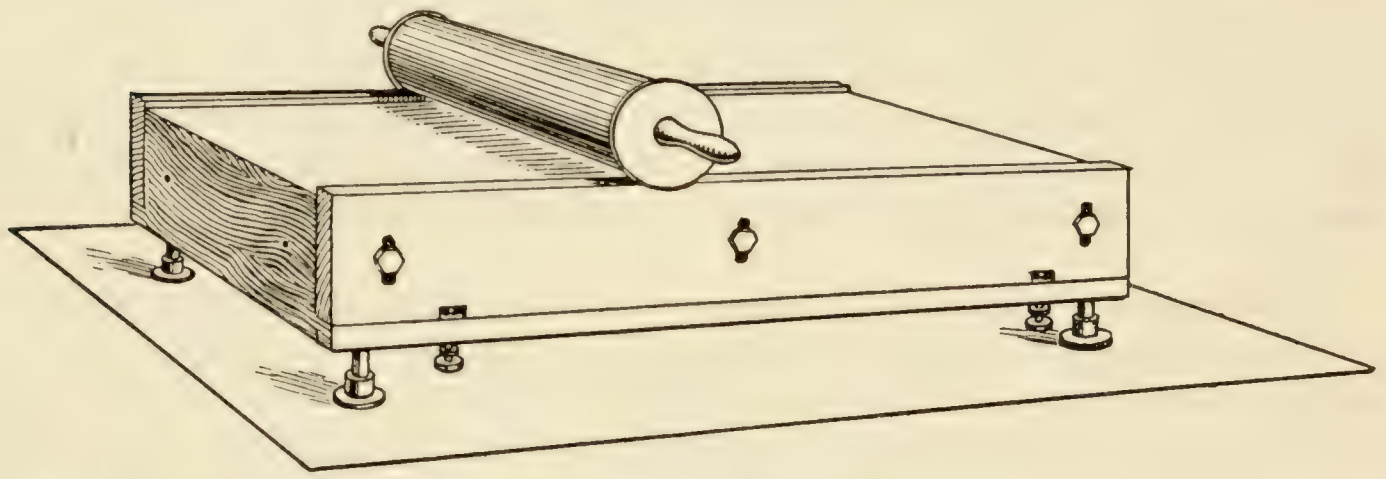

Fig. 9.—Apparatus for making wax plates, used in reconstruction by Born's method.

Huber and figured in Fig. 9 may be recommended for this purpose. It consists of a heavy cast-iron plate, supported by three adjustable legs. On two sides of the plate are found movable side-pieces which may be raised or lowered by micrometer screws to a desired height and then tightly clamped. There is, further, a heavy iron roller which runs on the adjustable side pieces. This roller needs to be heated in boiling water before use, and is kept in boiling water when not in use during the process of making wax plates. The method of making plates is as follows: The side plates are adjusted so that their upper surface projects above the main plate for a distance representing the thickness of the wax plate desired. Melted wax is then poured on the main plate, in an even layer somewhat thicker than the wax plate desired, and then rolled out with the hot roller until the roller runs evenly on the side pieces. The wax plate is now allowed to cool, when it is removed from the apparatus and placed in a pan of cold water, where it remains for a few minutes or until thoroughly cooled.

Drawing of the Portions of the Sections to be Reconstructed.—The drawings of the portions of the sections representing the portion to be reconstructed, at the magnification selected, may be made with the

aid of a camera lucida, or by means of a projection apparatus. Bardeen has devised a drawing table which is placed horizontally, over which is placed a mirror at an angle of 45 degrees. The table may be made to move by means of a windlass toward or away from the microscope so that any magnification may be quickly obtained. An ordinary microscope with the tube placed horizontally may be used, the illumination being obtained from an arc light. (For further details see Bardeen, "Johns Hopkins Bulletin," vol. xii, p. 148.) Sharp outlines of the parts to be reconstructed should be made and the drawing for each section labelled with reference to the series of drawings and with reference to the number of the section, as it is often necessary to refer to the sections while reconstructing. After the drawings have been completed they are transferred to the wax plates, which is conveniently done by placing the drawing over the wax plate and tracing the outline with a blunt-pointed instrument, using some pressure while doing so. The wax plates are numbered with reference to the drawings. It is necessary to maintain an equal ratio between the diameter of the magnification of the drawing of the sections, the thickness of the plates used and the thickness of the sections. Thus, if it is desired to reconstruct portions of a series of sections 5 μ in thickness and to use wax plates 2 mm. thick, the drawings need to be made at a magnification of 400 diameters.

Cutting Out the Parts to be Reconstructed and Completing the Model.—Those portions of the wax plates representing the parts to be reconstructed as outlined by the tracings are cut out with a sharp knife with narrow blade, the wax plate being placed on a glass plate during this procedure. If the parts of the sections to be reconstructed consist of a number of disjointed pieces, these are retained in their relative positions by means of remaining bridges of wax, which should be firm enough to keep all parts in their proper relation. The parts of each wax plate representing the portions of the section to be reconstructed are piled up in their proper sequence as they are cut out. The completion of the model consists in accurately adjusting the portions obtained from each wax plate to those which precede and follow them. This process is facilitated by building up the model in blocks representing five sections, as has been suggested by Bardeen. Those parts representing the portions of the sections to be reconstructed are united together by pins or small nails; other parts, such as wax bridges, are removed by means of a hot knife. The successive blocks are then similarly united and the model is completed by smoothing over the surfaces by means of a hot iron.

GENERAL HISTOLOGY.

I. THE CELL.

During the latter part of the seventeenth century, Hooke, Malpighi, and Grew, making observations with the simple and imperfect microscopes of their day, saw in plants small compartment-like spaces, surrounded by a distinct wall and filled with air or a liquid; to these the name *cell* was applied. These earlier observations were extended in various directions during the latter part of the seventeenth and the eighteenth century. Little advance was made, however, until Robert Brown (1831) directed attention to a small body found in the cell, previously mentioned by Fontana, and known as the *nucleus*. In the nucleus Valentin observed (1836) a small body known as the *nucleolus*. In 1838 Schleiden brought forward proof to show that plants were made up wholly of cells, and especially emphasized the importance of the nuclei of cells. In 1839 Schwann originated the theory that the animal body was built up of cells resembling those described for plants. Both Schleiden and Schwann defined a cell as a small vesicle, surrounded by a firm membrane inclosing a fluid in which floats a nucleus. This conception of the structure of the cell was destined, however, to undergo important modification. In 1846 v. Mohl recognized in the cell a semifluid, granular substance which he named *protoplasm*. Other investigators (Kölliker and Bischoff) observed animal cells devoid of a distinct cell membrane. Max Schultze (1861) attacked vigorously the older conception of the structure of cells, proclaiming the identity of the protoplasm in all forms of life, both plant and animal, and the cell was defined as a *nucleated mass of protoplasm endowed with the attributes of life*. In this sense the term cell is now used.

The simplest forms of animal life are organisms consisting of only one cell (*protozoa*). Even in the development of the higher animals, the first stage of development, the fertilized egg, is a single cell. This by repeated division gives rise to a mass of similar cells, which, owing to their likeness in shape and structure, are said to be undifferentiated. As development proceeds, the cells of this mass arrange themselves into three layers, the *germ layers*, the outer one of which is the *ectoderm*, the middle one the *mesoderm*, and the inner one the *entoderm*. In the further development, the cells of the germ layers change their form, assume new qualities, adapting themselves to perform certain definite functions; a division of labor ensues,—the cells become differentiated. Cells having similar shape

and similar function are grouped to form *tissues*, and tissues are grouped to form *organs*.

We shall now consider the structure of the cell. Every cell consists of a cell-body and a nucleus.

A. THE CELL-BODY.

The body of the cell consists of a substance known as protoplasm or cytoplasm. This is not a substance having uniform

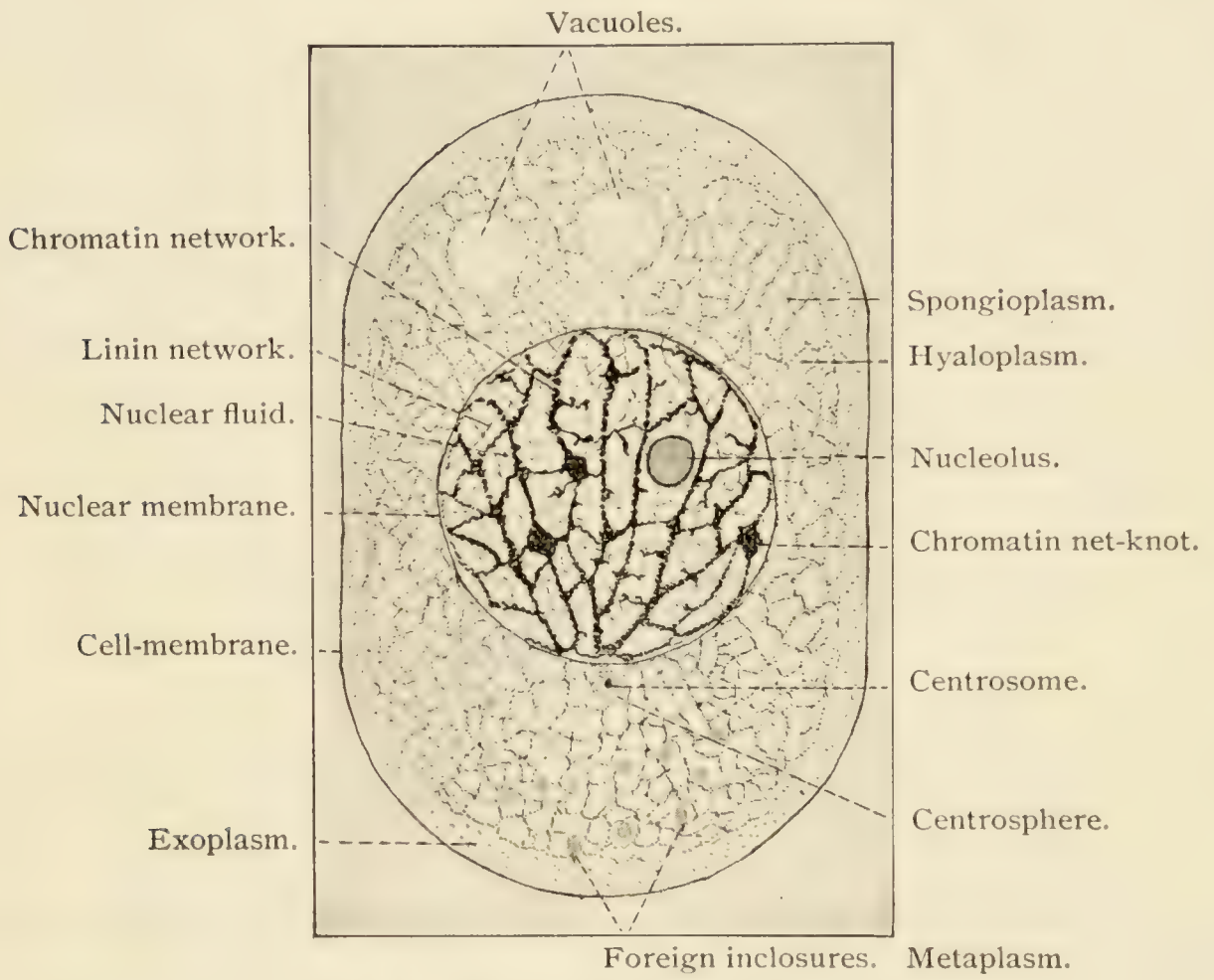

Fig. 10.—Diagram of a cell.

physical and chemical qualities, but a mixture of various organic compounds concerning which knowledge is not as yet conclusive, but which in general are proteid bodies or albumins in the widest sense.

In spite of the manifold differences in its composition, protoplasm exhibits certain general fundamental properties which are always present wherever it is found. Ordinarily, protoplasm exhibits certain structural characteristics. In it are observed two constituents,—threads or plates, which are straight or winding, which branch, anastomose, or interlace, and which are generally arranged in a regular framework, network, or reticulum. These threads probably consist of or contain small particles arranged in rows, called cell-microsomes (*vid.* van Beneden, 83; M. Heidenhain, 94; and others). Benda, who has devoted much time to the study of certain protoplasmic structures, has found in these threads small granules or

rod-shaped structures to which he has given the name "thread-granules" or mitochondria. The mitochondria can be differentially stained and are not distributed irregularly through the cell protoplasm, but in certain definite regions. They are regarded as in part identical with the microsomes. This thread-like substance is known as protoplasm in the stricter sense (Kupffer, 75); also as *spongioplasm*, or the fibrillar mass of Flemming (82). The other constituent of the cytoplasm is a more fluid substance lying between the threads in the meshes of the spongioplastic network, and is known as *paraplasm* (Kupffer), hyaloplasm, cytolymph, or the interfibrillar substance of Flemming. According to most investigators, the more important vital processes of the cell are to be identified with the spongioplasm, and are controlled by the nucleus, while the paraplasm assumes an inferior or passive rôle. With special methods Altman (94) was able to demonstrate granules in the protoplasm, associated with, but not in the spongioplastic threads. To these he gave the name *bioblasts*, and referred the vital qualities of the protoplasm to them. Bütschli believes the protoplasm to consist of

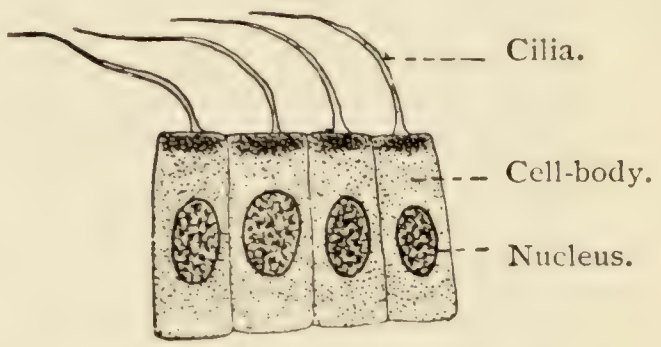

Fig. 11.—Cylindric ciliated cells from the primitive kidney of *Petromyzon planeri*; × 1200.

separate, honeycomb-like spaces, which give it a foam-like structure —foam-structure of protoplasm.

Protoplasm displays phenomena of motion, shown on the one hand by contraction, and on the other by the formation of processes that take the form either of blunt projections or lobes, or of long, pointed, and even branched threads or processes known as *pseudopodia*. The extension and withdrawal of the pseudopodia enable the cell to change its position. The point of such a process fastens to some object and the rest of the cell is drawn forward, thus giving the cell a creeping motion—*wandering cells*. Certain cells take up and surround foreign bodies by means of their pseudopodia. If these bodies are suitable for nutrition, they are assimilated; if not, they can, under certain circumstances, be deposited by the cell in certain localities (Metschnikoff's phagocytes). Similar thread-like processes which, however, can not be drawn into the cell, occur in some cells in the shape of cilia, which are in constant and energetic motion—*ciliated cells*. Certain cells possess only a single long process, by means of which unattached cells are capable of direct or rotating motion—*flagellate cells*, *spermatozoa*.

Inside of the cell-body the protoplasm also shows phenomena of motion, the streaming of the protoplasm. In plant cells there is often a noticeable regularity in the direction of the current. Mention should not be omitted of the so-called *molecular* or *Brownian* movement in the cells, which consists in a rapid whirling motion of particles or granules suspended in the protoplasm (Brown).

Living protoplasm is irritable in the highest degree, and reacts very strongly to chemic and physical agents. It is very sensitive to changes in temperature. All the phenomena of life occur in greater intensity and more rapidly in a warm than in a cold temperature, this fact being very strikingly shown by the phenomena of motion in the cell, as also in its propagation. By subjecting protoplasm to different temperatures, its various movements can be slowed or quickened. It dies in too high or too low a temperature.

Certain substances coming in contact with the cell from a given direction have on it an attracting or repelling action. These phenomena are known as positive and negative *chemotropism* (*chemotaxis*). The action of chemic agents on the different wandering cells of the body and on certain free-swimming unicellular organisms naturally varies to a great degree. Among these phenomena must be included those produced by water (hydrotropism) and light (heliotropism). It is very probable that all these phenomena are of importance to the proper appreciation of some of the processes going on in the vertebrate body (as, for instance, in the origin of diseases caused by micro-organisms).

Protoplasm may contain various structures. Of these, the *vacuoles* deserve special mention. They are more or less sharply defined cavities filled with fluid, and vary considerably in number and size. The fluids that they contain differ somewhat, but are always secreted by the protoplasm, and are, as a rule, finally emptied out of the cell. As a consequence, vacuoles are best studied where the function of the cell is a secretory one. Here they are often large, and sometimes fill up the whole cell, the contents of which are then emptied out (*glandular cells*).

Contents of a solid nature, such as fat, pigment, glycogen, and crystals, are peculiar to certain cells. By these deposits the cell is more or less changed, the greatest variation in form taking place in the production of fat. The latter, as a rule, takes the shape of a globule, and greatly modifies the position of the normal constituents of the cell. Deposits of pigment alter the cells to a less degree. This substance occurs in the protoplasm either in solution or in the form of fine crystalline bodies. Glycogen is more generally diffused, occurring very generally in embryonal cells and in the liver- and cartilage-cells of the adult. Occasionally we find larger crystals in animal cells, as, for instance, in the red blood-corpuscles of the teleosts. So-called margarin crystals sometimes occur in large numbers as stellate figures in dead fatty tissues kept at low temperatures.

Many cells are without a distinct cell membrane, another constituent of the protoplasm. In such cells the outer layer of the protoplasm is often more homogeneous and less dense than that lying more centrally, which has often a more granular appearance; the outer layer of the protoplasm is in such cells known as the exoplasm, in contradistinction to the more granular endoplasm.

In other cells, however, the outer layer of the cell-protoplasm shows differentiation, leading to the formation of a distinct cell-membrane (as in fat-cells, cartilage-cells, goblet-cells, etc.). F. E. Schulze has given it the name *pellicula* in cases where the entire cell is surrounded by a homogeneous layer, and *cuticula* or cuticle where only one side of the cell is supplied with the membrane (as in the intestinal epithelium). It is assumed that both spongioplasm and paraplasm are concerned in the formation of this membrane.

In the protoplasm of many cells there is found a small body known as the *centrosome*. This is usually situated near the nucleus of the cell, occasionally in the nucleus. Generally, it has the appearance of a minute granule, sometimes scarcely larger than a microsome. It is often surrounded by a small area of a granular or finely reticular or radially striated cytoplasm, known as the *attraction-sphere* or *centrosphere*.

B. THE NUCLEUS.

The second constant element of the cell is the nucleus. As a rule, it is sharply defined, and in its simplest form consists of a round vesicle of a complicated structure composed of several substances. The form of the nucleus corresponds in general to the shape of the cell; in an elongated cell, it is correspondingly long, and flattened where the cell is plate-like in shape. The nucleus of a wandering cell that is in the act of passing through a narrow intercellular cleft adapts itself to the changes of form in the cell without being permanently altered in shape. In other words, the nucleus is soft, and can be easily distorted by any solid substances within or without the protoplasm, only to resume its original form when the pressure is removed. It possesses, then, a certain amount of elasticity. Movements of certain nuclei, entirely independent of the surrounding protoplasm, have often been observed. It is only rarely that the general form of the nucleus differs materially from the general form of the cell. This, however, occurs in the nuclei of leucocytes and many of the giant cells of bone-marrow, which are often irregular, and may even be ring-shaped. In certain arthrozoa, branching forms of nuclei occur, as also in the skin glands of turtles. The proportionate size of nucleus to cell-body varies greatly in different cells. Especially large nuclei are found in immature ova, in certain epithelial cells, etc.

The contents of the nucleus consist of a framework or reticulum, in the meshes of which there is found a semifluid substance.

In treating the nuclei with certain stains, the nuclear reticulum will be seen to consist of two constituents, a substance appearing in the form of variously shaped, minute granules, which stains deeply, and is, therefore, known as *chromatin*. This is imbedded in and deposited on a less stainable network, the *linin*. The meshes of this network are occupied by a transparent, semifluid substance, which does not stain easily, and is known as the *achromatic* portion of the nucleus. It is also known as paralinin, nuclear sap, karyolymph, or nucleoplasm. Chemically, chromatin belongs to those albuminous substances known as nucleins.

In well-stained nuclei of considerable size the chromatin granules are seen closely placed in a continuous row throughout the network of linin, which penetrates the nuclei in all directions. In every resting nucleus one or more small round bodies are found imbedded in the nucleoplasm. These are known as true *nucleoli*, and do not stain quite so deeply as the chromatin. The fact that certain reagents dissolve the chromatin, but not the true nucleoli, proves that the substance of which the latter are composed is not identical with chromatin,—and is, therefore, known as *paranuclein* (F. Schwartz).

In many cases we find in the linin, granules of a substance known as lanthanin, which displays a marked affinity for the so-called acid anilin stains, in contradistinction to chromatin, which stains principally with the basic anilin colors. These are known as oxychromatin granules in contradistinction to the basichromatin granules of the chromatin (M. Heidenhain, 94).

The true nucleoli should not be confused with the slight swellings of the chromatin network found at the junction of the threads, and known as net-knots, or karyosomes.

Surrounding the resting nucleus is usually a *nuclear membrane* (amphipyrenin) resembling in many respects chromatin. As a rule, it does not form a continuous layer, but is perforated, having openings that contain nuclear fluid. We have, then, both substances, chromatin and nucleoplasm, as elements of the nuclear membrane. Besides this, the nuclear membrane receives an outer layer, differentiated from the protoplasm. Later investigations have shown that even during a period of rest the relationship of the nucleus to the protoplasm of the cell is much more intimate than was heretofore believed (*vid.* Reinke, 94).

A resting nucleus—*i.e.*, one not in process of division—usually consists, therefore, of a sharply defined membrane (amphipyrenin), which has in its interior a chromatic (nuclein) and an achromatic (linin) network, a nuclear fluid (paralinin), and nucleoli (paranuclein).

The chromatin of the nucleus is not always in the form of a network. In some cases—as, for instance, in the premature ova of certain animals (O. Hertwig, 93. II) and in spermatozoa—it is collected in compact bodies. In the ova it may often be mistaken for a true nucleolus (germinal spot). In this case, however, it consists of nuclein, and not of paranuclein.

C. NUCLEAR AND CELL-DIVISION.

The founders of the cell theory believed in what may be known as a modification of the theory of spontaneous generation, stating that cells might originate from a structureless substance known as *kytoblastema* or *blastema*, in which a nucleus was formed by precipitation. Henle (1841) drew attention to the fact that cells might multiply by the separation of small portions of the cell-body, a process known as *budding;* and Barry (1841) stated that during the multiplication of cells the nuclei divided. The same year Remak observed division of cells in the blood of embryos. Goodsir (1845) originated the theory that all cells were developed from preexisting cells. This was first clearly stated as a general law by Virchow (1855), and his saying, "*Omnis cellula a cellula*," is constantly being verified. Our more accurate knowledge of cell-division dates, however, from more recent times (1873–80), when Schneider, Fol, Strasburger, Flemming, and many others demonstrated that during the division of the cell the nucleus passed through a series of complicated changes which resulted in an exact division of the chromatin.

The phenomena which usher in cell-division are especially noticeable in the nucleus, the elements of which are arranged and transformed in a typic manner. During the division of the nucleus the nuclear membrane is lost, and the relationship of the substances of the nucleus to the protoplasm of the cell is a very intimate one. As a consequence, during the middle phases of division there is no well-defined demarcation between the nucleus and the cell-body. As a rule, the mother cell and nucleus divide into two daughter cells, each having a nucleus, alike in every particular. It was early observed, however, that occasionally cells divided by a much simpler process, in which case the nucleus did not pass through such complicated changes. Accordingly, two distinct types of cell-division are recognized, which are distinguished as *mitosis*, *karyokinesis*, or *indirect* cell-division, and *amitosis*, or *direct* cell-division. Both lead to the formation of two nuclei, which are known as daughter nuclei as distinguished from the original mother nucleus.

1. MITOSIS OR KARYOKINESIS (INDIRECT CELL-DIVISION).

The description of the process of mitotic cell-division is complicated by the fact that structural changes are observed which occur simultaneously in the nucleus, centrosome, and cytoplasm. This fact should be borne in mind, as, for the sake of clearness, a separate description of the changes involving each of these structures seems demanded. The process of mitotic cell-division may be divided into four periods or phases, which follow one another without clearly defined limits:

The *prophases*, in which the nuclear membrane disappears, the chromatin is transformed into definite threads, and the centrosome

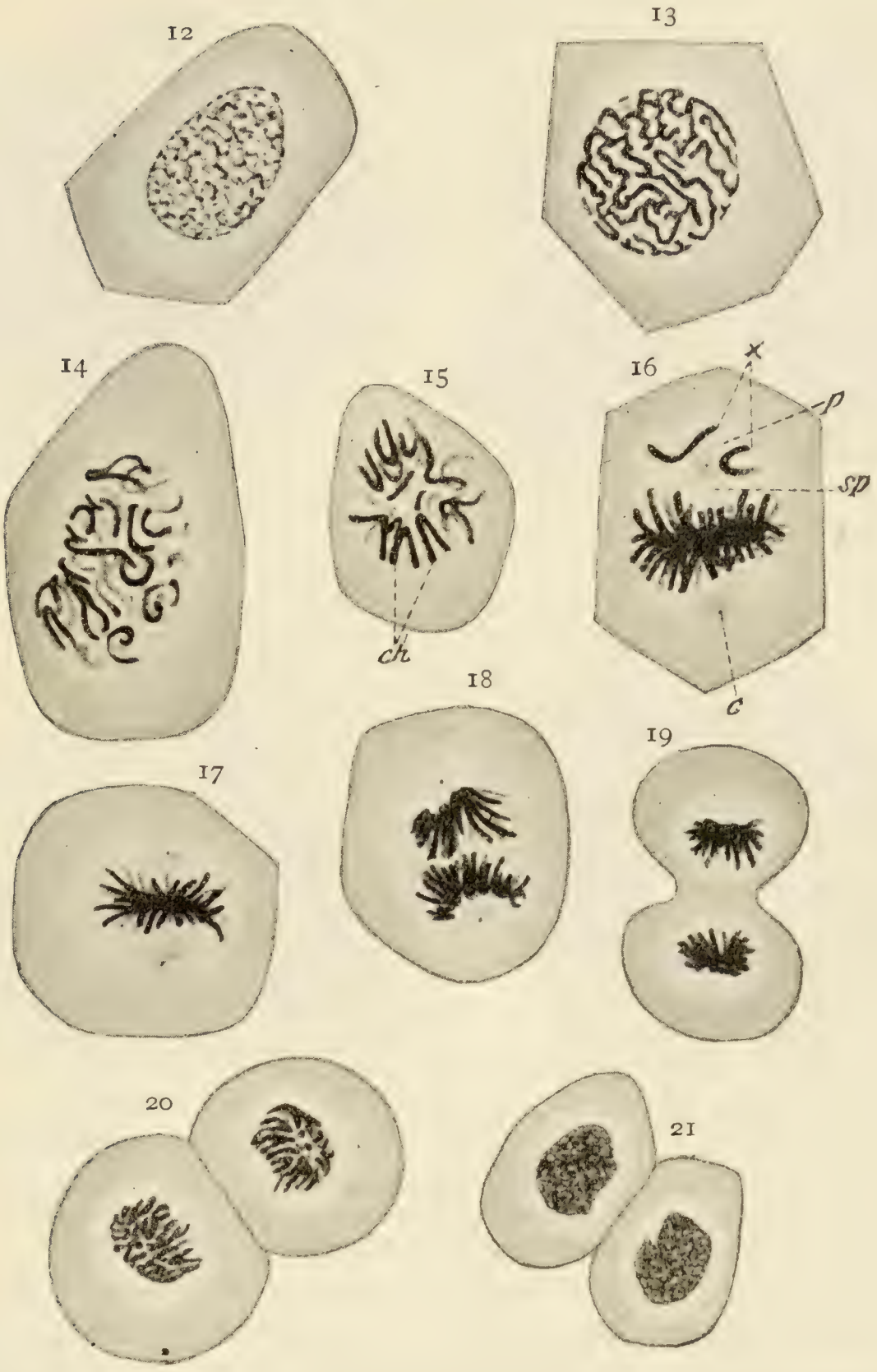

Figs. 12–21.—Ten stages of mitotic nuclear division from the oral epithelium of the larva of a salamander. (Plate I, Sobotta and Huber's "Atlas and Epitome of Human Histology," 1903) : Fig. 12, Cell with resting nucleus ; Fig. 13, cell with nucleus at the beginning of mitosis; Fig. 14, nuclear membrane has disappeared, chromosomes in a loose skein, pole field at the left ; Fig. 15, monaster viewed from above ; Fig. 16, monaster viewed from the side, achromatic spindle is also shown ; Fig. 17, monaster viewed from the side, with chromosomes crowded closely about the equator of the spindle ; Fig. 18, stage of metakinesis ; Fig. 19, diaster with beginning constriction of the cell-body ; Fig. 20, dispirem with completion of the cell division ; Fig. 21, telophase.

---

and centrosphere undergo important changes. This is the preparatory stage.

The *metaphases*, in which the division and the separation of the chromatin take place.

The *anaphases*, in which the daughter nuclei are formed and the cell-protoplasm begins to divide.

The *telophases*, in which the division of the cell is completed.

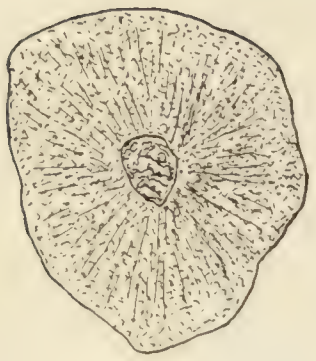

Fig. 22

Fig. 23.

Fig. 24.

Fig. 25.

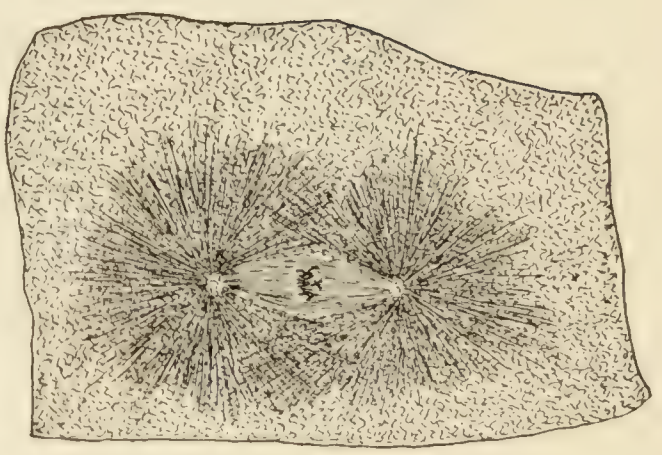

Fig. 26.

Figs. 22–26.—Mitotic cell-division of fertilized whitefish eggs—*Coregonus albus.*

Fig. 22, Cell with resting nucleus, centrosome, and centrosphere to the right of the nucleus; Fig. 23, cell with two centrospheres, with polar rays at opposite poles of nucleus; Fig. 24, spirem; Fig. 25, monaster; Fig. 26, metakinesis stage.

To give a better understanding of the process we have inserted a series of figures in which several phases of mitotic division are portrayed. In figures 12–21 are shown ten stages of mitotic nuclear division from the oral epithelium of the larva of a salamander, in which changes undergone by the nucleus and centrosome are clearly brought out. And, further, a series of figures (22–29) showing the different phases of mitotic cell-division of the fertilized eggs of the whitefish (*Coregonus albus*); the changes involving the centrosome, centrosphere, and cytoplasm are illustrated. Figure 30, showing a small portion of a section through the testis of the salamander, the object in which Flemming first observed this complicated series of changes, presents the appearance more generally seen during mitotic cell-division of the tissue cells of the higher vertebrates.

(*a*) **Prophases.**—The changes occurring in the nucleus will be considered first. At the beginning of the process of mitosis, the chromatin network, consisting of chromatin granules, is transformed into a twisted skein of threads, beginning at the periphery of the

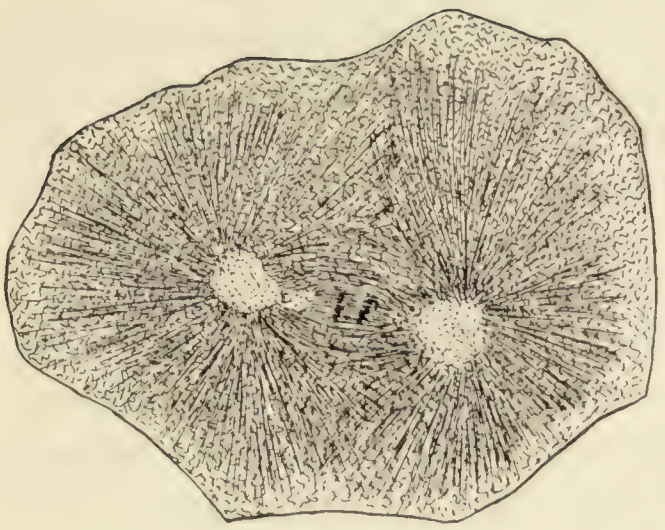

Fig. 27.

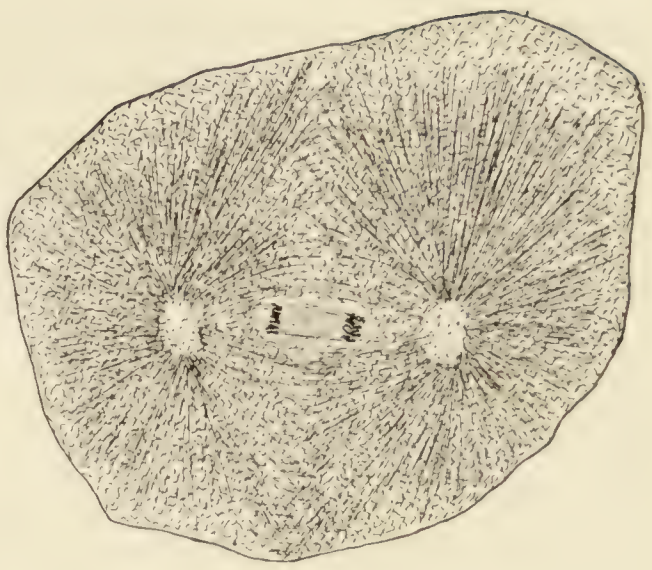

Fig. 28.

Fig. 29.

Figs 27–29.—Mitotic cell-division of fertilized whitefish eggs—*Coregonus albus.*

Fig. 27, Metakinesis stage; Fig. 28, diaster; Fig. 29, late stage of dispirem, the cell-protoplasm almost divided.

---

nucleus. This skein of threads is known as the *spirem* or *mother skein*, and may appear as a single thread, which breaks up into a definite number of segments, or the segments may appear as such when the skein is forming. At first the threads are coarse and often somewhat irregular, staining much more deeply than the linin network. The separate segments of chromatin are known as *chromosomes* (Waldeyer, 88). They appear, as a rule, in the form of rods varying in length and thickness, and staining very deeply, and often bent into characteristic U-shaped loops. The bent portion of each loop is called its crown. "Every species of plant or animal has a fixed and characteristic number of chromosomes, which regularly recurs in the division of all its cells; and in all forms arising by sexual reproduction the number is even" (Wilson, 96). In man the number of chromosomes is given as sixteen by Bardeleben (92) and Wilson (96), and as twenty-four by Flemming (98).

During the formation of the spirem the nuclear membrane, as a rule, disappears. The nucleolus is also lost sight of, although the manner of its disappearance can not be definitely stated. The net-knots are no doubt taken up by the chromosomes. The chromo-

somes are now free in the protoplasm ; gradually the crown of each chromosome approaches the center of the space occupied by the nucleus, and the chromosomes form a characteristic, radially arranged stellate figure, known as the *monaster*, in the equatorial plane of the cell. During the progress of the changes affecting the chromatin of the nucleus and resulting in the formation of the chromosomes, important phenomena are observed, connected partly with the achromatic substance of the nucleus, more especially with the centrosome, centrosphere, and cytoplasm of the cell. These phenomena result in the formation of a complicated structure known as the *achromatic spindle* or *amphiaster*. Its development is as follows : The centrosome and centrosphere, as has been stated, usually lie in the protoplasm to one side of the nucleus. If, at the beginning of the division, the centrosome be single, it divides, and the two centrosomes begin to separate, causing a division of the centrosphere. Between the centrosomes are usually seen finely drawn-out connecting threads. The centrosomes, each of which is surrounded by a centrosphere, now move apart, and a structure known as the *central spindle*, and consisting of fine threads arranged in the form of a spindle, develops between them. At each end of the central spindle is found a centrosome surrounded by a centrosphere from which radiate into the cytoplasm fine fibers known as *polar rays*. During the formation of the achromatic spindle the nuclear membrane disappears and the chromosomes develop, as above described. Some fibers, which seem to have their origin from the centrosphere, grow into the spirem formed of chromosomes, which they appear to pull into the equatorial plane of the cell, which is also the equator of the central spindle. Thus, the nuclear figure above described as the monaster is formed. In other cases the centrosomes and centrospheres continue moving apart until opposite each other and separated by the nucleus (Figs. 23, 24). As the nuclear membrane disappears and the spirems and chromosomes are forming, the central spindle develops, its fibers running from centrosphere to centrosphere. The polar rays also develop in the cytoplasm at the same time. As the central spindle develops, the chromosomes arrange themselves or are arranged about its equator —monaster.

(*b*) **Metaphases.**—Usually, during the formation of the monaster, or immediately after its formation (sometimes in the spirem stage or even earlier), the most important process of cell-division takes place. Each chromosome divides longitudinally into two *daughter chromosomes*. The loops first divide at the crown, the cleft extending up either limb until the free ends are reached. The smallest particle of chromatin divides, retaining the exact relative position in the twin chromosomes that it possessed in the mother chromosome. The daughter chromosomes now wander over the central spindle, their crowns presenting, in opposite directions toward the poles of the cell. This process is known as *metakinesis*. Two stel-

late figures are developed about the respective poles of the central spindle. The appearance presented is known as a *diaster*. Our knowledge of the part taken by the amphiaster or achromatic spindle in metakinesis is not above controversy. It would appear, however, that certain cytoplastic fibers, which arise from the centrosphere and hang over the central spindle and chromosomes, designated as *mantle fibers*, assist in drawing the daughter chromosomes toward the poles of the central spindle.

(*c*) **Anaphases.**—After the formation of the diaster, the loops belonging to each stellate figure are joined together to form a skein, thus forming the *dispirem*. The chromatin threads of the two skeins gradually assume the disposition found in the resting nucleus. This process takes place in such a way that the threads of the

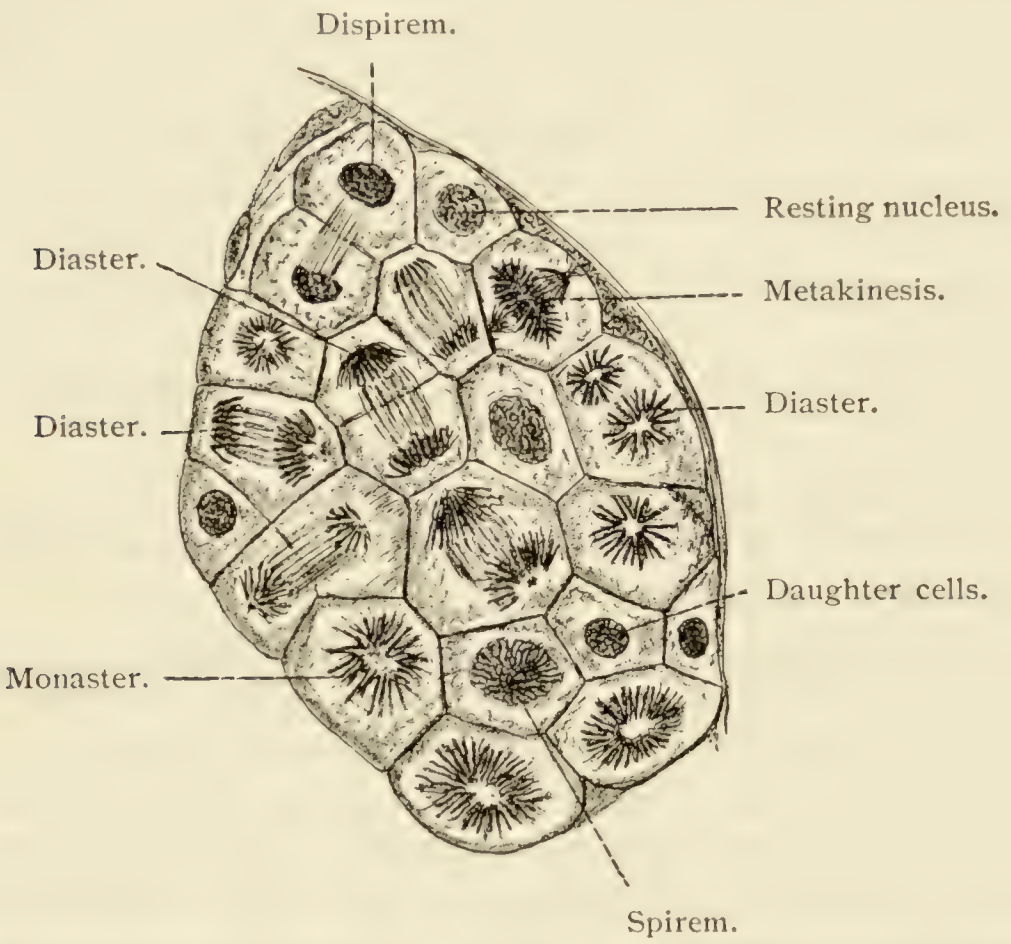

Fig. 30.—Mitotic division of cells in testis of salamander (Benda and Guenther).

skeins (or the single thread) send out lateral processes. These interlace, and little by little reproduce the network of the resting nucleus; at the same time the nuclear membrane and the nucleolus reappear. In this stage the changes that lead to the division of the cell-body are observed. In some cases the division of the cell-body is ushered in by an equatorial differentiation of the connecting threads of the central spindle. Chains of granules, arranged in double rows, are seen to appear in this region. The cell now begins to contract at its equator, the contraction extending between the two chains of granules until the cell is completely divided. At this time, also, the threads of the amphiaster disappear or are drawn into the nucleus. The centrosomes, with centrospheres, again lie by the side of the daughter nuclei.

According to the opinion of C. Rabl (85), there remains in the nucleus, even after it has fully returned to a state of rest, a polar arrangement of the chromatin loops—that is, an arrangement of the axis of the loops in the direction of the centrosphere. The area toward which the crowns of the loops point is known as the *polar field.*

The equatorial differentiation of the connecting threads of the central spindle, above mentioned, was first observed in vegetable tissue, and is known as the *cell-plate.* (Fig. 29.) In animal cells such a plate is relatively rare, and, when seen, is found developed in a rudimentary form (v. Kostanecki 92, I).

(*d*) **Telophases** (M. Heidenhain 94).—In these phases of mitosis the cell divides completely. The daughter nuclei and centrospheres, which do not yet occupy their normal position in the daughter cells, show movements that result in their assuming their normal positions.

From our description it is seen that the anaphases represent the same stages as the prophases, only in an inverted sequence. In the latter case, the result is the resting nucleus, while the prophases lead to the metaphases.

The fertilized ovum also divides by indirect nuclear division. (Figs. 22–29.) From it are derived, by this process, the segmentation cells, or *blastomeres,* from which the whole embryo is developed.

(*e*) **The Heterotypic Form of Mitosis.**—The above-described type of indirect or mitotic nuclear division (*homeotypic mitosis*) is the usual one. Variations, however, occur, as, for instance, in the so-called *heterotypic* form of division (Flemming 87), which occurs in certain cells of the testes (spermatocytes). In this form the first stages are lacking, the nucleus possessing from the beginning a skein-like structure. The longitudinal splitting and division of the chromatin threads take place during the first spirem stage, after which there is a phase in which the figure may be compared with an aster of ordinary mitosis, although the free ends of the threads in this case are seldom observed. The latter is due to the fact that after the longitudinal splitting, the ends of the chromosomes remain united, or, if entire separation occurs, they are again joined. In this way closed loops are formed extending from pole to pole. Later the threads break at the equator and move toward the poles, again dividing to form the daughter stars.

2. AMITOSIS.

Very different from the indirect form of nuclear division is the *direct* or *amitotic.* It appears to occur seldom as a normal process, and is only exceptionally followed by a subsequent cell-division (*vid.* Flemming, 91, III). As a consequence, this process, in most cases, results in the formation of *polynuclear cells* (polynuclear leucocytes, giant-cells, etc.). The complicated nuclear figures of

indirect division are here entirely absent. The nucleus merely contracts at a certain point and separates into two or more fragments (*direct fragmentation*, Arnold); often the nucleus first assumes an annular form and then breaks up into several fragments, which remain loosely connected (polynuclear cells). Centrospheres are also present, and appear to take a prominent part in the whole process, although the exact relationship between the achromatin and chromatin has not as yet been determined.

Nemiloff has recently called attention to two locations where amitotic divisions may readily be observed—namely, in the large surface cells of transitional epithelium of the bladder of mammals and in the lymphoid tissue layer of the liver of amphibia. In the cells of the former type the nuclear division is initiated by a division of the nucleolus which is followed by a division of nucleus and later the protoplasm. Centrosomes and attraction spheres were not noticed in these cells. The division of the lymphoid cells of the amphibian liver is initiated by a depression found in one side of their spherical nuclei. This depression deepens until the nuclei become perforated and assume an annular shape. These ring-shaped nuclei then break through in two or more places and two or more daughter nuclei are formed. During the process of division a centrosome with attraction sphere may often be observed, generally situated in the depression which initiates the division and later in the center of the perforated nucleus. Its rôle in the division of the nucleus and the cell-body is, however, not fully understood.

D. PROCESS OF FERTILIZATION.

The sexual cells form a special group among cells in general. Before the division of the egg-cell leading to the development of the embryo can take place, the ovum must be impregnated (the so-called parthenogenetic ova are an exception to this rule). Fertilization is produced by the male sexual cell, the spermatozoon.

The process of fertilization consists in a conjugation of two sexual cells, and in this process certain peculiarities in the behavior of both cells must be mentioned.

The cell forming the ovum and the one forming the spermatozoon must pass through certain stages before fertilization can be accomplished. These consist in the loss of half their chromosomes by the nuclei of both sexual cells. In this way are produced the *matured* sexual cells (ova and spermatozoa), which retain only half of the number of chromosomes of a *somatic* (body-) cell. In the conjugation of the male and female sexual cells their nuclei unite to form a single nucleus, known as the *segmentation nucleus*. Consequently, this nucleus contains the same number of chromosomes as does that of a somatic cell.

In its earlier developmental stages the ovum is an indifferent cell, the nucleus of which is known as the *germinal vesicle*. As the

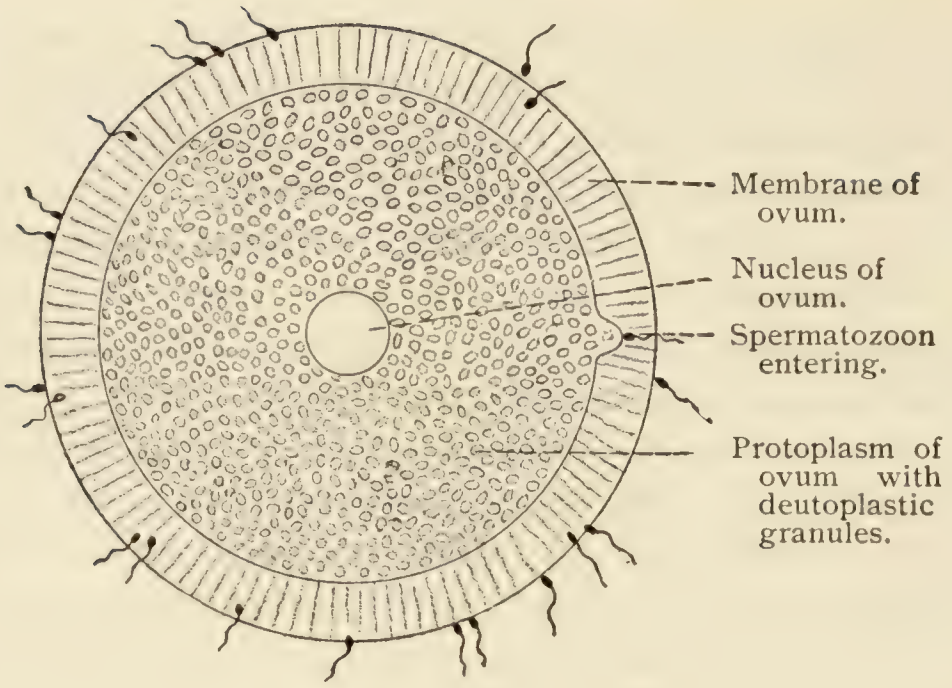

Fig. 31.

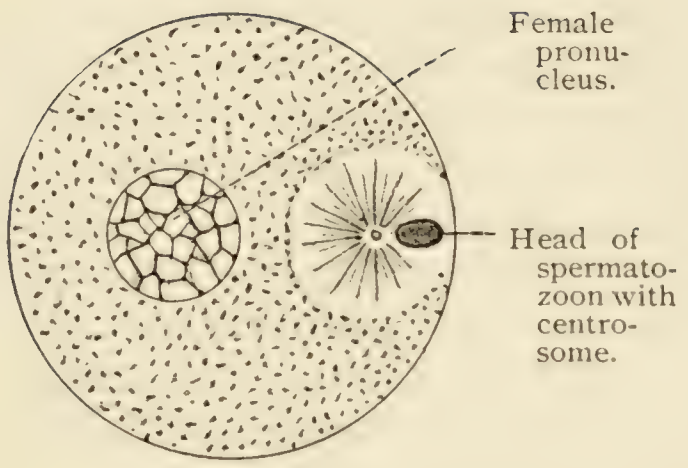

Fig. 32.

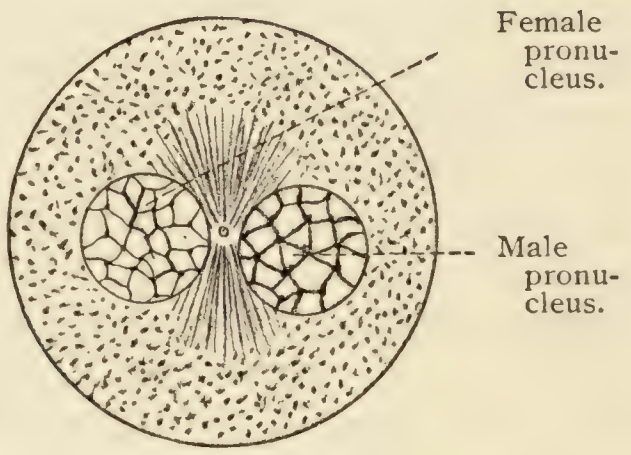

Fig. 33.

Figs. 31–33.—Diagrams of the process of fertilization, after Boveri.

Figure 31, the ovum is surrounded by spermatozoa, one of which is in the act of penetration. Toward it the yolk is pushed forward in a short, rounded process. Figure 32, the tail of the spermatozoon has disappeared. Beside the head is a centrosome with polar radiation. Figure 33, the pronuclei approach each other.

---

ovum matures the germinal vesicle approaches the periphery, and a peculiar metamorphosis, which may be regarded as a double, unequal division of the egg-cell, takes place. One portion, in the case of both divisions, is much smaller than the other, and is known as a *polar body*. At the close of these divisions, during which the chromosomes have been reduced to half the original number, there are, therefore, two polar bodies and the matured ovum, which is now ready for impregnation.

The development of the male sexual cell in its earlier stages is similar to that of the ovum. They are derived from cells known as *spermatogones*. These divide into equal parts, forming the cells of a second generation, the *spermatocytes*. From a further division of the spermatocytes, during which division the chromosomes are reduced to half the number, the *spermatids* are produced. These latter are then changed directly into spermatozoa. The reduction division of the egg-cell and that of the spermatocytes is in principle the same, except that in spermatogenesis *all* cells become matured sexual cells

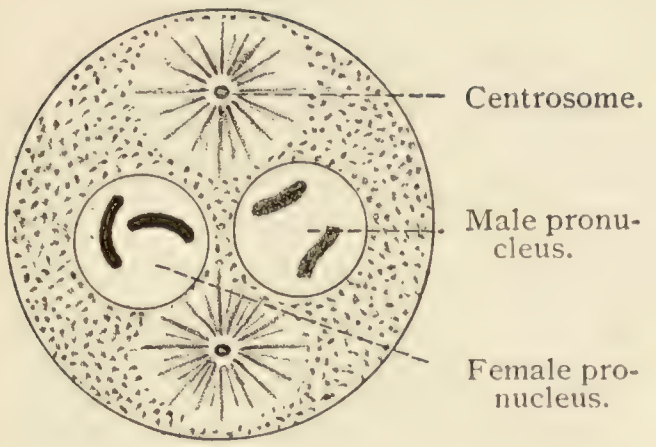

Fig. 34.

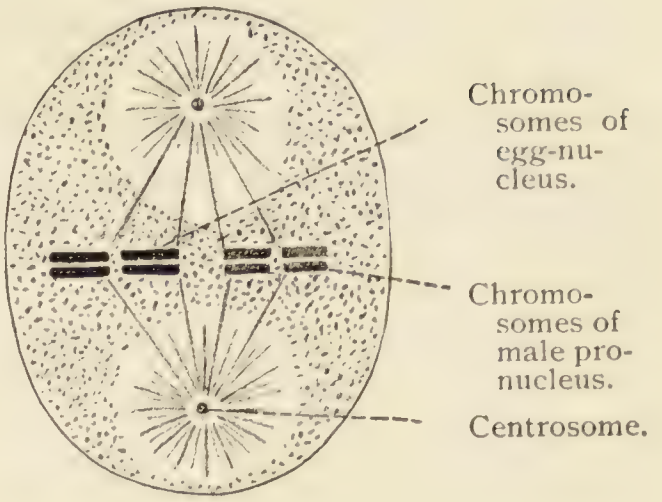

Fig. 35.

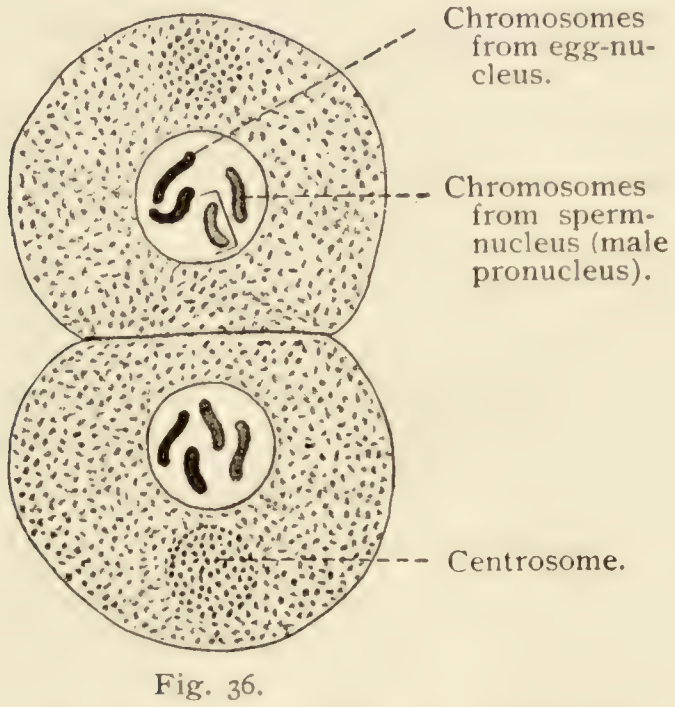

Fig. 36.

Figs. 34–36.—Diagrams of the process of fertilization, after Boveri.

Figure 34, from the spirems in the pronuclei, chromosomes have been formed. The centrosphere has divided. Figure 35, the double chromosomes of the two pronuclei lie in the equatorial plane of the ovum. Figure 36, the ovum has divided. Chromosomes from the male and female elements are seen in equal numbers in both daughter nuclei.

(spermatozoa). In short, there is here an absence of structures analogous to the polar bodies, which degenerate after maturation of the ovum.

The spermatozoa are flagellate cells. The head consists principally of nuclear substance, to which is added a smaller middle-piece containing, according to the investigations of Fick, the centrosome. These two portions of the male sexual cell, the head- and middle-piece, are the most important, and are exclusively concerned in fertilization, the flagellum or tail playing no part in this process.

The spermatozoon usually penetrates the ovum after the first polar body has been extruded. The tail disappears during this process, being either left at the periphery of the egg or dissolved in the protoplasm. From this time the head represents the so-called *male pronucleus*, and the middle-piece the centrosome. From this stage the male pronucleus undergoes changes, the first of which consists of a loosening of the chromatin. Chromatin granules are

formed, which later arrange themselves in the form of chromosomes.

After the second polar body has been extruded, the chromatin remaining in the ovum is transformed into the *female pronucleus*. The latter then approaches the male pronucleus, the membranes of both nuclei disappearing. The chromosomes of the two nuclei thus formed are of equal number, and now come to lie together. After a longitudinal division of the chromosomes, the daughter chromosomes glide along the filaments of the achromatic spindle, developed from the centrosome of the male pronucleus, toward its two poles, as in ordinary mitosis. This they do in such a manner that an equal distribution of the male and female daughter chromosomes results. Then follow the stages of the anaphase.

From the above description of the process of fertilization it is seen that it consists, in the end, of a union of the nuclei of both sexual cells.

If paternal qualities are inherited by the offspring, this can only take place through the nucleus, or through the centrosome of the male sexual cell. In other words, it can be safely said that these structures, or the nucleus alone, are the principal means of transmitting inherited qualities. The same may also be said of the female pronucleus. There is no doubt that the first two segmentation cells of the ovum are equally provided with male and female nuclear elements. Since all future cells are derivatives of these two, it is possible that the nucleus of every somatic cell (body-cell) is hermaphroditic.

E. CHROMATOLYSIS.

In the living organism many cells are destroyed during the various physiologic processes and replaced by new ones. On the death of a cell, changes take place in its nucleus which result in its gradual disappearance. These processes, which seem to follow certain definite but as yet unfamiliar laws, have been known since their study by Flemming (85, I) by the name of *chromatolysis* (karyolysis). The nuclei during the course of these changes show many varied pictures.

TECHNIC.

In a fresh condition, cells do not show much of their internal structure. Epithelial cells of the oral cavity, which can easily be obtained and examined in the saliva, show really nothing except the cell outlines and the nuclei. More, however, can be seen in young ova isolated from the Graafian follicles of mammalia ; or the examination may be facilitated by using the ovary of a young frog. Tissues that are especially adapted for the observation of cells in a fresh condition are small ova, blood-corpuscles, and epithelia of certain invertebrate animals (shellfish,

etc.). Unicellular organisms such as amebæ, infusoria, and many low forms of vegetable life make also good material for this purpose.

Protoplasmic currents are best seen in the tactile hairs of the nettle. Should fresh animal cells be desired, amebæ can occasionally be found in muddy or marshy water. The same phenomena may be observed in the leucocytes of the frog or, better still, in the blood of the crab.

In order to make a detailed study of the minute relationship of the different cellular structures, it is necessary to fix the cells; the same is true of nuclear division and cell proliferation. Although this process has been observed in living cells, it was not until it had been thoroughly worked out in preserved preparations. The best results in the study of the cell are obtained by methods that will be subsequently described. Fresh tissues are absolutely essential.

According to Hammer, mitosis in man does not cease immediately after death. The nuclei suffer chromatolytic destruction, and the achromatic spindle is the last element to disappear.

Flemming's solution here deserves first mention as a fixative. The tissues are imbedded, sectioned, and stained with safranin. An equally good fixative is Hermann's solution, which may be combined with a subsequent treatment with pyroligneous acid. Rabl fixes with a 0.1–0.12% solution of chlorid of platinum, washes with water, passes into gradually stronger alcohols, then stains with Delafield's hematoxylin, and finally examines the preparation in methyl alcohol.

Mitoses can also be seen by fixing in **corrosive sublimate, picric acid, chromic acid, etc.**, and staining in bulk with hematoxylin or carmin, although perhaps not so well as by the preceding method. The objects to be examined are best when obtained from young and growing animals, especially those possessing large cells. Above all are to be recommended the larvæ of amphibia, like the frog, triton, and salamander. If examination by means of sections be undesirable, thin structures should be procured, such as the mesentery, alveoli of the lungs, epithelium of the pharynx, urinary bladder, etc. These have the advantage of enabling one to observe the whole cell instead of parts or fragments of cellular structures. In sections of a larva that has been fixed *in toto*, mitotic figures can be seen in almost all the organs, and are particularly numerous in the epithelium of the epidermis, gills, central canal of the brain and spinal cord, etc. Other organs, such as the blood, liver, and muscle, also show mitoses.

Certain vegetable cells are peculiarly adapted to the study of mitosis, as, for instance, those in the ends of young roots of the onion. The onion should be placed in a hyacinth glass filled with water and kept in a warm place. After two or three days numbers of small roots will be found to have developed. Beginning at the points, pieces 5 millimeters in length are cut, which are treated in the same manner as animal tissues. These are then cut, either transversely or longitudinally, into very thin sections (not over 5 μ in thickness). In one plane, polar views of the mitoses are obtained; in the other, lateral views.

The methods used for demonstrating the remaining parts of the cell and its nucleus (except the chromatin) are, as a rule, more complicated, and consequently less reliable. In order to see the centrosome, the spindle fibrils, the linin threads, and the polar rays, one of the

methods already described may be used; viz., the treatment with pyroligneous acid of objects previously fixed in osmic acid mixtures.

According to Hermann (93, II), sections from such preparations can be **double-stained** as well as those that have not been treated with pyroligneous acid. They are accordingly stained with safranin in the usual manner, and afterward treated from three to five minutes with the following solution of gentian violet: 5 c.c. of a saturated alcoholic solution of the stain is dissolved in 100 c.c. of anilin water. The latter is composed of 4 c.c. of anilin oil in 100 c.c. of distilled water. This is shaken in a test-tube and then filtered through a wet filter. The sections are then placed in a solution of iodin and iodid of potassium (iodin 1 gm., iodid of potassium 2 gm., water 300 c.c.) until they have become entirely black, after which they are immersed in alcohol until they receive a violet tinge with a slight dash of brown. By this means the chromatin network, the resting nuclei, and the chromosomes in both of the spirem stages appear bluish-violet, while the true nucleoli are pink. The chromosomes of the aster and diaster are colored red.

Flemming (91, III) recommends the following method: Fixation by his mixture; the specimens or thin sections are then placed in safranin from two to six days, washed for a short time in distilled water, and then immersed in absolute alcohol weakly acidulated with hydrochloric acid (1 : 1000), until no more color is given off. They are then washed again with distilled water and placed in a concentrated solution of anilin-water-gentian-violet from one to three hours. After a third rinsing in distilled water, they come into a concentrated aqueous solution of orange G, until they begin to assume a violet color. Then wash with absolute alcohol, clear in clove or bergamot oil, and mount in Canada balsam.

A comparatively simple method showing the different structures of the cell and its nucleus with great clearness consists in staining with Heidenhain's hematoxylin.

Solger (89, I and 91) has discovered that both chromosomes and polar rays are shown in an exquisite manner in the pigment cells of the skin (corium) of the frontal and ethmoidal regions of the common pike (*vid.* Fig. 37). The preliminary treatment is optional, Flemming's solution or corrosive sublimate being the best. These cells illustrate the stability of the radiate structures of protoplasm, the polar rays showing as parallel rows of pigment granules.

The various structures of resting and dividing nuclei and cells are of such a complicated nature that they can be observed only with great difficulty in ordinary objects, because of the crowding of so many elements into a comparatively small space. For example, salamandra maculosa, which has become a classic histologic object through the researches of Flemming, possesses somatic cells whose nuclei have no less than twenty-four chromosomes. (It may here be remarked that, curiously enough, salamandra atra has only half this number.) Consequently, van Beneden's discovery (83), that the somatic cells of ascaris megalocephala have only four primary chromosomes, is a fact of considerable importance. Boveri (87, II and 88) has even found an ascaris showing only two chromosomes. As these animals also show distinct achromatic figures in the protoplasm of their ova and sperm cells, they are certainly worthy of being regarded as typic specimens for laboratory purposes. The processes of cell-proliferation are almost diagrammatic in their distinctness.

After opening the abdominal wall of the animal, the ovisacs are removed, their numerous convolutions separated as much as possible, and then fixed for twenty-four hours in a picric-acetic acid solution (a concentrated aqueous solution of picric acid diluted with 2 vols. of water to which 1 per cent. glacial acetic acid is added). Then follows washing for twenty-four hours with water, after which the specimen is transferred to increasing strengths of alcohol (Boveri, *ibid.*). Different regions of the ovisacs contain ova in various stages of development, those nearest the head containing cells ripe and ready for fecundation, while in the more posterior regions are ova in varying stages of segmentation showing mitoses. Specimens fixed in the manner above described can be stained with a borax-carmin solution. After staining, the ova are gently pressed out with needles upon a slide, separated, covered with a cover-glass, and cleared by gradual irrigation with glycerin. The ova, especially the segmentation spheres, are very small, and can be examined only under high magnification. In spite of the minuteness of the object and the fact that the yolk does not take the stain, and, on account of



Fig. 37.—Pigment cell from the skin of the head of a pike ; × 650.

its high refractive index, distorts the picture to a considerable extent, the mitotic figures are beautifully distinct.

Certain methods of treatment bring out in both cells and nuclei the presence of peculiar granules. The latter have been especially studied and described by v. Altmann (94, 2d ed.). The methods that he applies are as follows: The specimens of organs of recently killed animals are fixed in a mixture consisting of equal volumes of a 5% aqueous solution of potassium bichromate and a 2% solution of osmic acid, remaining in the mixture for twenty-four hours. They are then washed for several hours in water and treated with ascending strengths of alcohol; viz., 70, 90, and 100%. The specimens are now placed in a solution of 3 parts of xylol and 1 part of absolute alcohol, then in

pure xylol, and finally in paraffin. The tissues imbedded in paraffin must not be cut thicker than 1 to 2 μ.

Altmann mounts according to the following method: A rather thick solution of caoutchouc in chloroform (the so-called traumaticin of the Pharmacopeia—1 vol. guttapercha dissolved in 6 vols. chloroform) is diluted before use with 25 vols. of chloroform and the resulting mixture poured upon a slide. The latter is tilted, and after evaporation of the chloroform, heated over a gas flame. The paraffin sections are mounted upon the slides so prepared and then painted with a solution of guncotton in aceton and alcohol (2 gm. guncotton dissolved in 50 c.c. of aceton, 5 c.c. of which is diluted with 20 c.c. of absolute alcohol). After painting with this solution, the sections are firmly pressed upon the slide with tissue paper, and after drying are made to adhere more closely by slight warming. Fixation to the slide with water is equally good. The sections can now be treated with various staining solutions without becoming detached from the slides. The paraffin is gotten rid of by immersing in xylol, after which the specimens are placed in absolute alcohol. Fuchsin S. can be used as a stain (20 gm. fuchsin S. dissolved in 100 c.c. anilin water). A small quantity of this solution is placed upon the section, and the slide warmed over a flame until its lower surface becomes quite perceptibly warm and the staining solution begins to evaporate. The slide is then allowed to cool, washed with picric acid (concentrated alcoholic solution of picric acid diluted with 2 vols. of water), after which it is covered with a fresh quantity of picric acid, and again, but this time vigorously, heated (one-half to one minute). Occasionally the same results can be obtained by covering the section for five minutes with a cold solution of picric acid of the above strength. This last procedure has a decided influence upon the granula, and gives rise to a distinct differentiation between them and the remaining portions of the cell, the latter appearing grayish-yellow, while the granula themselves appear bright red. In some cases where the granula can not be sharply differentiated from the remaining structures, it may be necessary to repeat the staining process. Xylol-Canada balsam should not be used for mounting, as it has a bleaching effect upon the osmic acid in the specimen. Mount either in liquid paraffin (Altmann) or in undiluted Canada balsam, which is easily reduced to a fluid state, whenever needed, by heating.

There is another method used by Altmann which deserves mention, but practical application of which must be improved upon in the future; this consists in freezing the specimens and drying them for a few days in the frozen condition in a vacuum over sulphuric acid at a temperature of about —30° C.

According to Fischer, dilute solutions of pepton when treated with various reagents (especially with a potassium bichromate-osmium mixture) form precipitates and granules which are remarkable in that they react to stains exactly as do Altmann's granula. It is, therefore, doubtful whether Altmann's granules should be regarded as vital structures.

Altmann (92) has also devised a simpler negative method for demonstrating the granula. Fresh specimens are placed for twenty-four hours in a solution consisting of molybdate of ammonium 2.5 gm., chromic acid 0.35 gm., and water 100 c.c.; then treated for several days with absolute alcohol, sectioned in paraffin, and colored with a nuclear stain such as hematoxylin or gentian. The intergranular network

is colored, while the granula remain colorless. The amount of chromic acid used (0.25 to 1%) varies according to the object treated; if molybdate of ammonium alone be used, the nuclei will appear homogeneous, while if an excess of chromic acid be employed, the nuclei will appear coarsely reticulated. This method leads to the formation of granula in the cells as well as in the nucleus.

Bütschli's Foam-structure.—Fixing is done either in picric acid solution or in weakly iodized alcohol. The specimens are then stained with iron-hematoxylin—*i. e.*, first treated with acetate of iron, rinsed in water, and transferred to a 0.5% aqueous solution of hematoxylin (similar to the method of R. Heidenhain). Very thin sections are required (½ to 1 μ). Mounting is done, when the lighting is good, in media having low refractive indices, which emphasize the alveolar or foam-like structure of the protoplasm. Of various animal objects, Bütschli especially recommends young ovarian eggs of teleosts, and blood-cells and intestinal epithelium of the frog, etc. It is still a matter of uncertainty whether or not the structures are actually present in living protoplasm.

II. THE TISSUES.

The first few generations of cells which result from the segmentation of the fertilized ovum have no pronounced characteristics. They are embryonic cells of rounded form, and are known as *blastomeres.* As they increase in number they become smaller and of polygonal shape, owing to the pressure to which they are subjected. From the mass of blastomeres, known as the *morula mass*, there are formed, under various processes described under the name of *gastrulation*, two layers of cells, the so-called *primary germ layers*, of which the outer is the *ectoderm*, the inner the *entoderm.* To the primary germ layers is added still a third layer, called the *mesoderm;* it is derived from both the ectoderm and entoderm, but principally from the latter. From these three layers of cells, known as the *primary blastodermic layers*, are developed all the tissues, each layer developing into certain tissues that are distinct for this layer. In their further development and differentiation the cells of the blastodermic layers undergo a change in shape and structure characteristic for each tissue, and there is developed an *intercellular substance* varying greatly in amount and character in the several tissues. In the tissues developed from the ectoderm and entoderm the cellular elements give character to the tissue, while the intercellular substance is present in small quantity; in the majority of the tissues developed from the mesoderm, the intercellular substance is abundant, while the cellular elements form a less conspicuous portion.

The tissues derived from the **ectoderm** are:

The epidermis of the skin, with the epidermal appendages and glands; the epithelium lining the mouth, with the salivary glands and the enamel of the teeth; the epithelium and glands of the nasal tract and the cavities opening into it; the lens of the eye and retina,

and the epithelium of the membranous labyrinth of the ear ; and finally, the entire nervous system, central and peripheral.

From the **entoderm :**

The epithelium lining the digestive tract, and all glands in connection with it, including the liver and pancreas ; the epithelium of the respiratory tract and its glands ; the epithelium of the bladder and urethra (in the male, only the prostatic portion, the remainder being of ectodermal origin).

The cells of the **mesoderm** are early differentiated into three groups (Minot, 99) :

(a) *Mesothelium.*—The mesothelial cells retain the character of epithelial cells. They form the lining of the pleural, pericardial, and peritoneal cavities, and give origin to the epithelium of the urogenital organs (with the exception of the bladder and urethra), and striated and heart muscle tissue.

(b) *Mesenchyme*, from which are derived all the fibrous connective tissues, cartilage, and bone, involuntary muscle tissue, the spleen, lymph-glands, and bone-marrow ; and cells of an epithelioid character, lining the blood and lymph-vessels and lymph-spaces, known as *endothelial cells.*

(c) *Mesameboid cells*, comprising all red and white blood-cells.

It would be extremely difficult to attempt a classification of tissues according to their histogenesis, as identical tissue elements owe their origin to different germinal layers. The classification adopted by us is based rather on the structure of the tissues in their adult stage.

We distinguish :

A. Epithelial tissues with their derivatives.

B. Connective tissues ; adipose tissue ; supporting tissues (cartilage, bone).

C. Muscular tissue.

D. Nervous tissue.

E. Blood and lymph.

A. EPITHELIAL TISSUES.

Epithelial tissues are nonvascular, and composed almost wholly of epithelial cells, united into continuous membranes by a substance known as intercellular cement. They serve to protect exposed surfaces, and perform the functions of absorption, secretion, and excretion.

The epithelia are developed from all of the three layers of the blastoderm.

They secrete the cement-substance found between their contiguous surfaces. This takes the form of thin lamellæ between the cells, gluing them firmly together. In certain regions the epithelial cells develop short lateral processes (prickles), which meet like structures

from neighboring cells, thus forming *intercellular bridges.* Between these bridges are *intercellular spaces* filled with lymph-plasma for the nourishment of the cells. Epithelia do not, as a rule, possess processes of any length. However, it would appear that the *basement membranes,* situated beneath the epithelia, consist chiefly of processes from the basal portion of the cells. Some authors ascribe to them a connective-tissue origin, a theory which conflicts with the fact that such membranes are present in the embryo before connective tissue, as such, has been developed (*membrana prima*, Hensen, 76).

The free surfaces of epithelia often support *cuticular structures* which are to be regarded as the products of the cells. The cuticulæ of neighboring cells fuse to form a *cuticular membrane* or *marginal zone* which can be detached in pieces of considerable size (cuticula). In longitudinal sections the cuticula show, in many cases, a striation which would seem to indicate that they are composed of a large number of rod-like processes cemented together by a substance possessing a different refractive index. The cell-body is also striated for more than half its length, corresponding to the rods of the marginal zone. In the region of the nucleus at the basal portion the striation disappears, the cell here consisting of granular protoplasm of a more indifferent character.

Since one surface of each epithelial layer lies free, and is consequently exposed to other conditions than the inner surface, certain differences are noticed between the two ends of each cell. The cells may develop cuticular structures as above stated. In other cases motile processes (cilia) are developed on their exposed surface, which move in a definite direction in the medium surrounding them, and by means of this motion sweep away foreign bodies. It is not strange that the free surface of the epithelia, exposed as it is to stimulation from without, should develop special structures for the reception of sensations (sense cells).

On the other hand, the inner or basal surfaces of the cells usually retain a more indifferent character, and serve for the attachment of the cells and the conveyance of their nourishment. For this reason the nuclei of such cells are usually situated near the basal surface.

From the above it is seen that the two ends of the epithelial cell undergo varying processes of differentiation, the outer being adapted more to the animal, the inner more to the vegetative functions. This differentiation has recently been known as the *polarity* of the cell. This polarity appears to be retained even when the cell loses its epithelial character and assumes other functions (Rabl, 90).

With few exceptions, blood- and lymph-vessels do not penetrate into the epithelia, but the latter are richly supplied with nerves. The finer morphology of the epithelia will be described in the chapters on the different organs in Part II.

Epithelia are classified according to the shape and relation of the epithelial cells.

We give the following classification :

1. Simple epithelia (with or without cilia).
   - (*a*) Squamous epithelium.
   - (*b*) Cubic epithelium.
   - (*c*) Columnar epithelium.
   - (*d*) Pseudostratified columnar epithelium.
2. Stratified epithelia (with or without cilia).
   - (*a*) Stratified squamous epithelium, with superficial flattened cells (without cilia).
   - (*b*) Transitional epithelium.
   - (*c*) Stratified columnar epithelium, with superficial columnar cells (with or without cilia).
3. Glandular epithelium.
4. Neuro-epithelium.

1. SIMPLE EPITHELIUM.

In simple epithelia the cells lie in a single continuous layer.

Simple epithelia are very widely distributed. They line almost the entire alimentary tract, the smaller respiratory passages and air

Fig. 38.—Isolated cells of squamous epithelium (surface cells of the stratified squamous epithelium lining the mouth): *a*, *a*, Cells presenting under surface ; *b*, cell with two nuclei.

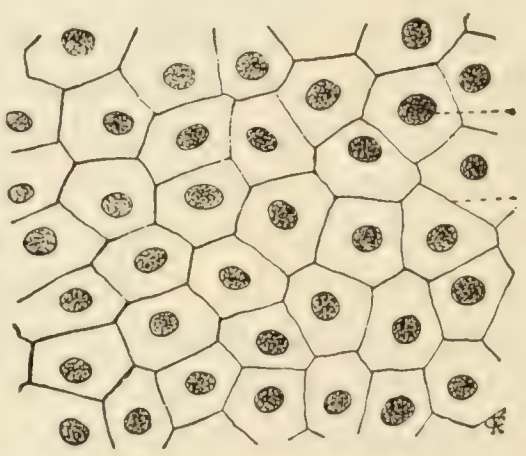

Fig. 39.—Surface view of squamous epithelium from skin of a frog; × 400.

sacs, the majority of the gland ducts, the oviducts and uterus, and the central canal of the spinal cord and ventricles of the brain.

(*a*) **Simple Squamous Epithelium.**—In simple squamous epithelium the cells are flattened. Their contiguous surfaces appear regular, forming, when seen from above, a mosaic. The nuclei lie, as a rule, in the middle of the cell, and if the latter be very much flattened, the position of the nucleus is made prominent by a bulging of the cell at this point. It occurs in the alveoli of the lung.

(*b*) **Simple Cubic Epithelium.**—Epithelial cells of this type differ from the above only in that they are somewhat higher. They appear as short polygonal prisms. Their outlines are, as a rule, not irregular, but form straight lines. Cubic epithelium occurs in the

smaller and smallest bronchioles of the lungs, in certain portions of the uriniferous tubules and their collecting ducts, in the smaller ducts of salivary and mucous glands, liver, pancreas, etc.

(*c*) **Simple Columnar Epithelium.**—In this type the cells take the form of prisms or pyramids of varying length. Cuticular structures are especially well developed. Columnar epithelium occurs in the entire intestinal tract from the cardiac end of the stomach to the anus, in certain portions of the kidney, etc.

Fig. 40.—Simple columnar epithelium from the small intestine of man : *a*, Isolated cells ; *b*, surface view ; *c*, longitudinal section.

Simple ciliated columnar epithelium is found in the oviduct and uterus, central canal of the spinal cord, and smaller bronchi.

(*d*) **Pseudostratified Columnar Epithelium.**—This type is one in which all the cells rest on a basement membrane, but they are so placed that the nuclei come to lie in different planes. Thus, in a longitudinal section the nuclei are seen to be placed in several rows.

Fig. 41.—Diagram of pseudostratified columnar epithelium.

The development of this type from the simpler forms occurs when the cells are too crowded to retain their normal breadth. As a result, they become pyramidal, alternate cells resting their bases or apices on the basement membrane. As the nucleus is usually situated at the broader portion of the cell, the result is that there are two rows of nuclei simulating a stratified epithelium. Occasionally there are spindle-shaped cells wedged in between the pyramidal cells, and as the broad portion of these cells is midway between the basement membrane and external surface, a third row of nuclei is seen midway between the other two. Such epithelia usually possess cilia (portions of the respiratory passages).

2. STRATIFIED EPITHELIUM.

Should the increase of the cells forming the last type of simple epithelium proceed to such an extent that all the cells no longer rest on the basement membrane, an epithelium is formed having dis-

tinct layers of cells—a stratified epithelium. It is clear that all the cells of a stratified epithelium can not be equally well nourished by the blood-supply from the vessels in the highly vascular connective tissue beneath. The middle and outer layers of cells accordingly suffer. The deeper layers are much better nourished, and as a consequence their cells increase much more rapidly than those above; they push outward, replacing the superficial cells as fast as they die or are thrown off. The proliferation of cells in a stratified epithelium occurs, therefore, chiefly in its basal layers.

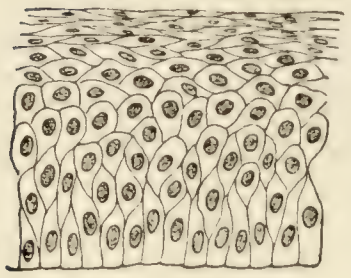

Fig. 42.—Schematic diagram of stratified pavement epithelium.

(*a*) **Stratified Squamous Epithelium.**—Stratified squamous epithelium with superficial flattened cells forms the epidermis with its continuations into the body, as, for instance, the walls of the oral cavity and the esophagus, the epithelium of the conjunctiva, the vagina, the external auditory canal, and the external sheath of the hair follicles.

The cells of the basal layer are here mostly cubic-cylindric. Then follow, according to the situation of the epithelium, one or more layers of polyhedral cells, which become gradually flattened toward the surface, the outermost layers consisting of thin plate-like cells.

In stratified squamous epithelia, where the outer cells become horny (as in the skin), the stratification is still more specialized. Here layers are inserted in which the horny or chitinous substance is gradually formed, although the cells do not become chitinous until the superficial layers are reached.

Especially characteristic of stratified squamous epithelium is the arrangement of the connective tissue on which this epithelium rests. There are cone-like projections, known as *papillæ*, arising from the connective tissue beneath the epithelium, projecting into the latter in such a way that on cross-section the junction of the two tissues appears as a wave-like line. These papillæ not only serve to fasten the epithelium more firmly to the connective tissue below, but influence very favorably the nourishment of the former by allowing a greater number of its basal cells to approximate the under-

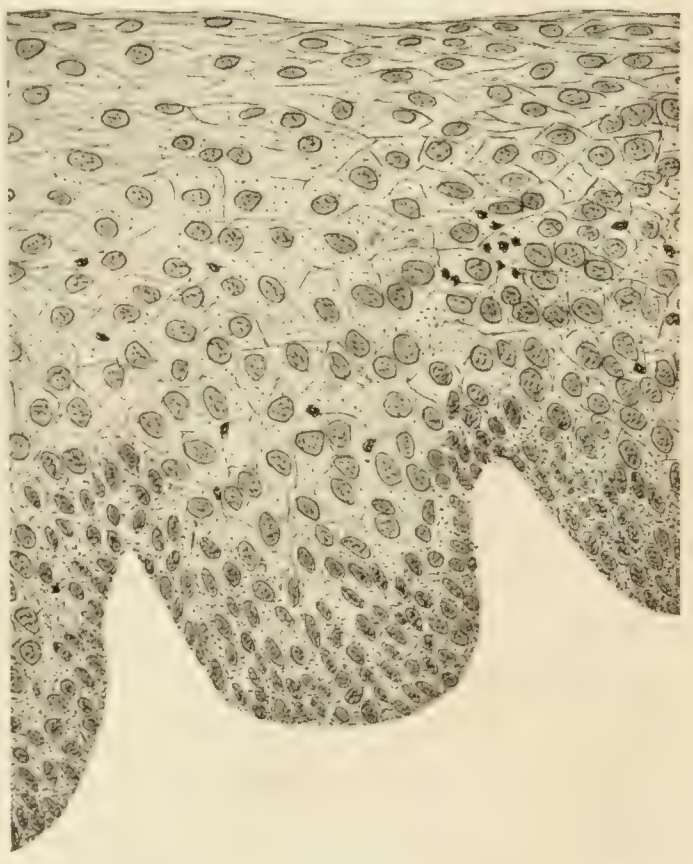

Fig. 43.—Cross-section of stratified squamous epithelium from the esophagus of man.

lying blood-capillaries. The pyramidal extensions of the epithelium between the papillæ are designated *interpapillary epithelial processes.* In regions where the stratified squamous epithelium consists of many layers, the prickle cells, intercellular bridges, and the intercellular spaces are especially well developed. These spaces facilitate the passage of the lymph-plasma to the more superficial layers of cells.

(*b*) **Transitional Epithelium.**—Transitional epithelium is a stratified epithelium occurring in the pelvis of the kidney, the ureters, bladder, and the posterior portion of the male urethra. It is composed of four to six layers of cells and rests on a connective tissue free from papillæ. In sections the cells of the deeper layers appear to be of irregularly columnar, cubic or triangular shape. The

Fig. 44.—Isolated transitional epithelial cells from the bladder of man : *a*, *b*, *c*, *d*, Large surface cells, *c* and *d* presenting the pitted undersurface ; *e*, variously shaped cells from the deeper layers.

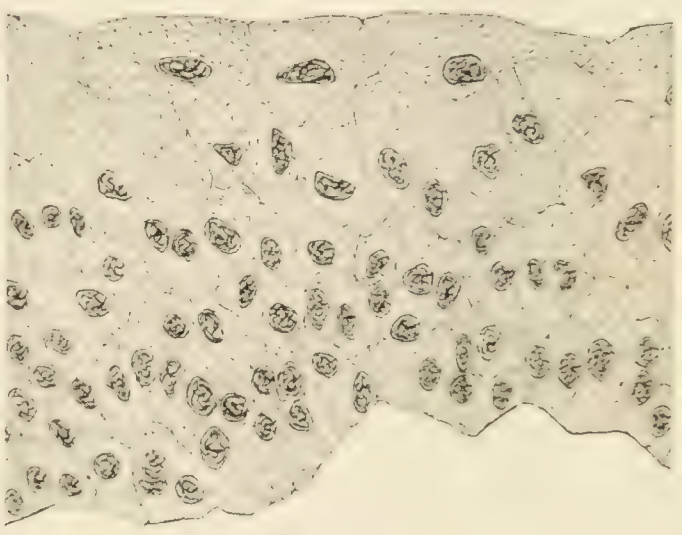

Fig. 45.—Cross-section of transitional epithelium from the bladder of a young child.

cells forming the superficial layer are large, somewhat flattened cells, with convex free surfaces, often possessing two, sometimes three, nuclei. They cover a number of the cells of the layer just beneath them, their under surfaces being pitted to receive the upper ends of the deeper cells. In teased preparations the cells of the deeper layers appear very irregular, often showing ridges or variously shaped processes. (See Fig. 44.)

(*c*) **Stratified Columnar Epithelium.**—In this type the superficial layer consists of columnar cells, the basal ends of which are usually somewhat pointed, or may branch. The deeper cells, which may be arranged in one or more layers, are of irregular, triangular, polyhedral, or spindle shape. It is found in the larger gland ducts, olfactory mucous membrane, palpebral conjunctiva, portions of the

male urethra and the vas deferens, and in certain regions of the larynx.

The ciliated variety of this epithelium differs from the foregoing in that the superficial columnar cells are provided with cilia. Stratified ciliated columnar epithelium is found in the respiratory portion

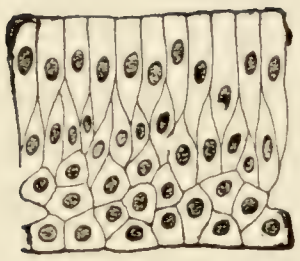

Fig. 46. — Schematic diagram of stratified columnar epithelium.

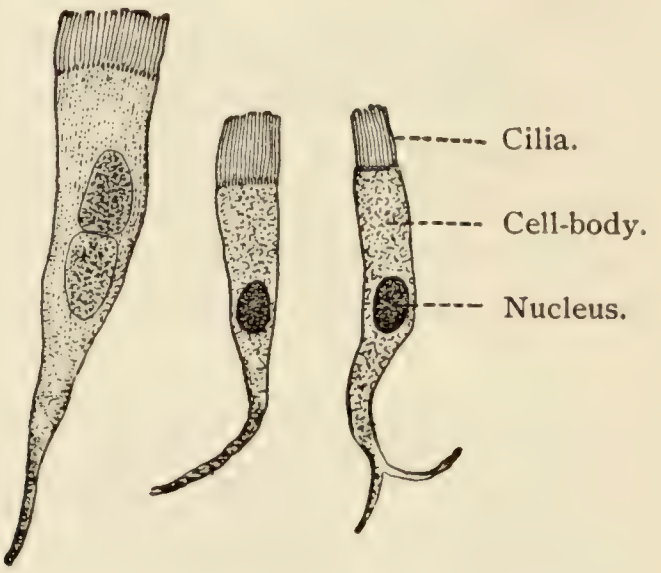

Fig. 47.—Ciliated cells from the bronchus of the dog, the left cell with two nuclei; × 600. Technic No. 126.

of the nose, larynx, trachea, and larger bronchi, in the Eustachian tube, epididymis, and a portion of the vas deferens.

All epithelial cells are probably joined together by short processes forming intercellular bridges, the lymph supplying them with nourishment circulating in the intercellular spaces thus formed. Toward the surface, these intercellular spaces are roofed over, thus preventing the escape of the fluid. When seen from the surface, epithelia treated by certain methods (iron-hematoxylin) show the cells joined together by very minute, clearly defined and continuous

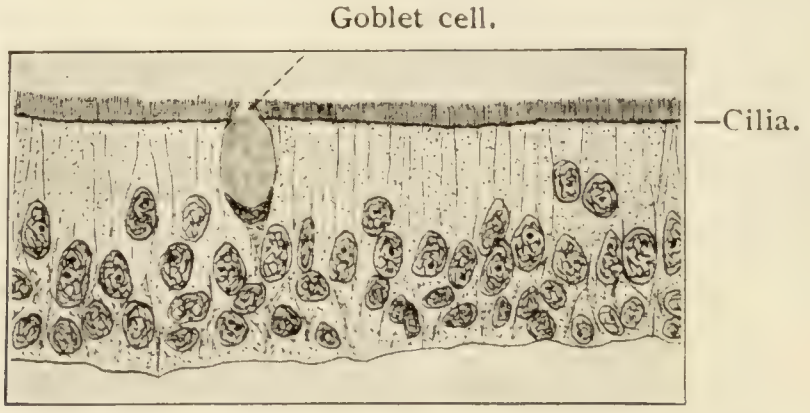

Fig. 48.—Cross-section of stratified ciliated columnar epithelium from the trachea of a rabbit.

cement-lines. Bonnet has called them *terminal ledges* or *bars* (Schlussleisten). The function of this structure would seem to consist in its power to prevent the escape of lymph from the surface, and the penetration of micro-organisms (M. Heidenhain, 92; Bonnet, 95).

3. GLANDULAR EPITHELIUM.

Glandular epithelium is composed of epithelial cells differentiated so as to possess the power of elaborating certain compounds or substances which are finally given off from the cells in the form of secretions. Those substances which form the essential constituents of such secretions appear in the protoplasm of the majority of glandular cells, in the intervals of secretory activity, in the form of smaller and larger granules which may be discharged from the cells in granular form or may be changed into homogeneous, viscid substances before leaving or on leaving the cells. Glandular epithelium appears in the form of isolated glandular cells, scattered here and there among other epithelial cells, in certain types of epithelium, or as smaller or larger aggregations of glandular cells, possessing definite and typical arrangement and associated with

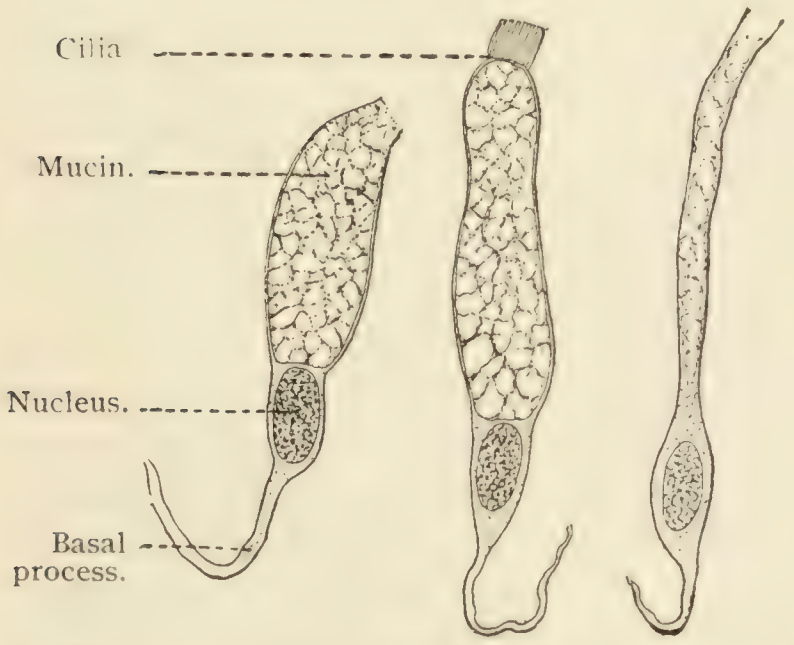

Fig. 49.—Goblet cells from the bronchus of a dog. The middle cell still possesses its cilia; that to the right has already emptied its mucous contents (collapsed goblet cell); × 600.

Fig. 50.—A mucus-secreting cell (goblet cell), showing secretory granules, situated between two epithelial cells. From the epithelium of the large intestine of man.

other tissues—connective tissue, blood- and lymph-vessels, nerve tissue—to form structures or organs known as secreting glands.

Unicellular Glands.—Isolated glandular cells, which we may know as unicellular glands, are frequently met with in the epithelium of the intestinal canal and respiratory organs, where, owing to their shape, they are known as goblet cells, or, again, as mucus secreting cells, since their secretion is mucus. Such cells are in the ordinary preparation distinguished from the neighboring cells by the fact that their free ends appear clearer and are more vesicular, while their basal portions, containing the nuclei, are narrow and pointed. Closer examination generally reveals a fine protoplasmic network in the clear portion of the cell, the interspaces of which are filled with the mucus. (See Fig. 49.)

The secretion is, however, elaborated in the cell-protoplasm in

the form of rather coarse granules, which may be as large as 1 ½ μ to 2 μ. These granules are found in a hyaline substance, from which they are probably formed, which substance is found in the interspaces of a protoplasmic network with relatively wide meshes (Langley). The granules as they develop and enlarge distend the free portions of the cells. They are eventually extruded from the cells, probably in the form of granules, as granules identical with those found in the cells are found in the lumina of intestinal glands in well-fixed material. After the extrusion of the secretion the cell collapses, and may again assume a secretory function by the elaboration of new granules. (See Fig. 50.)

Multicellular glands originate by the metamorphosis of a number of adjacent cells into glandular cells. This is usually accompanied by a more or less marked dipping down of the epithelial layer into the underlying connective tissue. The glandular cells are generally arranged in a single layer, and rest on a delicate membrane, known as the basement membrane (membrana propria); outside of this there is found fibrous connective tissue, containing the terminal ramifications of capillaries and lymph-spaces and of nerve-fibers. The simplest form of such an invagination is a cylindrical tube or a small sac (known as an alveolus) lined entirely by glandular cells. A further differentiation may take place in that all the invaginated cells do not assume a secretory function, those at the upper portion of the tube or sac forming the lining membrane of an *excretory duct*. The originally uniform tube or sac is thus differentiated into a duct and a secretory portion. Multicellular glands may lie entirely within the epithelium, and are then known as intra-epithelial glands, in contrast to the extra-epithelial or ordinary type, the greater part of which lies imbedded in the underlying connective tissue. Glands of the former type have been studied in amphibian larvæ, and, according to Sigmund Mayer, occur also in the epididymis, conjunctiva, etc., of mammals.

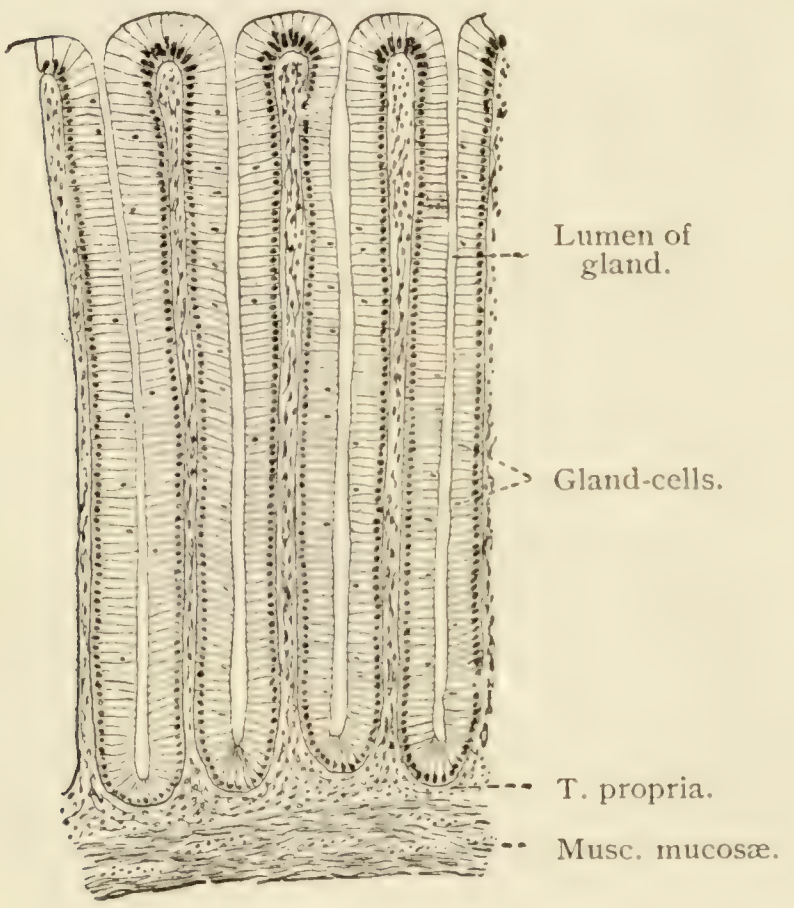

Fig. 51.—Simple tubular glands. Lieberkühn's glands from the large intestine of man. Sublimate fixation; × 90.

General Consideration of the Structure and Classification of Glands.—Since glandular tissue is composed almost wholly of epithelial cells, it may not be out of place to consider at this time

the classification of glands. The fuller consideration of these structures will, however, be deferred to a later time. In the classification here given we have been guided by that presented by Maziarski, in an observation on the structure and classification of glands, based on a series of reconstructions with the Born wax-plate method and comprising nearly all the important glandular structures of the human body. In brief, it may be stated that the variation in glandular types affects principally the secretory portions of glands, while the excretory ducts are more or less uniform. Glands are classified, according to their shape, into tubular and alveolar glands; each of these types is further divided into simple and branched tubular, and simple and branched alveolar glands. In certain glands tubules and alveoli unite to form the secretory

Fig. 52.—Excretory ducts and lumina of the secretory portion of a componnd tubular gland. Lingual gland of the rabbit. Chrome-silver preparation; × 215.

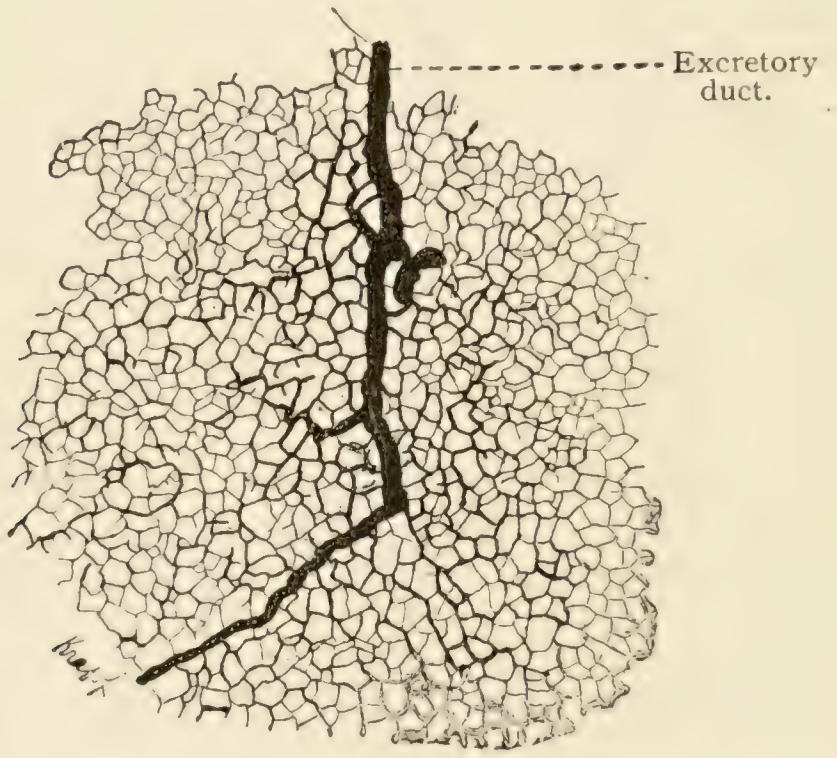

Fig. 53.—Lumina of the secreting portion of a reticulated tubular gland; from the human liver. Chrome-silver preparation; × 120.

portion; such glands are known as tubulo-alveolar glands. They may also be simple or branched.

Tubular Glands.—In a tubular gland the secreting portion consists of a longer or shorter tubule, which may be relatively straight or variously twisted or coiled, one end of which ends blindly while the other end opens on a free surface or into a duct. The blind ends of the tubules of tubular glands often present more or less well-marked enlargements. Simple tubular glands consist of a single tubule, which may be lined throughout by secretory epithelium or may be differentiated into a portion lined by secretory epithelium and a portion lined by a non-secretory epithelium forming a duct. An increase of the secretory surface of tubular glands is obtained in one of the following ways:

1. *Coiled Tubular Gland.*—The secreting portion of the tubule may be coiled up into a compact mass;

2. *Simple Branched Tubular Glands.*—Several tubules, which may be either branched or unbranched, and which may vary greatly in length, may unite in one duct, which carries to the surface the secretion of all the tubules connected with it;

3. *Compound Branched Tubular Glands.*—Glands of this type consist of a varying number of simple branched tubular glands, the ducts of which unite to form a common duct (Fig. 52);

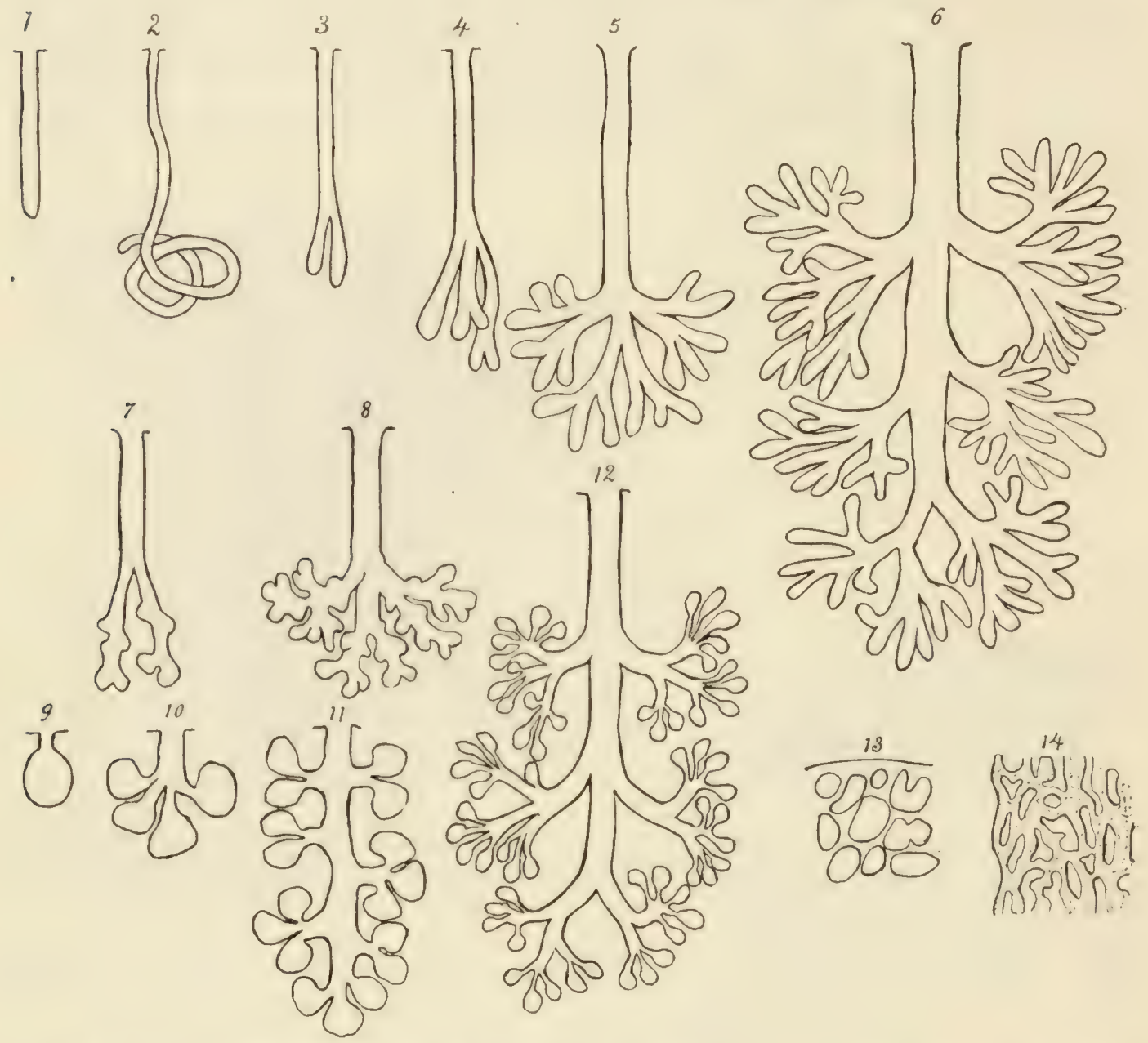

Fig. 54.—Schematic diagram of glandular classification: 1, Simple tubular gland; 2, simple tubular gland with coiled secreting portion; 3, 4, 5, types of simple branched tubular glands; 6, compound branched tubular gland; 7, 8, types of simple branched tubulo-alveolar glands; 9, simple alveolar gland; 10, 11, types of simple branched alveolar glands; 12, compound branched alveolar gland; 13, type of follicular gland; 14, reticular gland, the shaded portions representing anastomosing tubules.

4. *Reticulated Tubular Glands.*—In certain of the branched tubular glands the secreting tubules anastomose with each other, forming a *reticulated gland* (Fig. 53);

5. *Tubulo-alveolar Gland.*—The secreting surface of tubular glands may be further increased by the formation of small and variously shaped protuberances or saccules, known as alveoli, which may be situated at the end or on the sides of the tubules, and are lined by secretory epithelium and empty the secretion

formed in them into the tubules with which they are connected. We have thus, in addition to the several types of tubular glands above mentioned: Simple tubulo-alveolar glands, simple branched tubulo-alveolar glands, and compound branched tubulo-alveolar glands.

Alveolar Glands.—In the alveolar glands the secreting compartments have the form of variously shaped vesicles or saccules, known as alveoli, lined by secretory epithelium, which communicate with narrow tubules of varying length and lined by non-secretory epithelium, which form the ducts. Alveolar glands are classified as:

1. *Simple alveolar glands*, consisting of a single alveolus which communicates with the surface by means of a narrow duct.

2. *Simple Branched Alveolar Glands.*—In this type a varying number of alveoli are united through their respective ducts to a larger duct which reaches the surface.

3. *Compound Branched Alveolar Glands.*—Glands of this type consist of a varying number of simple branched alveolar glands united by a common duct.

4. *Follicular Glands.*—Glands of this type may be classed under alveolar glands, since they consist of numerous closed alveoli or follicles, of round, oval, or even irregular shape, which do not communicate with a duct system.

The main features of this classification of glands are portrayed in the accompanying diagram (Fig. 54).

According to the above description multicellular glands may be classified as follows:

Tubular glands.

1. Simple tubular glands: crypts of Lieberkühn, the majority of the sweat glands.
2. Simple branched tubular glands: fundus glands of stomach, the majority of the pyloric glands, uterine glands.
3. Compound branched tubular glands: kidneys, testis, lachrymal glands, serous glands of mucous membranes.
4. Reticulated tubular glands: Liver (fully developed in mammals).

Tubulo-alveolar glands.

1. Simple tubulo-alveolar glands: certain of the pyloric glands.
2. Simple branched tubulo-alveolar glands: Littré's glands, certain of the sweat glands, and modified sweat glands (circumanal and axillary glands, ceruminous glands, ciliary glands).
3. Compound branched tubulo-alveolar glands: many mucous glands, Brunner's glands, prostate, lung.

Alveolar glands.

1. Simple alveolar glands: the smallest sebaceous glands, the skin glands of amphibia.
2. Simple branched alveolar glands: sebaceous glands, Meibomian glands.
3. Compound branched alveolar glands: pancreas, mammary gland, serous salivary glands—in the latter, however, a portion of the duct system possesses secretory function (Maziarski).
4. Follicular glands: ovary, hypophysis, thyroid (according to Streiff, certain of the closed follicles of the thyroid have a tubular form, others show secondary alveolar enlargements on the primary follicles).

The secretory epithelium of the various types of glands rests upon a thin membrane (membrana propria), which has, according to some authors, a connective-tissue origin, while, according to others, it is the product of the glandular cells themselves. In some cases it appears structureless, in others a cellular structure can be distinguished; in the latter case the cells are flattened, with very much flattened nuclei, and show irregular outlines. Macroscopically, compound glands present a more or less lobular structure, the separate lobules being held together by connective tissue. In the immediate neighborhood of the gland and its larger lobes, the connective tissue is thickened to form the so-called *tunica albuginea* or capsule. In this fibrous-tissue sheath are found numerous blood-vessels which penetrate between the lobes and lobules of the gland and form a dense capillary network about the tubules and alveoli immediately beneath the membrana propria. Nerve-fibers are also plentiful.

Remarks on the Process of Secretion.—The gland-cell varies in its microscopic appearance according to its functional condition. In the great majority of the glandular epithelial cells the essential constituents of the secretion are stored in the cell in the form of secretory granules, in others in vacuoles which are filled with the secretion. The secretory process varies. In one case the cell remains intact throughout the process (salivary glands); in another a portion of each cell is used up in the production of the secretion, only the basal portion containing the nucleus being preserved. When this occurs, the upper part of the cell is reconstructed from the remaining basal portion, and the cell is ready to renew the process (mammary glands). In a third type the whole cell is destroyed, and is replaced by an entirely new cell (sebaceous glands).

4. NEURO-EPITHELIUM.

In certain of the organs of special sense (inner ear and taste-buds) the epithelial cells about which the nerves terminate undergo a high degree of specialization. This differentiation is more apparent in the outer portions of these cells, resulting in the formation of one or several stiff, hair-like processes, which appear especially receptive to stimuli. Such cells are known as *neuro-epithelial cells.* In the epithelia in which they occur they are surrounded by supporting or *sustentacular cells.*

5. MESOTHELIUM AND ENDOTHELIUM.

The pleural, pericardial, and peritoneal cavities are lined by a single layer of flattened epithelioid cells which develop from the mesothelium lining the primitive body cavity (celom). For this reason, as has been suggested by Minot (90), the term mesothelium may with propriety be applied to this layer in its developed condi-

tion. In silver nitrate preparations, in which the boundaries of these cells are brought to view, they appear as much flattened cells, resembling those of squamous epithelium, with faintly granular protoplasm, possessing flattened, oval, or nearly round nuclei. These cells are of polyhedral shape, and appear to be united into a single layer by a small amount of intercellular cement substance. The borders of these cells may be quite regular or slightly wavy (Fig. 55); more often they are serrated (Figs. 56, 57). According to Kolossow, who has investigated these cells by means of special methods devised by him, the mesothelial cells are said to be made

Fig. 55.—Mesothelium from pericardium of rabbit. Silver nitrate preparation, stained in hematoxylin.

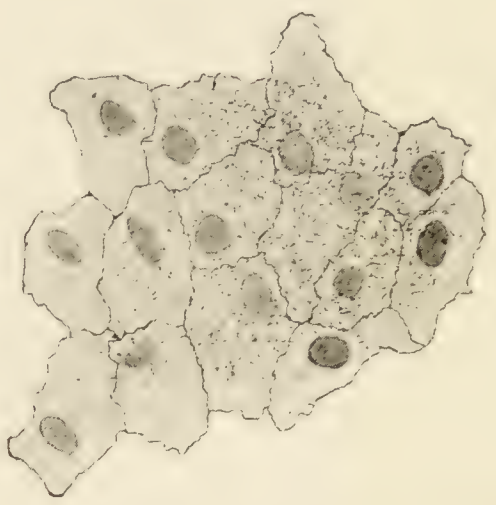

Fig. 56.—Mesothelium from mesentery of rabbit.

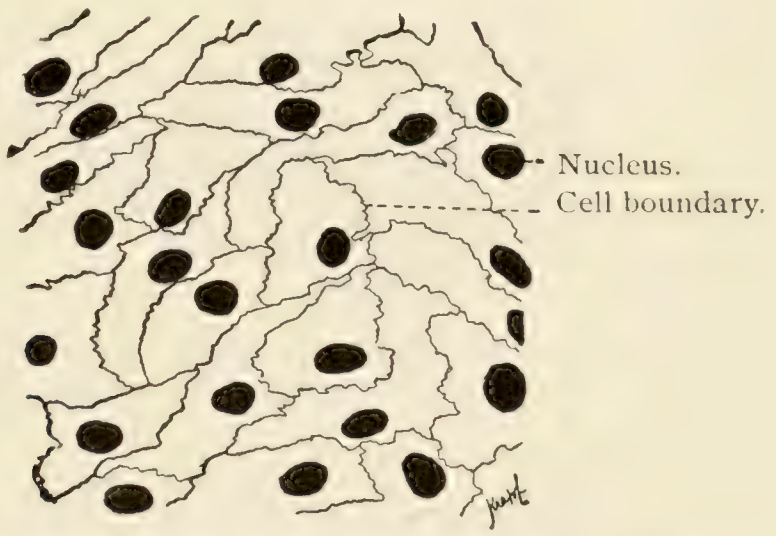

Fig. 57.—Mesothelium from peritoneum of frog; × 400.

up of two quite distinct portions: a superficial, homogeneous cell-plate, beneath which is found a finely granular protoplasm containing the nucleus. These two portions are intimately united to form a single cell. The outlines of the superficial cell-plates are figured in the accompanying illustrations. The protoplasmic position of one cell unites with that of contiguous cells by means of protoplasmic branches, between which are found intercellular spaces. These intercellular spaces are here and there indicated in silver nitrate preparations, forming what are known as stigmata and stomata, which are looked upon by certain writers as representing

openings between the mesothelials cells through which fluids and solid particles may pass into underlying lymph spaces. They are, however, now generally regarded as artifacts.

Endothelial cells are differentiated mesenchymal cells. They line the blood- and lymph-vessels and lymph-spaces (arachnoidal and

Fig. 58.—Mesothelium covering posterior abdominal wall of frog. Stained with silver nitrate and hematoxylin.



Fig. 59.—Endothelial cells from small artery of the mesentery of a rabbit. Stained with silver nitrate and hematoxylin.

synovial spaces, anterior chamber of the eye, bursæ, and tendon sheaths). Endothelial cells are in structure like those of the mesothelium. In blood- and lymph-vessels they are of irregular, oblong shape, with serrated borders. The boundaries of these cells are clearly brought out by silver nitrate.

TECHNIC.

Epithelium may be examined in a fresh condition. The simplest method consists in placing some saliva under a cover-glass and examining it with a moderate power. In it will be found a number of isolated squamous epithelial cells, suspended in the saliva singly and in groups. The cells that are cornified still show the nucleus and a small granular area of protoplasm.

In order to examine **isolated epithelial cells** of organs, it is necessary to treat the epithelial shreds or whole epithelial layers with the so-called isolating or maceration fluids. These are: (1) Iodized serum; (2) very dilute osmic acid (0.1% to 0.5%); (3) very weak chromic acid solution (about 1:5000 of water); (4) 0.5% or 1% solution of ammonium or potassium bichromate; and, above all, the one-third alcohol recommended by Ranvier (28 vols. absolute alcohol, 72 vols. distilled water). The mixture recommended by Soulier (91), consisting of sulphocyanid of potassium or ammonium, and the mixture of Ripart and Petit serve the same purpose. All these solutions are used by allowing a quantity of the isolation fluid to act upon a small fresh piece of epithelium for from twelve to twenty-four hours, according to the temperature of the medium and quality of the tissue. As soon as the isolation fluid has done its work, it is easy to complete the isolation of the cells by shaking the specimen or teasing it with needles. Separation of the elements may be accomplished either in the isolation solution itself or in a so-called indifferent fluid, or in gum-glycerin. The macerated preparation may be stained in a hematoxylin or carmin solution before teasing and mounting in gum-glycerin.

The movement of **the cilia** can be observed in mammalian tissues by scraping the epithelium from the trachea with a scalpel and examining it in an indifferent fluid. As the ciliated epithelium of mammals is very delicate and sensitive, specimens with a longer duration of ciliary movement are more desirable. They can be obtained by using the mucous membrane from the palate of a frog (examine in normal salt solution). Particularly large epithelial cells, as well as very long cilia, are found on the gill-plates of mussels or oysters.

In order to study **the relations of mesothelial and endothelial cells,** the silver method is the most satisfactory. The outlines of the mesothelial cells may be clearly brought out by placing pieces of the pericardium, central tendon of the diaphragm, or the mesentery in a 0.75% to 1% solution of silver nitrate. Before placing in this solution, they should be rinsed in distilled water in order to remove any adherent foreign bodies, such as blood-corpuscles, etc. In this solution they remain until opaque, which occurs in from ten to fifteen minutes. They are then again rinsed with distilled water, in which they are exposed to sunlight until they begin to assume a brownish-red color. Once again they are washed with distilled water, and either placed in glycerin, in which they may be mounted, or dehydrated and mounted in Canada balsam, according to the usual methods. The margins of the cells subjected to this treatment will appear black.

Endothelial cells may be demonstrated after the following method: A small mammal (rat, Guinea-pig, rabbit, or cat) is narcotized. Before the heart's action is completely arrested, the thorax is opened and the heart incised. As soon as the blood stops flowing, a cannula is inserted and tied in the thoracic aorta a short distance above the diaphragm, and 50 to 80 c.c. of a 1% aqueous solution of silver nitrate injected through the cannula. About fifteen minutes after the injection of the silver nitrate solution, there is injected through the same cannula 100 to 150 c.c. of a 4% solution of formalin (formalin 10 parts, distilled water 90 parts). The abdominal cavity is then opened, loops of the intestine with the attached mesentery removed and placed in a 4% solution of formalin, in which the tissue is exposed to the sunlight. As soon as the reduction of

the silver nitrate has taken place, which is easily recognized by the reddish-brown color assumed by the tissues, the mesentery is divided into small pieces, dehydrated first in 95%, then in absolute alcohol, cleared in oil of bergamot, and mounted in balsam. As a rule, the mesothelial cells covering the two surfaces of the mesentery, and the endothelial cells lining the arteries, veins, and capillaries are clearly outlined by the reduced silver nitrate.

If desired, the tissue may be further stained in hematoxylin (we have used Böhmer's hematoxylin solution) or in a carmin solution after dehydration in 95% alcohol, after which they are dehydrated, cleared, and mounted in balsam. In preparations made after this method the endothelial cells are outlined by fine lines of dark brown or black color.

Silver nitrate may also be dissolved in a 2% to 3% solution of nitric acid, in osmic acid, and various other fluids. Stratified epithelia can also be impregnated with silver nitrate, but only after prolonged immersion. They are exposed to sunlight after sectioning on the freezing microtome, or after hardening and imbedding, followed by sectioning. After the reduction of the silver the sections are dehydrated and mounted in balsam.

Kolossow has devised the following excellent method for demonstrating **intercellular bridges:** Fine membranes, or even minute fragments of previously fixed tissues, are placed for about a quarter of an hour in a 0.5% to 1% osmic acid (or in a mixture composed of 50 c.c. absolute alcohol, 50 c.c. distilled water, 2 c.c. concentrated nitric acid, and 1 to 2 gm. osmic acid) and then into a 10% aqueous solution of tannin for five minutes, or into a developer consisting of the following: water, 450 c.c.; 85% alcohol, 100 c.c.; glycerin, 50 c.c.; purified tannin, 30 gm., and pyrogallic acid, 30 gm. In the latter case they are subsequently rinsed in a weak solution of osmic acid, washed with distilled water, and then carried over into alcohol.

There are, of course, special methods of fixing and subsequently examining epithelial structures; these, and the methods of examining gland tissue, will be discussed in the chapters devoted to the various organs.

B. THE CONNECTIVE TISSUES.

In the connective tissues, the intercellular substance gives character to the tissue, the cellular elements forming a less conspicuous portion. In their fully developed condition some of the members of the connective-tissue group are only slightly altered from embryonic connective tissue. In other members there are developed, in less or greater number, fibers, known as connective-tissue fibers, thus forming reticular connective tissue and the looser and denser forms of fibrous connective tissue. A more marked condensation of the intercellular substance is observed in cartilage; and in bone and dentin a still greater degree of density is obtained by the deposition of calcareous salts in the intercellular matrix. In the different types of connective tissue the cellular elements are morphologically very similar. The rôle played by the connective tissues in the economy of the body is largely passive, depending on their

physical properties. Bone and cartilage serve as supporting tissues; the looser fibrous tissues for binding and holding the organs and parts of organs firmly in place. The denser fibrous connective tissues come into play where strength and pliability are desired, as in ligaments, or else are used in the transmission of muscular force, as in tendons. Another important characteristic of connective tissue is that its various members are capable of undergoing transformation into wholly different types; bone, for instance, being developed from fibrous connective tissue and from cartilage. Certain structures are represented by different members of the connective-tissue group in the different classes of vertebrates. In certain fishes the skeleton is cartilaginous, and in certain birds the leg tendons are formed of osseous tissue, etc. The connective tissues receive their nutrition from the lymph. In the denser connective tissues this permeates the tissues through clefts or spaces in the ground-substance, in which the connective-tissue cells are found and which are united by means of fine canals into a canalicular system. In the looser fibrous tissues and in mucous connective tissue the system of lymph-channels is not present; here the lymph seems to pass through the ground-substance.

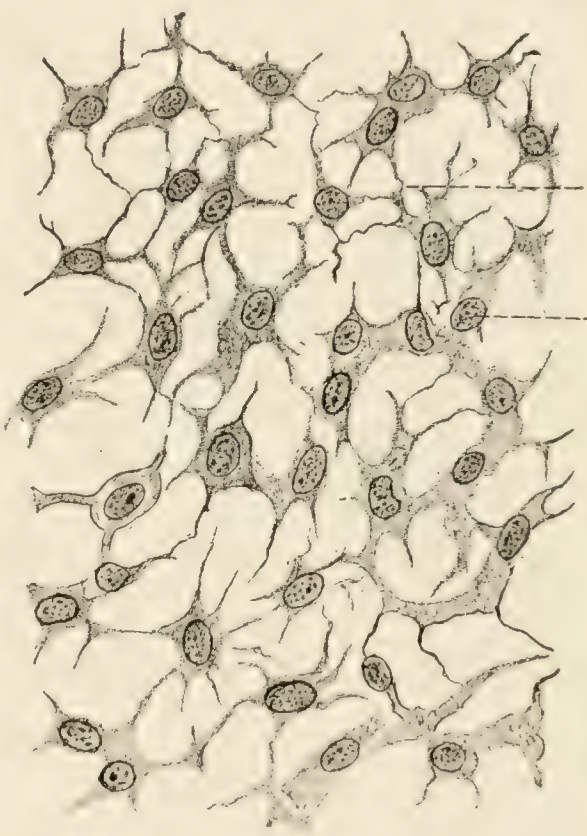

Fig. 60.—Mesenchymatous tissue from the subcutis of a duck embryo; × 650.

Certain connective-tissue cells have the function of producing fat. In various parts of the body, masses of fat tissue are formed as a protection to various organs and as a reserve material upon which the body can call when necessary. This type can hardly be considered a separate class of connective tissues, as it can be demonstrated that it is merely modified connective tissue, and can occur wherever the latter is found. Finally, certain elements of the middle germinal layer are capable of producing colored substances known as *pigments*. To this class belong the pigment cells and the red blood-corpuscles.

All the members of this group are developed from the mesenchyme, an embryonic tissue developed early in embryonic life from the middle germ layer or mesoderm. In its early development the mesenchyme is probably composed of individual cells. As development advances the protoplasm of these cells increases, and is united by means of the protoplasmic branches formed by the cells to form a protoplasmic complex known as a syncytium. The further

development and differentiation of the syncytium has been described in full by F. P. Mall, whose account is here followed. As soon as the syncytium is formed its protoplasm grows rapidly, and appears in large bands with spaces between them, and with relatively few nuclei. In its further development the protoplasm of the syncytium differentiates into a fibrillar part, which forms the main portion of the syncytium—the exoplasm—and a granular part which surrounds

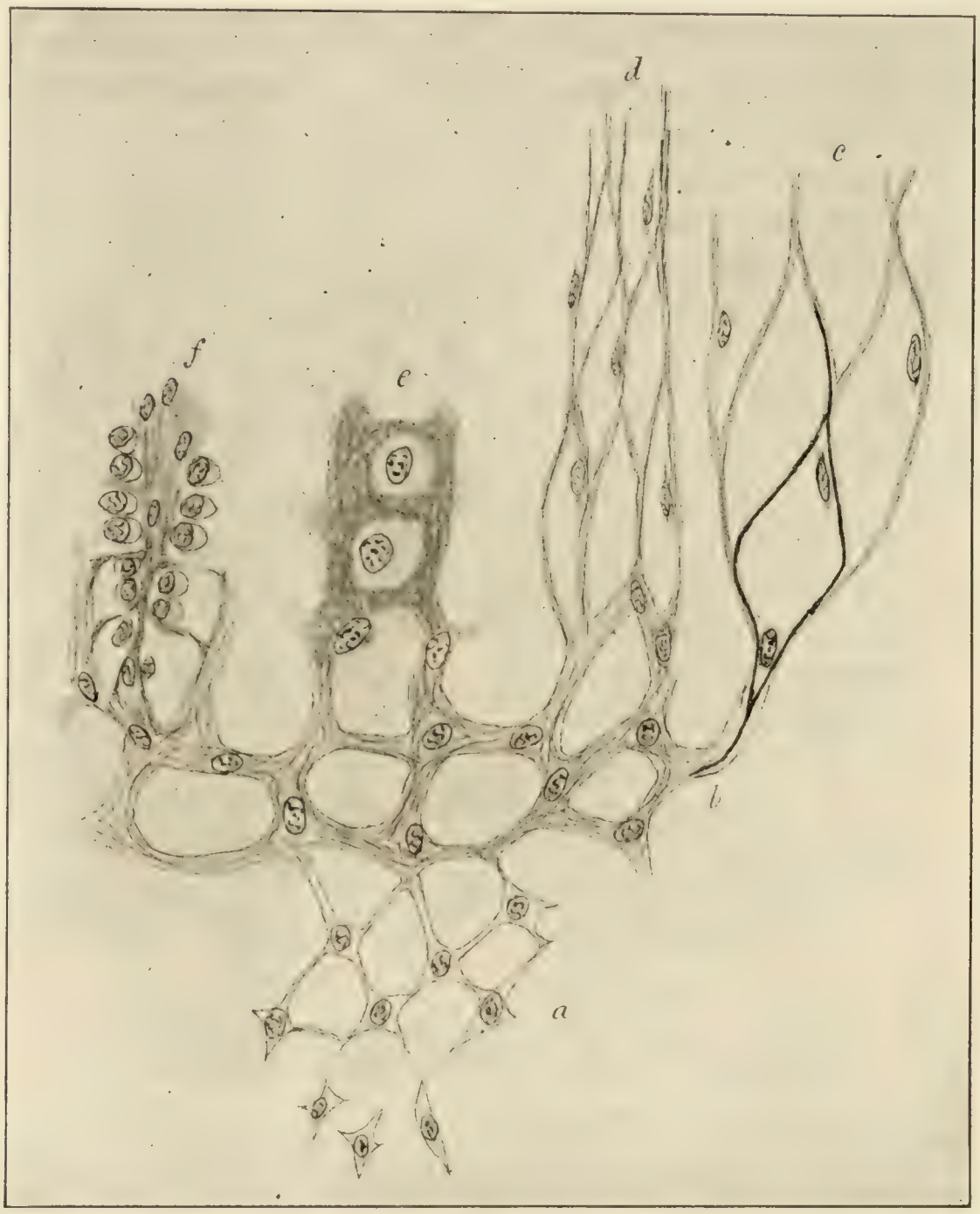

Fig. 61.—Schematic diagram given to show the development of the different types of connective tissue from the mesenchyma: *a*, Mesenchymal cells, certain of which are separate, others are joined by protoplasmic branches; *b*, syncytium with large strands of protoplasm and relative few nuclei; *c*, reticular tissue,—the dark fibers are elastic fibers; *d*, white fibrous tissue; *e*, cartilage; *f*, membranous bone.

the nucleus—the endoplasm. The fibrils of the exoplasm are very delicate and anastomose freely. Probably in all the members of the connective-tissue group, the so-called intercellular substance—fibers, matrix of cartilage and bone—is developed in or from the exoplasm, while the cellular elements are differentiated from the nuclei and endoplasms. The main features of the development of the different types of connective tissue is portrayed, in part schemati-

cally, in fig. 61, combined from a number of figures illustrating F. P. Mall's article dealing with this subject.

The fibers of white fibrous tissue develop in the exoplasm, while the endoplasm containing the nuclei rest on the bundles. In cartilage the ground-substance or matrix is deposited into the exoplasm of the syncytium, the endoplasm and nuclei forming the cartilage cells. In bone, the bone substance or matrix is developed from the exoplasm, either by a transformation of it or by a deposition in it, while the endoplasm increases and the nuclei enlarge to form the bone-forming cells, the osteoblasts. The reticulum of reticular connective tissue is developed directly from the exoplasm of the syncytium, while the nuclei and endoplasm are converted into cells which rest upon the reticulum fibrils.

The following kinds of connective tissue are recognized: (1) mucous connective tissue, (2) reticular connective tissue, (3) fibrous connective tissue, (4) adipose tissue, (5) cartilage, (6) bone.

Fig. 62.—White fibrils and small bundles of white fibrils from teased preparation of a fresh tendon from the tail of a rat.



Fig. 62½.—Elastic fibers from the ligamentum nuchæ of the ox, teased fresh; × 500. At *a* the fiber is curved in a characteristic manner.

The fibrous connective tissues are composed of a ground-substance or matrix in which are imbedded the cellular elements and two kinds of connective-tissue fibers, namely, white and elastic fibers. As the character of the fibrous connective tissue depends largely on the arrangement of the fibers and on the relative proportion of the white and elastic fibers, these will be considered prior to a description of the several types of fibrous connective tissue.

White Fibers.—White fibrous connective tissue consists of exceedingly fine homogeneous fibrillæ, cemented by a small amount of an interfibrillar cement substance into bundles varying in size. In the bundles these fibrillæ have a parallel course, although the bundles are often slightly wavy. The fibrillæ of white fibrous connective tissue vary in size from 0.25 to 1 μ, and neither branch nor anastomose. They become transparent and swollen when treated with acetic acid, are not at all or only very slowly digested by pancreatin, and yield gelatin on boiling.

Elastic Fibers.—These are homogeneous, highly refractive, distinctly contoured fibers, varying in size from 1 μ to 6 μ, and in some animals are even larger. They branch and anastomose, and are not cemented into bundles. When extended, they appear straight; when relaxed, they show broad, bold curves, or are arranged in the form of a spiral. The broken ends of the fibers are bent in the form of a hook. F. P. Mall has shown that elastic fibers are composed of two distinct substances—an outer delicate sheath which does not stain in magenta, and an interior substance which is intensely colored in this stain. The interior substance is highly refractive. Elastic fibers are not affected by acetic acid, but are readily digested in pancreatin and less readily in pepsin. They yield elastin on boiling.

1. MUCOUS CONNECTIVE TISSUE.

Mucous connective tissue is a purely embryonal type, and scarcely represented in the adult human body. It consists of branched, anastomosing cells imbedded in a ground-substance which gives a reaction for mucus and contains a varying number of white fibrous tissue fibers which are developed from a syncytial protoplasm. The latter as well as the mucous matrix are, directly or indirectly, the products of the cells. During the development of the embryo this tissue is found in large quantities in the umbilical cord, and is here known as *Wharton's jelly*. Mucous connective tissue is merely another name for embryonic connective and is found as such wherever connective tissue develops. In the adult it occurs in the posterior chamber of the eye as the vitreous humor.

2. RETICULAR CONNECTIVE TISSUE.

Reticular connective tissue is a fibrous connective tissue in which the intercellular substance has disappeared. The tissue is often described as being composed of anastomosing branched cells, arranged in the form of a network with open spaces. The observations of Ranvier and Bizzozero, and more recently those of Mall, have shown that the framework of reticular tissue is composed of very fine fibrils or bundles of fibrils. These interlace in all planes to form a most intricate network, surrounding spaces of varying size and shape. According to F. P. Mall, the fibrils of reticular tissue differ chemically from both the white and elastic fibers, although their composition has not been fully determined. Like white fibrous tissue, reticular tissue is not digested by pancreatin, but, unlike white fibrous tissue, it does not appear to yield gelatin upon boiling in water, but a mixture of gelatin and reticulin, a substance identified by Siegfried.

The cells of reticular connective tissue, which are flattened and often variously branched, lie on the reticular network, being often wrapped about the bundles of fibrils. Unless they are removed, the

reticulum has the appearance of a network composed of branched and anastomosing cells.

Reticular connective tissue is found in adenoid tissue and lymph-glands, in the spleen, and in the mucous membrane of the intestinal canal, and in these locations the meshes of the reticulum are filled with lymph-cells and other cellular elements, which, unless removed, obscure the reticulum. Connective-tissue fibrils giving the same reaction as those found in the adenoid reticulum are found associated with white and elastic fibers in the liver, kidneys, in the lung, and in many other tissues. In bone-marrow a reticulum is found, in the meshes of which are the cellular elements of this tissue.

Fig. 63.—Reticular fibers from a thin section of a lymph-gland, digested on the slide in pancreatin and stained in iron-lac-hematoxylin.

3. FIBROUS CONNECTIVE TISSUE.

Fibrous connective tissue can be divided morphologically into two groups: In one the bundles of fibers cross and interlace in all directions, forming a network with meshes of varying size—formless or areolar connective tissue. In the other the bundles of fibers are parallel to each other, as in tendon and many of the aponeuroses and ligaments, or less regularly arranged, yet very densely woven, as in fascias, the dura mater, and the firm, fibrous capsules of some of the organs.

(*a*) In **areolar connective tissue** the bundles of white fibers, which vary greatly in size and which often divide and anastomose with portions of other branching bundles, intercross and interlace in all directions. If the bundles of fibers are numerous, the interlacement is more compact, thus forming a dense areolar connective tissue; if less numerous, the network is more open, as in loose areolar connective tissue. Elastic fibers are always found in areolar connective tissue, though in varying quantity. They anastomose to form a network with large, irregular meshes, and run on or between the bundles of white fibers. The meshes between the bundles of fibers, and the

minute spaces between the fibrils in these bundles, are occupied by a semifluid, homogeneous substance known as the *ground-substance*, or *matrix*. The fibrous elements of areolar connective tissue are,

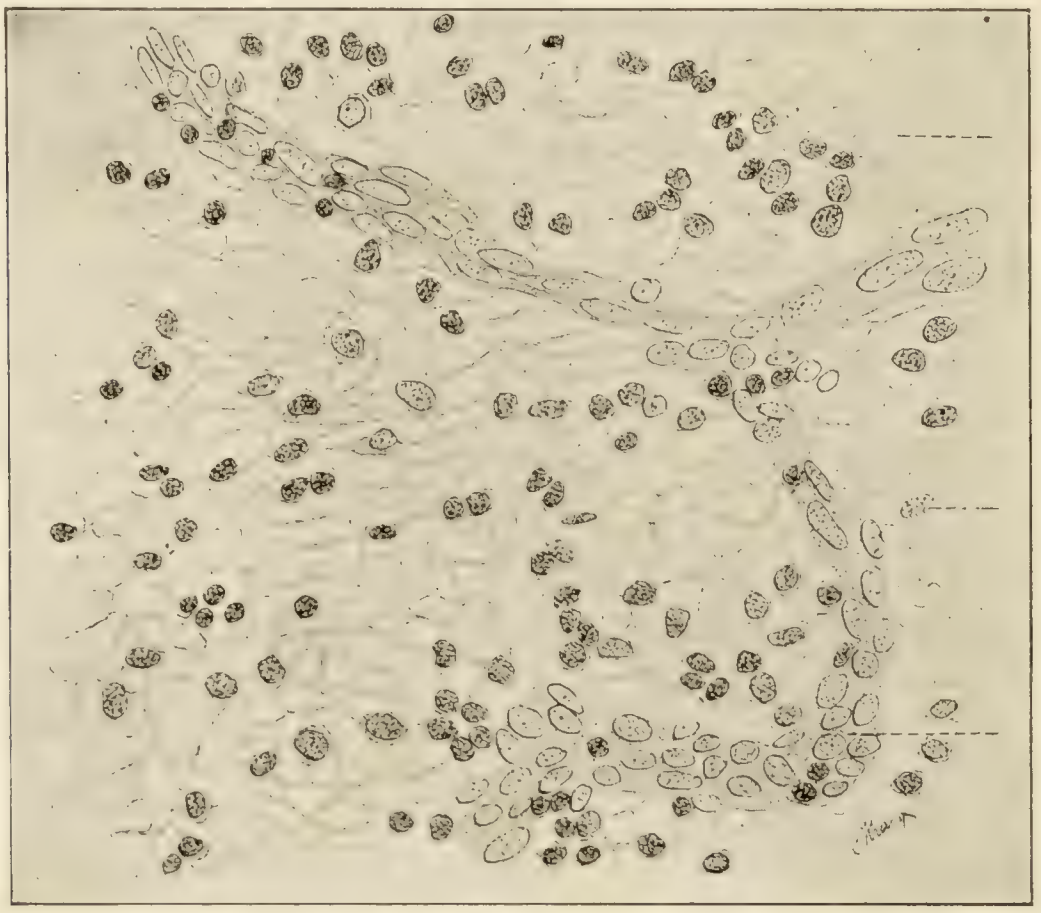

Fig. 64.—Reticular connective tissue from lymph-gland of man; × 280. Brush preparation.

therefore, imbedded in this ground-substance. In dense areolar connective tissue the fibrous elements appear to have nearly displaced the ground-substance. In the ground-substance are found irregular, branched spaces,—*cell-spaces*,—in which lie the cellular elements of this connective tissue. These spaces anastomose by means of their branches, thus forming part of a system of spaces and small channels, known as the *lymph canalicular system*. These spaces and channels permeate the ground-substance in all directions, and serve to convey lymph to the tissue elements. The cell-spaces and their anastomosing branches can be demonstrated by immersing areolar connective tissue (preferably from a young animal), spread out in a thin layer, in a solution of silver nitrate (1 %) until the tissue becomes opaque. If then the tissue is exposed to sunlight, the silver is reduced in the ground-substance, giving it a brown color, while the cell-spaces remain unstained. The ground-substance of areolar connective tissue contains mucin.

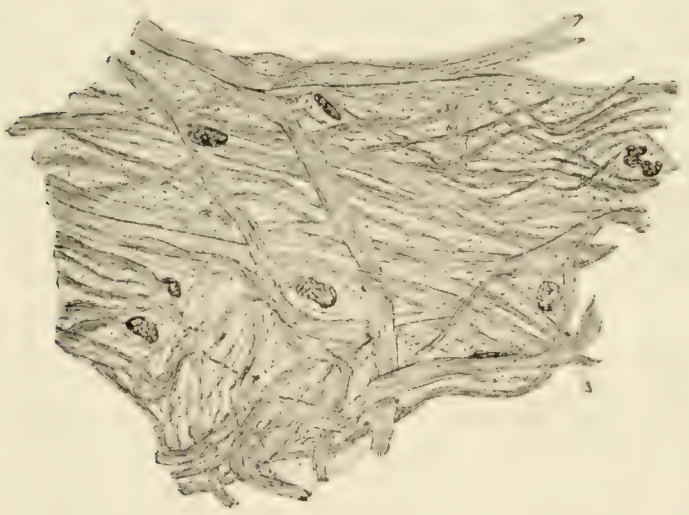

Fig. 65.—Areolar connective tissue from the subcutaneous tissue of a rat. Elastic fibers not shown.

The **cellular elements** of areolar connective tissue, which, as above stated, are found in the cell-spaces, are either *fixed connective-tissue* cells or *wandering* or *migratory* cells. The former are again divided, according to their shape and structure, into true connective-tissue cells or corpuscles, plasma cells, mast-cells, and pigment-cells.

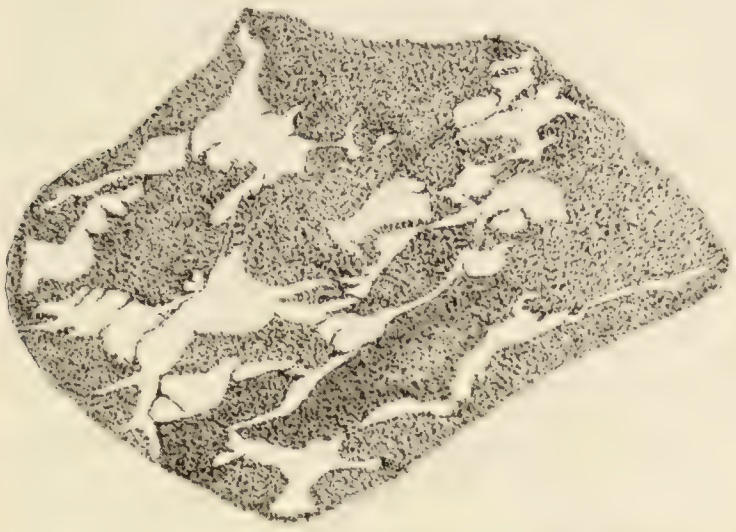

Fig. 66.—Cell-spaces in the ground-substance of areolar connective tissue (subcutaneous) of a young rat. Stained in silver nitrate.

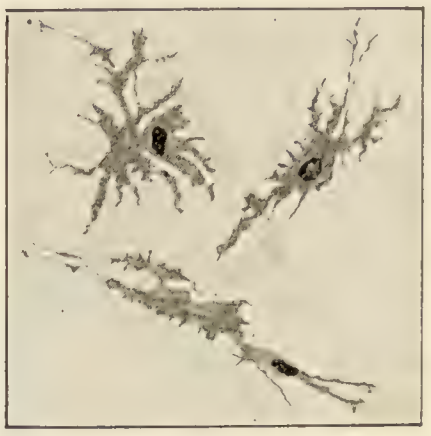

Fig. 67.—Three connective-tissue cells from the pia mater of a dog. Stained in methylene-blue (*intra vitam*).

The *connective-tissue cells* or *corpuscles* are flattened, variously shaped cells of irregular form, usually having many branches. The protoplasm is free from granules; the nucleus, situated in the thicker portion of the cell-body and of oval shape, shows a nuclear network and one or several nucleoli. The cells assume the shape of

Fig. 68.—Two pigment cells found on the capsule of a sympathetic ganglion of a frog.

the space that they occupy and nearly fill. The branches of neighboring cells often anastomose through the fine channels uniting the cell-spaces.

Plasma cells (Unna) vary in size and shape according to the space which they occupy. They may be round, oval, or spindle-shaped, and measure from 6 μ to 10 μ. The nucleus is round or oval. They are characterized by the fact that their protoplasm stains intensely in basic aniline dyes, often of a color differing from that of the solution used. According to some observers, the plasma cells are thought to be developed from the connective cells, while others regard them as derived from the white blood-cells (lymphocytes). They are found in various mucous membranes and in lymphoid tissues generally.

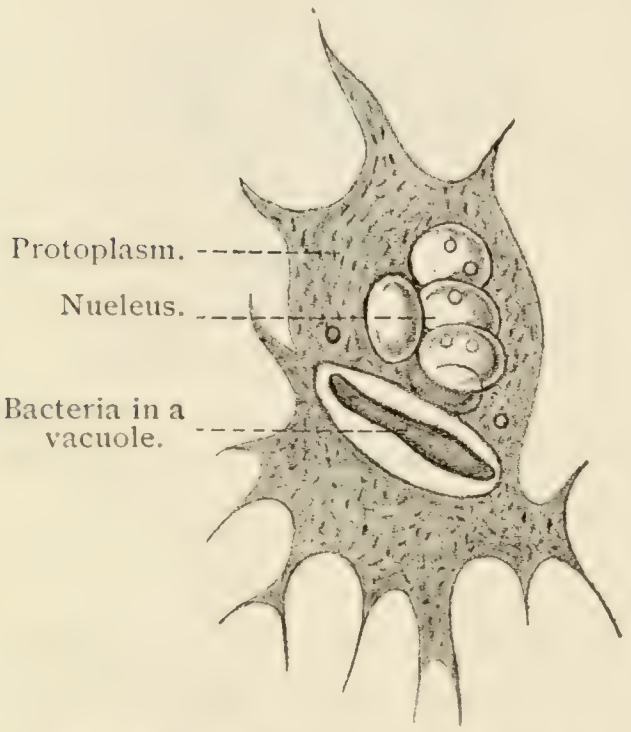

Fig. 69.—Leucocyte of a frog with pseudopodia. The cell has included a bacterium which is in process of digestion. (After Metschnikoff, from O. Hertwig, 93, II.)

Mast-cells (Ehrlich) are relatively large cells of round, oval, or irregular shape, the protoplasm of which contains relatively large granules which stain chiefly in basic aniline dyes, which granules are often found in such numbers that they cover up the nucleus. The granules are stained by a number of basic aniline dyes, often of a color differing from that of the stain used. They are found generally in mucous membranes, generally near the vessels, in the skins, in involuntary muscle, and in the bone-marrow.

Pigment cells are branched connective-tissue cells, in the protoplasm of which are found brown or nearly black granules. In man they occur in the choroid and iris and in the dermis. In the lower animals they have, however, a much wider distribution, and in the frog and other amphibia they are very large and irregular. These cells have the power of withdrawing their processes and, to a limited degree, of changing their location (dermis).

The *wandering* or *migratory cells* are described in this connection not because they form one of the structural elements of areolar connective tissue, but because they are always associated with it. They are lymph- or white blood-cells, which have left the lymph- or blood-vessels and have migrated into the lymph canalicular system. They possess ameboid movement, and wander from place to place, and are the phagocytes of Metschnikoff. They seem to be intrusted with the removal of substances either superfluous or detrimental to the body (as bacteria). These are either digested or rendered harmless. The wandering cells even transport substances thus taken up to some other region of the body, where they are deposited.

In the peritoneum and other serous membranes the network formed by the fibrous tissue lies in one plane, and does not branch

and intercross in all directions, as where areolar tissue is found in larger quantity. (Fig. 70.)

(*b*) **Tendons, aponeuroses,** and **ligaments** represent the densest variety of fibrous connective tissue, and are composed almost wholly of white fibrous tissue. This is found in the form of relatively large bundles of white fibrils, having a parallel or nearly parallel course. In tendons these bundles are known as *primary tendon bundles* or *tendon fasciculi.* The fibrils of white fibrous con-

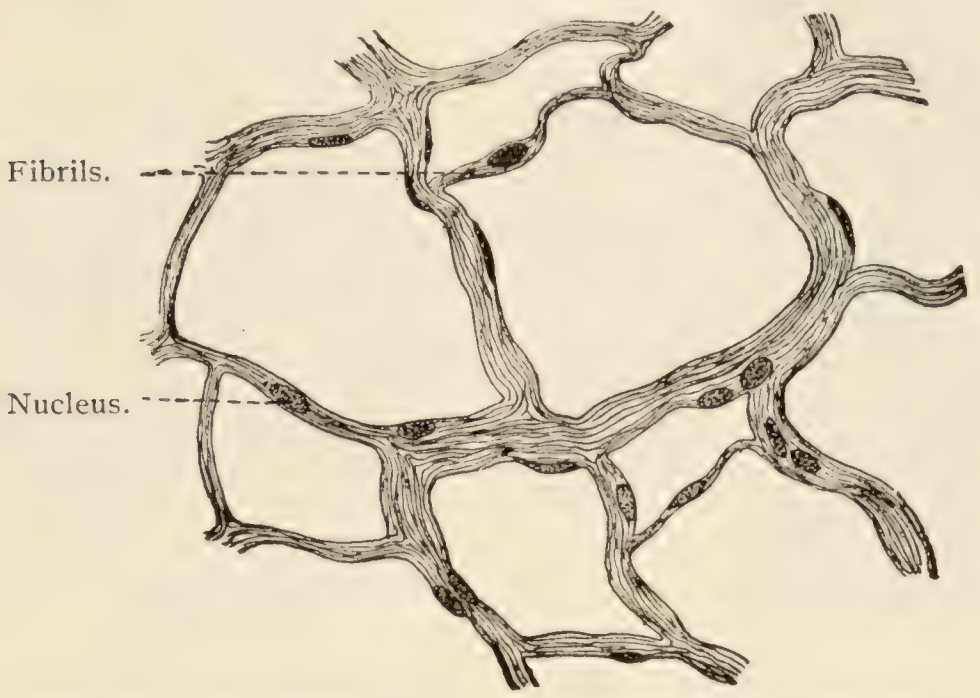

Fig. 70.—Fibrous connective tissue (areolar) from the great omentum of the rabbit; × 400.

nective tissue forming the fasciculi are cemented together by an interfibrillar cement substance. Here and there the fasciculi branch at very acute angles and anastomose with other fasciculi. The fasciculi are grouped into larger or smaller bundles, the *secondary tendon bundles*, which are surrounded by a thin layer of areolar connective tissue, and in part covered by endothelial cells. Between the tendon fasciculi there is found a ground-substance, *interfascicular ground-substance*, identical with the ground-substance in areolar connective tissue. In this there are cell-spaces occupied by the tendon cells, morphologically similar to the branched cells of areolar connective tissue. The tendon cells are arranged in rows between the tendon fasciculi. They have an irregular, oblong body, containing a nearly round or oval nucleus. Two, three, or even more wing-like processes (lamellæ) come from the cell-body and pass between the tendon fasciculi. In cross-section the tendon cells have a stellate shape.

The secondary tendon bundles are grouped to form the tendon, and the whole is surrounded and held together by a layer of areolar connective tissue, called the *peritendineum.* From this, septa pass in between the secondary tendon bundles, forming the internal peritendineum. The blood- and lymph-vessels and the nerve-fibers reach the interior of the tendon through the external and internal peritendineum.

The structure of an aponeurosis and a ligament is like that of a tendon.

The structure of a fascia, the dura mater, and the more fully

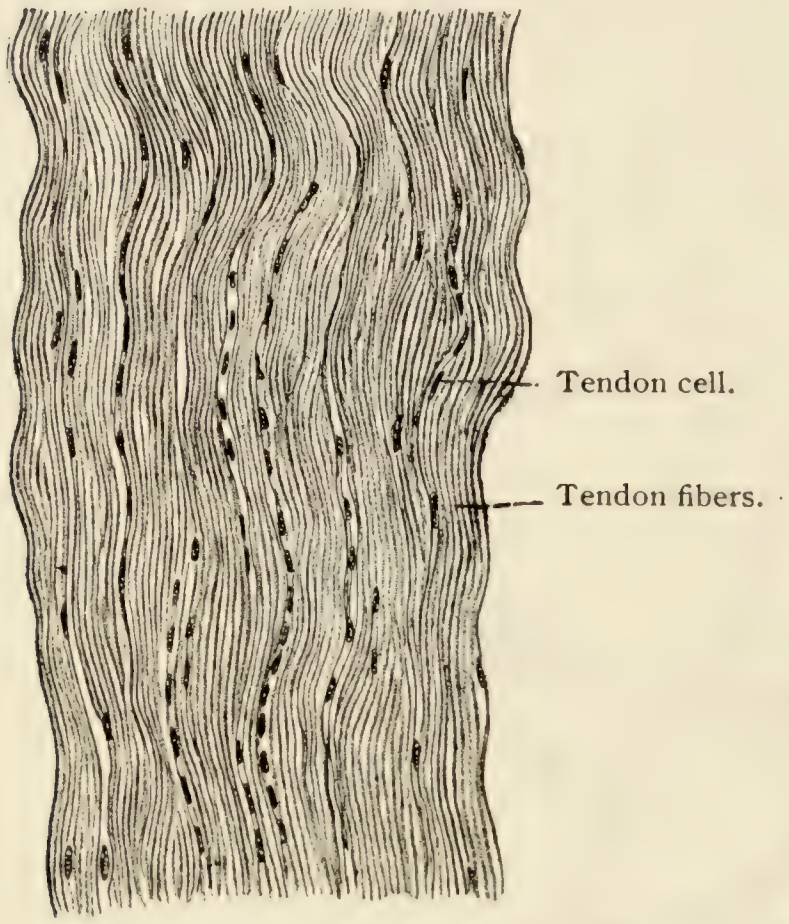

Fig. 71.—Longitudinal section of tendon; × 270.

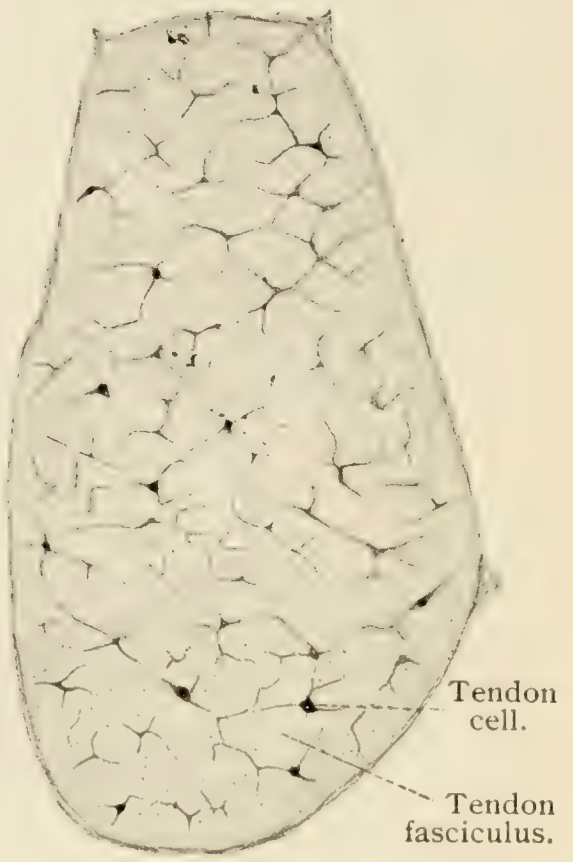

Fig. 72.—Cross-section of secondary tendon bundle from tail of a rat.

developed gland capsules, differs from that of the formed connective tissues above described, in that the fasciculi are not so regularly arranged, but branch and anastomose and intercross in several planes.

(*c*) **Elastic Fibrous Tissue.**—In certain connective tissues the elastic fibers predominate greatly over the fibers of white fibrous connective tissue. These are spoken of as elastic fibrous tissues and their structural peculiarities warrant the making of a special subgroup.

The ligamentum nuchæ of the ox consists almost exclusively of elastic fibers, many of which attain a size of about 10 μ. The elastic fibers branch and anastomose, retaining, however, a generally parallel course. They are separated by a small amount of areolar connective tissue, in which a connective-tissue cell is here and there found, and are grouped into bundles surrounded by thin layers of areolar connective tissue; the whole ligament receives an investment of this tissue. In cross-sections of the ligamentum nuchæ, the larger elastic fibers have an angular outline; the smaller ones are more regularly round or oval. (Fig. 74.) In man the ligamenta subflava, between the laminæ of adjacent vertebræ, are elastic ligaments.

In certain structures (arteries and veins), the elastic tissue is arranged in the form of membranes. It is generally stated that

such membranes are composed of flat, ribbon-like fibers or bands of elastic tissue arranged in the form of a network, with larger or smaller openings; thus the term *fenestrated membranes.* F. P. Mall has reached the conclusion that such membranes are composed of three layers—an upper and a lower thin transparent layer in which no openings are found and which are identical with the sheaths of elastic fibers described by this observer, and a central layer, containing openings, and staining deeply in magenta. This substance is identical with the central substance of elastic fibers.

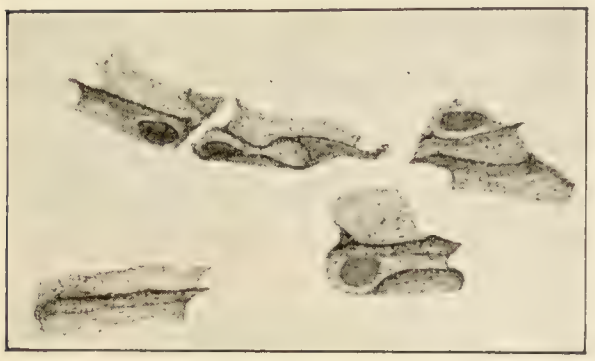

Fig. 73.—Tendon cells from the tail of a rat. Stained in methylene-blue (*intra vitam*).

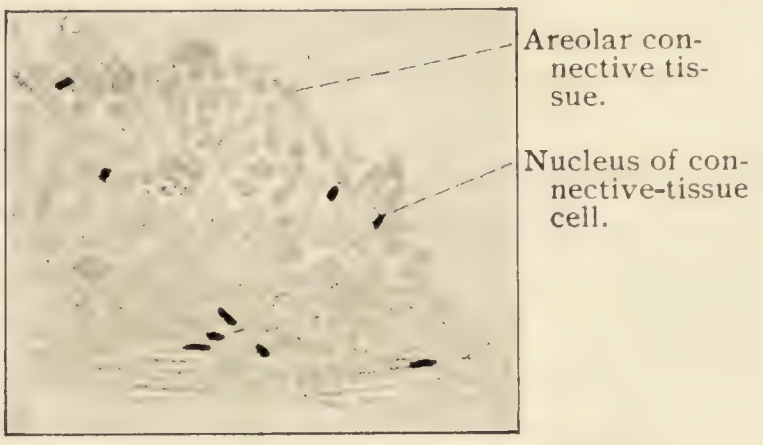

Fig. 74.—Cross-section of ligamentum nuchæ of ox.

4. ADIPOSE TISSUE.

In certain well-defined regions of the body occur typical groups of fixed connective-tissue cells which always change into fat-cells (fat organs, Toldt). Connective-tissue cells in various other portions of the body may also change into fat-cells, but in this case the fat, as such, sometimes disappears, allowing the cells to resume their original connective-tissue type, only again to appear and a second time change the character of the tissue. The formation of fat is very gradual. Very fine fat globules are deposited in the cell; these coalesce to form larger ones, until finally the cell is almost entirely filled with a large globule (*vid.* also H. Rabl, 96). As the fat globule grows larger and larger, the protoplasm of the cell, together with its nucleus, is crowded to the periphery. The protoplasm then appears as a thin layer just within the clear cellular membrane. The nucleus becomes flattened by pressure, until in profile view it has the appearance of a long, flat body. In regions in which large masses of fat-cells are developed, they are seen to be gathered into rounded groups of various sizes (fat lobules) separated by strands of connective tissue. Such lobules have, as was first pointed out by Toldt, a typical and very rich blood-supply from the time that they are recognized as fat organs in the embryo. A small artery

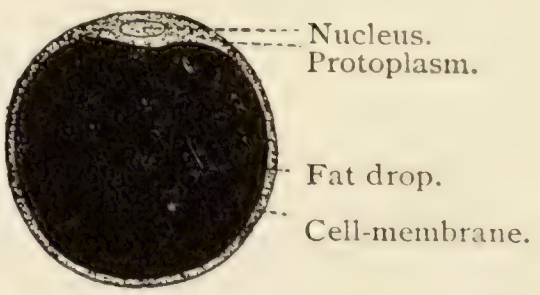

Fig. 75.—Scheme of a fat-cell.

courses through the center of the fat lobule, breaking up into capillaries which form a network around the fat cells. The capillaries unite to form several veins which are situated at the periphery of the lobule. Where fat cells develop from connective-tissue cells, even though these are present in considerable number this typic arrangement of the blood-vessels is wanting.

Microscopically, fat is easily recognized by its peculiar glistening appearance (by direct light). It has a specific reaction to certain reagents. It becomes black on treatment with osmic acid, and is stained red by Sudan III and blue in cyanin.

5. CARTILAGE.

Cartilage is readily distinguished from other connective tissues by its ground-substance or matrix,—intercellular substance,—which yields chondrin on boiling. Three varieties are found in higher vertebrates: (1) hyaline cartilage; (2) elastic cartilage; (3) white fibro-cartilage or connective-tissue cartilage.

The simplest type is *hyaline* cartilage, so named because of its

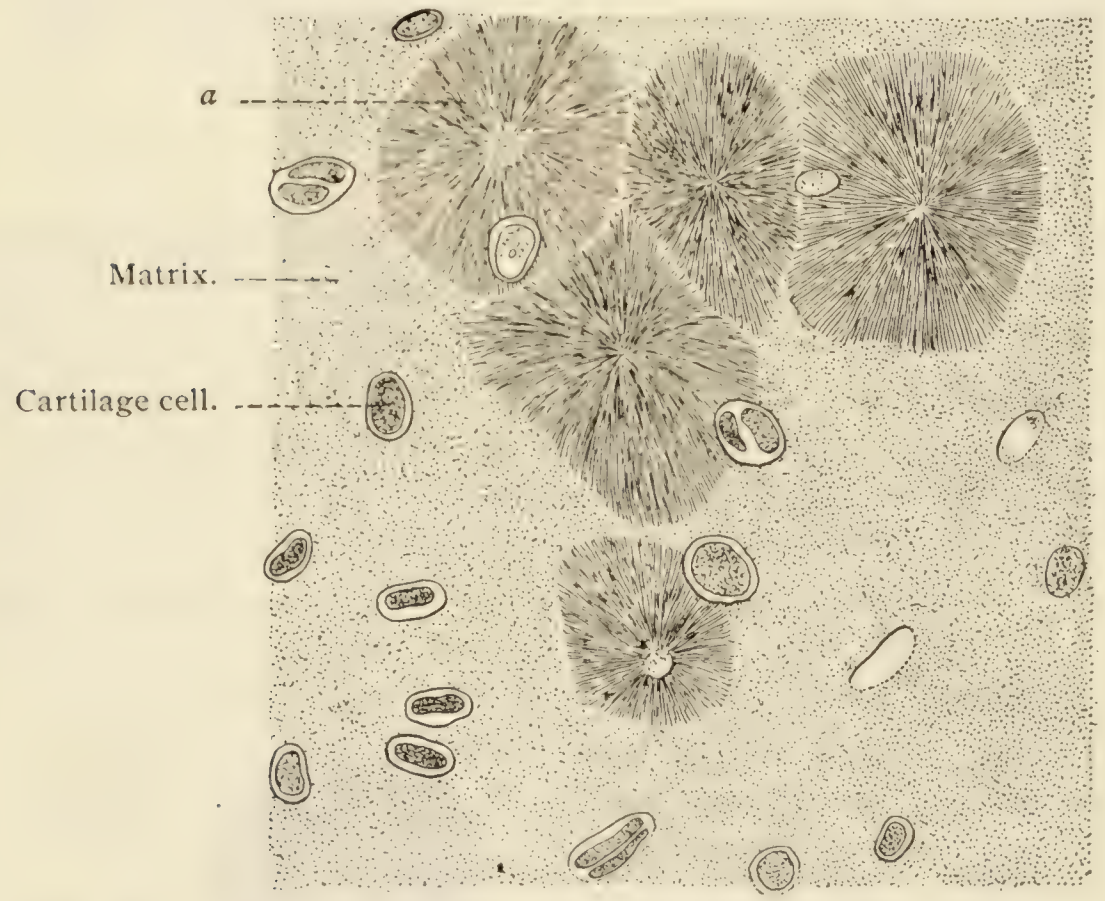

Fig. 76.—Hyaline cartilage (costal cartilage of the ox). Alcohol preparation; × 300. The cells are seen inclosed in their capsules. In the figure *a* are represented frequent but by no means characteristic radiate structures.

homogeneous and transparent ground-substance, which, however, in reality consists of fibrils and an interfibrillar substance, the two having essentially the same refractive index. In this ground-substance are found the cartilage cells, occupying spaces known as lacunæ. The spaces or lacunæ are surrounded by a narrow zone of ground-substance, which does not stain as does the ground-

substance and which refracts the light more strongly. This zone is generally known as the capsule of the cartilage cells. As previously stated, the matrix or ground-substance, develops in the exoplasm of the protoplasmic syncytium from which cartilage has its origin, while the endoplasm and nuclei form the cartilage cells. Cartilage cells, as such, are of various shapes, and have no typical appearance. They are usually scattered irregularly throughout the matrix, but are often arranged in groups of two, three, four, or even more cells. At the periphery of cartilage, either where it borders upon a cavity (articular cavity) or where it joins the perichondrium, the cells are arranged in several rows parallel to the surface of the tissue. Cartilage cells often contain glycogen, either in the form of drops or diffused throughout their protoplasm.

Cartilage grows by intussusception, and an appositional growth, although in a lesser degree, also takes place. It occurs where the cartilage borders upon its connective-tissue sheath or *perichondrium*,

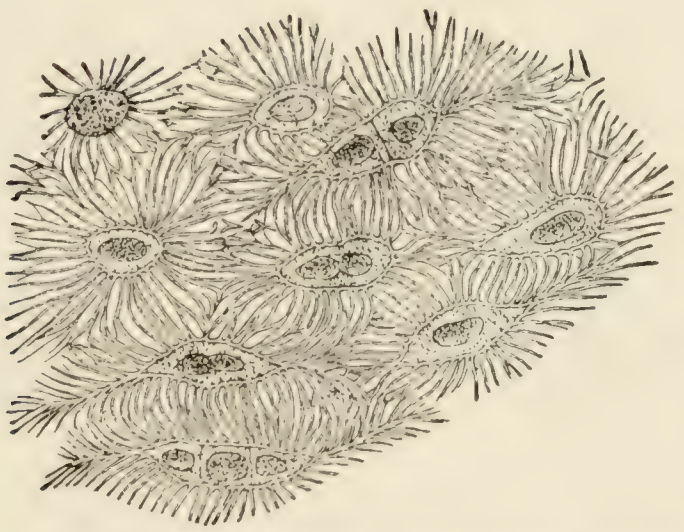

Fig. 77.—From a section through the cranial cartilage of a squid (after M. Fürbinger, from Bergh).

a vascular, fibrous-tissue membrane composed of white and elastic fibers, which covers the cartilage except where it forms a joint surface. The relations of the cartilage and perichondrium are extremely intimate. Fibers are seen passing from the perichondrium into the cartilaginous matrix, and the connective-tissue cells appear to change directly into cartilage-cells.

Certain observers (Wolters, Spronk, and others) have described a system of canaliculi in the ground substance, which are said to unite the lacunæ and are thought to serve as channels for the passage of lymph. Such structures are, however, not generally recognized. It is an interesting fact, however, that the cartilage of certain invertebrate animals, the cephalopoda, shows cells with anastomosing processes. (Fig. 77.) In this case the cartilage-cell is similar to a bone-cell, thus theoretically allowing of the possibility of the metamorphosis of the elements of cartilage into those of bone (M. Fürbringer).

Hyaline cartilage occurs as articular cartilage, covering joint surfaces, as costal cartilage and in the nose, larynx, trachea, and

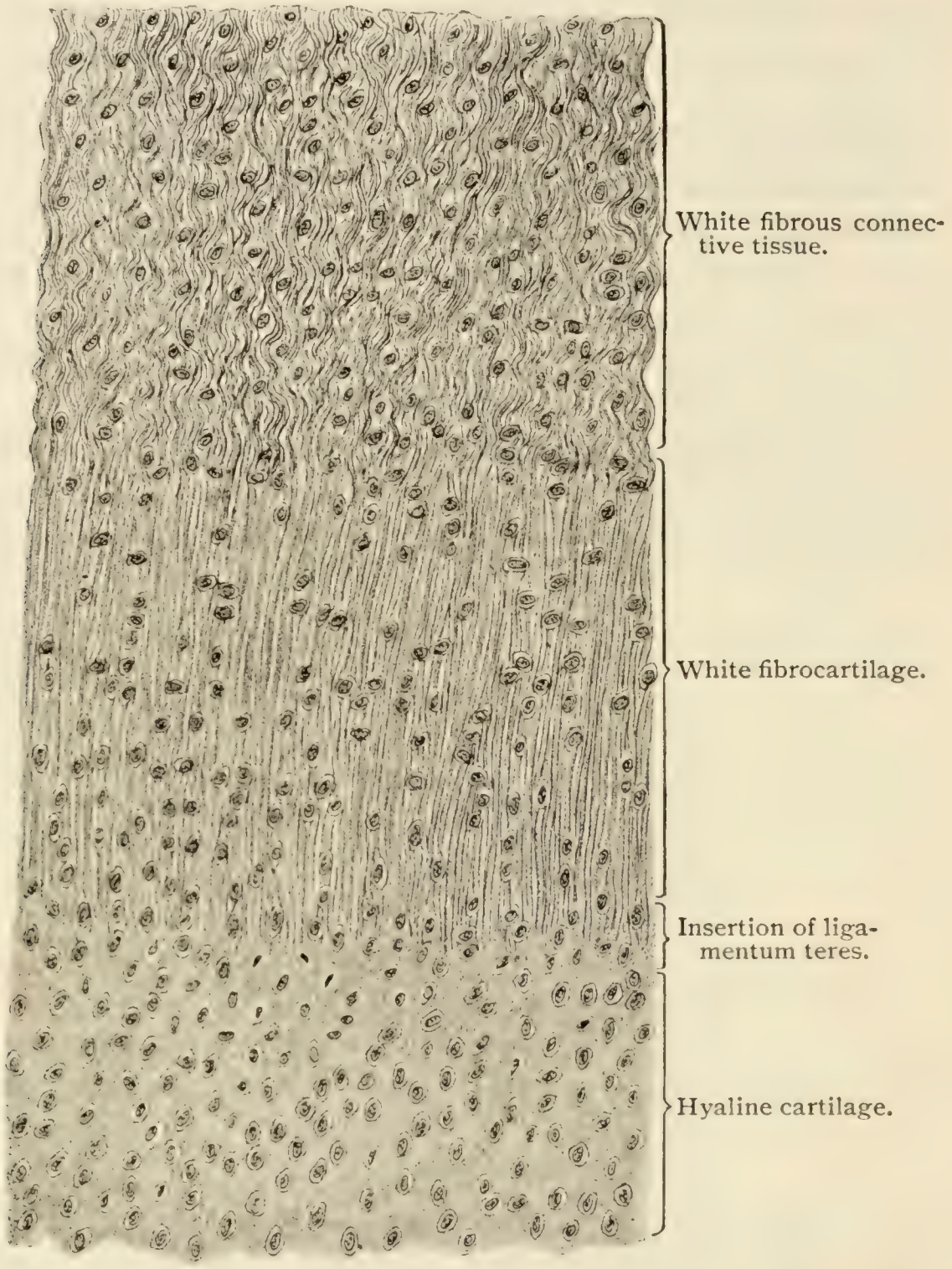

Fig. 78.—Insertion of the ligamentum teres into the head of the femur. Longitudinal section ; × 650.

bronchi. All bones except those of the vault of the skull and the majority of the bones of the face are preformed in hyaline cartilage.

In *white fibrocartilage* (Fig. 78) there are from the beginning, even in precartilage, fibrous strands in the ground-substance. They preponderate over the matrix and, as a rule, have a parallel direction. White fibrocartilage is found in the intervertebral and interarticular disks, the symphysis pubis, and in the insertion of the ligamentum teres ; it deepens the cavity of ball-and-socket joints, and lines the tendon grooves.

In some places elastic fibers are found imbedded in hyaline cartilage—*fibro-elastic cartilage*. The elastic fibers send off at acute angles finer or coarser threads which interlace to form a delicate or

dense network which permeates the hyaline matrix (Fig. 79), passing over into the corresponding elements of the perichondrium. Elastic cartilage is found in the external ear, the cartilage of the Eustachian tube, the epiglottis, a portion of the arytenoid cartilages, and the cartilages of Wrisberg and Santorini.

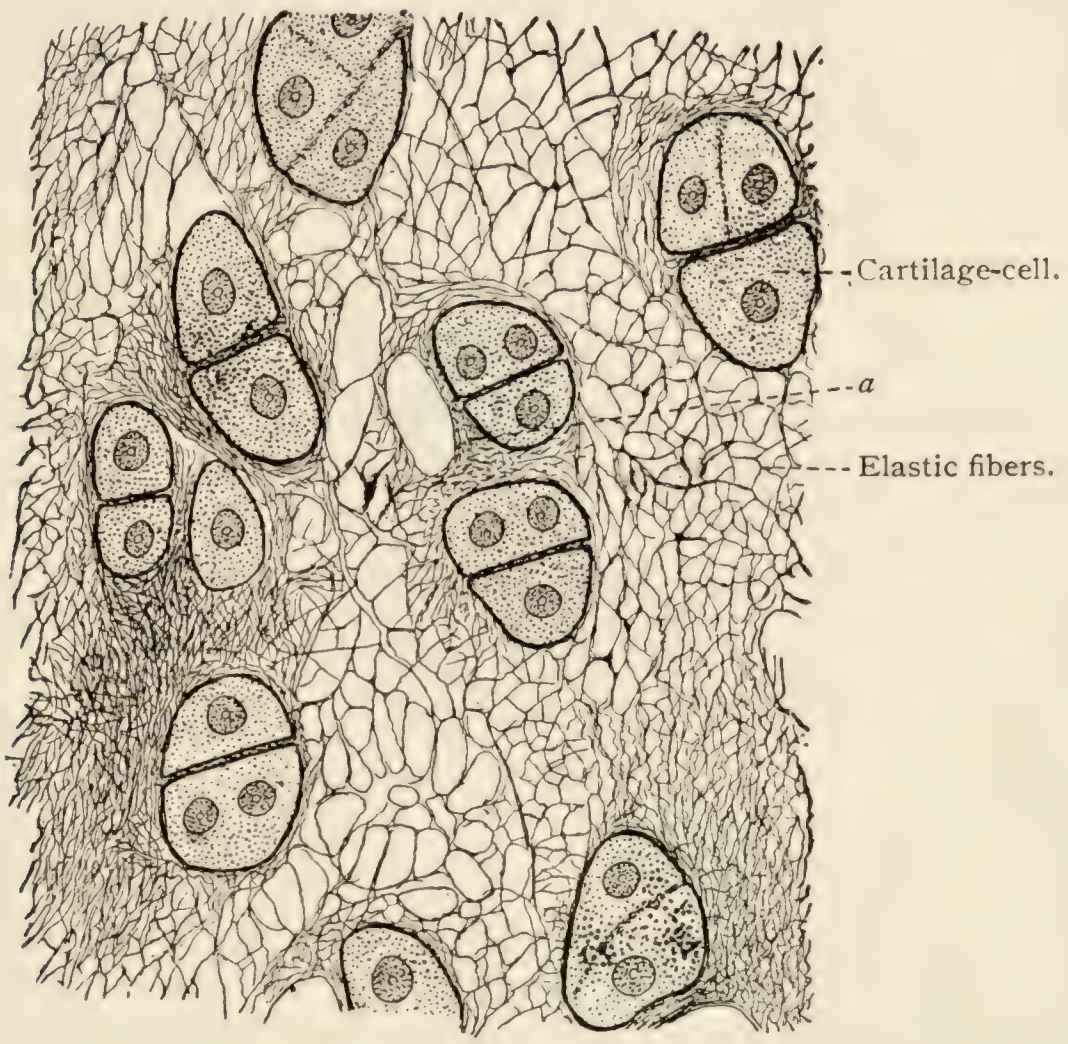

Fig. 79.—Elastic cartilage from the external ear of man; × 760. *a*, Fine elastic network in the immediate neighborhood of a capsule.

The ground-substance of cartilage undergoes changes as age advances. In certain cartilages there is observed a fibrillar formation, in the ground-substance between the cells. The fibers are coarse and differ from white fibrous or yellow elastic fibers. This change is observed in laryngeal cartilages as early as the twentieth year, and is sometimes designated as an asbestos-like alteration of cartilage. *Calcification* occurs in many cartilages—laryngeal, tracheal, costal—and consists of the deposition in the ground-substance of fine granules of carbonate of lime, first in the immediate vicinity of the cartilage cells. Calcification is observed as early as the twentieth year in the laryngeal cartilages. *Ossification* may be regarded as a normal occurrence in many cartilages. It begins with an ingrowth of blood-vessels from the perichondrium into the matrix. These vessels are surrounded by connective tissue. Around such locations ossification occurs. Chievitz has shown that the laryngeal cartilages begin to ossify in man at about the twentieth year, and in women at about the thirtieth year; and the tracheal

cartilage in men about the fortieth year, and in women about the sixtieth year.

To obtain *chondrin*, a piece of cartilage matrix is placed in a tube containing water. This is hermetically closed and heated to 120° C., after which it is opened and the fluid filtered and treated with alcohol. A precipitate of chondrin is the result. This substance is insoluble in cold water, alcohol, and ether, but soluble in hot water, although, on cooling, it gelatinizes. In contrast to gelatin, chondrin is precipitated by acetic acid. This precipitate does not redissolve in an excess of this acid but disappears in an excess of certain mineral acids.

6. BONE.

(*a*) **Structure of Bone.**—Bone nearly always develops from a connective-tissue foundation, even where it occurs in places formerly occupied by cartilage.

The inorganic substance of bone is deposited in or between the fibers of connective tissue, while the cells of the latter are transformed into bone-cells.

As in connective tissue, so also in bone, the ground-substance is fibrous. Between the fibers remain uncalcified cells, *bone-cells*, each of which rests in a cavity of the matrix—*lacuna*.

Primarily, bone consists of a single thin lamella, its later complicated structure being produced by the formation of new lamellæ in apposition to the first. During its development the bone becomes vascularized, and the vessels are inclosed in especially formed canals known as *vascular* or *Haversian* canals.

The bone-cells have processes that probably anastomose, and that lie in special canals known as *bone canaliculi*. Whether, in man, all the processes of bone-cells anastomose is still an open question.

The appearance presented by a transverse section of the shaft of a long bone is as follows: In the center is a large marrow cavity, and at the periphery the bone is covered by a dense connective-tissue membrane, the *periosteum*. In the new-born and in young individuals the periosteum is composed of three layers—an outer layer, consisting mainly of rather coarse, white fibrous-tissue bundles that blend with the surrounding connective tissue; a middle fibro-elastic layer, in which the elastic tissue greatly predominates; and an inner layer, the osteogenetic layer, vascular and rich in cellular elements, containing only a few smaller bundles of white fibrous tissue. In the adult the osteogenetic layer has practically disappeared, leaving only here and there a few of the cells of the layer, while the fibro-elastic layer is correspondingly thicker (Schulz, 96). A large number of Haversian canals containing blood-vessels, seen mostly in transverse section, are found in compact bone-substance.

Lamellæ of bone are plainly visible throughout the ground-substance, and are arranged in the following general systems:

First, there is a set of bone lamellæ running parallel to the external surface of the bone, while another set is similarly arranged around the marrow cavity. These are the so-called *fundamental*, or *outer* and *inner circumferential lamellæ* (known also as *periosteal* and *marrow lamellæ*). Around the Haversian canals are the concentrically arranged lamellæ, forming systems of Haversian or *concentric lamellæ*. Besides the systems already mentioned, there are found *interstitial* or *ground lamellæ* wedged in between the Haversian

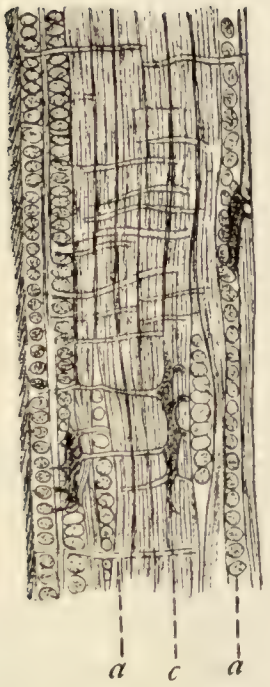

Fig. 80.—Longitudinal section through a lamellar system.



Figs. 81 and 82.—Lamellæ seen from the surface; × 460 (after v. Ebner 75).

a, Primitive fibrils and fibril-bundles; *c*, bone-corpuscles with bone-cells; *d*, bone canaliculi.

or concentric systems of lamellæ. Some authors group the interstitial lamellæ with the systems of fundamental lamellæ.

Lying scattered between the lamellæ are found spaces known as *bone corpuscles* (Virchow) or *lacunæ*. These are present in all the lamellar systems. It is very probable that all the lacunæ are in more or less direct communication with each other by means of fine canals called *canaliculi* (1.1 μ to 1.8 μ in diameter). It can be demonstrated without difficulty that the lacunæ of a single lamellar system communicate not only with each other, but also with those of

adjacent systems. In the lamellæ adjoining the periosteum and marrow cavity the canaliculi end respectively in the subperiosteal tissue and in the marrow cavity. The canaliculi of the Haversian lamellæ empty into the Haversian canals.

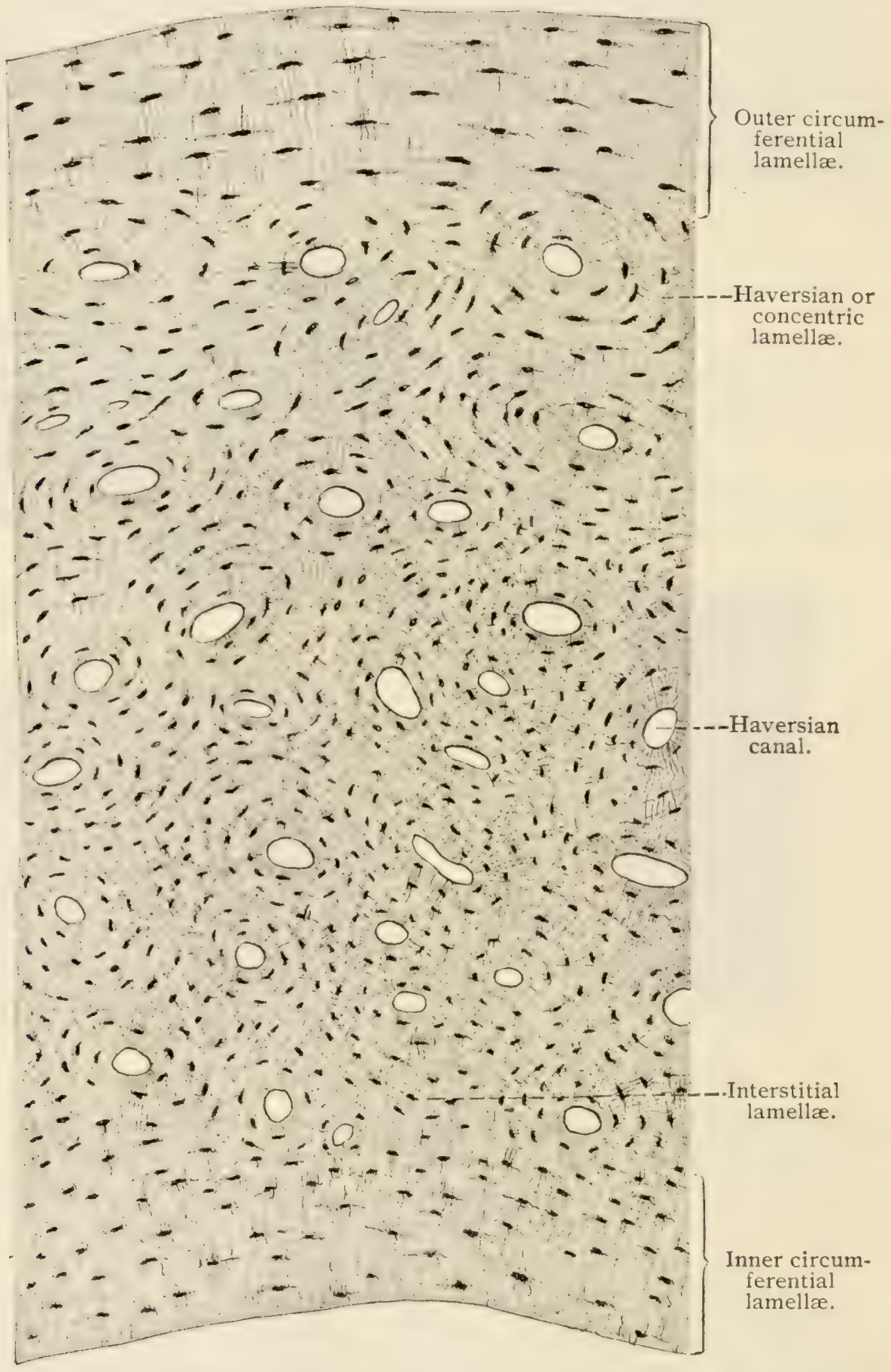

Fig. 83.—Segment of a transversely ground section from the shaft of a long bone, showing all the lamellar systems. Metacarpus of man; × 56.

The lamellæ of bone are composed of fine white fibrous-tissue fibrils, embedded in a ground-substance, in which they are arranged in layers, superimposed in such a way that the fibrils in the several layers cross at about a right angle, forming an angle of 45° with

the long axis of the Haversian canal. It is as yet undecided whether the mineral salts (phosphate and carbonate of lime, sodium chlorid, magnesium salts, etc.) are deposited in the ground-substance (v. Ebner) or in the fibrillæ (Kölliker). The lacunæ (13 μ to 31 μ long, 6 μ to 15 μ wide, and 4 μ to 9 μ thick) have, in common with the canaliculi, walls which present a greater resistance to the action of strong acids than the rest of the solid bone-substance. In each lacuna there is found a *bone-cell*, the nucleated body of which practically fills the lacuna, while its processes extend out into the canaliculi.

The Haversian canals contain blood-vessels, either an artery or a vein or both. Between the vessels and the walls of the canals are perivascular spaces bounded by endothelial cells, resting on the adventitious coats of the vessels and the sides of the canals. Into these spaces empty the canaliculi of the Haversian system. Lymph-spaces beneath the periosteum and at the periphery of the marrow

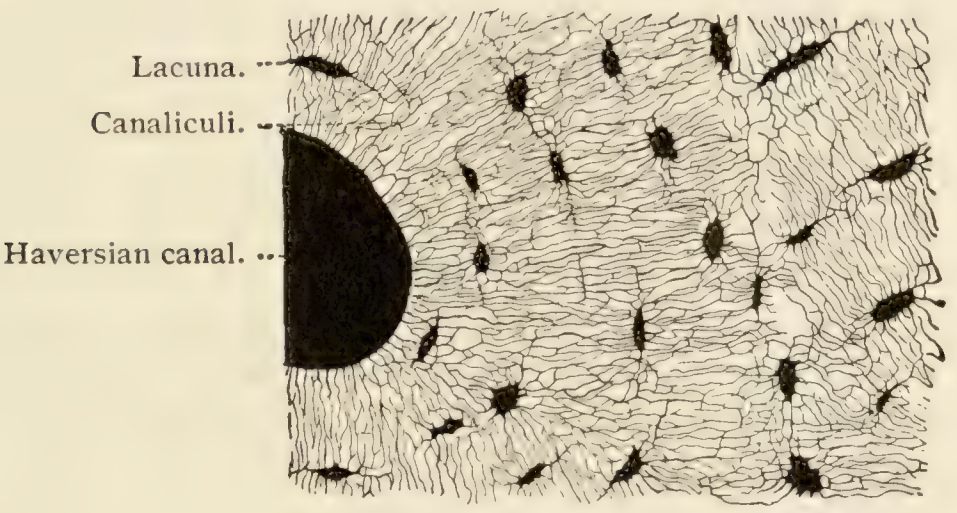

Fig. 84.—Portion of a transversely ground disc from the shaft of a human femur; ×400.

cavity communicate directly with the canaliculi of the circumferential systems.

All the lacunæ and canaliculi should be thought of as filled by lymph plasma which circulates throughout, bathing the bone-cells and their processes. The formed elements of the lymph are probably too large to force their way through the very small canaliculi. The plasma current probably flows from the periosteal and marrow regions toward the Haversian canals.

Between the lamellæ are bundles of fibers (some of which are calcified), which can be demonstrated by heating the bone, or in decalcified preparations on staining by certain methods. These are the so-called *fibers of Sharpey;* in the adult they contain elastic fibers.

In the circumferential lamellæ are found canals, not surrounded by concentric lamellæ, which convey blood-vessels from the periosteum to the Haversian canals. These are called *Volkmann's canals.*

The structure of bone-marrow will be discussed with the blood-forming organs.

(*b*) **Development of Bone.**—Nearly all the bones of the adult body are, in the earlier stages of embryonic life, preformed in embryonic cartilage. As development proceeds, this embryonic cartilage assumes the character of hyaline cartilage, its cells becoming vesicular, and probably disappearing. In the matrix, however, there are formed spaces that are soon occupied by cells and vessels which grow in from a fibrous-tissue membrane (the future periosteum) surrounding the cartilage fundaments of the bones. These cells deposit a bone matrix in the cartilage spaces. Bone developed in this manner is known as *endochondral* or *intracartilaginous* bone. In certain bones—namely, those of the vault of the skull and nearly all the bones of the face—there is no preformation in cartilage, these bones being developed from a connective-tissue foundation. They are known as *intramembranous* bones. As will become evident upon further discussion of the subject, the formation of fibrous-tissue bone (intramembranous) is not confined to bones *not* preformed in cartilage. In bones preformed in cartilage, fibrous-tissue bone develops from the connective-tissue membrane surrounding the cartilage fundaments, the two types of bone-development going on simultaneously in such bones. Attention may further be drawn to the fact that nearly all endochondral bone is absorbed, so that the greater portion of all adult bone, even that preformed in cartilage, is developed from a foundation of fibrous tissue. The two modes of ossification—endochondral or intracartilaginous and intramembranous—even though appearing simultaneously in the majority of bones, will, for the sake of clearness, be discussed separately.

1. **Endochondral Bone-development.**—The cartilage that forms the fundaments of the bones preformed in cartilage has at first the appearance of embryonic cartilage, consisting largely of cells with a small amount of intercellular matrix. These fundaments are surrounded by a fibrocellular membrane—the perichondrium. Ossification is initiated by certain structural changes in the embryonic cartilage, in one or several circumscribed areas, known as *centers of ossification*. In the long bones a center of ossification appears in the middle of the future diaphysis. In this region the intercellular matrix increases in amount and the cells in size ; thus the embryonic cartilage assumes the character of hyaline cartilage. This is followed by a further increase in the size of the cartilage-cells, at the expense of the thinner partitions of matrix separating neighboring cells, while at the same time lime granules are deposited in the matrix remaining. During this stage the cells appear first vesicular, distending their capsules, then shrunken, only partly filling the enlarged lacunæ. They stain less deeply, and their nuclei show degenerative changes. The center of ossification, in the middle of which these changes are most pronounced, is surrounded by a zone in which these structural changes are not so far advanced and which has the appearance at its periphery of hyaline cartilage.

Simultaneously with these changes in the cartilage, a thin layer

of bone is deposited by the perichondrium (in a manner to be described under the head of intramembranous bone-development) and the perichondrium becomes the periosteum. This in the meantime has differentiated into two layers—an outer, consisting largely of fibrous tissue with few cellular elements, and an inner, the osteogenetic layer, vascular and rich in cellular elements and containing few fibrous-tissue fibers.

Ossification in the cartilage begins after the above-described

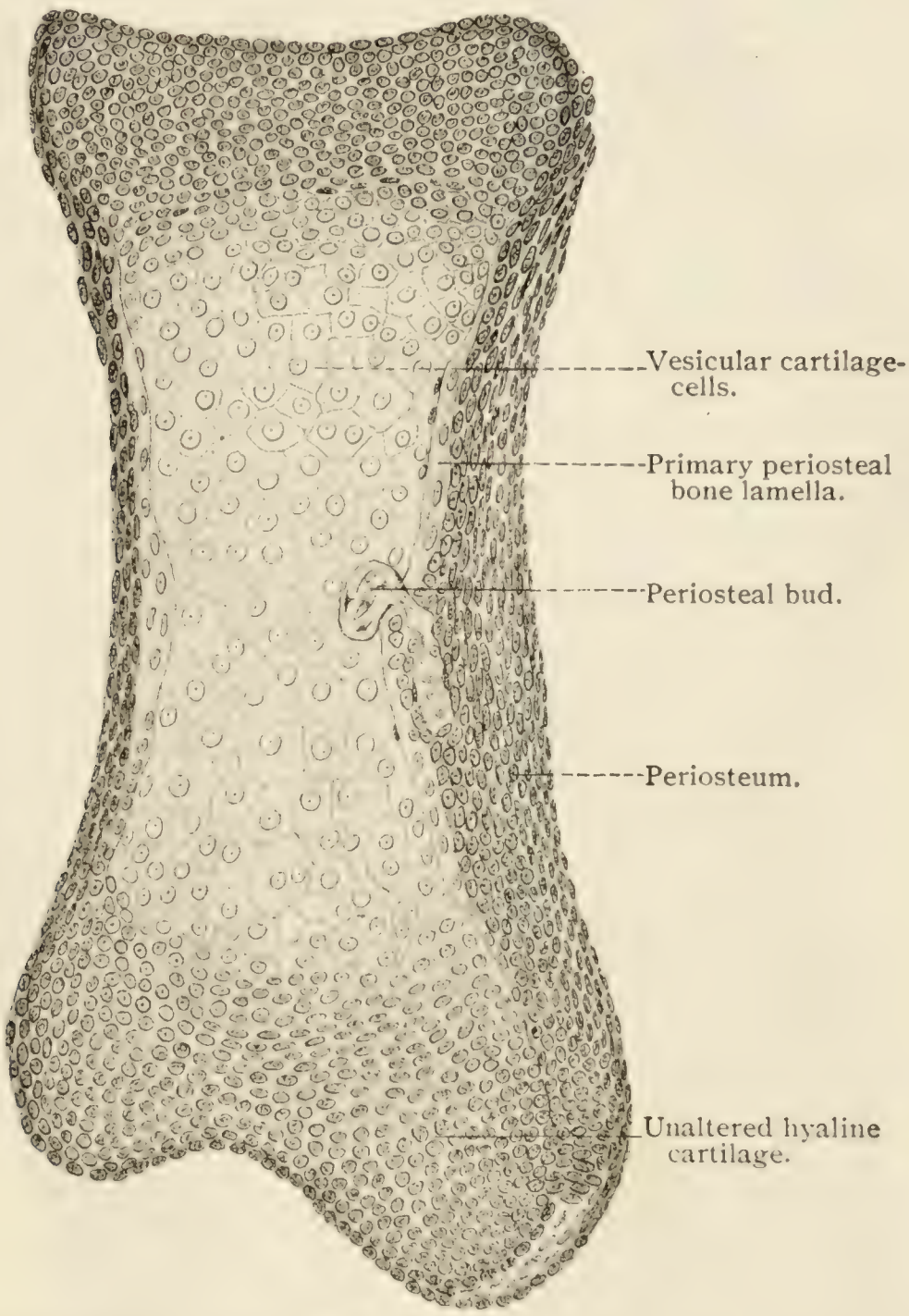

Fig. 85.—Longitudinal section through a long bone (phalanx) of a lizard embryo. The primary bone lamella originating from the periosteum is broken through by the periosteal bud. Connected with the bud is a periosteal blood-vessel containing red blood-corpuscles.

structural changes have taken place at the center of ossification. Its commencement is marked by a growing into the cartilage of one or several buds or tufts of tissue derived principally from the osteogenetic layer of the periosteum. As the periosteal buds grow into the cartilage, some of the septa of matrix separating the altered cartilage-cells disappear, and the cells become free and probably degenerate. In this way the cartilage at the center of ossi-

fication becomes hollowed out, and there are formed irregular anastomosing spaces, *primary marrow spaces*, separated by partitions or trabeculæ of calcified cartilage matrix. Into these primary marrow spaces grow the periosteal buds, consisting of small blood-vessels, cells, and some few connective-tissue fibers, forming embryonic marrow tissue. Some of the cells which have thus grown into

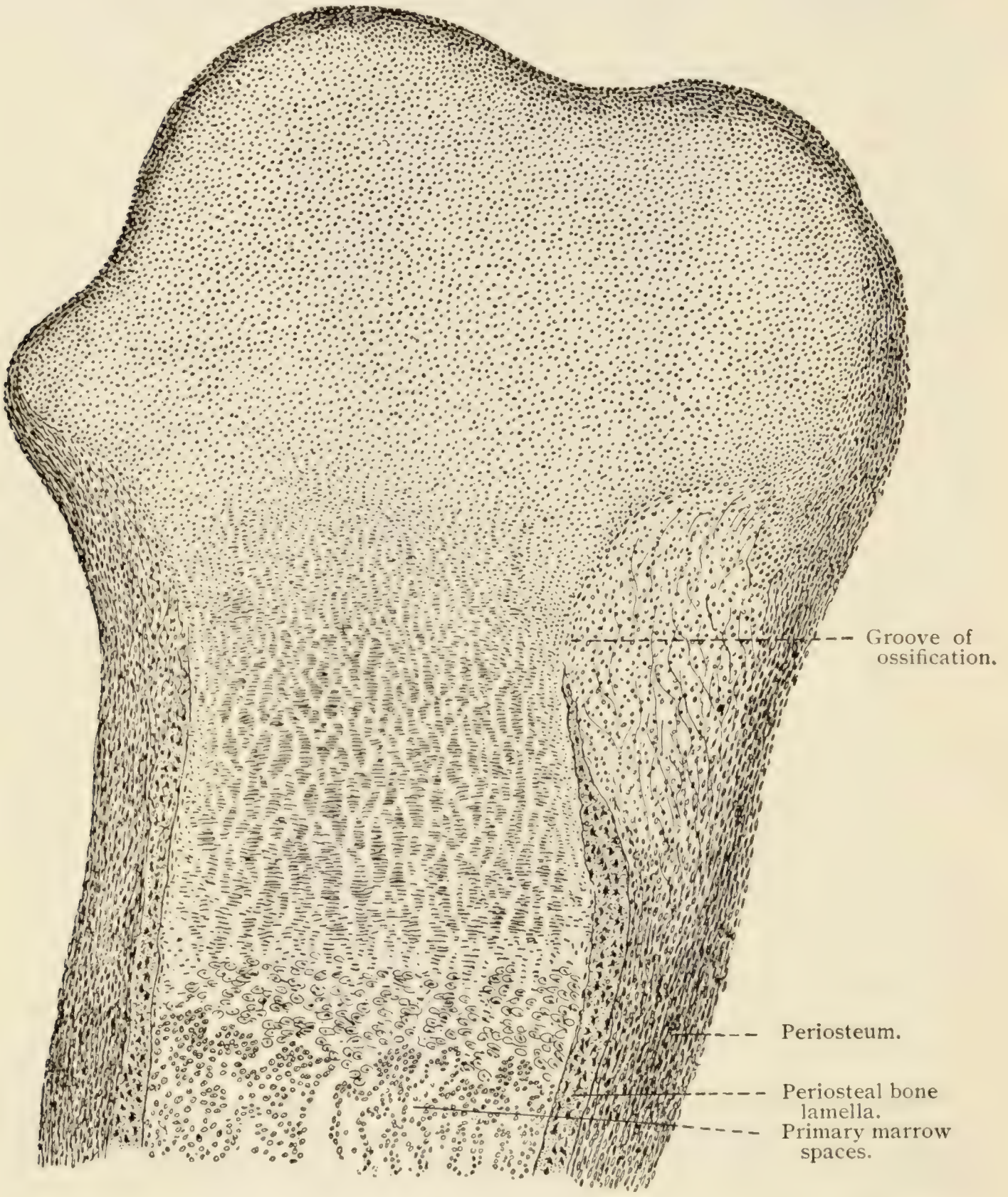

Fig. 86.—Longitudinal section of the proximal end of a long bone (sheep embryo); × 30.

the primary marrow spaces arrange themselves in layers on the trabeculæ of calcified matrix, which they envelop with a layer of osseous matrix formed by them. The cells thus engaged in the formation of osseous tissue are known as *osteoblasts*.

Ossification proceeds from the center of ossification toward the

extremities of the diaphysis (in a long bone), and is always preceded as at the center of ossification, by the characteristic structural changes above described. Beginning at the center of ossification and proceeding toward either extremity of the diaphysis, the enlarged and vesicular cartilage-cells will be observed to be arranged in quite regular columns, separated by septa or trabeculæ of calcified cartilage matrix. The cells thus arranged in columns show the degenerative changes above described. They are shrunken and flattened, and their nuclei, when seen, stain less deeply than the nuclei of normal cartilage-cells. Beyond this zone of columns of altered cartilage-cells are found smaller or larger groups of less changed cartilage-cells, and beyond this zone, hyaline cartilage.

Fig. 87.—Longitudinal section through area of ossification from long bone of human embryo.

The arrangement of the cartilage-cells in the columns above mentioned is, according to Schiefferdecker, mainly due to two factors — the current of lymph plasma which flows from the center of ossification toward the two extremities of the cartilage fundament, and the mutual pressure exerted by the groups of cartilage-cells in their growth and proliferation. Ossification proceeds from the center of the diaphysis toward its two extremities by a growth of osteoblasts and small vessels into the columns of cartilage-cells. Here, also, these degenerate, leaving in their stead irregular, oblong, anastomosing spaces, separated by septa and trabeculæ of calcified cartilage matrix on which the osteoblasts arrange themselves in layers, and which they envelop in osseous tissue. In a longitudinal section of a long bone, preformed in cartilage, the various steps of endochondral bone-development may, therefore, be observed by viewing the preparation from either end to the center of the diaphysis, as may be seen in figures 86, 87. The former represents the appearance as seen under low magnification, the latter a small portion of such a section from the area of ossification, more highly magnified.

Adjoining the primary marrow spaces is vesicular cartilage and columns and groups of cartilage-cells and finally hyaline cartilage.

In the upper portion of figure 87 is observed a zone composed of groups of cartilage-cells, adjoining this a zone composed of columns of vesicular and shrunken cartilage-cells, the nuclei of which are indistinctly seen. These columns are separated by septa and trabeculæ of calcified matrix. This zone is followed by one in which the cartilage-cells have disappeared, leaving spaces into which the osteoblasts and small blood-vessels have grown. In certain parts of the figure, the osteoblasts are arranged in a layer on the trabeculæ of calcified cartilage, some of which are enveloped in a layer of osseous matrix, less deeply shaded than the darker cartilage remnants.

As the development of endochondral bone proceeds from the center of ossification toward the extremities of the diaphysis in the manner described, the primary marrow spaces at the center of ossification are enlarged, a result of an absorption of many of the smaller osseous trabeculæ and the remnants of calcified cartilage matrix enclosed by them. In this process are concerned certain large and, for the most part, polynuclear cells, which are differentiated from the embryonic marrow. These are the *osteoclasts* (bone breakers) of Kölliker (73). They are 43 μ to 91 μ long and 30 μ to 40 μ broad, and have the function of absorbing the bone. The spaces which they hollow out during the beginning of the process appear as small cavities or indentations, containing osteoclasts either single or in groups, and are known as *Howship's lacunæ*. All bone absorption goes hand in hand with their appearance. At the same time, the osseous trabeculæ not absorbed become thickened by a deposition of new layers of osseous tissue (by osteoblasts), during which process some of the osteoblasts are enclosed in the newly formed bone and are thus converted into bone-cells. In this way there is formed at the center of ossification a primary or embryonic spongy or cancellous bone, surrounding *secondary marrow spaces* or *Haversian spaces*, filled with embryonic marrow. This process of the formation of embryonic cancellous bone follows the primary ossification from the center of ossification toward the extremities of the diaphysis. It should be further stated, that long before the developing bone has attained its full size—indeed, before the end of embryonic life—the embryonic cancellous bone is also absorbed through the agency of osteoclasts. The Haversian spaces are thus converted into one large cavity, which forms a portion of the future marrow cavity of the shaft of the fully developed bone. The absorption of the embryonic cancellous bone begins at the center of ossification and extends toward the ends of the diaphysis.

Some time after the beginning of the process of bone development at the center of ossification of the diaphysis, centers of ossification appear in the epiphyses, the manner of the development of bone being here the same as in the diaphysis. Several periosteal buds grow into each center of ossification, filling the irregular spaces formed by the breaking down of the degener-

ated cartilage-cells. Osteoblasts are arranged in rows on the trabeculæ of cartilage thus formed, which they envelop in osseous tissue. As development proceeds, the primary osseous tissue is converted into embryonic cancellous bone as above described.

In the development of the epiphyses, as in the development of the smaller irregular bones, the formation of bone proceeds from the center or centers of ossification in all directions, and not only in a direction parallel to the long axis of the bone as described for the diaphysis. The epiphyses grow, therefore, in thickness as well as in length, by endochondral bone-development.

There remains between the osseous tissue developed in the diaphysis and that in the epiphyses, at each end of the diaphysis, a zone of hyaline cartilage in which ossification is for a long time delayed ; this is to permit the longitudinal growth of the bone. These layers of cartilage constitute the epiphyseal cartilages. Here the periosteum (perichondrium) is thickened and forms a raised ring around the cartilage. As it penetrates some distance into the substance of the cartilage, the latter is correspondingly indented. (Fig. 86.) The impression thus formed appears in a longitudinal section of the bone as an indentation,—the *ossification groove* (*encoche d'ossification*, Ranvier, 89). That portion of the perichondrium filling the latter is called the *ossification ridge*. The relation of the elements of the perichondrium to the cartilage in the region of the groove just described is an extremely intimate one, both tissues, perichondrium and cartilage, merging into each other almost imperceptibly. It is a generally accepted theory that so long as the longitudinal growth of the bone persists, new cartilage is constantly formed at these points by the perichondrium. In the further production of bone this newly developed cartilage passes through the preliminary changes necessary before the actual commencement of ossification —*i. e.*, it goes through the stages of vesicular cartilage and the formation of columns of cartilage-cells, in place of which, later, the osteoblasts and primary marrow cavities develop.

By the development of new cartilage elements from the *encoche* the longitudinal growth of the bone is made possible ; at the same time, those portions of the cartilage thus used up in the process of ossification are immediately replaced. (Fig. 88.)

The following brief summary of the several stages of endochondral bone-development may be of service to the student :

1. The embryonic cartilage develops into hyaline cartilage, beginning at the centers of ossification.

2. The cartilage-cells enlarge and become vesicular. In the diaphysis of long bones such cells are arranged in quite regular columns, while in the epiphyses and irregular bones this arrangement is not so apparent.

3. Calcification of the matrix ensues ; the cartilage-cells disappear (degenerate) ; primary marrow spaces develop.

4. Ingrowth of periosteal buds. The osteoblasts are arranged

in layers on the trabeculæ of calcified cartilage, which they envelop with osseous tissue.

5. Osteoclasts cause the absorption of many of the smaller osseous trabeculæ; others become thickened by a deposition of new layers of osseous tissue. Osteoblasts are enclosed in bone-tissue and become bone-cells. In this way there is formed embryonic cancellous bone, bounding Haversian spaces inclosing embryonic marrow.

6. In the diaphysis, the greater portion of the embryonic cancellous bone is also absorbed (by osteoclasts); the Haversian spaces unite to form a part of the marrow space of the shaft of the bone.

2. **Intramembranous Bone.**—This, the simpler type of ossification, occurs in bone developed from a connective-tissue foundation, and is exemplified in the formation of the bones of the

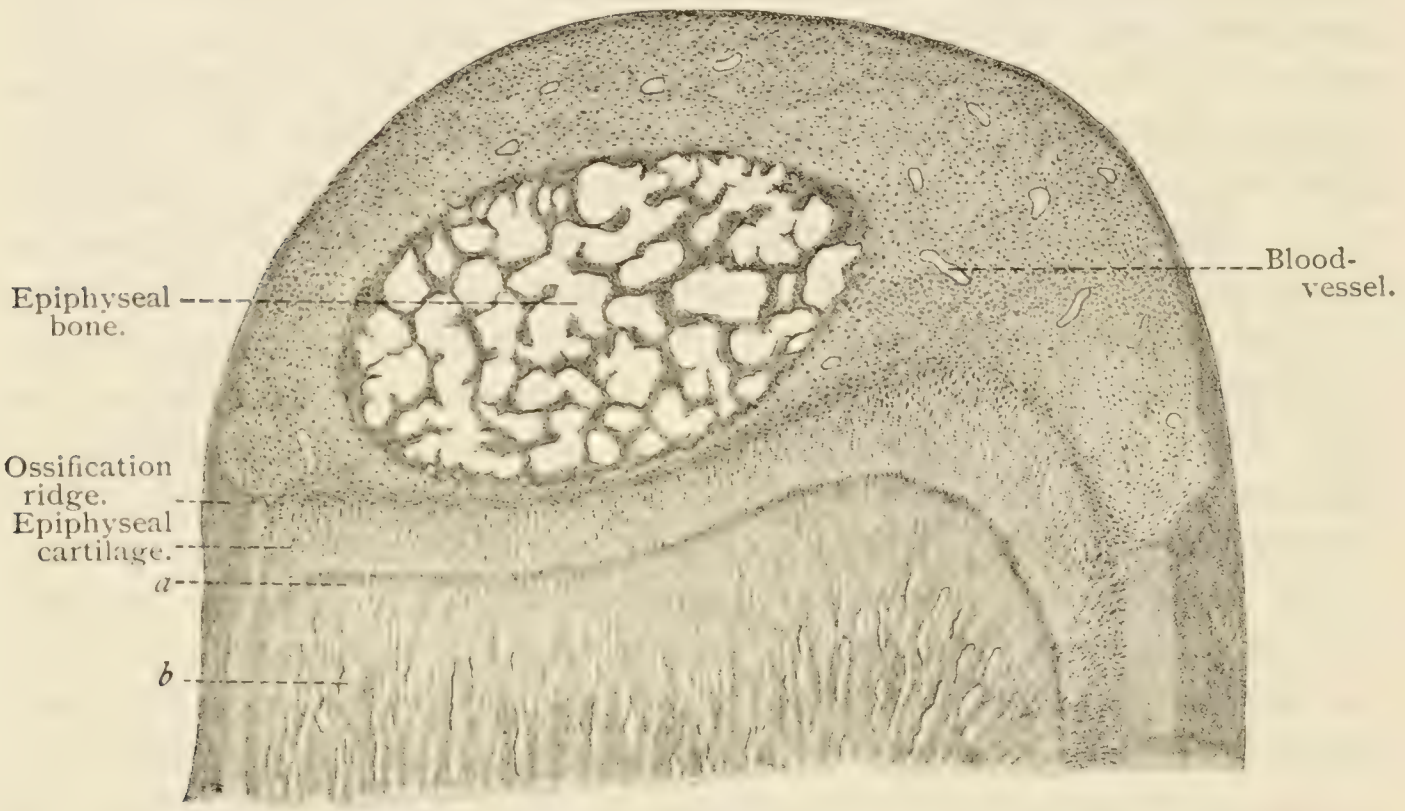

Fig. 88.—Longitudinal section through epiphysis of arm bone of sheep embryo; × 12.
a, *b*, Primary marrow spaces and bone lamellæ of the diaphysis.

cranial vault and the greater number of the bones of the face, and also in bone developed from the periosteum (perichondrium) surrounding the cartilage fundaments of endochondral bone. All fibrous-tissue bone is developed in the same way.

The intramembranous bone-development begins by an approximation and more regular arrangement of the osteoblasts of the osteogenetic layer of the periosteum about small fibrous-tissue bundles. The osteoblasts then become engaged in the formation of the osseous tissue which envelops the fibrous-tissue bundles. In this way a spongy bone with large meshes is formed, consisting of irregular osseous trabeculæ, surrounding primary marrow spaces. These latter are filled by embryonic marrow and blood-vessels developed from the tissue elements of the periosteum not engaged in the formation of bone.

Intramembranous bone first appears in the form of a thin lamella of bone, which increases in size and thickness by the formation of trabeculæ about the edges and surfaces of that previously formed and in the manner above described. A layer of intramembranous bone thus surrounds the endochondral bone in bones preformed in hyaline cartilage. The two modes of ossification may, therefore, be observed in either a cross or a longitudinal section of a developing bone preformed in hyaline cartilage. In such preparations the endochondral bone can be readily distinguished from the intra-

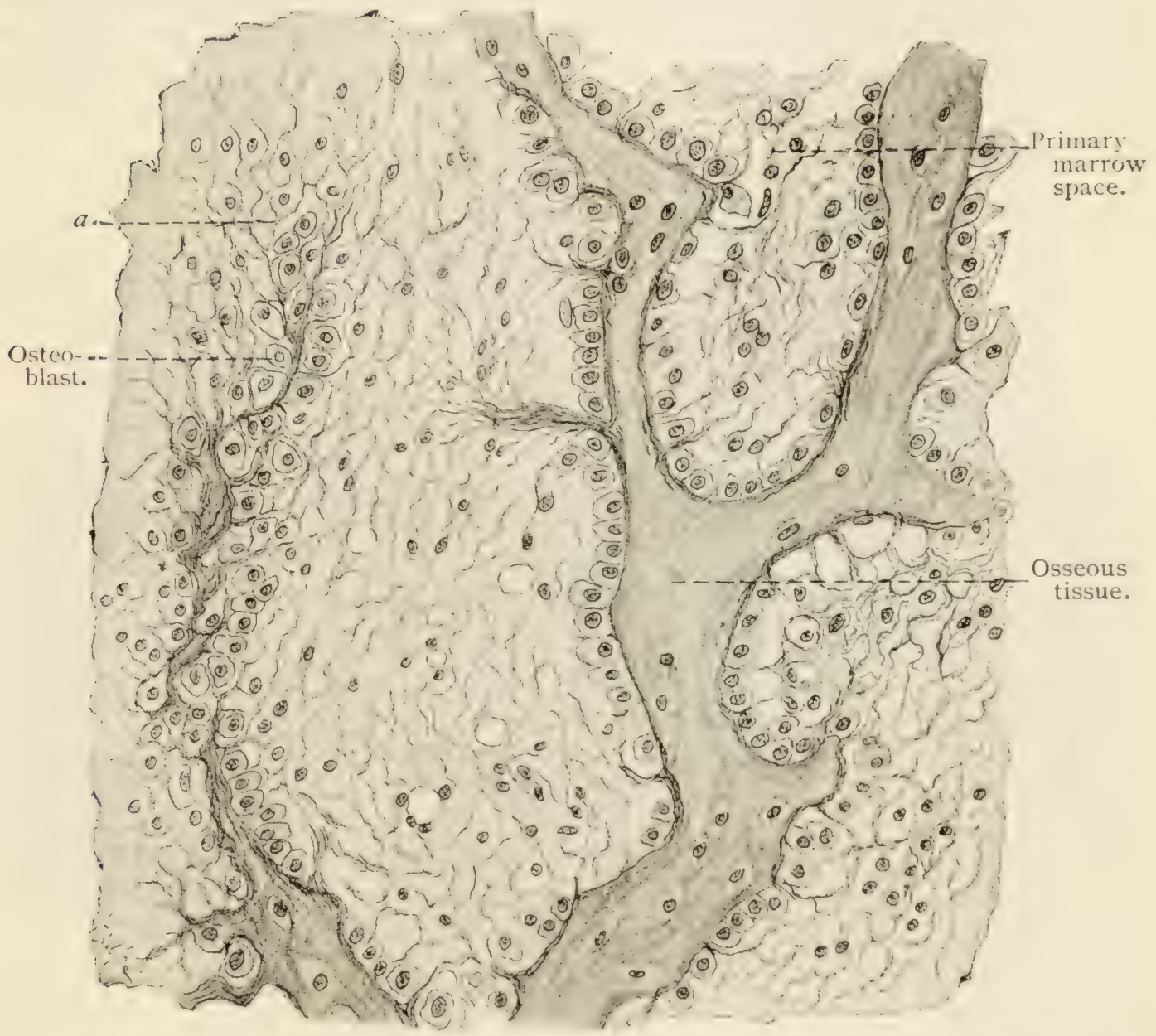

Fig. 89.—Section through the lower jaw of an embryo sheep (decalcified with picric acid); × 300. At *a* and immediately below are seen the fibers of a primitive marrow cavity lying close together and engaged in the formation of the ground-substance of the bone, while the cells of the marrow cavity, with their processes, arrange themselves on either side of the newly formed lamella and functionate as osteoblasts.

membranous bone by reason of the fact that remnants of calcified cartilage matrix may be observed in the osseous trabeculæ of the former. It will be remembered that these osseous trabeculæ develop about the calcified cartilage matrix remaining after the disappearance of the cartilage-cells. In figure 90, which shows a cross-section of a bone from the leg of a human embryo, these facts are clearly shown. A study of this figure shows the endochondral bone, with the remnants of the cartilage matrix (shaded more

deeply) inclosed in osseous tissue, making up the greater portion of the section and surrounded by the intramembranous bone.

In figure 91, more highly magnified, the relations of endochondral to intramembranous bone and the details of their mode of development are shown ; also the structure of the periosteum.

As was stated in the previous section, soon after the formation of the endochondral bone, this is again absorbed ; the process of endochondral bone-formation and absorption extending from the center of ossification toward the ends of the diaphysis. Before the absorption of the endochondral bone, the intramembranous bone has attained an appreciable thickness and surrounds the marrow cavity formed on the absorption of the endochondral bone. Before,

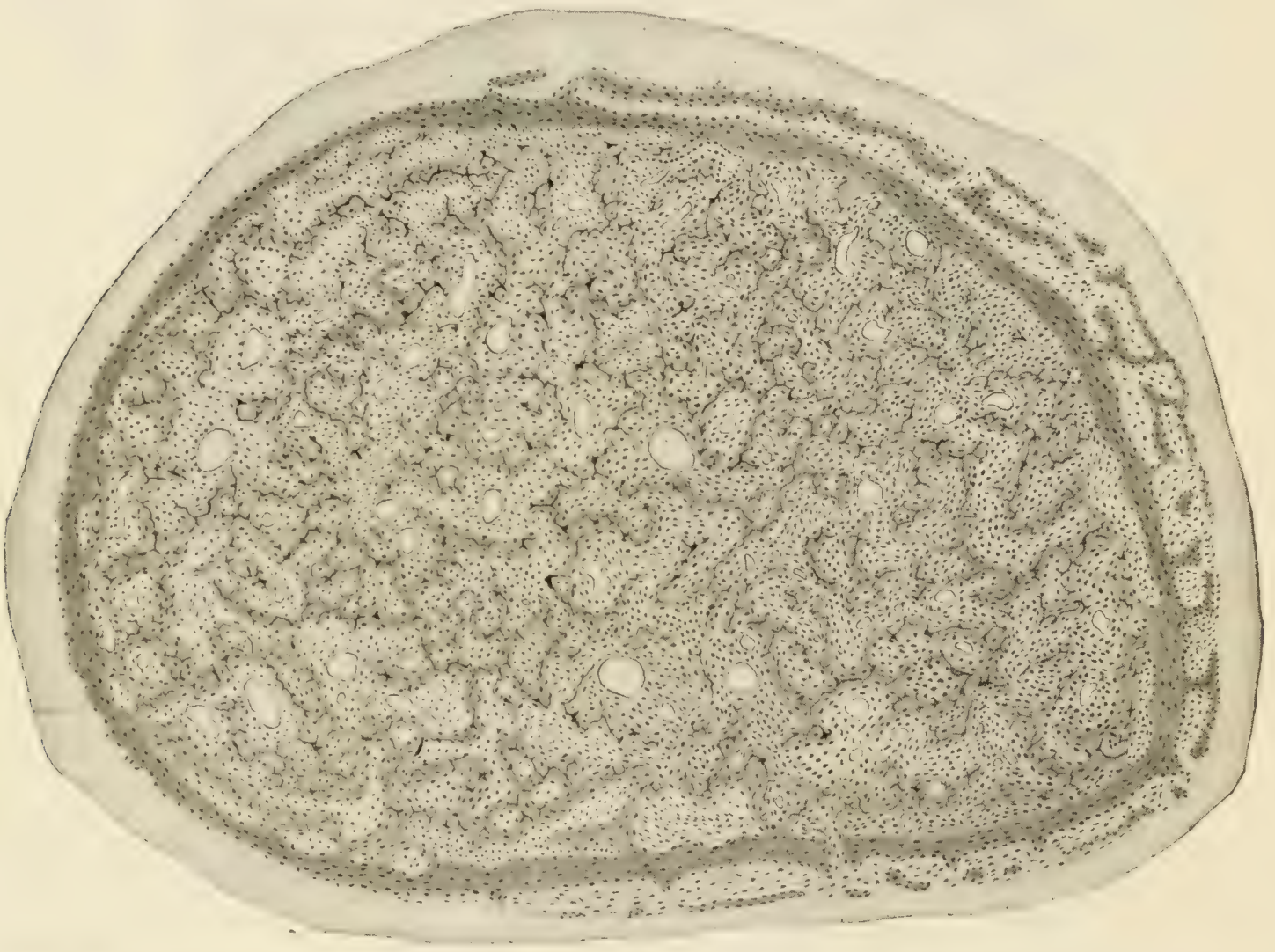

Fig. 90.—Cross-section of developing bone from leg of human embryo, showing endochondral and intramembranous bone-development.

however, the marrow cavity can attain its full dimensions, much of the intramembranous bone must also undergo absorption. While intramembranous bone is being developed from the periosteum and thus added to the outer surface of that already formed, osteoclasts are constantly engaged in its removal from the inner surface of the intramembranous bone. The marrow cavity is thus enlarged, the process continuing until the shaft attains its full size.

The compact bone of the shaft is developed from the primary spongy intramembranous bone after the following manner : The primary marrow spaces are enlarged by an absorption, through the agency of osteoclasts, of many of the smaller trabeculæ of osse-

ous tissue and by a partial absorption of the larger ones, the primary marrow spaces thus becoming secondary marrow spaces, or Haversian spaces. The osteoblasts now arrange themselves in layers

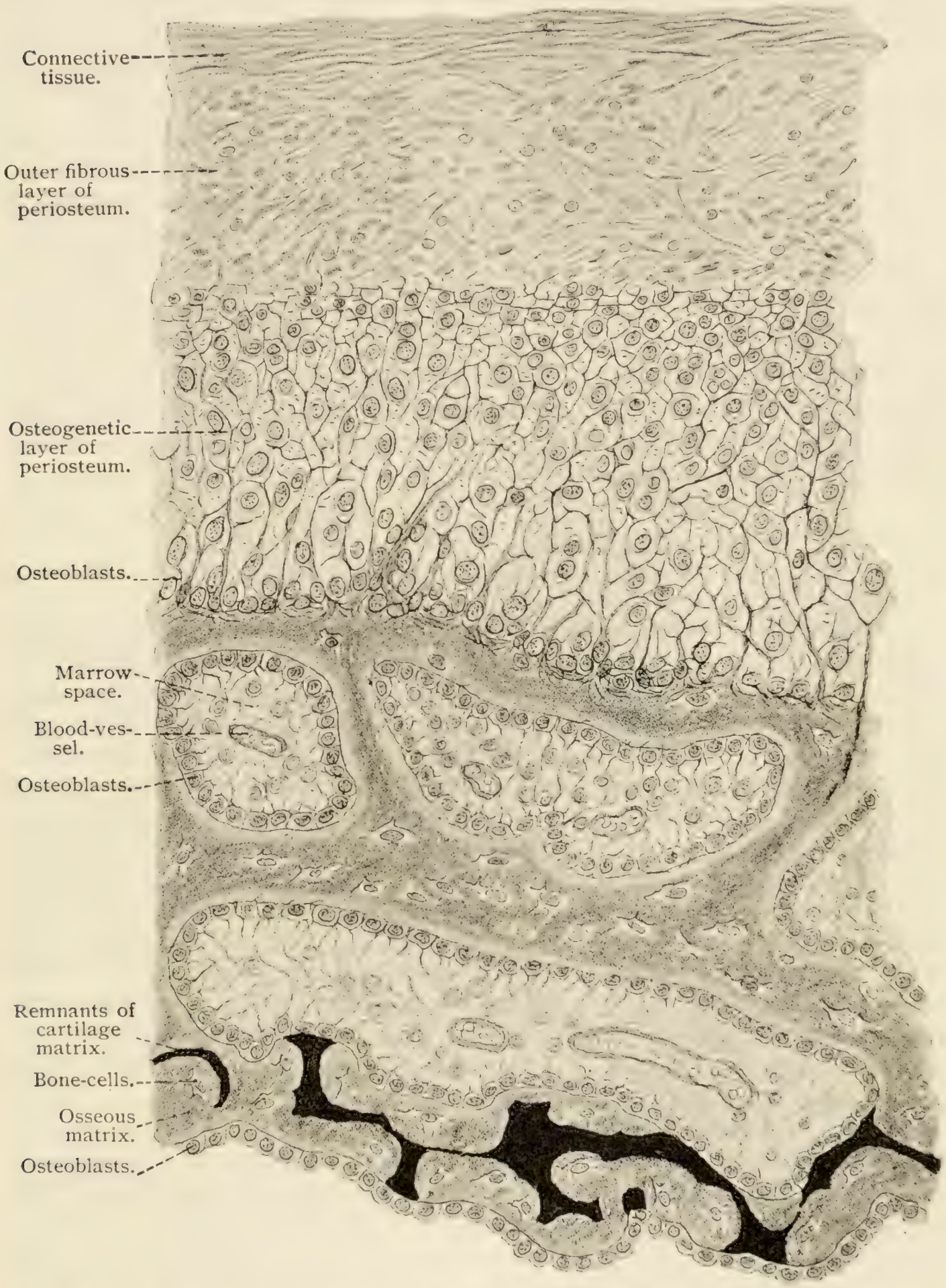

Fig. 91.—From a cross-section of a shaft (tibia of a sheep); × 550. In the lower part of the figure is endochondral bone-formation (the black cords are the remains of the cartilaginous matrix); in the upper portion is bone developed from the periosteum.

about the walls of the Haversian spaces and deposit lamella after lamella of bone matrix, concentrically arranged, until the large Haversian spaces have been reduced to Haversian canals. During

this process many of the osteoblasts become inclosed in bone matrix, forming bone-cells and the blood-vessels of the Haversian spaces remain as the vessels found in the Haversian canals. The spongy intramembranous bone not absorbed at the commencement of the formation of the system of concentric lamellæ, remains between the concentric systems as interstitial lamellæ. The circumferential lamellæ are those last formed by the periosteum. Calcification of the osseous matrix takes place after its formation by the osteoblasts.

From what has been stated it may be seen that the shafts of the long bones and bones not preformed in cartilage develop by the process of intramembranous bone-formation, while the cancellous bone in the ends of the diaphysis and in the epiphyses is endochondral bone. Further, that long bones grow in length by endochondral bone-development, and in thickness by the formation of intramembranous bone. In the development of the smaller irregular bones, both processes may be engaged; the resulting bone can not, however, be so clearly defined.

TECHNIC.

Ranvier's Method.—One of the methods for examining connective-tissue cells and fibers is that recommended by Ranvier (89); it is as follows: The skin of a recently killed dog or rabbit is carefully raised, and a 0.1% aqueous solution of nitrate of silver injected subcutaneously by means of a glass syringe. The result is an edematous swelling in which the connective-tissue cells and fibers (the latter somewhat stretched) come into immediate contact with the fixing fluid and are consequently preserved in their original condition. In about three-quarters of an hour the whole elevation should be cut out (it will not now collapse) and small fragments placed upon a slide and carefully teased. Isolated connective-tissue cells with processes of different shapes, having the most varied relations to those from adjacent cells, are seen. The fibers themselves either consist of several fibrils, or, if thicker, are often surrounded by a spirally encircling fibril. By this method numerous elastic fibers and fat-cells are also brought out. If a drop of picrocarmin be added to such a teased preparation and the whole allowed to remain for twelve hours in a moist chamber, and formic glycerin (a solution of 1 part formic acid in 100 parts glycerin) be then substituted for twenty-four hours, the following instructive picture is obtained: All nuclei are colored red, the white fibrous connective-tissue fibers pink, the fibrils encircling the latter brownish-red, and the elastic fibers canary yellow. The peripheral protoplasm of the fat-cells is particularly well preserved, a condition hardly obtainable by any other method.

Connective tissue with a parallel arrangement of its fibers is best studied in tendon, those in the tails of rats and mice being particularly well adapted to this purpose. If one of the distal vertebræ of the tail be loosened and pulled away from its neighbor, the attached tendons will become separated from the muscles at the root of the tail and appear as thin glistening threads. These are easily teased on a slide into fibers and

LIBRARY

fibrils. Such preparations are also useful in studying the action of reagents (see below).

The substance resembling mucin which cements the fibrillæ together is soluble in lime-water and baryta-water—a circumstance made use of and recommended by Rollet (72, II) as a method for the isolation of connective-tissue fibrils. In necrotic tissue the fibers show a degeneration into fibrils (Ranvier, 89).

If connective tissue be heated in water or dilute acids to 120° C., and the fluid then filtered, a solution is obtained from which collagen can be precipitated by means of alcohol. This is insoluble in cold water, alcohol, and ether, but is soluble in hot water and when dissolved in the latter and cooled, becomes transformed into a gelatinous substance. Unlike mucin and chondrin this substance does not precipitate on the addition of acetic and mineral acids. Tannic acid and corrosive sublimate will cause precipitation, as also in the case of chondrin, but *not* with mucin (*vid.* also Hoppe-Seyler).

Elastic tissue may be obtained by treating connective tissue with potassium hydrate solution, and if the alveoli of the lungs be treated for some time with this reagent, very small elastic fibers can be obtained. By this means the connective-tissue fibers are dissolved, but not the elastic fibers. Particularly coarse fibers are found in the ligamenta subflava.

According to Kühne, connective and elastic tissues are differently affected by **trypsin digestion**—*i. e.*, alkaline glycerin-pancreas extract at 35° C.—white fibrous connective tissue being resolved into fibrils, while elastic tissue is entirely dissolved.

To F. P. Mall also belongs the credit for a few data, which we insert, as to the different reactions which various connective-tissue substances show when treated by the same reagents.

When a tendon is boiled it becomes shorter, but if it be fixed before boiling, there is no change. Adenoid reticulum shrinks when boiled, but after a short time swells, and finally dissolves. Both tendon and adenoid reticulum shrink at 70° C. If, however, they be first treated with a 0.5% solution of osmic acid, the shrinkage will not take place until 95° C. is reached. If the reticulum or the tendon has become shrunken through heat, they are easily digested with pancreatin, and putrefy very readily. Tendon fibers do not become swollen in glacial acetic acid, either concentrated or in strengths of 0.05% or less, but in strengths of 0.5% to 25% they swell, and if placed in a 25% solution they will dissolve in twenty-four hours. They also swell in hydrochloric acid in strengths of 0.1% to 6%. In strengths of 6% to 25% the fibers remain unchanged for some time, and only dissolve in a concentrated solution of this acid. Reticulated tissue, on the other hand, swells in a 3% hydrochloric acid solution, but remains unchanged in strengths of 3% to 10%. It dissolves in twenty-four hours in solutions of 25% and over. After treatment with a dilute solution of acid, tendon dissolves more rapidly on boiling than does reticular tissue.

Tendon exposed to the action of the gastric juice of a dog does not dissolve more rapidly than elastic tissue ; but if placed in an artificial solution of gastric juice, tendon dissolves first, then reticular tissue, and finally elastic fibers. Pancreatin affects neither tendon nor reticulated tissue, but if boiled, both tissues are easily digested by its action. If taken out of the body, neither tendon nor reticulum will become affected by putrefaction. In the body, however, and especially at high temperatures (37° C.), both tissues are decomposed within a few days.

Elastic fibers remain unchanged in **acetic acid**, and even when boiled in a 20% solution they only become slightly brittle. They are, however, rapidly destroyed by concentrated hydrochloric acid, although in a 10% solution at ordinary temperature no change is seen. In a 50% solution the fiber is dissolved in seven days, and in a concentrated solution in two days. The inner substance of the fiber is first attacked, then the membrane. To demonstrate this membrane, the fibers are boiled several times in concentrated hydrochloric acid and the whole then poured into cold water. Occasionally, a longitudinal striation of the membrane is seen, indicating a fibrillar structure. Concentrated solutions of potassium hydrate disintegrate the fibers in a few days; weak solutions, more slowly. A 1% solution of potassium hydrate requires months to produce the effect; a 2% solution, one month; a 5%, three days; a 10%, one day; and 20% to 40%, only a few hours. A weak solution of potassium hydrate, even when brought to the boiling-point, does not dissolve elastic fibers, nor does it cause them to become brittle. If, however, they be boiled in a 5% or 10% solution of potassium hydrate, the membranes of the fibers will be isolated. A cold 20% solution has the same effect in one or two days. Pepsin induces a disintegration of the contents of the fiber, leaving the membranes intact.

To demonstrate the inner substance of elastic fibers and their membranes, **magenta red** has been recommended (a small granule is added to 50 c.c. glycerin and 50 c.c. water). By this method the internal substance is colored red while the sheath remains colorless.

Orcein, Unna's Method.—Make a solution consisting of Grübler's orcein 1 part, hydrochloric acid 1 part, absolute alcohol 100 parts. The sections are stained in a porcelain dish. The stain is heated over a flame or in an oven until the stain becomes quite thick. Rinse thoroughly in alcohol, clear in xylol, and mount. Elastic fibers stain a dark brown, white fibrous tissue a light brown.

Fuchsin-resorcin Elastic Fibers Stain (Weigert).—A solution containing 1% of basic fuchsin and 2% of resorcin is made and brought to boiling. To 200 c.c. of this solution there is added 25 c.c. of liquor ferri sesquichlorati (Germ. Pharm.). Boil for about five minutes, stirring the meanwhile. Filter on cooling, and place the filter paper and the precipitate collected in a porcelain dish and add 200 c.c. of 95% alcohol and bring to boiling. Filter on cooling and add to the filtrate 4 c.c. of hydrochloric acid and enough alcohol to bring it up to 200 c.c. Stain sections for about one hour. Sections are then washed in alcohol or acidulated alcohol, or, better still, in alcohol to which a few crystals of picric acid have been added. Clear in xylol and mount. Elastic fibers are stained dark blue or bluish-black if washed in picric alcohol.

Differential Stain for Connective-tissue Fibrillæ and Reticulum (Mallory).—Fix tissues in corrosive sublimate or in Zenker's solution. (Tissues fixed by other methods may also be used, although the results are not quite so satisfactory, if the sections are immersed for fifteen to thirty minutes in a saturated corrosive sublimate solution just before staining.) The sections, which may be cut in celloidin or paraffin, are stained for one to three minutes in a $\frac{1}{10}$% aqueous solution of acid fuchsin, rinsed in water, and placed in a 1% aqueous solution of phosphomolybdic acid for five to ten minutes, and then washed in two changes of water. They are now stained in the following solution for two to twenty

minutes: Grübler's aniline blue soluble in water, 0.5 gm.; Grübler's orange G, 2 gm.; oxalic acid, 2 gm.; distilled water, 100 c.c. After staining, the sections are washed in water and dehydrated in 95% alcohol, blotted on the slide, and cleared in xylol and mounted in xylol balsam. The connective-tissue fibers and reticulum stain blue.

Dr. Sabin's modification of this method deserves mention. Fix in Zenker's fluid, cut in paraffin, and fix sections to the slide with the water method. After removing the paraffin, stain sections in $\frac{1}{10}$% acid fuchsin until red, and without washing fix in a saturated aqueous solution of phosphomolybdic acid diluted ten times for about ten minutes. Wash in 95% alcohol and stain for a very short time in the following solution: Grübler's aniline blue soluble in water, 1 gm.; orange G, 2 gm.; oxalic acid, 2 gm.; boiling water, 100 c.c. Wash in alcohol, blot on the slide, clear in xylol and mount in xylol balsam.

Digestion Method for Demonstrating the Connective-tissue Framework of Organs and Tissues (Mall, Spalteholz, Hoehl, Flint).—For bringing out the framework of white fibrous and reticular fibers of organs and tissues digestion by means of trypsin may be recommended. For the account here given we follow Flint. The tissues are fixed in graded alcohol, corrosive acetic, or Van Gehuchten's chloroform-acetic-alcohol mixture. After complete dehydration, small pieces of tissue, not to exceed 3 mm. in thickness, are placed in paper cups and dropped into a Soxhlet apparatus and extracted with ether for a period of six to eight days in order to free the tissue of the fat. After the fat has been removed, the tissues are brought into water, through graded alcohol, and then digested in pancreatin. (Grübler's pancreatin is recommended; that of Park, Davis & Co. may be used.) The pancreatin solution to be used is made by adding as much pancreatin as can be taken up on the end of an ordinary scalpel handle to 100 c.c. of a 0.5% solution of bicarbonate of soda. This solution is changed every forty-eight hours. To prevent putrefaction enough chloroform is added to cover the bottom of the dish. The digestion is continued until the cellular element has been removed—five to ten days. It is often necessary to repeat the fat extraction and digestion several times. After the cellular elements have been removed the tissue is thoroughly washed in flowing water, and may then be mounted in glycerine and studied with a stereoscopic microscope, or it may be dehydrated and imbedded in celloidin and sectioned. Such sections may then be stained in fuchsin and thoroughly washed in alcohol; this removes the stain from the celloidin, leaving only the connective tissue stained.

Slide Digestion.—The method may also be applied for digesting tissues on the slide. Fix as above described, imbed in paraffin, and cut very thin sections which are fixed to the slide by the water method. Remove the paraffin and place the sections from alcohol into the Soxhlet apparatus, where they are extracted with ether for a number of hours. Bring the sections through graded alcohol into water, in which they remain several hours. The sections are now digested in the above-mentioned pancreatin solution for several hours to several days, or until the cellular elements have been removed. Wash carefully in water. The remaining connective tissue may now be stained in iron-lac hematoxylin or in an aqueous solution of toluidin blue or in an aqueous solution of fuchsin. Dehydrate, clear, and mount.

Fresh adipose tissues can be obtained in lobules and in small groups of cells from the mesenteries of small animals. As a rule, the highly refractive fat globule hides from view the nucleus and protoplasm of the cell. The latter structures can be brought out by the subcutaneous injection of silver nitrate solution, this forming the edematous elevation previously described. Fresh fat is soluble in ether and chloroform, especially if the latter be heated. Strong sulphuric acid does not dissolve fat. The stains made from the root of the henna plant color fat red (the color disappearing in ethereal oils). Quinolin-blue, dissolved in dilute alcohol, stains fat a dark blue. If a 40% potassium hydrate solution be then added, everything will become decolorized except the fat. The most important reagent for demonstrating adipose tissue is osmic acid (and its mixtures). Small pieces of adipose tissue are treated for twenty-four hours with a 0.5% to 1% osmic acid solution; if mixtures containing osmic acid be used, the specimens are generally immersed for a somewhat longer period. The pieces are then washed with water, and should not be placed directly into alcohol of full strength, as all the structures would then become intensely black (Flemming, 89), but carried into alcohols of ascending strength. When treated in this way the globules of fat take a more intense stain than the other tissues, which, nevertheless, are blackened to some extent. Fat that has been subjected to **osmic acid treatment** dissolves readily in turpentine, xylol, toluol, ether, and creosote, with difficulty in oil of cloves, and not at all in chloroform. Such preparations are best carried from chloroform into paraffin. Fat that has been stained with osmic acid can be decolorized by nascent chlorin. The specimens are placed in a jar of alcohol in which crystals of potassium chlorid have been previously placed. Hydrochloric acid is then added (to 1%) and the vessel tightly sealed (P. Mayer, 81).

L. Daddi has recently recommended **Sudan III** as a stain for fat. This reagent can be applied in two ways: (1) Either the animals are fed with the coloring matter for some days, in which case all the fat will be colored red, or (2) either fresh or fixed pieces of tissue or sections are stained. Fixation before staining must be done in media that do not dissolve fat, as, for instance, Müller's fluid. A saturated alcoholic solution of the stain is used and allowed to act from five to ten minutes. The specimen is then washed with alcohol and mounted in glycerin. The author's experiments with Sudan have been very satisfactory.

Thin lamellæ of fresh cartilage are examined after separating them from the soft parts and placing them in indifferent fluids. Cartilage removed from the hyposternum or episternum or scapula of a frog is especially adapted for examination. Larger pieces of uncalcified cartilage may be used if cut into sufficiently thin sections with a razor moistened with an indifferent fluid. Under the microscope such sections show a finely punctated background with capsules containing cartilage-cells, provided the latter have not fallen out in the process of cutting, in which case lacunæ will be observed.

Osmic acid and corrosive sublimate are by far the best fixing agents for cartilage. If the cartilage be calcified, it is fixed for some time in picric acid, which at the same time acts as a decalcifying agent. Although alcohol fixes cartilage fairly well, it causes shrinkage of the

cells. The ground substance may be specifically colored by certain reagents, safranin producing an orange and hematoxylin a blue stain.

On treating cartilage by certain methods, systems of lines appear in its ground substance, possibly indicating a **canalicular system** in the cartilage. In order to make these structures visible, Wolters recommends staining thin sections for twenty-four hours in a dilute solution of Delafield's hematoxylin (violet blue). They are then treated with a concentrated alcoholic solution of picric acid.

The capsules are seen to best advantage if small pieces of cartilage are treated with a 1% solution of **gold chlorid.**

Connective-tissue and elastic fibers in cartilage are easily demonstrated by staining the specimens with **picrocarmin.** The connective-tissue fibers are colored a pale pink, the elastic fibers yellow. The latter may also be stained with a 1% aqueous solution of acid fuchsin.

If a section of fresh cartilage be placed in a weak solution of **iodo-iodid of potassium** (Lugol's solution), glycogen can sometimes be seen in the cartilage-cells, stained a peculiar mahogany brown. If elastic fibers be present, they also are stained brown, but of a different shade.

Thin bone lamellæ, such as occur in the walls of the ethmoidal cells, can be cleaned of all the soft parts and examined without further manipulation. If larger bones are scraped with a sharp knife, pieces suitable for microscopic examination are sometimes obtained.

Microscopic Preparation of Undecalcified Bone.—A long bone is thoroughly freed from fat and other soft parts by allowing it to macerate, after which it is thoroughly washed and dried, thus freeing it from its organic material. Then, by means of two parallel cuts with a saw, as thin a disc as possible is cut out. The section is now ground still thinner, either between two hones or upon a piece of glass covered with emery. One surface of the bone is then polished and fastened by means of heated Canada balsam to a thick square plate of glass with the polished side toward the glass. Care should be taken that no air-bubbles are inclosed between the section and the glass. As soon as the specimen is firmly adherent, the other side is ground upon the emery plate or hone, during which manipulation the glass to which the bone has been fastened is held between the fingers. As soon as the section is sufficiently thin and transparent, it is polished. In order to remove the Canada balsam and powdered bone from the section, the glass and bone are dried and placed in some solvent of Canada balsam, such as xylol. This loosens the specimen from the glass, after which it is immersed in absolute alcohol, thoroughly washed, and dried in the air. On examining the bone through the microscope, its lacunæ will appear black on a colorless background. The reason is, that the air has taken the place of the evaporated alcohol and the spaces appear black by direct light. Sections thus prepared may be permanently mounted as follows: Small pieces of dry Canada balsam are placed both upon a slide and a cover-glass and warmed until they have become fluid, then allowed to cool until a thin film forms over the balsam; the bone disc is then placed upon the balsam on the slide and quickly covered with the cover-glass. A firm pressure will evenly distribute the balsam, and if

the whole has been done with sufficient rapidity the air will have been caught in the open spaces of the bone before the Canada balsam has had a chance to enter these spaces.

Other substances may be used to demonstrate the spaces in bone. Ranvier (75) recommends the following method: A few c.c. of a concentrated alcoholic solution of anilin blue (which is soluble in alcohol and not soluble in water and sodium chlorid solution) are placed in an evaporating dish containing the dry bone. The solution is very carefully evaporated, as the alcohol may otherwise ignite. The specimen, which will soon be covered on both surfaces by a blue powder, is taken out and ground upon a rough glass plate until thoroughly clean. While being polished the bone should be kept moist by a solution of sodium chlorid. On heating in the evaporating dish, the air is driven from the spaces and replaced by the anilin blue. As already stated, anilin blue is insoluble in sodium chlorid solution, and it therefore remains unaffected by the latter during the process of grinding and cleaning. Hence it remains in the lacunæ and canaliculi of the bone, which then appear blue. The specimen may either be mounted in glycerin-sodium chlorid and the edge of the cover-glass sealed with varnish, or the section may be washed for a short time in water (in order to remove the sodium chlorid), dried, and finally mounted in Canada balsam as directed.

A method adapted to the study of the hard and soft parts together is that first used by von Koch in studying corals. The specimen is first fixed, and if it be a long bone, the marrow cavity should first be opened to permit the fixing agent to come in contact with all parts of the tissue. After fixing, the bone is stained and then placed in absolute alcohol, and when completely dehydrated the pieces are placed in chloroform, then in a thin solution of Canada balsam in chloroform, and finally put into an oven kept at a temperature of about 50° C. for from three to four months. By this means the pieces are completely penetrated by the Canada balsam, and as the latter becomes very hard on cooling, the sections may be afterward ground without difficulty. Long as this procedure may seem, it is still the one which enables us to see the soft and hard parts of bone in a relationship the least changed by manipulation.

In bone, as also in cartilage, there sometimes occur amorphous as well as crystalline deposits of lime-salts. Upon the addition of acetic acid the carbonate of calcium gives off bubbles; upon the addition of sulphuric acid, short, thin needles will be formed—crystals of gypsum. Hematoxylin stains the lime-salts blue, with the exception of the oxalate of lime. Alkaline solution of purpurin stains calcium carbonate red. Caustic potash does not affect lime.

In order to study the organic constituents of bone, it must first be decalcified and thus rendered suitable for sectioning—*i. e.*, the lime-salts must first be removed, and that without destroying the cellular elements of the bone. The process of decalcification consists in substituting the acids of the decalcifying fluids for those of the bone salts. As a consequence, new combinations are formed, soluble in water or in an excess of the decalcifying acids themselves.

The **decalcifying fluids** most frequently used are:

(*a*) *Hydrochloric acid* (1% aqueous solution), used in quantities amounting to about fifty times the volume of the specimen. The solution

is changed daily, and the bone remains immersed until it is soft enough to be cut. This stage is reached when a needle can be introduced with no resistance.

(*b*) An *aqueous solution of nitric acid* in strengths of 3% to 10%, according to the delicacy of the specimen, and of a specific gravity of 1.4. Instead of water, 70% alcohol may be used as a solvent for the acid. Thoma has recommended for this purpose a solution consisting of 1 vol. nitric acid of a specific gravity of 1.3, and 5 vols. alcohol. This fluid is changed daily and decalcifies small objects in a few days. The specimens are then washed several times in 70% alcohol to remove as much as possible of the acid. 95% alcohol, with the addition of a little precipitated calcium carbonate, has been recommended for washing sections that have been treated by Thoma's method. After from eight to fourteen days the specimens are again washed with clear 95% alcohol.

(*c*) The process of decalcification recommended by v. Ebner (75) is of considerable value, as it also reveals the fibrillar structure of the bone lamellæ. A cold saturated solution of sodium chlorid is diluted with 2 vols. of water, and 2% of hydrochloric acid added. This fluid decalcifies very slowly, and must either be changed daily or a small quantity of hydrochloric acid occasionally added. As soon as the specimen is thoroughly decalcified, it is washed with a half-saturated solution of sodium chlorid. A little ammonia is now added from time to time until the reaction of the fluid and bone is neutral.

(*d*) Very small pieces that contain very little lime-salts, as, for instance, bones in an embryonal condition where calcification has only just begun, can be deprived of their lime-salts by means of acid fixing solutions like Flemming's fluid, chromic acid, picric acid, etc.

(*e*) Bone should be first fixed in some one of the fixing fluids and then decalcified.

Schmorl's Method for Demonstrating the Bone Corpuscles and their Processes in Decalcified Preparations.—The tissues are fixed in Müller's fluid or in Müller's fluid with formalin, decalcified in V. Ebner's fluid, and imbedded in celloidin. The sections are stained in either of the following thionin solutions: concentrated 50% alcoholic thionin solution, 10 c.c.; 1 per cent. carbolic acid water, 90 c.c.; or concentrated 50% alcoholic thionin solution, 10 c.c.; distilled water, 100 c.c.; liquor ammoniæ, 10 drops. Bring sections from water into the stain, in which they remain from five to ten minutes or longer. Rinse sections in water, and place them in a saturated aqueous solution of picric acid for one to two minutes or longer. Rinse in water and wash in 70% alcohol until no more stain is given off. Dehydrate in alcohol, clear in xylol, and mount in balsam. The bone corpuscles and processes are stained brownish-black, the ground substance yellow, the cells red-violet.

Schmorl's method for staining the boundary-sheaths of the bone corpuscle: Harden, decalcify, imbed, and stain as in the preceding method. After staining wash in water for two minutes or longer; rinse in alcohol for one-half minute, and again rinse in water and place the sections in a saturated aqueous solution of phosphomolybdic or phosphotungstic acid for three minutes or longer; wash in water which needs to be changed frequently for ten minutes. The sections are now placed for three to five minutes in a 10% aqueous solution of liquor ammoniæ, after

which they are washed in 90% alcohol, dehydrated, cleared in xylol, and mounted. The boundary-sheaths are stained bluish-black, the bone cells dark blue, and the bone substance light blue.

Fibers of Sharpey.—Sections treated by Ranvier's method show the perforating fibers of Sharpey as bright, sharply defined ribbons, appearing as streaks or circles, according to the section made (longitudinal or transverse). If decalcified specimens be first rendered transparent by glacial acetic acid, and then immersed for a minute in a concentrated aqueous solution of indigocarmin, washed with water, and then mounted in glycerin or Canada balsam, the fibers of Sharpey will appear red and the remaining structures blue. Thin sections of bone can be deprived of their organic elements by bringing them for from one-half a minute to a minute into a platinum crucible at a red heat. In such preparations calcified Sharpey's fibers may be seen (Kölliker, 86).

Virchow's bone corpuscles may be isolated in the following manner: Very thin fragments or discs of bone are immersed for some hours in concentrated nitric acid. They are then placed on a slide and covered with a cover-glass; pressure with a needle upon the latter will isolate the lacunæ, and occasionally also their numerous processes, the canaliculi.

C. MUSCULAR TISSUE.

Almost all the muscles of vertebrates have their origin from the middle germinal layer. In the simplest type the protoplasm of the formative cell changes into contractile muscle substance, the cell in the meantime undergoing a change in shape (unstriped muscle-cell). In other cases contractile fibrils are formed which are separated by the remains of the undifferentiated protoplasm (striped muscle-cells). In this case the cells either increase very little in length and possess only a single nucleus (heart muscle), or they grow considerably longer and develop many nuclei (voluntary skeletal and skin muscles).

A peculiarity of muscle-substance is that it contracts in only one direction, while undifferentiated protoplasm contracts in all directions.

1. NONSTRIATED MUSCLE-CELLS.

The smooth, unstriped, or nonstriated muscle-cells belong to involuntary muscle, and are found in the walls of the intestine, trachea, and bronchi, genito-urinary apparatus, blood-vessels, in certain glands, and also in connection with the hair follicles of the skin. The involuntary muscle-cells are spindle-shaped cells, which are 40–200 μ long and 3–8 μ broad. The longest are found in the pregnant uterus, where they attain a length of 500 μ. At the thickened middle portion of the cell is a long rod-like nucleus, typic of this class of cells. Nonstriated muscle-cells are doubly refractive —anisotropic. The cell substance is longitudinally striated, the striation being due to relatively coarse fibrils situated in the outer

portion of the cell substance (M. Heidenhain, Schaper, Benda). These fibrils have a longitudinal course, and probably run the entire length of the cell; whether they branch and anastomose must be regarded as an open question. In the interior of the cell substance there are found much finer fibrils, which branch and anastomose. Between the fibrils there is found a homogeneous substance, which we may know as the sarcoplasm, in which granules are often seen, situated at the poles of the nuclei. It is generally stated that nonstriated muscle-cells are united into membranes and bundles by a small amount of intercellular cement substance which may be darkened by silver nitrate. Recent investigations have, however, revealed the fact that nonstriated muscle-cells are encased in delicate connective membranes, which membranes unite to form compartment-like spaces, of fusiform shape, in which the muscle-cells are found. These membranes are not to be regarded as cell-membranes—sarcolemma—since one membrane serves as the sheath for two contiguous muscle-cells (Schaffer, v. Lenhossék, Henneberg). The existence of such membranes is clearly shown in involuntary muscle tissue subjected to trypsin digestion. In such preparation stained in iron-lac-hematoxylin it may be observed that the membranes are not complete, but are fenestrated, showing a varying number of round or oval openings (Henneberg). The membranes are also clearly shown in tissue fixed in corrosive sublimate and stained in Mallory's differential connective-tissue stain, the membranes showing as delicate blue lines while the muscle-cells are stained of a red or orange color. (See Fig. 92.) According to certain observers (Kultschitzky, Barfruth), nonstriated muscle-cells are thought to be joined by intercellular, protoplasmic bridges. It may, however, be clearly shown that such intercellular bridges are artifacts, due to peripheral vacuolization and to shrinkage of the muscle-cells (Schaffer, v. Lenhossék, Henneberg). What

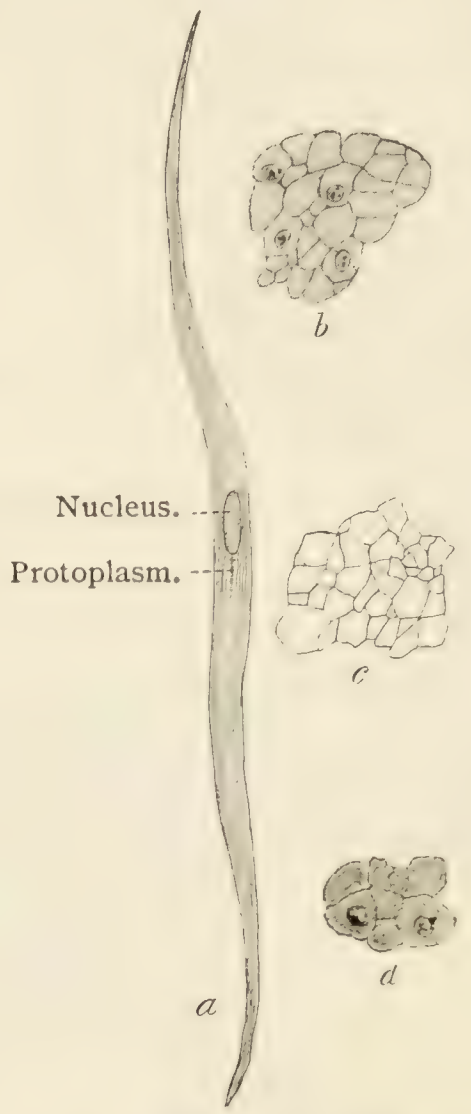

Fig. 92.—Nonstriated muscle from the intestine of a cat. × 300. *a*, Isolated muscle-cell; *b*, from cross-section of nonstriated muscle, stained after Mallory's differential connective-tissue stain. Observe the apparent difference in size of the cross-cut cells; four of the cells show nuclei; the black lines separating the cells represent the connective-tissue membranes. *c*, Cross-sections of the connective-tissue membranes separating involuntary muscle-cells; *d*, an area showing so-called intercellular bridges; they are attached to the connective tissue membranes surrounding the cells (Mallory's differential connective-tissue stain).

has been described as intercellular bridges may readily be seen in corrosive sublimate preparation, stained in Mallory's differential connective-tissue stain, especially in portions of the preparation not well fixed. In such preparation the so-called intercellular bridges end at the connective membranes separating cells, to which they are attached but which they do not penetrate. Nonstriated muscle-cells develop from the mesenchyme. (Exceptions to this statement appear to be found in the nonstriated muscular tissue of the iris [Szili] and in the sweat-glands, where the muscular tissue appears to be developed from ectodermal cells.) The nuclei of the mesenchymal cells elongate and become rod-shaped, with oval ends, while the cells become spindle-shaped, the protoplasm staining somewhat more deeply than that of the surrounding mesenchymal cells. Further details as to the development of nonstriated muscular tissue are lacking.

2. STRIPED MUSCLE-FIBERS.

Soon after the segmentation of the mesoderm begins, certain cells of the mesoblastic somites or myotomes commence the formation of muscle-substance in their interior, a process which is accompanied by increase in the number of nuclei, the formation of a membrane, a lengthening of the cells, and the appearance of fibrils in the peripheral protoplasm of the cells.

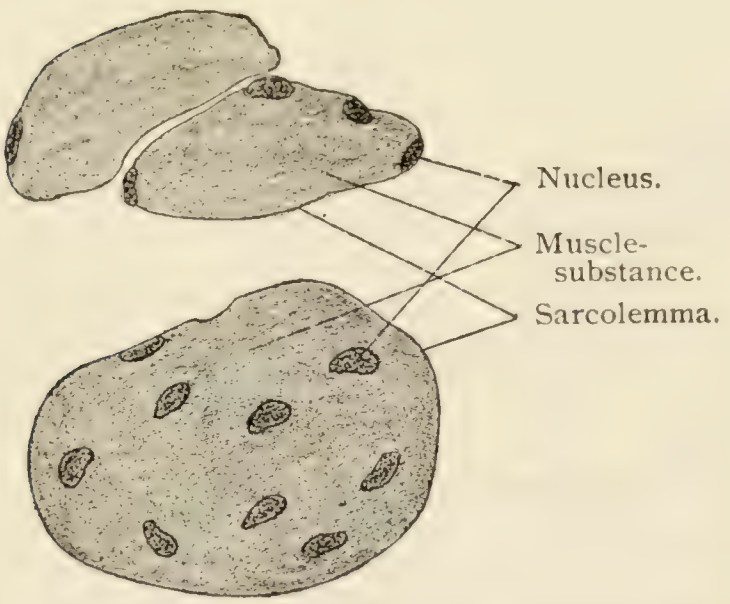

Fig. 93.—Cross-section of striated muscle-fibers: 1, Of man; 2, of the frog. The relations of the nuclei to the muscle-substance and sarcolemma are clearly visible; × 670.

Fig. 94.—Muscle-fiber from one of the ocular muscles of a rabbit, showing its free end; × 175.

Voluntary or striated muscle-cells are large, highly differentiated, polynuclear cells, which may attain a length of 12 cm., with a width of 10–100 μ. They are consequently known as muscle-fibers. Their free ends are usually pointed; the ends attached to tendon rounded (Fig. 94).

Each striated muscle-fiber consists of a delicate membrane, the *sarcolemma*, a muscle protoplasm, in which are recognized very fine fibrils and a semifluid interfibrillar substance (the sarcoplasm) and the muscle nuclei. The sarcolemma is a very delicate, transparent, and apparently structureless membrane, which resists strong acetic acid, even after boiling for a long time. If we examine in an indifferent fluid fresh muscle-fibers, the contents of which have been broken without rupturing the sarcolemma, we may see this sheath as a fine glistening line. (Fig. 95.)

The fibrils of the muscle-protoplasm constitute the contractile part of the muscle-fiber. They are exceedingly fine and extend the entire length of the muscle-fiber. These fibrils are, however, not of the same composition throughout, but are made up of segments which show different physical properties and stain differently. The structure of the fibrils may be expressed in the form of a diagram (Fig. 96) giving the more recently expressed views of the structure of these fibrils. The fibrils present alternating darker and lighter segments, which taken together give the striation which is so char-

Fig. 95.—Striated muscle-fiber of frog, showing sarcolemma.

acteristic of striated muscle. The darker segments are slightly longer, are doubly refracting, *anisotropic*, and in general stain more deeply than do the lighter segments, which are slightly shorter and are singly refracting, *isotropic*. The darker segments, known as the transverse discs, or Brücker's lines, are indicated in the diagram by the letter Q; the lighter segments, known as the intermediate discs of Krause, are indicated by the letter J. In the intermediate discs of Krause there is found a dark line, which is doubly refractive, which is known as Krause's membrane (Z) (Grundmembran), and which, according to certain observers (M. Heidenhain, J. B. MacCallum), is continuous through the fibril bundles, as will be stated more fully later. This membrane divides disc J into two equal parts. The transverse disc (Q) is likewise divided into equal parts by a narrow, isotropic band, known as the median disc of Hensen, and designated by the letter H. In the median discs of Hensen—H—there is found a thin membrane, known as the median membrane of M. Heidenhain, and designated as M, which, like the membrane of Krause, is continuous through the fibril bundles, uniting

the fibrils (M. Heidenhain). By grouping the unequally refracting substances (or unequally staining substances) a fibril may be divided into successive portions or protoplasmic metameres which may be termed sarcomeres (Schäfer) and which are bounded by the membrane of Krause (z). In such a sarcomere or muscle-casket we may recognize, beginning with Krause's membrane, z, an isotropic intermediary disc, J; an anisotropic, transverse disc, Q, divided by a less refracting Hensen's disc, H, into two equal parts, Hensen's disc showing the median membrane of Heidenhain, M; again an iso-

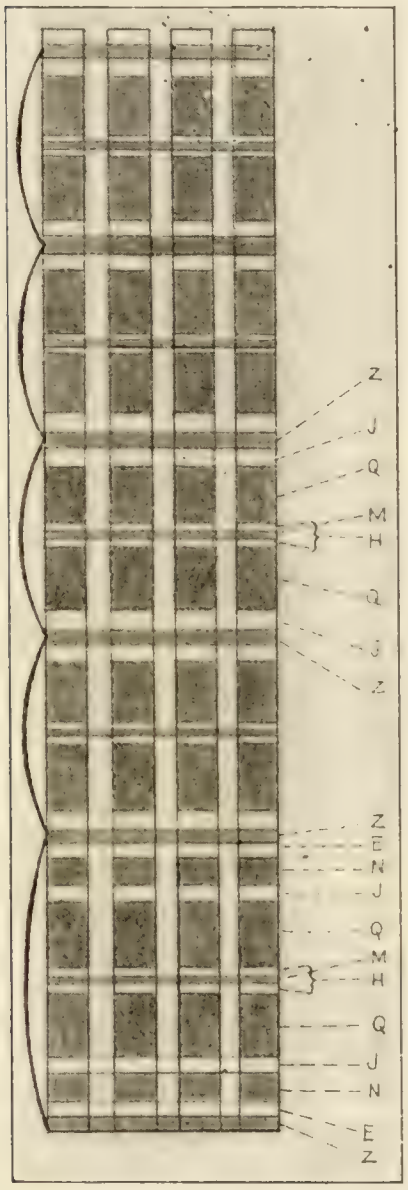

Fig. 96.—Diagram of the structure of the fibrils of a striated muscle-fiber. The light spaces between the fibrils may represent the sarcoplasm.

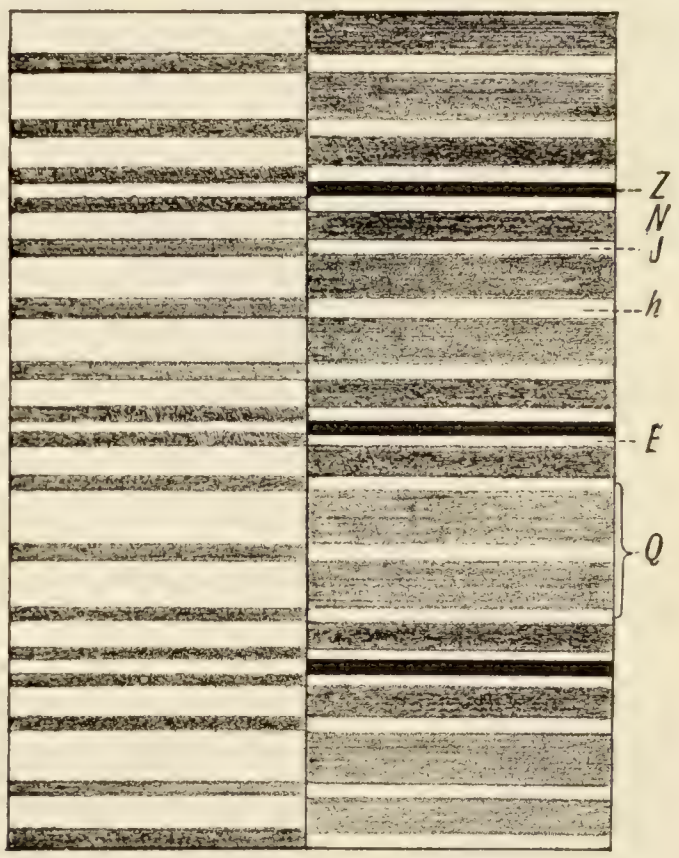

Fig. 97.—Diagrams of the transverse striation in the muscle of an arthropod; to the right with the objective above, to the left with the objective below its normal focal distance (after Rollett, 85): *Q*, Transverse disc; *h*, median disc (Hensen); *E*, terminal disc (Merkel); *N*, accessory disc (Engelmann); *J*, isotropic substance.

tropic intermedian disc, J, and Krause's membrane, z. Krause's membrane, as above stated, is continuous across the small bundles into which the fibrils are grouped, and is also attached to the sarcolemma (M. Heidenhain, J. B. MacCallum). This is shown to the left in Fig. 96, where the sarcolemma appears festooned, with Krause's membrane attached, thus indicating clearly the sarcomeres.

One of the best objects for the study of transverse striation is the muscle of some of the arthropods (beetles). In the striated

muscle of beetles and other arthropods there is, however, a further division into isotropic and anisotropic substance. Here it will be noticed that the disc J is separated by an anisotropic disc, known as the accessory disc of Engelman, and designated by the letter N, into an isotropic disc J, next to the anisotropic transverse disc Q, and an isotropic disc, known as Merkel's terminal disc, and designated by the letter E, situated next to Krause's membrane (Z). (See lower portion of Fig. 96.) The muscle fibrils present a different appearance when focused high than they do when focused low, as may be seen from the diagram given in Fig. 97; those parts which appear light on high focusing appear dark on deep focusing.

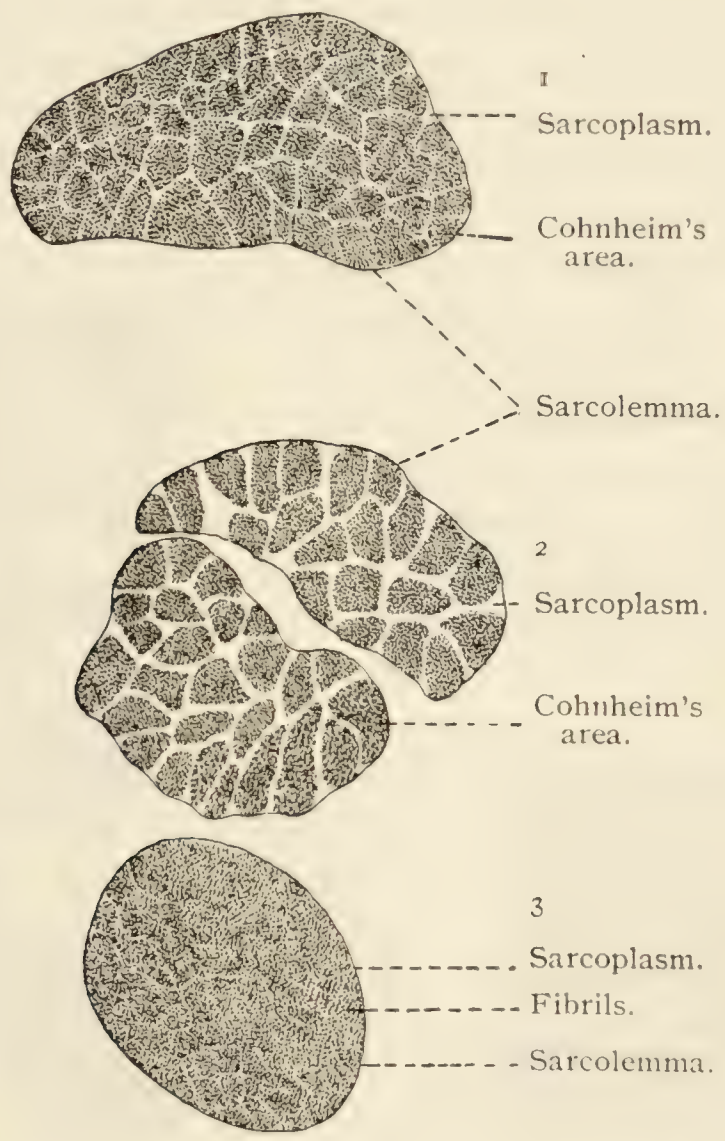

Fig. 98.—Transverse section through striated muscle-fibers of a rabbit. 1 and 3, from a muscle of the lower extremity; 2, from a lingual muscle; × 900. In 2, Cohnheim's fields are distinct; in 1, less clearly shown; in 3, the muscle-fibrils are more evenly distributed.

It has recently been suggested by J. B. MacCallum that Krause's membrane with the primitive fibrils form a continuous network in the muscle-fiber, the meshes of which would be fairly regular, the fibrils of such a network which run parallel to the long axis of the muscle-fiber being larger than the cross fibrils. Such a network is not to be confused with a network which may be brought out on staining striated muscle-fibers with gold chlorid, which network is due, in part at least, to a staining of the sarcoplasm.

The ultimate fibrils are grouped into small bundles (0.3–0.5 μ in

diameter), forming the *fibril bundles or muscle-columns* of Kölliker. In the muscle-columns the fibrils are so placed that the larger segments fall respectively in the same plane. (See Fig. 96.) The same disposition of the fibrils prevails in all the numerous muscle-columns forming a muscle-fiber, and all the muscle-columns bear such a relation to each other that the larger segments of the fibrils fall in the same plane. The semifluid, interfibrillar substance, the sarcoplasm, penetrates between the fibrils of the muscle-columns and separates these from each other and from the sarcolemma. In fresh preparations the substance forming the fibrils appears somewhat darker and dimmer, while the sarcoplasm appears clearer. The sarcoplasm is found in greater abundance between the muscle-columns than between the fibrils in the columns. The sarcoplasm between the muscle-columns appears in the form of narrower or broader lines, parallel to the long axis of the muscle-fibers, giving the cross-striated muscle-fiber also a longitudinal striation. The sarcoplasm between the muscle-columns is seen to best advantage in cross-sections of the muscle-fiber. Here it appears in the form of a network in closing the muscle-columns. Thus, we have in a cross-section slightly darker areas, the cross-sections of the muscle-columns, known as *Cohnheim's fields* or *areas*, separated by the network of sarcoplasm. (Fig. 98.)



Fig. 99.—From a striated muscle of man; obtained by teasing; × 1200. *h*, A median disc lying in the transverse disc *Q*; *z*, the membrane of Krause borders above and below on the light isotropic discs.

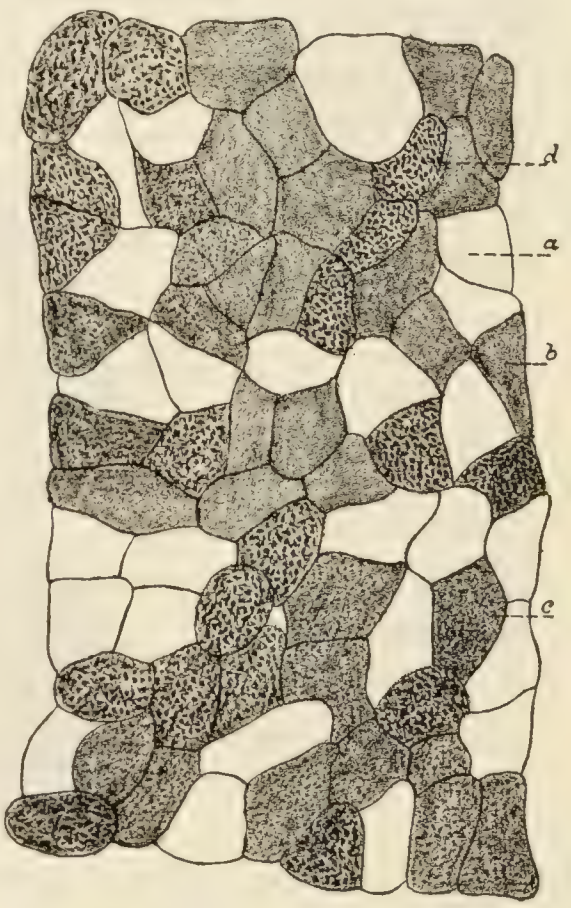

Fig. 100.—From a cross-section through the trapezius muscle of man, showing dark fibers rich in protoplasm, and light fibers containing very little protoplasm (after Schaffer, 93, II): *d*, Dark fibers; *a*, light fibers; *b* and *c*, transitional fibers from light to dark.

In figure 99 is shown a portion of a striated muscle-fiber of man very highly magnified. The larger and darker transverse disc (*Q*) formed by the larger segments of fibrils is divided by a light line (H), Hensen's median disc; the clearer band, largely isotropic substance, is divided by a dark line, the membrane of Krause, Z.

After a prolonged treatment with 98% alcohol the muscle-fibers

of the water-beetle (*Hydrophilus piceus*) can be made to separate into transverse discs (Rollet, 85). One of these discs would correspond to the segment *Q*, and it is very probable that this is the portion which has long been known under the name of Bowman's disc. Other reagents, as weak chromic acid, cause a separation of the muscle-substance into longitudinal fibrils. In this case the discs *Q* are split up longitudinally into a number of very small columns which were at one time regarded as the primary elements of the fiber and termed by Bowman *sarcous elements.*

In adult skeletal and skin muscle-fibers of mammalia the positions of the nuclei vary. There are muscles in which the nuclei are imbedded in the sarcoplasm between the muscle-columns (so-called red muscles, as the semitendinosus of the rabbit); in other muscles they lie immediately beneath the sarcolemma (white muscles, as the semimembranosus of the rabbit; Ranvier, 89). In the striated muscle-fibers of the lower vertebrates and of mammalian embryos the nuclei lie between the fibrillæ, or muscle-columns. The red muscle-fibers are rich in sarcoplasm, and the fibrils are grouped in well-marked and large muscle-columns surrounded by sarcoplasm which often contains granules of various sizes, the *interstitial granules* of Kölliker, often especially abundant at the poles of the nuclei. The white muscle-fibers have a relatively small quantity of sarcoplasm. In cross-sections of the light fibers the fibrils show as fine points, not distinctly grouped, and surrounded by the homogeneous sarcoplasm. Both varieties occur in almost every human muscle, and the relative number of each varies greatly in the different muscles (Schaffer, 93, II, Fig. 100).

Muscles with transversely striated fibers are, with the exception of those of the heart, subject to the will of the individual, and are characterized by a rapid contraction in which the anisotropic substance increases in size at the cost of the isotropic discs; the former appears to play the chief rôle. Besides morphologic differences, the red and white muscle-fibers appear to possess differences of a physiologic character, in that the contraction in the red

Fig. 101.—Branched, striated muscle-fiber from the tongue of a dog.

variety is slower than that in the white (Ranvier, 80). Only the striated muscles of the esophagus, the external cremaster, and a few others, as well as the somewhat differently constructed muscles of the heart, are involuntary.

Fig. 102.—Cross-section of rectus abdominis of child, as seen under low magnification.

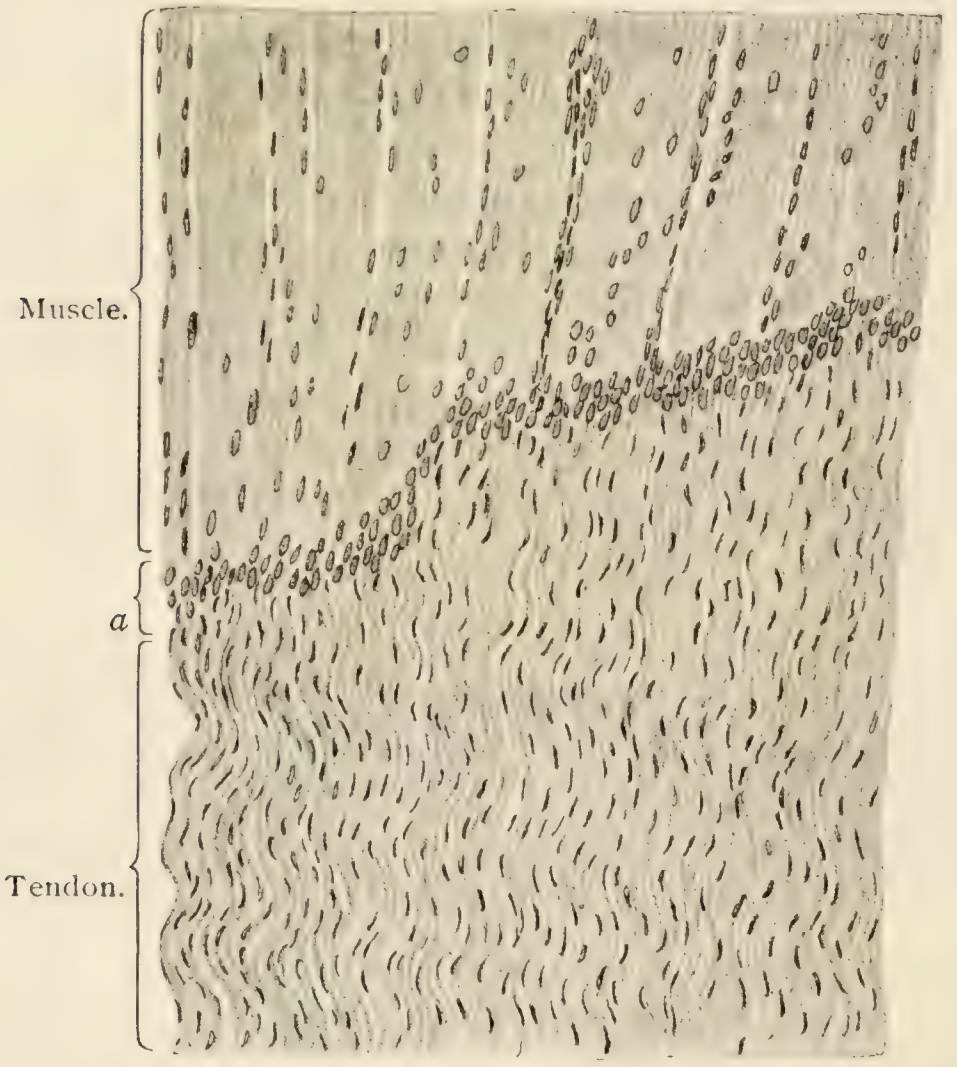

Fig. 103.—Part of a longitudinal section through the line of junction between muscle and tendon; × 150. At the line where the tendon-fibrils join the sarcolemma (*a*), the nuclei of the muscle are very numerous. Sublimate preparation.

Transversely striated muscle-fibers are usually unbranched. The muscle-fibers of the tongue and of the ocular muscles do, however, show occasionally communicating branches; the same are but very rarely seen in other muscles. In regions where striated muscle-fibers terminate under the epithelium, as in the tongue and in the skin of the face, the end of the fiber terminating under the epithelium is often very much branched; the cross-striation and nuclei may be observed in the finest branches. (Fig. 101.)

Each muscle-fiber is surrounded by a thin connective-tissue envelope, the *endomysium*, which binds them into primary and secondary bundles, the muscle-fasciculi. These are surrounded by a denser sheath of similar character, the *perimysium*. The muscle is made up of numerous fasciculi, all bound together by a thicker connective-tissue covering, the *epimysium*. (Fig 102.)

Blood-vessels are very numerous in transversely striated mus-

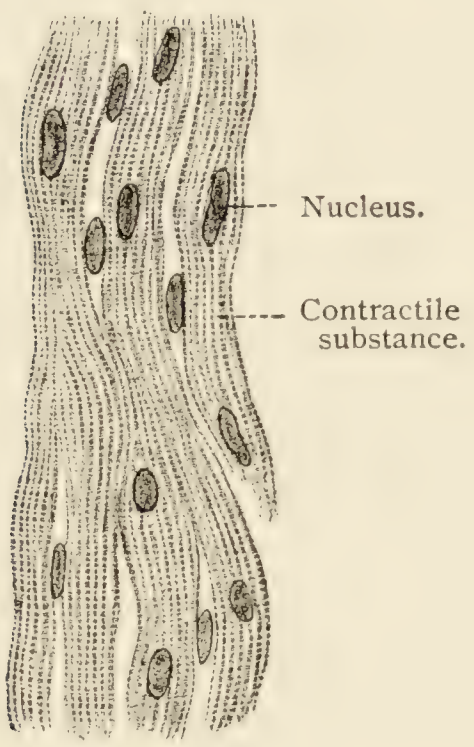

Fig. 104.

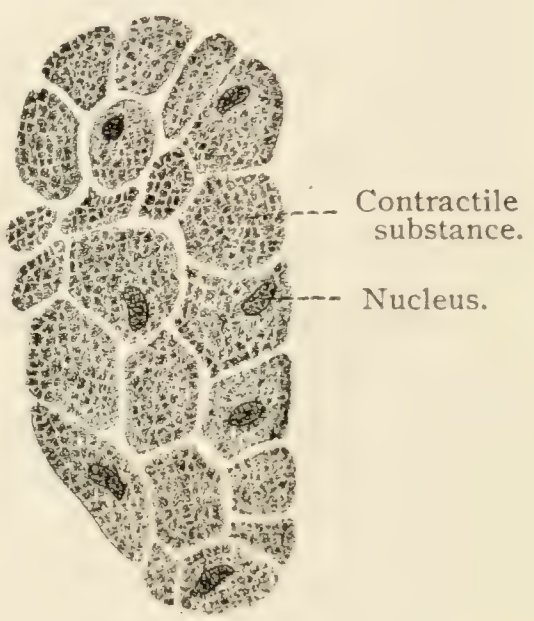

Fig. 105.

Longitudinal and cross-section of muscle-fibers from the human myocardium, hardened in alcohol; × 640. The muscle-cells in the longitudinal section are not sharply defined from each other, and appear as polynuclear fibers blending with each other. Between them lie, here and there, connective-tissue nuclei.

cular tissue. One or several arteries enter each muscle and form superficial and deeper plexuses by anastomosis. In these plexuses the arteries are accompanied by veins. On reaching the perimysium the arteries give off terminal branches which run transversely over the muscle fasciculi, at quite regular intervals. From these branches precapillaries and capillaries are given off which have a course which is in general parallel to the muscle-fibers; these capillaries anastomose frequently and collect to form small veins, which are situated between the terminal arterial branches, the terminal arterial and venous branches thus alternating in such a way that one venous branch is situated between two arterial branches or *vice versa*. The veins, even the smallest, are provided with valves (Spalteholz).

At its junction with tendon the muscle-fiber with its sarcolemma is rounded off into a blunt point, the fibrils of the tendon being cemented to the sarcolemma.

The longitudinal growth of muscle-fibers takes place principally at the distal ends of the fibers, at which point their nuclei are numerous. (Fig. 103, at *a*.) Schaffer (93, II) has recently suggested that there is a formative tissue between the tendon and muscle-substance, from which, on the one hand, muscle-fibers are developed, and, on the other hand, connective-tissue fibrils and cells are formed.

As recent investigations have shown, the development of muscle continues throughout the life of the individual. Muscular tissue is consequently to be regarded as in a perpetual stage of transition, the destruction and compensatory reproduction of its elements going on hand in hand. Its destruction is ushered in by a process which can be compared to a physiologic contraction. Nodes or thickened rings are formed, and at these points the muscle-substance separates into fragments with or without nuclei (sarcolytes), which are then absorbed, in most cases without phagocytic aid. This loss of substance is replaced by new elements developed from the free sarcoplasm, which is characterized by rapid growth and increase in the number of its nuclei. The result is that new elements are formed which have been called *myoblasts*. The process by which myoblasts are changed into the finished muscle-fibers is exemplified in the embryonal type of development of the tissue.

Development of Voluntary Muscle-fibers.—The striated, voluntary muscular tissue, as above stated, develops from the myotomes, segmentally arranged differentiated portions of the mesoderm. In the myotomes are developed round or oval cells known as myoblasts, which proliferate by mitotic cell division. According to the observations of certain observers, the myoblasts elongate and become spindle-shaped, while the nuclei proliferate, without an accompanying division of the cell body, to form the muscle-fibers, which may thus be regarded as polynuclear cells developing from a single cell. Other observers, notably Godlewsky, state that only relatively few of the muscle-fibers develop in this way, the majority being formed by a fusion of myoblasts, forming a syncytium, a muscle-fiber being thus a syncytial structure developed from a varying number of myoblasts.

The contractile fibrils are differentiated from the protoplasm of the differentiating myoblasts. When first seen, they present a uniform structure, and only later can a differentiation into isotropic and anisotropic substance be recognized. The discs Q and J appear first; the other parts of the sarcomeres somewhat later. The first formed fibrils divide longitudinally to give rise to new fibrils. Embryonic striated muscle tissue, even after striation of the fibers may be observed, forms a very compact tissue with only narrow interspaces between the cells. In the further development of this tissue certain of the embryonic muscle-fibers undergo degeneration

(Bardeen, Godlewski), and mesenchymal tissue, blood-vessels, and nerve-fibers make their appearance between the developing muscle-fibers.

CARDIAC MUSCLE.

Cardiac muscle or heart muscle is striated muscle, but differs physiologically and structurally from voluntary striated muscle. It resembles involuntary muscle in that it is not subject to the will. Heart muscle after fixation with many reagents used in the laboratories, and when treated with macerating fluids, or subjected to the action of silver nitrate, appears to consist of irregularly shaped oblong cells, cemented end-to-end to form heart muscle-fibers; such fibers appear to anastomose by means of side processes possessed by the cells. A number of recent investigators, notably v. Ebner and M. Heidenhain, have, however, shown that what has been regarded as cement lines uniting cells are to be otherwise interpreted, since they are known to bound nonnucleated areas of heart muscle, and since the contractile fibrils possessed by heart muscle pass through such lines without interruption. It would appear, therefore, that heart muscle must be regarded as a syncytium in which no distinct and separate cells occur, but rather of a complex plexus of branching and anastomosing fibers which differ in size and shape. Heart muscle-fibers consist, as was shown for voluntary striated muscle-fibers, of contractile, primitive fibrils, which are grouped into fibril bundles or muscle columns, between which there is found undifferentiated protoplasm, the sarcoplasm. They are surrounded by a sarcolemma, which differs, however, from the sarcolemma of voluntary muscle-fibers in not being so well developed. The primitive fibrils present the same structure as described for similar fibrils of voluntary muscle, each sarcomere consisting of Krause's membrane, Z; two intermediary discs, J; the transverse disc, Q, bisected by Hensen's median disc, H, which in turn contains the median membrane of Heidenhain, M. (See Fig. 96.) Krause's membranes (Z) and the median membranes (M) extend across the fibril bundles; the former are attached to the sarcolemma (M. Heidenhain). The primitive fibrils are grouped into fibril bundles or muscle columns, which in cross-sections are often band-shaped and are placed radially with reference to the center of the heart muscle-fibers. The sarcoplasm is present in relatively larger quantity than in voluntary striated muscle, especially between the fibril bundles, giving the fibers a distinct longitudinal striation. The primitive fibrils pass uninterruptedly through the anastomoses between the fibers. The nuclei, which are round or oval and possess a distinct chromatin network, are situated near the center of the fibers, occurring at irregular intervals, and are surrounded by an axial core of undifferentiated protoplasm, in which are found granules which stain in basic stains, also fat droplets, and, especially in older individuals, pigment granules. The structures which have been regarded as intercellular

cement lines may be especially stained in certain anilin stains. In such preparations it may be seen that they often do not extend through an entire fiber, are frequently irregular, often presenting the appearance of steps, and now and then involve only one or two fibril bundles. They are frequently seen to bound portions of a muscle-fiber which are nonnucleated. They are looked upon by M. Heidenhain as representing growth areas. See Fig. 106, in which such intercalated growth areas (cement lines?) are represented darker than the remaining structures.

Heart muscle-fibers are surrounded by delicate connective-tissue sheaths, very much as described for nonstriated muscle tissue. These are well shown in tissue fixed in corrosive sublimate and stained after Mallory's differential connective-tissue stain. The

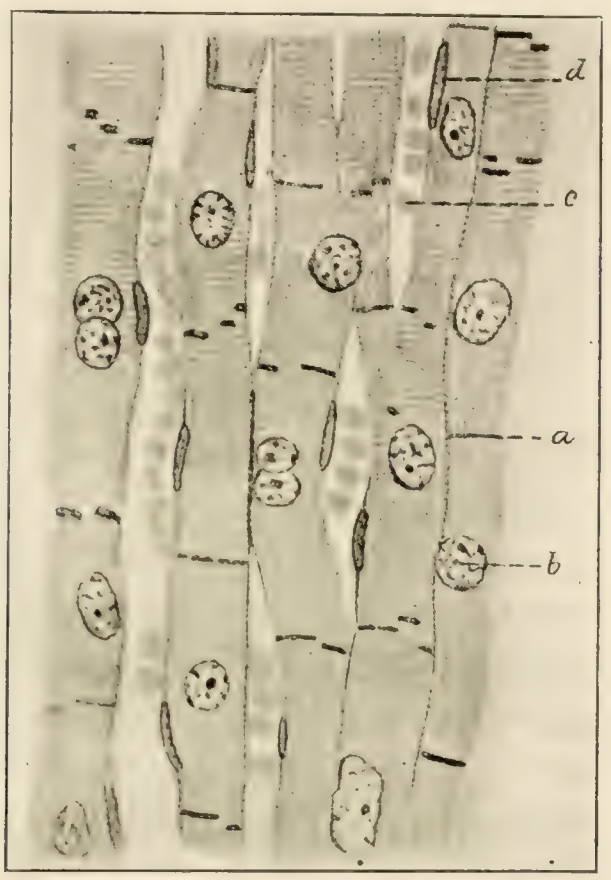

Fig. 106.—Longitudinal section of heart-muscle of a grown individual, fixed in corrosive sublimate and stained in hematein: *a*, Intercalated disc (so-called cement line); *b*, nucleus of heart muscle-fiber; *c*, red blood-corpuscles; *d*, nucleus of blood capillary.

fibers are grouped into bundles or fasciculi which are surrounded by internal perimysium.

Development of Heart Muscle-tissue.—Heart muscle-tissue develops from the mesenchyme, and shows from the beginning a syncytial structure, in that the cells are united by protoplasmic branches (von Ebner, M. Heidenhain, Godlewsky). As development proceeds, the interspaces between the cells become smaller and the protoplasmic bridges larger and more prominent, forming a distinct syncytium, through which the nuclei are scattered. In this syncytial protoplasm are developed the contractile fibrils, which may be traced uninterruptedly for long distances. These fibrils show at first a uniform structure, and later differentiate into isotropic and anisotropic discs, Q and J discs appearing first as in voluntary striated

muscle, and later the other parts of the sarcomeres (Godlewsky). It may be stated that, according to J. B. MacCallum (and other observers), the heart-muscle develops from spindle-shaped cells lying close together in the protoplasm of which there is found a fairly regular network. As development proceeds, fibrils or fibril bundles which run parallel to the long axis of the cells make their appearance at the nodal points of this network.

The muscle-cells of the so-called *fibers of Purkinje* lie immediately beneath the endocardium, and are remarkable in that their protoplasm is only partially formed of transversely striated substance, and that only at their periphery. Such cells are found in great numbers in some animals (sheep), but rarely in man. Heart muscle has a rich blood supply, which will be considered more fully when the heart is discussed as an organ.

For the nerve-endings in smooth and striated muscle-fibers see the chapter on Nervous Tissues.

TECHNIC.

Fresh, striated muscle-fibers may be isolated by teasing them in an indifferent fluid. After a short time the sarcolemma may separate as a very fine membrane. If a freshly teased muscle be placed in a cold saturated solution of ammonium carbonate, the sarcolemma will become detached in places within five minutes (Solger, 89, III).

Striated muscle-fibers may be examined in an extended condition by placing an extremity in such a position as to stretch certain groups of muscles. A subcutaneous injection of 0.25–0.5 c.c. of a 1% osmic acid solution is then made. The acid penetrates between the fibers and fixes them. Pieces of muscle are then cut out and washed in distilled water. Teased fibers, even if not stained, will show the striation plainly if mounted in glycerin. Muscles thrown into a state of tetanic contraction by electric stimulation may also be fixed in this state and later examined.

Cross-sections of muscles, extended and fixed in osmic acid, also show the relation of the fibrils to the sarcoplasm (Cohnheim's fields). A remarkable quantity of sarcoplasm in proportion to the number of fibrils is seen, for instance, in the muscles which move the dorsal fin of hippocampus; among the mammalia a similar condition is found in the pectoral muscles of the bat (Rollett, 89).

In the muscles of all adult vertebrates (except the mammalia) the nuclei lie between the fibrils. In young mammalia they also have this position, but in the adult animals only the nuclei of red muscles are found between the fibrillæ; in all other muscles the nuclei are under the sarcolemma.

The fibrillar structure of muscle-fibers can be seen by teasing old alcoholic preparations, or tissue treated with weak chromic acid (0.1%) or one of its salts.

In alcoholic preparations of mammalian muscle, the cross-striation is clearly seen, and is intensified by staining with hematoxylin. This stain colors everything anisotropic in the muscle, but does not affect the remaining structures. Similar results may be obtained with other

stains, such as basic anilin dyes, but not with the same precision as with hematoxylin.

A certain species of beetle (*Hydrophilus*) is admirably adapted for the study of the finer details of striation. The beetle is first wiped dry and then immersed alive in 93% alcohol. On examining in dilute glycerin after from twenty-four to forty-eight hours, the substance of its muscles will show disintegration into Bowman's discs (*vid.* p. 141). The latter swell up in acids and are finally dissolved, as may be seen, by adding a drop of formic acid to a specimen prepared as above (Rollet, 85).

In order to study the relation of muscle to tendon, small muscles with their tendons are put into a 35% potassium hydrate solution for a quarter of an hour, after which the specimen is placed upon a slide and teased at the line of junction of the two tissues. This will separate the muscle-fibers from their respective tendon-fibrils (Weismann).

Similar results may be obtained by immersing a frog in water at a temperature of 55° C., in which the animal soon dies with muscles perfectly rigid. As soon as the water begins to cool (one-quarter hour) the frog is removed and a small piece of its muscle cut out and teased in water on a slide (Ranvier).

Cardiac muscle-cells are isolated by maceration for twenty-four hours in a 20% solution of fuming nitric acid (potassium hydrate with a specific gravity of 1.3 will do the same in one-half or one hour). The margins of the cells may be brought more clearly into view by placing pieces of heart muscle for twenty-four hours in a 0.5% aqueous solution of silver nitrate and then cutting into sections.

Isolated fibers of Purkinje are obtained by immersing pieces of endocardium (0.5 mm. in size) in 33% alcohol and then teasing them on a slide. The sheep's heart is especially well adapted for this purpose.

Nonstriated muscle-fibers are isolated in the same way as heart muscle. In thin cross-sections (under 5 μ in thickness) of intestinal muscle, preferably of a cat, fixed in osmic acid, the intercellular bridges may be seen here and there between the fibers.

D. THE NERVOUS TISSUES.

The entire nervous system, peripheral as well as central, is composed of cells possessing one or many processes. These cells develop early in embryonic life from certain ectodermal cells (*neuroblasts*) of the neural canal, which is formed by a dorsal invagination of the ectoderm. The neuroblasts soon develop processes,—many of them *in loco*, others only after wandering from the neural canal.

The processes of the nerve-cells are of two kinds: (1) unbranched processes having a nearly uniform diameter throughout, with lateral offshoots known as collateral branches; these, as we shall see, generally form the central part of a nerve-fiber, and are known as *neuraxes* (Deiters' processes, axis-cylinder processes, neurites, neuraxones or axones); and (2) processes which branch soon after leaving the cell-body and break up into many smaller

branches; these are the *dendrites*, dendrons, or protoplasmic branches. In the spinal ganglia and the homologous cranial ganglia these morphologic differences in the processes are not observed, the neuraxis and the dendrites of each presenting essentially the same structure.

To the entire nerve-cell, cell-body and processes the term *neurone* (Waldeyer, 91) has been applied; *neura* (Rauber), or neurodendron (Kölliker, 93).

The neuraxes of many neurones attain great length. Those of some of the neurones, the cell-bodies of which are situated in the lower part of the spinal cord, extend to the foot. In other regions neuraxes nearly as long are to be found, and in the majority of neurones the neuraxes terminate some distance from the cell-body. It is therefore manifestly impossible in the majority of cases to see a neurone in its entirety. Usually, only a portion of one can be studied in any one preparation. Consequently, the more detailed description which follows will deal with the neurone in this fragmentary manner. The cell-bodies of the neurones, to which the term "nerve-cells" or "ganglion cells" is usually restricted, the dendrites and neuraxes, often forming parts of nerve-fibers, and their mode of terminating, will receive separate consideration.

NERVE-CELLS, OR GANGLION CELLS; THE CELL-BODIES OF NEURONES.

The cell-bodies of neurones are usually large. The bodies of the motor neurones of the human spinal cord measure 75 to 150 μ, their nuclei 45 μ, and their nucleoli 15 μ. The smallest nerve-cells, the neurones of the granular layer of the cerebellum, are 4 to 9 μ in diameter. The protoplasm of nerve-cells shows a distinct fibrillar structure and the fibrils may be followed into the processes. (Fig. 107.) Their nuclei are also large, with very little chromatin, but as a rule are supplied with a large nucleolus.

After treatment by certain special methods, the protoplasm of the ganglion cells shows granules or groups of granules which show special affinity to certain stains, consequently known as chromatophile granules; these are densely grouped around the nucleus, so that the cell-body shows an inner darker and an outer lighter portion. These chromatophile granules, also spoken of as *tigroid* granules or as the tigroid substance (v. Lenhossék), as a rule are not arranged in concentric layers, but lie mostly in groups, giving to the protoplasm a mottled or reticular appearance. In the cells of the anterior horns (man, ox, rabbit) the granules join to form flakes, which are also more numerous in the region of the nucleus. In all cases the granules or flakes are continued into the dendrites of the cell. Here they change their shape into long pointed rods, with here and there nodules, which are probably the chief causes of the varicosities so often seen in dendrites (Golgi's method). The cell usually has a clear, nongranular peripheral border (not a membrane), and in the

case of large cells there is a similar area around the nucleus, the inner border of which belongs to the nuclear membrane. H. Held has found that the chromatophile granules are brought out by treatment with alcohol and acid fixing fluids, but not in alkaline or neutral. They appear, according to the treatment, as fine or coarse granules. They can not be seen in fresh nerve-cells. He consequently regards them as artefacts—precipitations of the protoplasm due to reagents (*vid.* A. Fischer). At its junction with the cell the neuraxis spreads out into a cone which is entirely free from granules, and apparently fitted into a depression in the granular substance of the cell (implantation cone or axone hillock). The shape, number, and size of the tigroid granules vary with the physiologic activity of neurones. They practically disappear from the neurones in certain diseased conditions or after the administration of poisons which affect more particularly nerve-cells ; also after extreme fatigue.

The cellular substance between the chromatophile granules consists also of very fine, highly refractive granules, which appear to be arranged in a reticulum surrounding the chromatophile granules

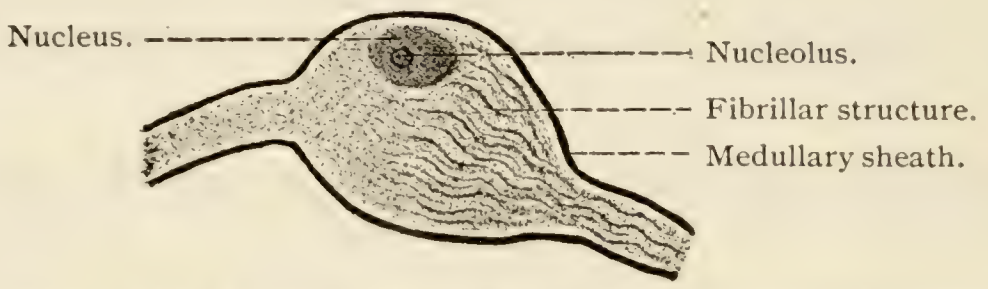

Fig. 107.—Bipolar ganglion cell from the ganglion acusticum of a teleost (longitudinal section). The medullary sheath of the neuraxis and dendrite is continued over the ganglion cell ; × 800.

(*vid.* Nissl, 94, and v. Lenhossék, 95), and the recent observations of Apáthy and Bethe make it very probable that in the intergranular substance of the protoplasm of the nerve-cell there exist very fine fibrils which may be traced into the processes of the cell, and from the branches of one neurone to and into the branches of other neurones without interruption. It requires, however, further observation before more positive statements may be made concerning them.

Besides the granules above mentioned, and which are revealed by special methods, there are found in the protoplasm of many of the larger nerve-cells pigment granules of a yellow or brown color which stain black with osmic acid.

The *dendrites* are usually relatively thick at their origin, but gradually, as a result of repeated divisions, taper until their widely distributed arborescent endings appear as minute threads of widely different shapes. When treated by certain methods, they present uneven surfaces studded with varicosities and nodules, in contradistinction to the neuraxes, which are smooth and straight. Their terminal branches end either in points or in small terminal thickenings. The groups of terminal end-branches of a dendrite (also of a neuraxis) are known as *telodendria* (Rauber), or end-branches. The

branches of the dendrites form a dense feltwork, which, together with the cell-bodies of the neurones and with other elements to be described later, constitute the gray substance (gray matter) of the brain and spinal cord.

All neurones, with possibly a few exceptions, possess only a single neuraxis. Neurones without a neuraxis have never been found in vertebrates. The neuraxis usually arises from a cone-shaped extension of the cell-body free from chromatophile granules, the implantation cone or axone hillock, more rarely from the base of one of its dendrites, or from a dendrite at some distance from the cell-body. Its most important characteristics are its smooth and regular contour and its uniform diameter. At some distance from the cell-body, usually near its termination, now and then in its course, a neuraxis may divide into two equal parts. Golgi (94) called attention to the fact that the neuraxes of certain neurones (Purkinje's cells in the cerebellum, pyramidal cells of the cerebral cortex, and certain cells of the spinal cord) give off lateral processes, the collateral branches.

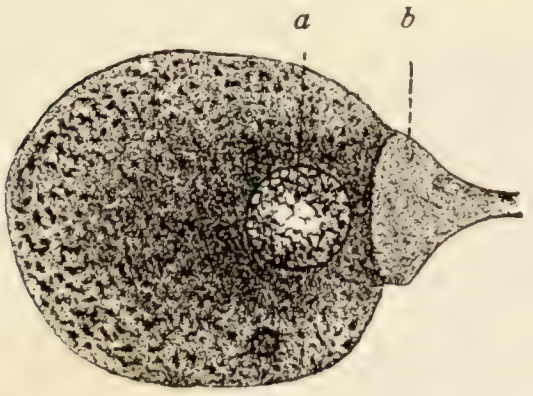

Fig. 108.—Chromatophile granules of a ganglion cell from the Gasserian ganglion of a teleost: *a*, Nucleus; *b*, implantation cone.

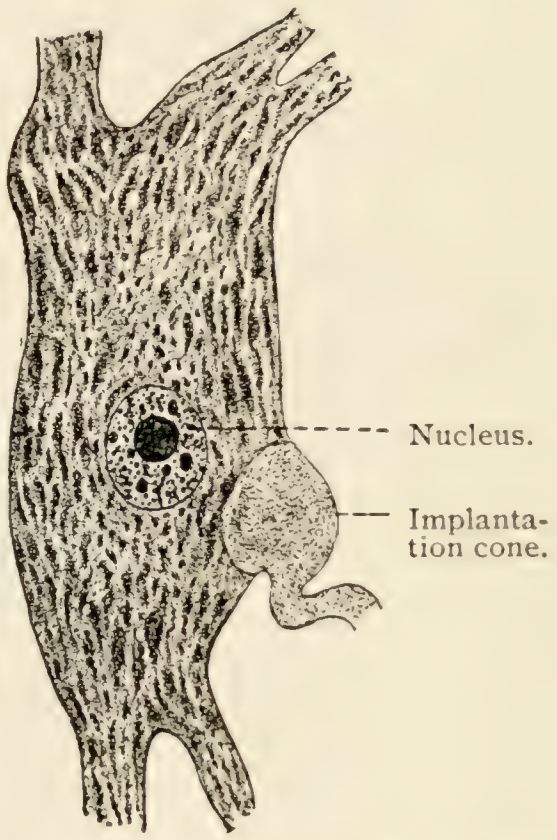

Fig. 109.—Nerve-cell from the anterior horn of the spinal cord of an ox, showing coarse chromatophile flakes.

Two types of cell are recognized according to the disposition of their neuraxes: In the first the neuraxis is continued as a nerve-fiber; in the second and rarer type it does not long preserve its independence, nor is it continued as a nerve-fiber, but soon breaks up into a complicated arborization, the *neuropodia* of Kölliker (93). The latter type of cell occurs in the cortex of the cerebrum and cerebellum and in the gray matter of the spinal cord. The cells of the two types can be simply described as having long (type I) or short, branched neuraxes (type II). The neuraxes of the cells of type I possess the collateral branches which end in small branching tufts.

In its simplest form, a neurone consists of a cell-body and a neuraxis with its telodendrion. In more complicated types one or several

dendrites may be present, as also collaterals from the neuraxis, and in rare cases even several neuraxes. According to the number of its processes, a ganglion cell is known as unipolar, bipolar, or multipolar.

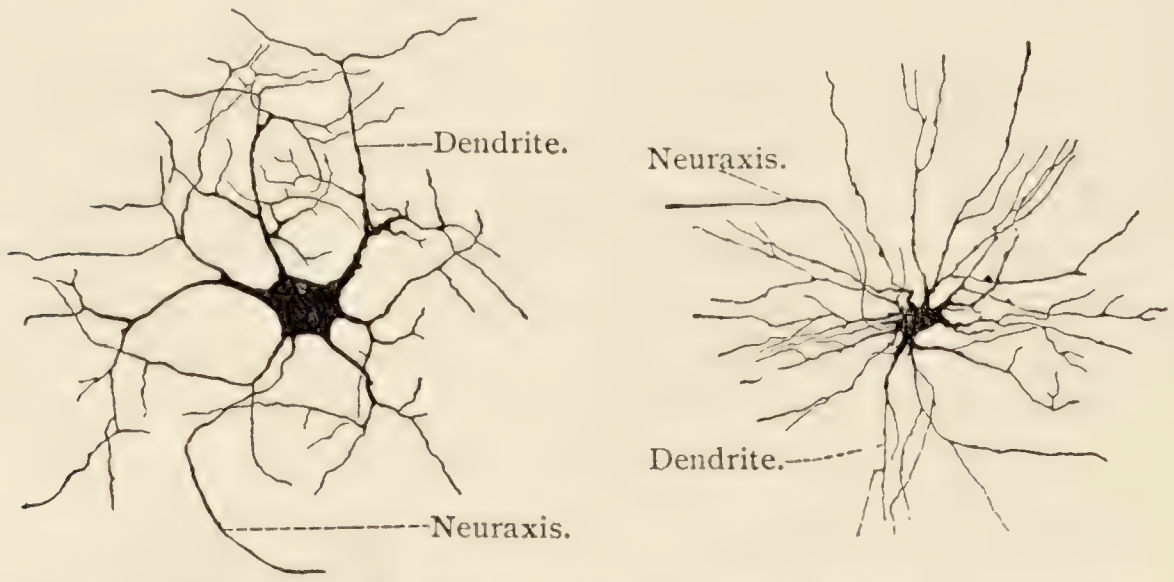

Fig. 110.—Motor neurones from the anterior horn of the spinal cord of a new-born cat. Chrome-silver method.

Although neurones present a great variety of morphologic differences,—large and variously shaped cell-bodies or small ones scarcely larger than the nucleus; large and numerous dendrites or

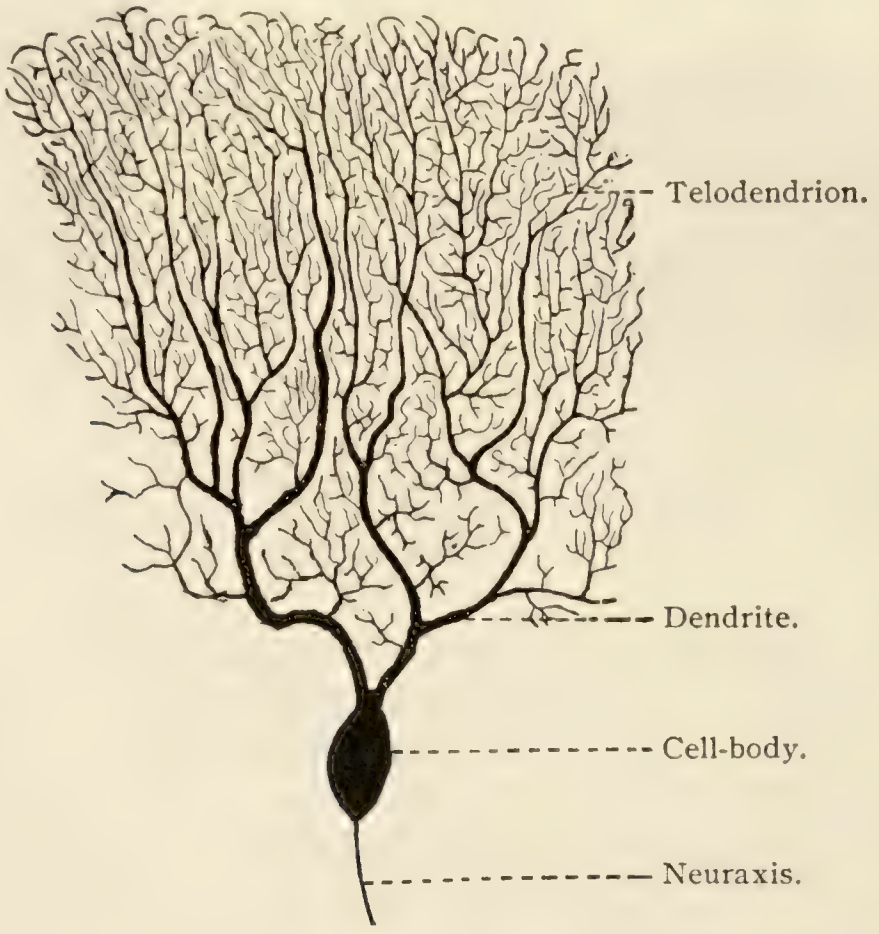

Fig. 111.—A nerve-cell with branched dendrites (Purkinje's cell), from the cerebellar cortex of a rabbit; chrome-silver method; × 125.

few and less conspicuous ones,—and although these various forms are widely distributed and intermingled in the different parts of the nervous system, yet in many regions there are found nerve-cells of fixed and characteristic morphologic appearance, which would

enable a determination of their source. A few of the most characteristic types are here figured and may receive brief consideration. In the anterior horn of the spinal cord are found large multipolar neurones (motor neurones), with numerous dendrites, which terminate after repeated branching in the neighborhood of the cell-body, while the neuraxis with its collateral branches proceeds from the cell-body and becomes a part of a nerve-fiber. (Fig. 110.)

In the cerebellum are found large neurones, discovered by Purkinje, and known as Purkinje's cells, with flask-shaped cell-body, from the lower portion of which arises a neuraxis with collateral branches,

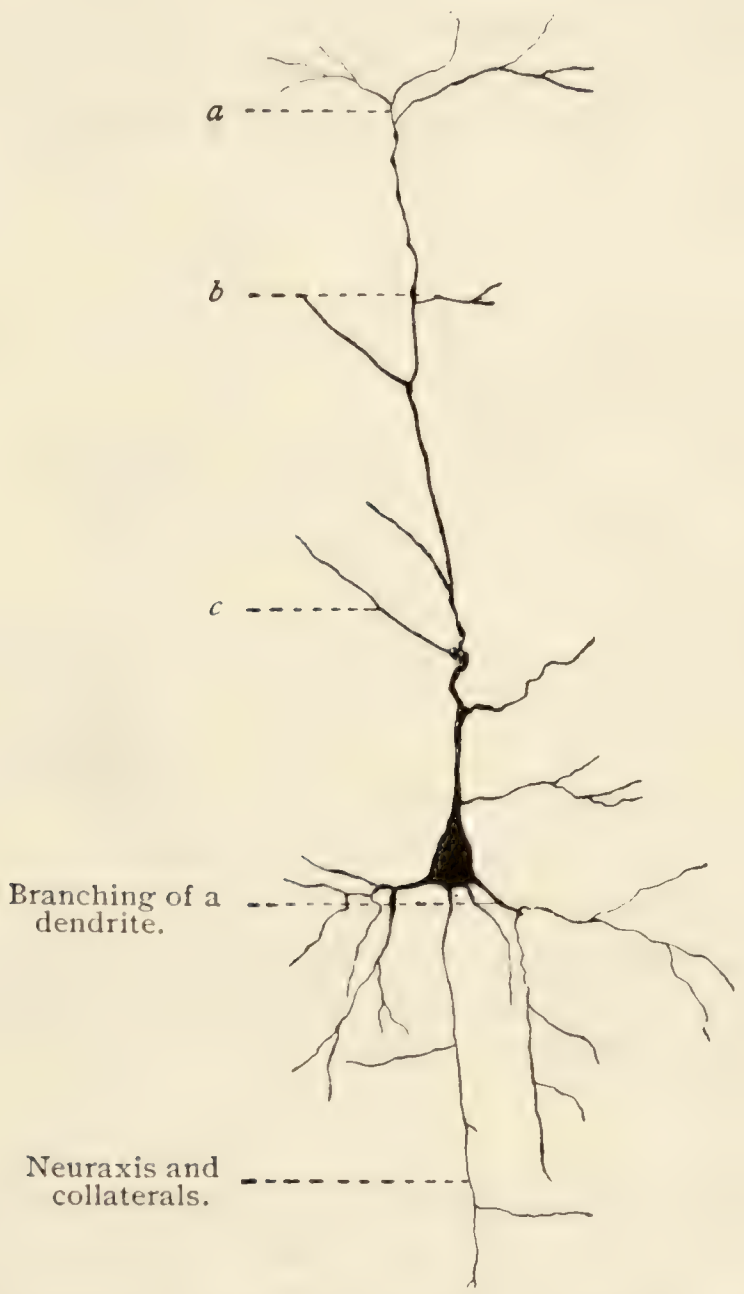

Fig. 112.—Pyramidal cell from the cerebral cortex of man; chrome-silver method: *a*, *b*, *c*, Branches of a dendrite.

from the upper portion one or two very large and typic dendrites the smaller branches of which are beset with irregular granules. (Fig. 111.)

In the cortex of the cerebrum occur large neurones, each with a cell-body the shape of a pyramid (pyramidal cell of the cerebral cortex), from the apex of which arises one large dendrite, and from angles at the base, or from the sides of the cell-body, several smaller dendrites. The neuraxis arises from the base directly or from one of the basal dendrites. (Fig. 112.)

In figure 113 is shown a neurone with relatively small cell-body and short dendrites, from the granular layer of the human cerebellum.

The function of the dendrites has given rise to considerable discussion. Golgi and his school regard them as the nutrient roots of the cell, a theory which is opposed by Ramon y Cajal (93, I), van Gehuchten (93, I), and Retzius (92, II). According to the latter, all the processes of the nerve-cell are analogous structures; they pass out from a sensitive element, and probably have a correspondingly uniform function.

In the spinal ganglia and the homologous cranial ganglia, are grouped the cell-bodies of neurones (peripheral sensory neurones, peripheral centripetal neurones) which differ in many respects from those above described. In the peripheral sensory neurones the

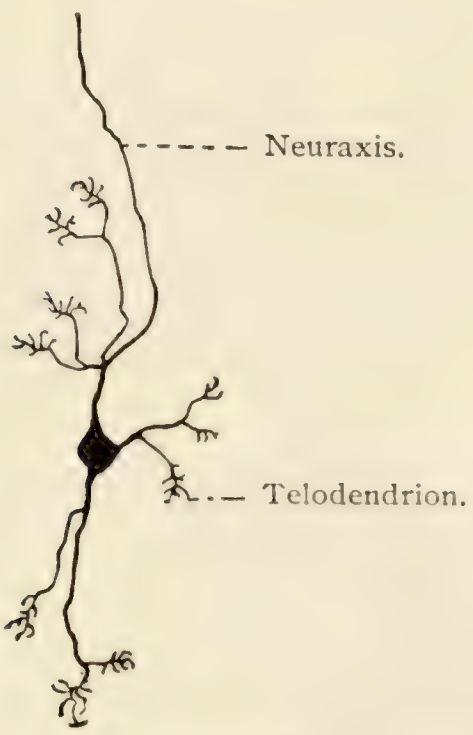

Fig. 113.—Nerve-cell with dendrites ending in claw-like telodendria; from the granular layer of the human cerebellum; chrome-silver method; × 110.

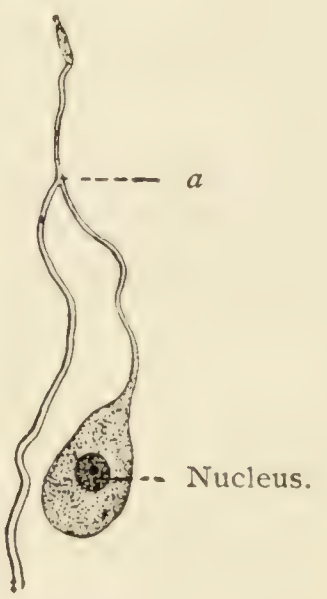

Fig. 114.—Ganglion cell with a process dividing at *a* (T-shaped process); from a spinal ganglion of the frog; × 230.

neuraxes and dendrites have essentially the same structure, both forming part of a nerve-fiber. From a relatively large, nearly round, oval, or pear-shaped cell-body there arises a single process, which, at a variable distance from the cell-body, divides into two branches forming a right or obtuse angle with the single process (T-shaped or Y-shaped division of Ranvier, 78). Both of these branches form the central axis of a nerve-fiber; one of the branches passing as a nerve-fiber to the spinal cord or brain, as the case may be; the other forming a nerve-fiber which passes to the periphery. (Figs. 114 and 115.)

The ganglion cells of the spinal ganglia and homodynamic structures of the brain are therefore apparently unipolar cells, but, as Ranvier has shown, their processes are subject to a T-shaped or Y-shaped division. The branches going to the periphery are re-

garded as dendrites, the others as neuraxes. As to the significance to be attached to the single process, the theory of v. Lenhossék

Fig. 115.—Ganglion cell from the Gasserian ganglion of a rabbit; stained in methylene-blue (*intra vitam*).

(94, I) that it represents an elongated portion of the cell, and that therefore the origin of the dendrite and that of the neuraxis are in this case close together, is very plausible. In the embryo these ganglion cells are at first bipolar, a process arising from each end, of a spindle-shaped cell; as development proceeds, the two processes approach each other and ultimately arise from a drawn-out portion of the cell-body, the single process. (Fig. 116.)



Fig. 116.—Three ganglion cells from a spinal ganglion of a rabbit embryo. The cells are still bipolar. Their processes come together in later stages, and finally form the T-shaped structure seen in the adult animal; chrome-silver method; × 170.

The sympathetic ganglia are composed mainly of the cell-bodies and dendrites (also some structures to be mentioned later) of neurones of the sympathetic nervous system. In nearly all vertebrates, and with but few exceptions in any one ganglion, these neurones are multipolar and resemble morphologically the multipolar ganglion cells of the anterior horn of the spinal cord, though they are somewhat smaller. In the cell-body there may be ob-

served fine chromatophile granules and a large nucleus and nucleolus. From the cell-body there proceed a varying number of dendrites which branch and rebranch and terminate, as a rule, near the cell-body, forming plexuses in the ganglia. The neuraxis arises either directly from the cell-body from an implantation cone, or from one of the dendrites at a variable distance from the cell-body. (Fig. 117.) In nearly all ganglia a few unipolar or bipolar cells are to be found. In the sympathetic nervous system of amphibia the sympathetic neurones are unipolar ; the single process present is the neuraxis.

A most important result of the more recent investigations on the nervous system is the theory of the independence of the neurone. Each neurone develops from a single cell (neuroblast), and functionates as an independent cell under physiologic and pathologic conditions. Only very rarely has any direct connection between two neighboring neurones been demonstrated, so rarely that the

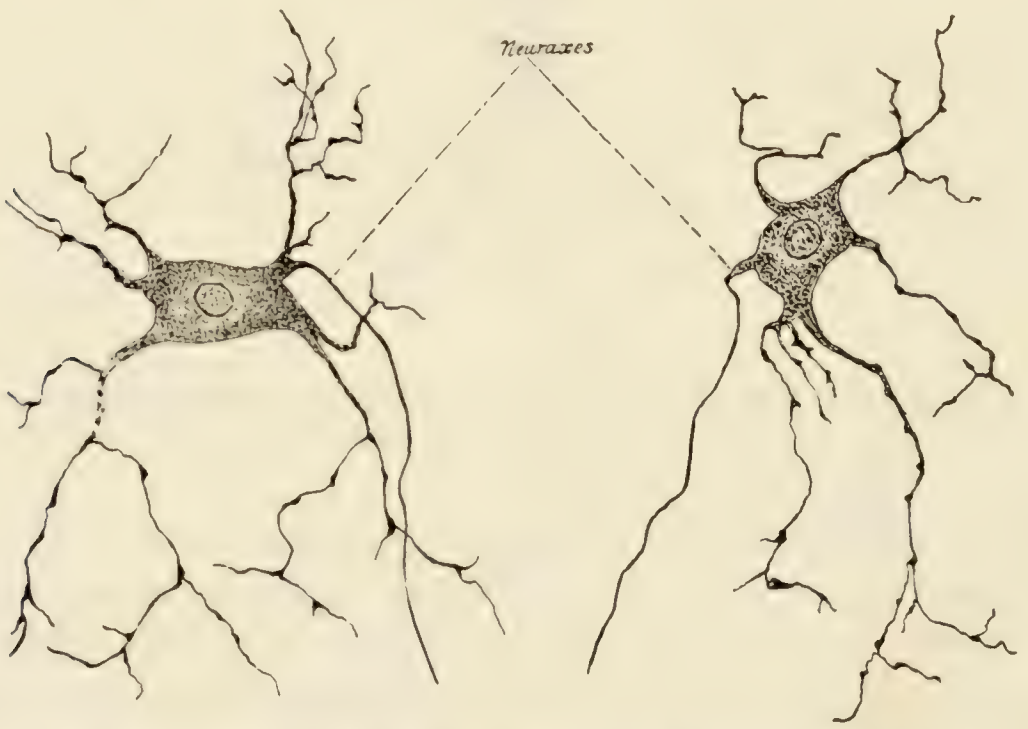

Fig. 117.—Neurone from inferior cervical sympathetic ganglion of a rabbit ; methylene-blue stain.

scattered observations at hand do not vitiate the above statement. Recent investigations have, however, shown that, while a neurone is a distinct anatomic unit, it is always found associated with other neurones. Nowhere in the body of a vertebrate does one find a neurone completely disconnected from other neurones. This association of one neurone with one or several other neurones is always effected by a close contiguity existing between the telodendria (end-branches) of the neuraxis of one neurone with the cell-body or dendrites of one or several other neurones. The telodendrion of the neuraxis of one neurone may form a feltwork inclosing the cell-body of one or several neurones, forming structures known as terminal baskets or end-baskets, or the end ramifications of the neuraxis of a neurone may come in very close proximity to the end-branches of the dendrites of one or several neurones. By this contiguity of the telodendria of the neuraxis of one neurone with

LIBRARY
MEDICAL SCHOOL

the cell-bodies or the dendrites of other neurones, they are, without losing their identity, linked into chains, so that a physiologic continuity exists between them. In such neurone chains the dendrites are regarded as cellulipetal, transmitting the stimulus to the cell ; the neuraxes as cellulifugal, transmitting the impulse imparted by the cell to the motor nerve-endings or central organs (Kölliker, 93). The entire nervous system may therefore be said to be made up of such neurone chains, the complexity of which varies greatly according to the number of neurones which enter into their construction. This subject will be considered more fully in a chapter on the nervous system.

THE NERVE-FIBERS.

The neuraxes of the cells of type I, and the dendrites of the peripheral sensory neurones (spinal ganglia and homologous cranial ganglia), form the chief elements in all the nerve-fibers. In the nerve-fibers they possess a distinctly fibrillar structure. The fibrils composing them, the *axis-fibrils*, are imbedded in a semifluid substance, the *neuroplasm* (Kupffer, 83, II) the whole being surrounded by a very delicate membrane, the *axolemma*. In the nerve-fibers, the axis-fibrils and the neuroplasm form *axial cords* which are surrounded by a special membrane or membranes, the presence or absence of which serves as a basis for a classification of nerve-fibers. Two kinds are distinguished, medullated and nonmedullated nerve-fibers.

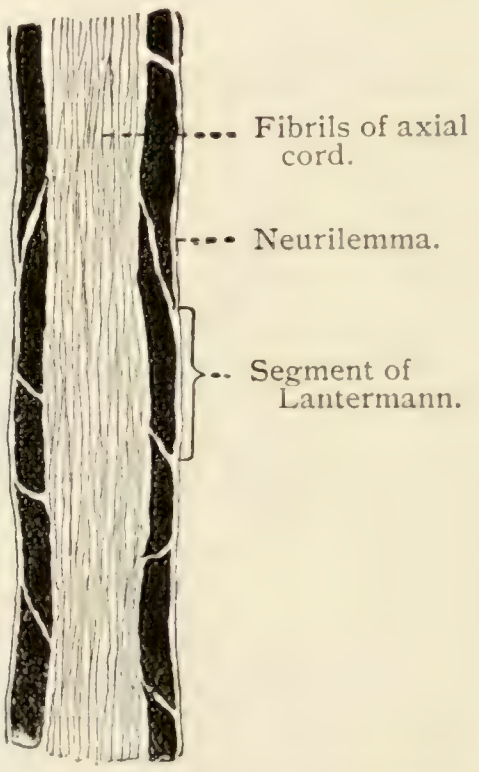

Fig. 118.—Longitudinal section through a nerve-fiber from the sciatic nerve of a frog ; ×830.

In medullated nerve-fibers, the axial cords (neuraxes of cells of type I, and dendrites of spinal ganglion cells) are surrounded by a highly refractive substance very similar to fat, which is blackened in osmic acid, the so-called *medullary* or *myelin sheath*. In a fresh condition this sheath is homogeneous, but soon changes and presents segments separated from each other by clear fissures. These segments vary in size and are known as " Schmidt-Lantermann-Kuhnt's segments." On boiling in ether or alcohol the entire medullary sheath of a nerve-fiber does not dissolve, but a portion is left in the shape of a fine network which is not affected by exposure to the action of trypsin. From the latter circumstance it has been thought that this network consists of a substance very similar to horn, and is therefore known as *neurokeratin* (horn-sheath, Ewald and Kühne). On burning isolated neurokeratin, an odor exactly like that of burn-

ing horn is given off. It is thought that the meshes of this neurokeratin network contain the highly refractive substance similar to fat, composing the greater portion of the medullary sheath. The medullary sheath is interrupted at intervals of from 80 to 900 μ, the constrictions thus formed being known as the *nodes of Ranvier*. The smaller the fiber, the less the distance between the nodes. In a fiber with a diameter of 2 μ the internodal segments are usually about 90 μ in length.

In peripheral nerves the medullary sheath is in its turn surrounded by a clear, structureless membrane, the *neurilemma* or sheath of Schwann. Nerve-fibers contain here and there relatively long, oval nuclei (neurilemma-nuclei) which are surrounded by a small quantity of protoplasm, and are situated in small excavations between the neurilemma and the medullary sheath. In the higher vertebrates a single nucleus is found midway between each two

Fig. 119.—Transverse section through the sciatic nerve of a frog; × 820. At *a* and *b* is a diagonal fissure between two Lantermann's segments; as a result, the medullary sheath here appears double. (Compare Fig. 118.)

nodes; in the lower vertebrates (fishes) several scattered nuclei (5–16) may be found in each internodal segment. At the nodes, where the medullary sheath is interrupted, the neurilemma is thickened and contracted down to the axial cord (contraction-ring).

Just beneath the contraction-ring, Ranvier found that the axis-cylinder presents a slight, biconic swelling (*renflement bicônique*). Thus the sheath of Schwann represents a continuous tube throughout the length of the fiber in contrast to the medullary sheath. In the nerve-fibers of the spinal cord and brain there is no neurilemma, although the medullary sheath is present.

In the fresh nerve-fiber the axial cord fills the space (axial space) within the medullary sheath, and appears transparent. After treatment with many fixing fluids the neuroplasm coagulates and shrinks, no longer filling the entire axial space, but appears in the latter as a wavy cord composed of an apparently homogeneous

mass, the fibrillæ of which are no longer recognizable. Such pictures, which formerly were supposed to represent the normal condition of the nerve-fibers, gave rise to the conception of an *axis-cylinder* (*vid.* Technic). That which is known as an axis-cylinder is therefore, in reality, the changed contents of the axial space. It may be stated, however, that the term axis-cylinder is still much used, since the methods commonly employed in the investigation of the nervous system do not preserve the axial cord in its integrity, but nearly always result in the formation of an *axis-cylinder.* Consequently, although we shall make use of the term, its limitations are to be kept in mind.

Medullated nerve-fibers vary greatly in di-

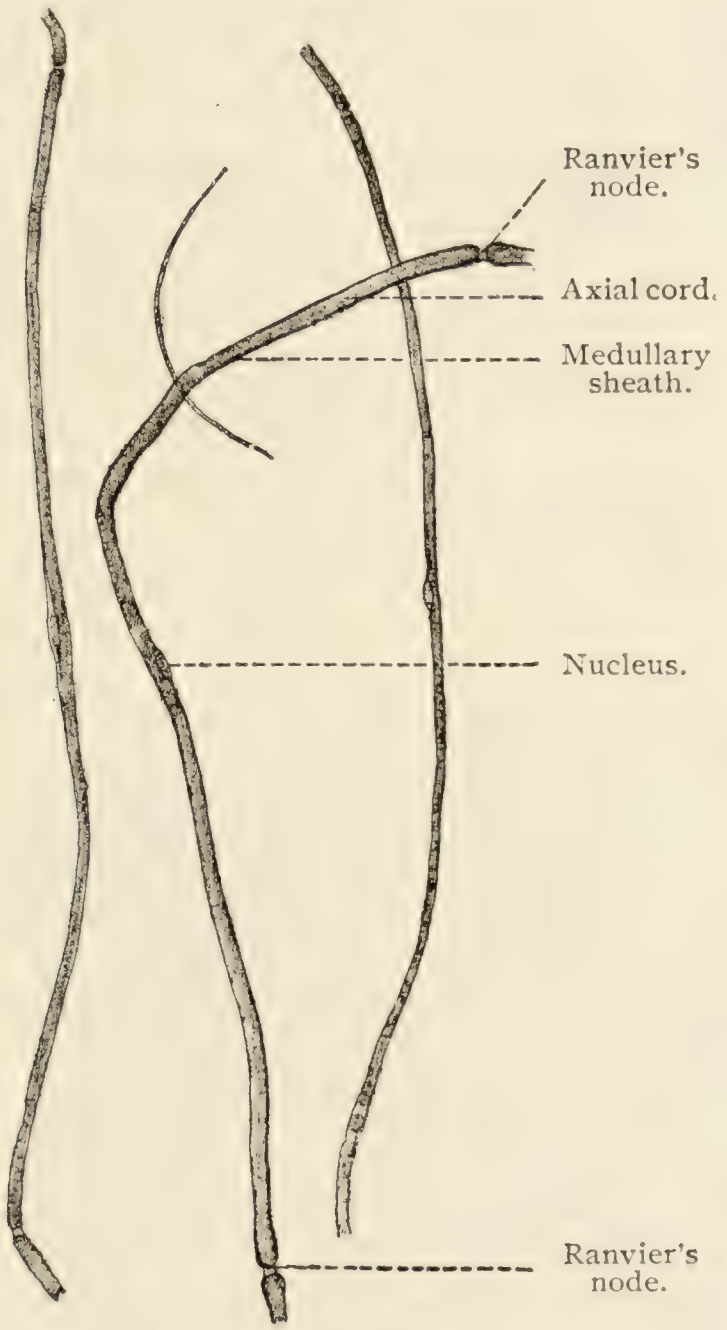

Fig. 120.—Medullated nerve-fibers from a rabbit, varying in thickness and showing internodal segments of different lengths. In the fiber at the left the neurilemma has become slightly separated from the underlying structures in the region of the nucleus; × 140.

Fig. 121.—Remak's fibers (nonmedullated fibers) from the pneumogastric nerve of a rabbit; × 360.

ameter, but whether this points to a corresponding variation in function has not been fully decided. Fine fibers possess a diameter of 2–4 μ, those of medium size 4–9 μ, and large fibers 9–20 μ (Kölliker, 93). A division of medullated fibers during their course through a nerve is relatively rare. The greater number of fibers pass unbranched from their central origin to the periphery, and only when in the neighborhood of their terminal arborization do they begin to divide. A point of division is always marked by a node of Ranvier.

The segmental structure of nerve-fibers would seem to give the impression that they are formed by a number of cells fused end to end. After what has been said with regard to ganglion cells and their processes, this can be the case only so far as the nerve-sheaths are concerned. According to this theory, the formative cells of the latter gather in chains along the neuraxes or dendrites, forming a mantle around them, and in the adult nerve-fibers taking the shape of the segments or internodes just described (His, 87 ; Boveri, 85). The points at which the sheath-cells are joined would then correspond to the nodes of Ranvier. Other investigators have concluded that the whole nerve-fiber is developed from a terminal apposition of ectodermal cells. In this case not only the sheaths of the fibers but also the corresponding portions of the nerve processes are formed by them (Kupffer, 90). In both theories the neurilemma corresponds to the cell-membrane ; in the former the neurilemma nucleus corresponds to that of the sheath-forming cell, in the latter to that of the formative cell of the whole nerve segment. It should be noticed that, according to the second theory, a fiber segment is the product of a single cell, while according to the first it is evolved from at least two cells (ganglion cell (process) and sheath-forming cell). The former theory is now very generally accepted.

The **nonmedullated** nerve-fibers, *Remak's fibers*, possess no medullary sheath ; the axial cord shows nuclei which can be regarded as belonging to a thin neurilemma. The majority of the neuraxes of the neurones of the sympathetic nervous system are of this structure, although small medullated nerve-fibers (the neuraxes of sympathetic neurones) are found in certain regions.

All nerve-fibers, medullated as well as nonmedullated, in the central and peripheral nervous systems lose the sheaths here described before terminating ; the axis-cylinders (axial cords) ending without special covering (naked axis-cylinders). These terminal branches are, in fixed and stained preparations, beset with small thickenings—varicosities—which vary greatly in size and shape. Nerve-fibers presenting such appearances are spoken of as varicosed fibers. The varicose enlargements may be regarded as small masses of neuroplasm ; the fine uniting threads, as representing the axial fibrils.

In the peripheral nervous system the nerve-fibers are grouped to form nerve-trunks. The nerve-fibers, as has been stated and as will be seen from the diagram (Fig. 122) on the next page, are the neuraxes of neurones, the cell-bodies of which are situated in the spinal cord or brain and in the sympathetic ganglia, and the dendrites of peripheral sensory neurones, the cell-bodies of which are found in the spinal and homologous cranial ganglia.

In the nerve-trunks the nerve-fibers are gathered into bundles termed *funiculi*. The nerve-fibers constituting such a bundle are separated by a small amount of fibro-elastic tissue, containing here and there connective-tissue cells, the *endoneurium*. This is continu-

ous with a dense, lamellated fibrous sheath surrounding each funiculus, the *perineurium*. Between the lamellæ of this sheath are lymph-spaces, communicating with the lymph-clefts found between the

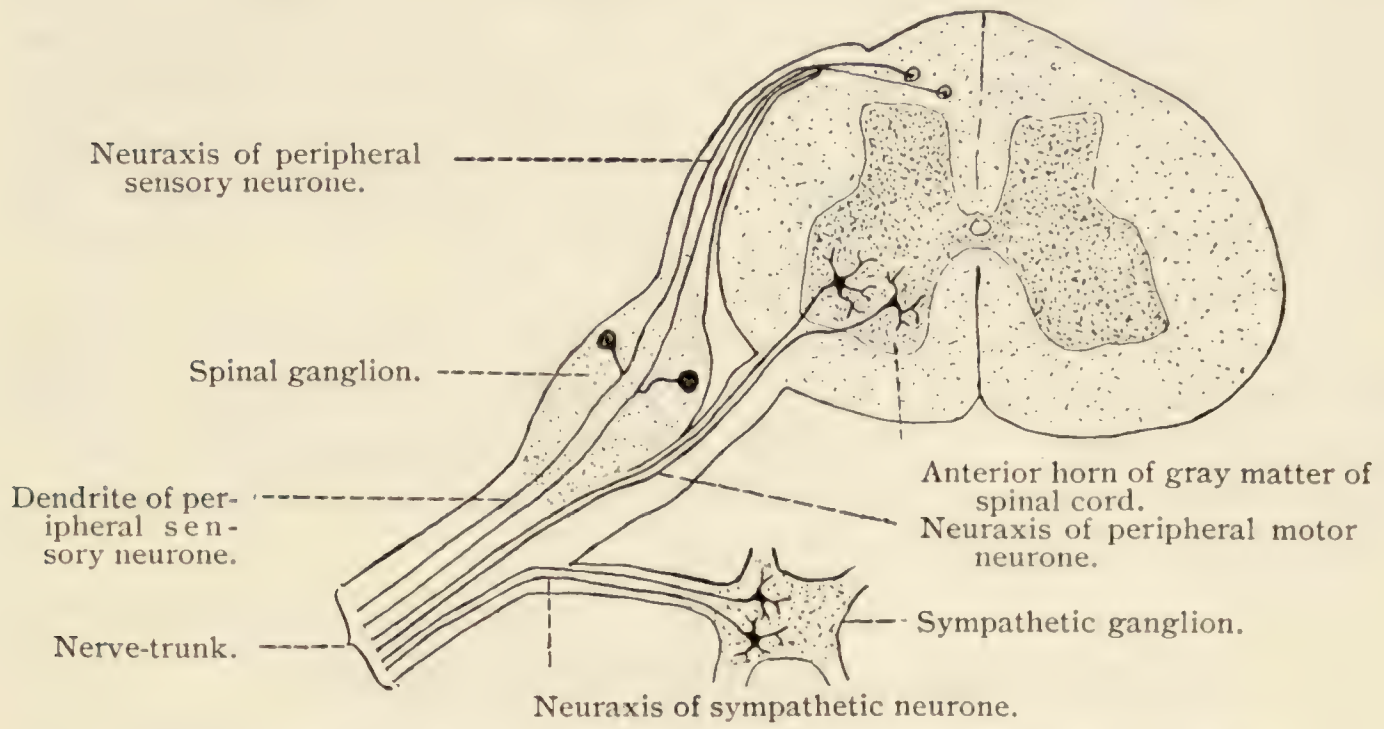

Fig. 122.—Diagram to show the composition of a peripheral nerve-trunk.

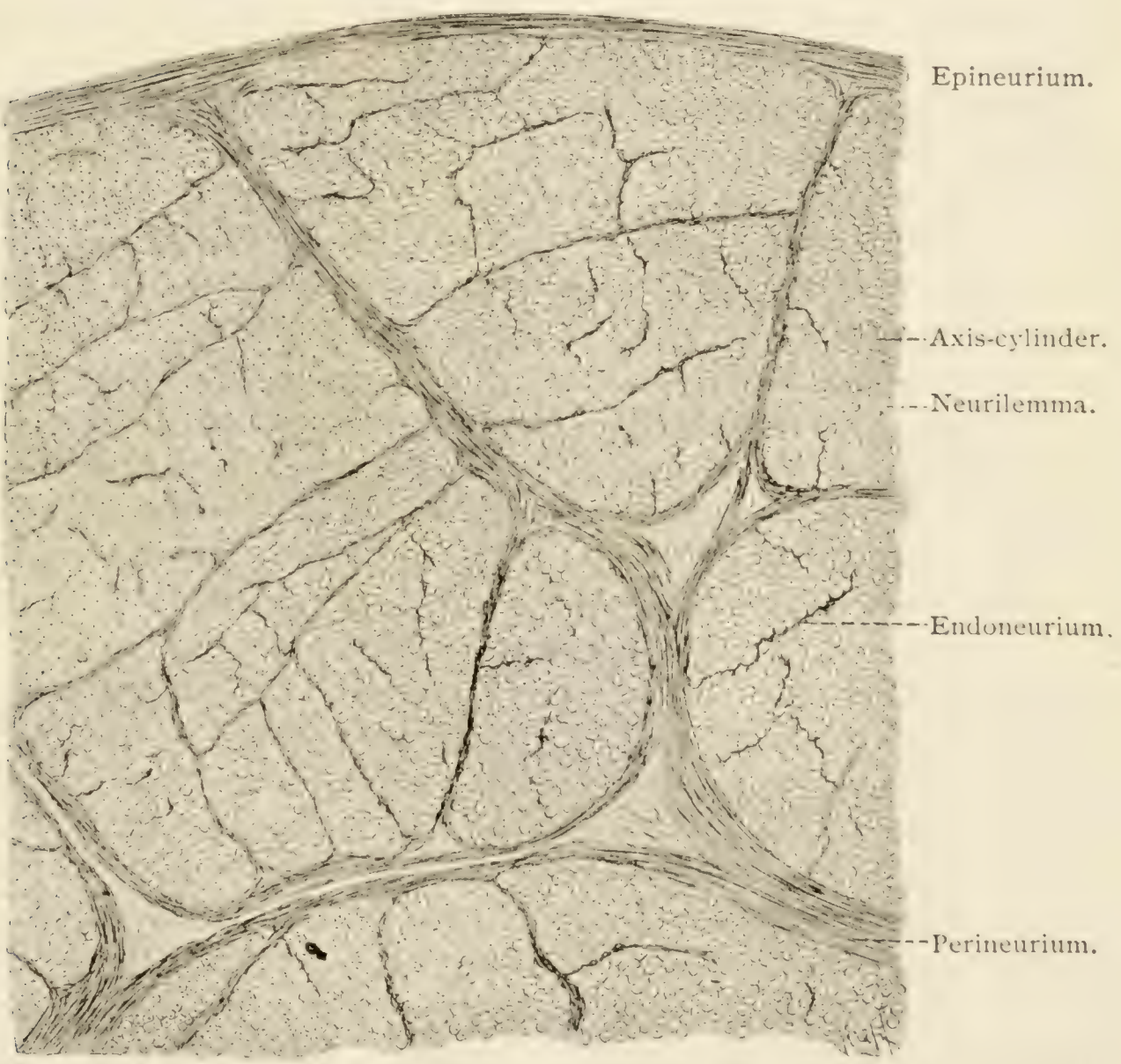

Fig. 123.—Part of a cross-section through a peripheral nerve treated with alcohol. The small circles represent the cross-sections of medullated nerve-fibers; the axis-cylinders show as points in their centers. The nerve is separated by connective tissue intc large and small bundles—funiculi; × 75.

nerve-fibers of the funiculi; consequently, the lamellæ are covered by a layer of endothelial cells. In the larger funiculi, septa of fibrous connective tissue pass from the perineurial sheath into the funiculi, dividing them into compartments varying in shape and size; these are spoken of as *compound funiculi*. The funiculi of a nerve-trunk are bound together by an investing sheath of loose fibro-elastic tissue, continuous with the perineurial sheaths, which penetrates between the funiculi, and which contains fat-cells, blood-vessels, and lymph-vessels; the latter are in communication with the lymph-spaces of the perineurial sheaths.

When a nerve-trunk divides, the connective-tissue sheaths above mentioned are continued on to the branches, and this even to the smallest offshoots. Thus, single fibers even possess a connective-tissue sheath,—*Henle's sheath*,—which consists of a few connective-tissue fibers and of flattened cells.

PERIPHERAL NERVE TERMINATIONS.

According to the character of the peripheral organs in which the telodendria of nerve-fibers (neuraxes of type I cells and dendrites of spinal ganglion cells) occur, the nerve-fibers are known as motor and sensory nerve-fibers, the terminations as motor and sensory nerve-endings.

Motor Nerve-endings (the Telodendria of Nerve-fibers Ending in Muscle Tissue).—The motor nerve-endings in striated, voluntary muscle tissue will first be considered. The motor nerve-endings in voluntary muscle tissue are the endings of neurones (peripheral motor neurones), the cell-bodies of which are situated in the ventral horns of the spinal cord and in the medulla. The neuraxes of these cells leave the cerebrospinal axis as medullated nerve-fibers (motor fibers) which, after branching, end in the muscle-fibers in the so-called motor endings. In figure 124 is represented, by way of diagram, a complete peripheral motor neurone. Each motor nerve-fiber branches repeatedly before terminating, although this branching does not often take place until near the termination of the nerve-fiber. Kölliker estimates that in the *sternoradialis* of the frog, each motor fiber innervates about twenty muscle-fibers; but whether this number may be regarded as the average number of muscle-fibers receiving their motor nerve-supply from one motor neurone can not be stated with any degree of certainty at the present time.

Each motor ending represents the termination of one of the terminal medullated branches of a motor nerve-fiber. The neuraxis of this fiber passes under the sarcolemma and terminates in a telodendrion (end-brush) in an accumulation of sarcoplasm, in which are found numerous muscle nuclei, forming a more or less distinct elevation on the side of the muscle-fiber, *Doyère's elevation*. The medullary sheath accompanies the nerve-fiber until it passes under the sarcolemma, when it stops abruptly. The neurilemma of the

nerve-fiber becomes continuous with the sarcolemma of the muscle-fiber at the place where the neuraxis passes under the sarcolemma. Henle's sheath continues over the motor ending as a thin sheath, containing here and there flattened nuclei, the *telolemma nuclei.*

With the majority of the reagents used to bring to view the motor endings, notably chlorid of gold, the sarcoplasm, in which

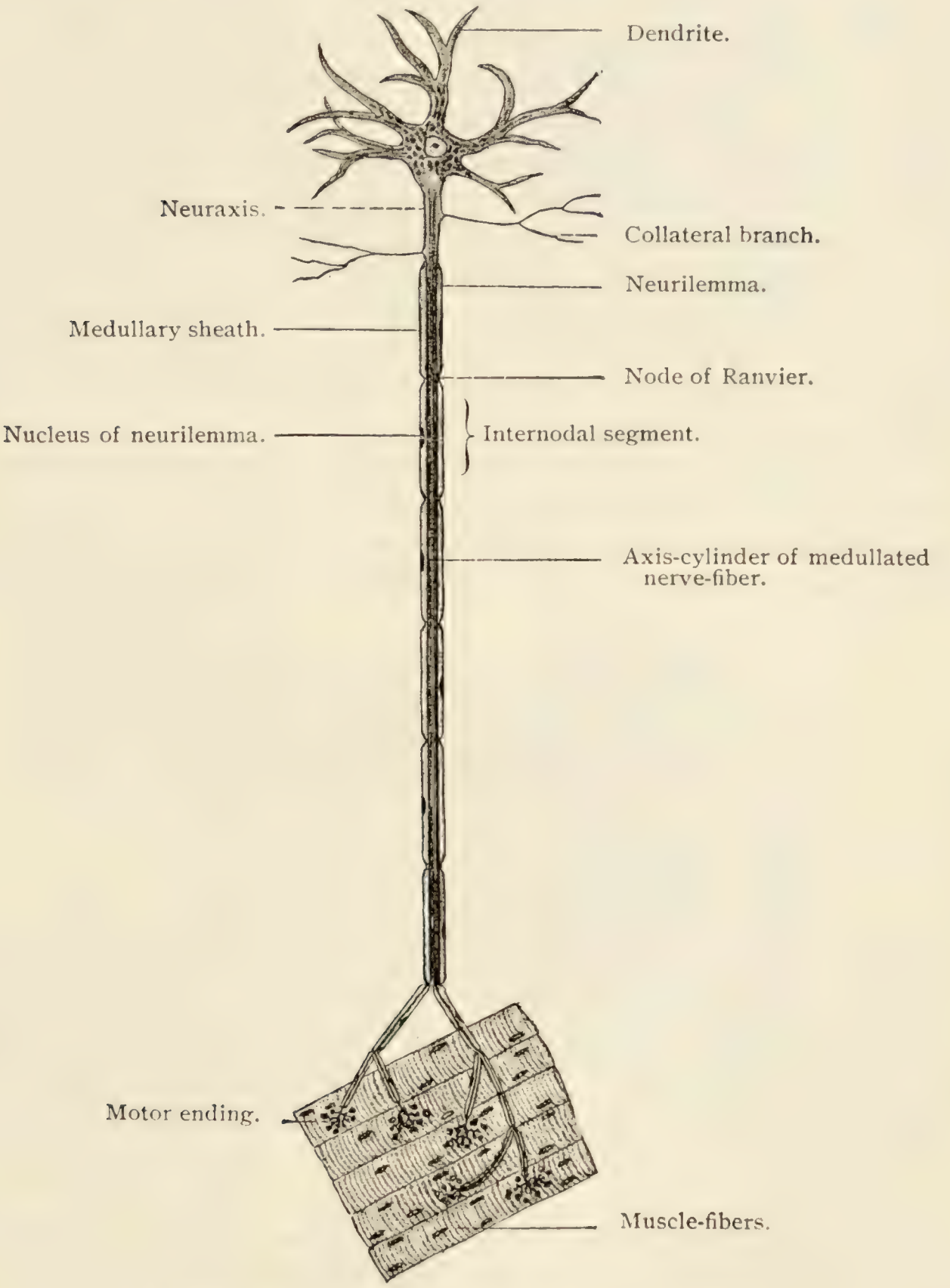

Fig. 124.—Diagram of peripheral motor neurone.

the telodendrion of the nerve-fiber is found, has a granular appearance, and is consequently differentiated from the remaining sarcoplasm of the muscle-fiber. To this the term *granular sole plate* has been applied, the nuclei contained therein being known as *sole nuclei,* the whole ending as the *motor end-plate.* If the above interpreta-

tion of the structure of the motor nerve-ending is correct, there would seem to be no reason why the sarcoplasm in which the telodendria occur should be considered other than the sarcoplasm of the muscle-fiber, the nuclei as muscle-nuclei ; the terms motor end-plate, granular sole plate, and sole nuclei would therefore seem unnecessary and misleading. It may be stated in this connection that Bardeen has recently shown that in teased muscle-tissue subjected to trypsin digestion the muscle substance may be removed from the fiber leaving the sarcolemma and on its inner surface a portion of the nerve-ending, with the neurolemma continuous with the sarcolemma. He has also shown that the motor ending is in part differentiated in connection with developing muscle-fibers before a sarcolemma can be shown on such fibers. In figures 126 to 130 are shown motor nerve-endings from several vertebrates as seen when stained with gold chlorid.

The mass of sarcoplasm in which the neuraxes terminate as above described is about 40 to 60 μ long, 40 μ broad, and 6 to 10 μ thick ; these dimensions vary greatly, however ; they may be greater or less than the averages here given.

In amphibia the motor nerve-endings are not so localized as in the majority of vertebrates, as above described, but are spread over a relatively greater surface of the muscle-fiber, and there is no distinct accumulation of the sarcoplasm, and the muscle-nuclei are

Fig. 125.—Motor nerve-ending in voluntary muscle of rabbit, stained in methylene-blue (*intra vitam*) (Huber, DeWitt, "Jour. Comp. Neurol.," vol. VII) : *A*, Surface view ; *B*, longitudinal section through motor ending ; *C*, cross-section : *a*, *a*, *a*, neuraxes of nerve-fibers ; *s*, *s*, *s*, sarcolemma ; *nl*, *nl*, neurilemma ; *d*, Doyère's elevation ; *m n*, muscle nuclei ; *t n*, telolemma nucleus.

relatively less numerous. The telodendrion of the nerve-fiber is, however, under the sarcolemma, between it and the contractile substance of the muscle-fiber. (Fig. 131.)

Usually only one motor ending is found on each striated muscle-fiber. This may be situated near the center of the muscle-fiber or at a variable distance from the center, nearer one or the other of its extremities. Now and then two nerve-endings are found on one muscle-fiber, in which case the nerve-endings are found in close proximity.

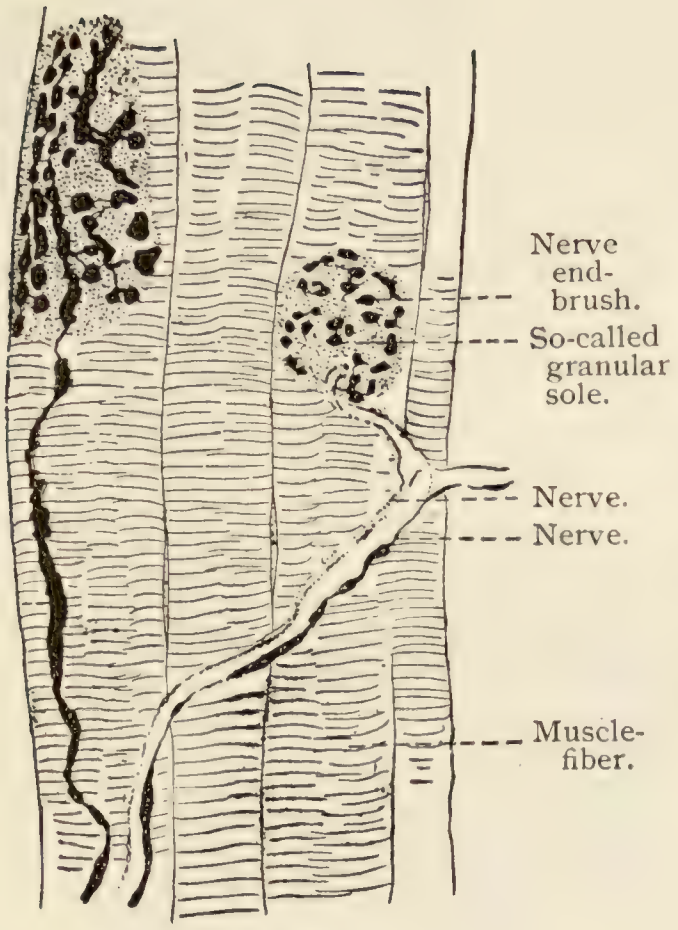

Fig. 126.

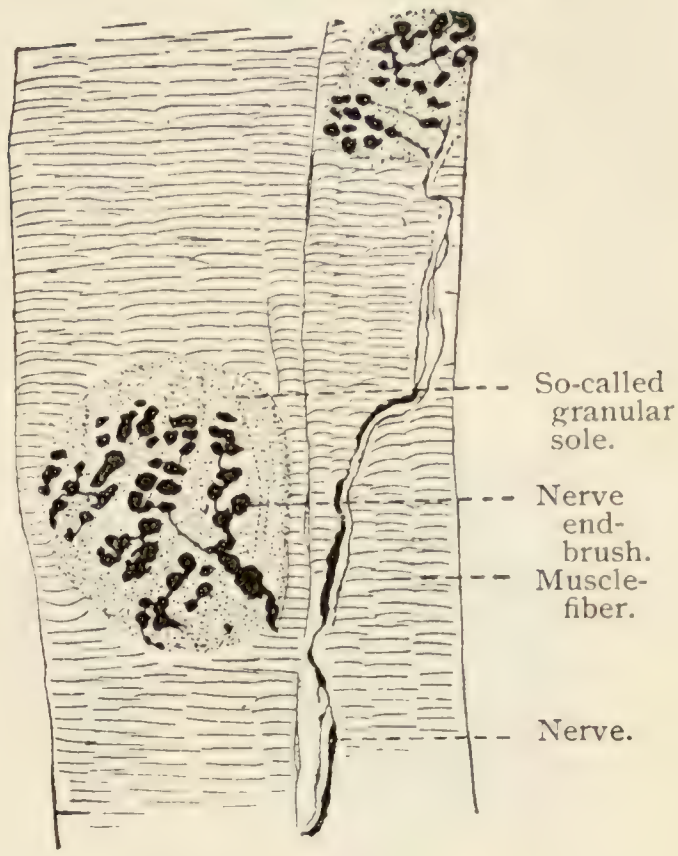

Fig. 127.

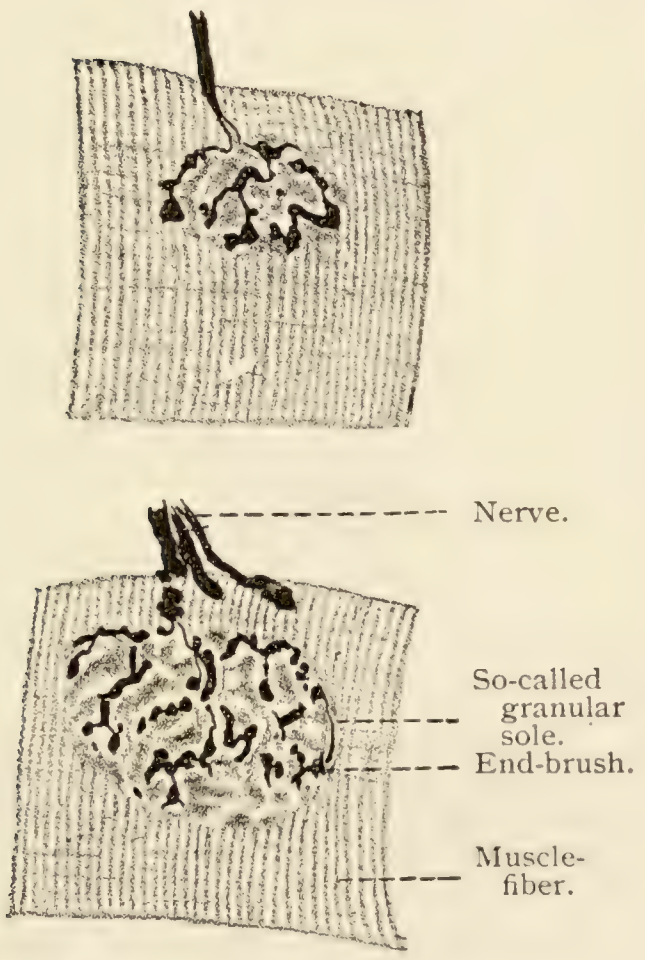

Figs. 128 and 129.

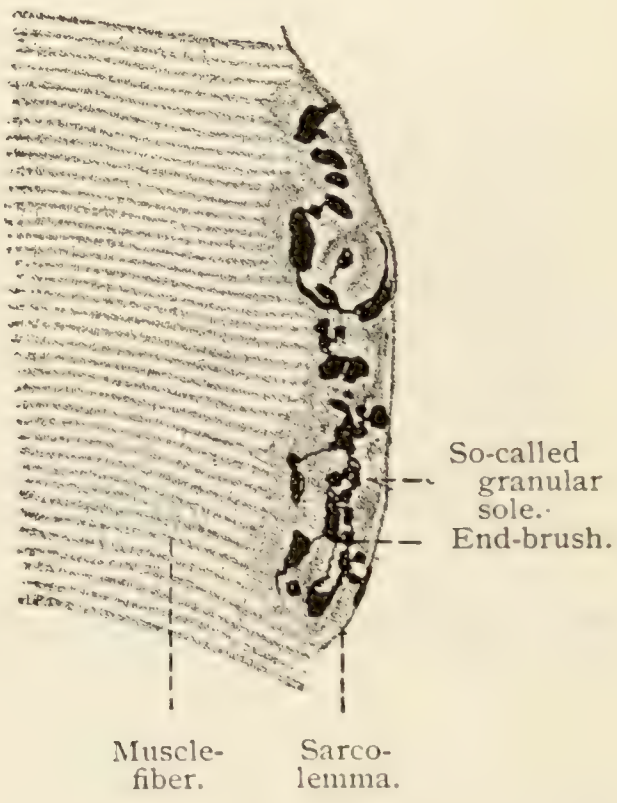

Fig. 130.

Figs. 126–130.—Motor endings in striated voluntary muscles.

Fig. 126, from *Pseudopus Pallasii;* × 160. Fig. 127, from *Lacerta viridis;* × 160. Figs. 128 and 129, from a guinea-pig; × 700. Fig. 130, from a hedge-hog; × 1200. As a consequence of the treatment the arborescence is shrunken and interrupted in its continuity. In Figs. 126 and 127 the end plate is considerably larger than in 128 and 129. In Fig. 126 it is in connection with two nerve-branches. Fig. 130 shows a section through an end-plate. The latter is bounded externally by a sharply defined line, which can be traced along the surface of the muscle-fiber. This is to be regarded as the sarcolemma.

Heart muscle and *nonstriated muscle* receive their motor nerve-supply from neurones of the sympathetic nervous system. The cell-bodies of these neurones are situated in sympathetic ganglia; the neuraxes, the majority of which form nonmedullated nerve-fibers, branch repeatedly, forming primary and secondary plexuses which surround the larger or smaller bundles of heart muscle-fibers or involuntary muscle-cells. From these plexuses, naked, varicosed axis-cylinders, or small bundles of such, penetrate between the heart muscle-fibers or involuntary muscle-cells, also forming

Fig. 131.—Motor nerve-ending in striated voluntary muscle of a frog; methylene-blue stain (*intra vitam*) (Huber, DeWitt): *A*, Surface view; *B*, cross-section; *s*, *s*, sarcolemma; *nl*, neurilemma.

Fig. 132. — Motor nerve-ending on heart muscle-cells of cat; methylene-blue stain (Huber, De Witt).



Fig. 133.—Motor nerve-ending on involuntary nonstriated muscle-cell from intestine of cat; methylene-blue stain (Huber, De Witt).

plexuses. The fine fibers of this terminal plexus give off from place to place small, lateral twigs, which end on the muscle-fiber and muscle-cells. In heart muscle these lateral twigs may end in one or two small granules, or in a small cluster of such granules (Fig. 132); in involuntary, nonstriated muscle the ending is very simple, the small lateral twigs terminating in one or two small granules. (Fig. 133.)

Sensory Nerve-endings.—The sensory nerve-endings are, in their essentials, the peripheral telodendria of dendrites of peripheral

sensory neurones. The cell-bodies of such neurones, as has been stated, are found in the spinal and homologous cranial ganglia. Of the two branches arising from the single process possessed by each peripheral sensory neurone, the one going to the periphery is regarded as the dendrite and forms the axis-cylinder of a medullated nerve-fiber, such nerve-fibers constituting the sensory nerves of the

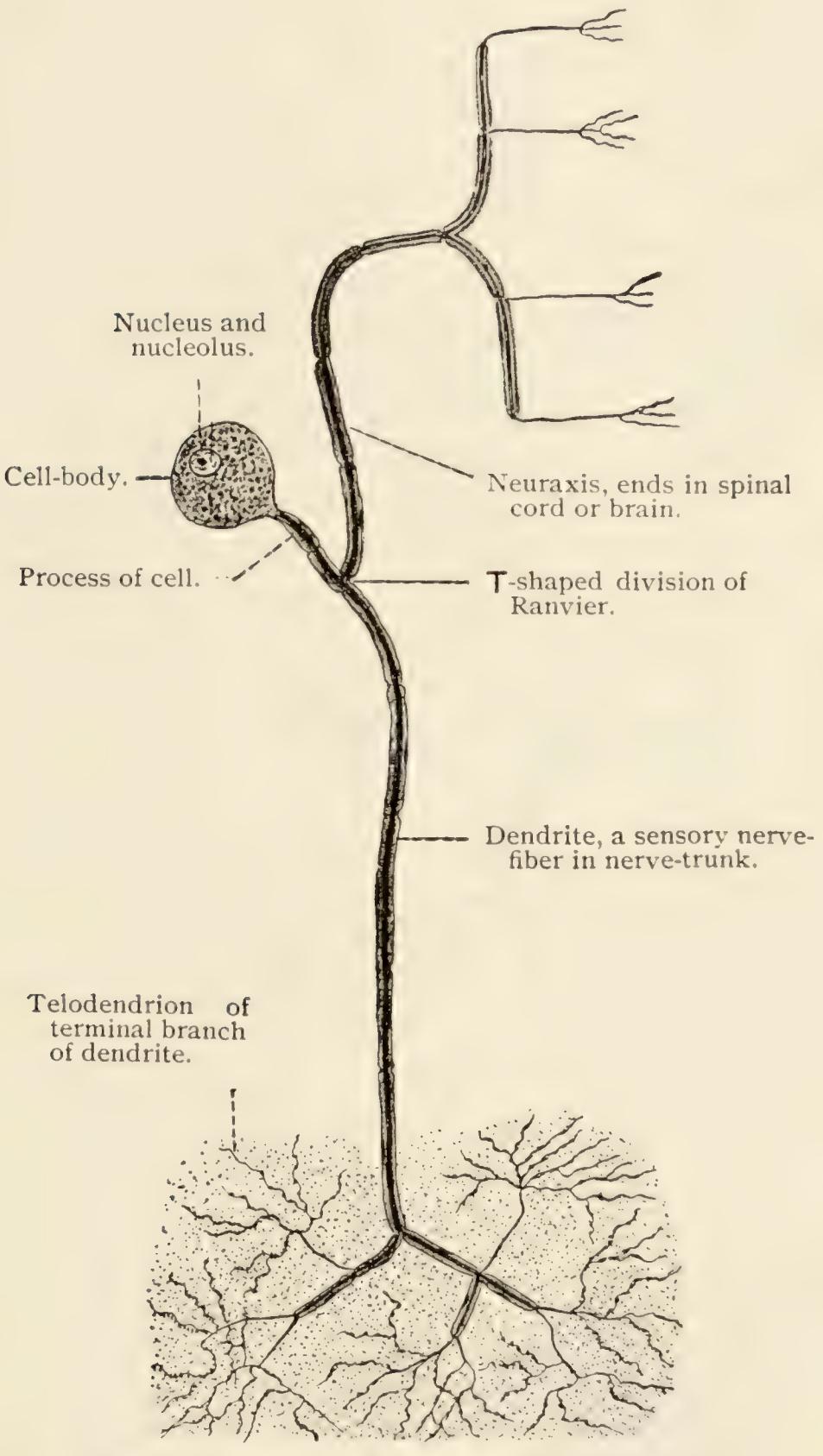

Fig. 134.—Diagram of a peripheral sensory neurone.

peripheral nerve-trunks. A peripheral sensory neurone may therefore be diagramed as in figure 134. The statement was made above that the essential portion of a sensory nerve-ending is a telodendrion (end-brush) or several telodendria of the dendrite of a peripheral sensory neurone. The character of a sensory nerve-

ending depends, therefore, on the complexity of this end-brush and on its relation to the other tissue elements which take part in the formation of the sensory nerve-endings. Bearing this in mind, the

Fig. 135.—Termination of sensory nerve-fibers in the mucosa and epithelium of the urethra of cat; methylene-blue preparation (Huber, "Jour. Comp. Neurol.," vol. x).

following classification of such nerve-endings can be made:

1. *Free Sensory Nerve-endings.*—In these the telodendrion is not

inclosed in an investing capsule which forms a structural part of the ending.

2. *Encapsulated Endings.*—In which the telodendrion or several telodendria are surrounded by an investing capsule which separates them more or less completely from the surrounding tissue.

1. **Free sensory nerve-endings** are found in all epithelial tissues and in fibrous connective tissue of certain regions. A sensory nerve-fiber terminating in such an ending usually proceeds without branching to near its place of termination, where, while yet a medullated fiber, it branches and rebranches a number of times, always at the nodes of Ranvier, the resultant branches diverging at various angles. If the free sensory endings are in epithelial tissue, these larger medullated branches are situated in the connective-tissue mucosa under the epithelium. From these larger medullated branches, are given off smaller ones, also medullated, which may divide further, and which pass up toward the epithelium, and near its under surface divide into nonmedullated branches. Nonmedullated branches are also given off from the medullated ones as they approach the epithelium, leaving the parent fibers at the nodes of Ranvier. Many of the nonmedullated branches thus formed, after coursing a variable distance under the epithelium, enter it and break up into numerous very small branches, which, after repeated division, terminate between the epithelial cells in small nodules or discs of variable size and configuration. The small branches resulting from a division of one of the larger nonmedullated branches constitute one of the terminal telodendria or end-branches of the dendrites of peripheral sensory neurones terminating in free sensory nerve-endings. In fibrous connective tissue the same general arrangement of the branches prevails. In figure 135 is shown the peripheral distribution of the dendrite of a peripheral sensory neurone terminating in a free sensory nerve-ending.

2. **Encapsulated Sensory Nerve-endings.**—These nerve-endings may be divided into two quite distinct groups,—such as have a relatively thin fibrous-tissue capsule, containing mainly telodendria of the nerve or nerves terminating therein, and such as have a distinctly lamellated, fibrous tissue capsule, usually investing, besides the nerve-termination, other tissue elements. To the former group belong three types of sensory nerve-endings, which, owing to their similarity of structure, may be described together. These are the end-bulbs of Krause, Meissner's tactile corpuscles, and the genital corpuscles. They have all been investigated recently by

Fig. 136.—End-bulb of Krause from conjunctiva of man; methylene-blue stain (Dogiel, "Arch. f. mik. Anat.," vol. XXXVII).

Dogiel, and the account here given follows closely his description.

End-bulbs of Krause.—Under this designation there are described a variety of endings which vary slightly in size and shape. They are found in the conjunctiva and edge of the cornea, in the lips and lining of the oral cavity, in the glans penis and clitoris, and probably also in other parts of the dermis. In form they are round, oval, or pear-shaped. Their size varies from 0.02 to 0.03 mm. long and from 0.015 to 0.025 mm. broad for the smaller ones, and from 0.045 to 0.10 mm. long and from 0.02 to 0.08 mm. broad for the larger ones. They have a relatively thin capsule in which nuclei are quite numerous. One, two, or three medullated nerves go to each end-bulb. These may lose their medullary sheath at the capsule or at a variable distance from it. The naked axis-cylinders, soon after entering the capsule, divide into two, three, or four branches, which form several circular or spiral turns in the same or in opposite directions. These fibers then divide into varicose branches, which undergo further division, the resulting branches interlacing to form a bundle of variously tangled fibers which may be loosely or tightly woven.

Between the nerve-fibers and their branches, within the capsule, there is found a semifluid substance, which is granular in fixed preparations.

Fig. 137.—Meissner's tactile corpuscle; methylene-blue stain (Dogiel, "Internat. Monatsschr. f. Anat. u. Phys.," vol. IX).

Meissner's Corpuscles.—These corpuscles are found in man in the subepidermal connective tissue of the hand and foot and outer surface of the forearm, in the nipple, border of the eyelids, lips, glans penis and clitoris. They are most numerous in the palmar surface of the distal phalanx of the fingers. They are oval in shape, sometimes somewhat irregular, and vary in size, being from 45 μ to 50 μ broad and from 110 μ to 180 μ long. They possess a thin connective-tissue capsule, in which are found round or oval nuclei, some of which have an oblique position to the axis of the corpuscle. One medullated nerve ends in the smaller corpuscles, two or three or even more in the larger ones. After piercing the capsule, the medullated nerves lose their medullary sheaths, the naked axis-cylinders making a variable

number of circular or spiral turns, some of which are parallel, others crossing at various angles. These larger branches are all beset with large, spindle-shaped, round, or pear-shaped varicosities. The larger branches, after making the windings mentioned, break up into many varicose branches, which interlace and form a most complex network. One usually finds one or several larger naked axis-cylinders, which pass up through the axis of the spiral of fibers thus formed; these give off branches which contribute to the spiral formation.

Genital Corpuscles.—These corpuscles are found in the deeper part of the mucosa of the glans penis and the prepuce of the male and the clitoris and neighboring structures of the female. Their shape varies; they may be round, oval, egg- or pear-

Fig. 138.—Genital corpuscle from the glans penis of man; methylene-blue stain (Dogiel, "Arch. f. mik. Anat.," vol. XLI).

shaped, or even slightly lobulated. Their size varies from 0.04 to 0.10 mm. in breadth and from 0.06 to 0.40 mm. in length. They are surrounded by a relatively thick fibrous capsule, consisting of from three to eight quite distinct lamellæ, between which irregular flattened cells with round or oval nuclei are found. Within this capsule, there is found a core, which seems to consist of a semi-fluid substance, slightly granular in fixed preparations, the nature of which is not fully known. The number of sensory nerves going to each corpuscle varies from one to two for the smaller ones, and from eight to ten for the larger corpuscles. The medullated nerves, after entering the corpuscle, divide dichotomously, the resultant branches assuming a circular or spiral course, and interlacing in various ways, within the capsule. After a few turns, the medullated

branches lose their medullary sheaths and undergo further division, often dividing repeatedly. The nonmedullated nerves resulting from these divisions, the majority of which are varicose, form a most complicated network, the whole nerve network presenting a structure which resembles a tangle of fine threads. In the meshes of this network is found the semifluid substance of the core. Now and then some of the larger fibers of the network leave the corpuscle and terminate in neighboring corpuscles, or pass to the epithelium, where they end between the cells.

These three sensory nerve-endings—end-bulbs of Krause, Meissner's tactile corpuscles, genital corpuscles—are, as Dogiel has stated, very similar in structure. Each has a thin connective-tissue capsule, surrounding a core, consisting of a semifluid substance, concerning which our knowledge is as yet imperfect. One or several medullated nerves go to each corpuscle, which, after losing their medullary sheaths, divide and subdivide into numerous fine varicose branches, which are variously interwoven, forming a more or less dense plexus of interlacing and, according to Dogiel, anastomosing fibers. The chief differences are those of form and size, and of position with reference to the epithelium. Of the three forms of endings, the genital corpuscle is the largest, and occupies the deepest position in the subepithelial connective tissue; Meissner's corpuscle is intermediate in size, and is found immediately under the epithelium; while the end-bulbs of Krause are the smallest of these



Fig. 139.—Cylindric end-bulb of Krause from intermuscular fibrous tissue septum of cat; methylene-blue stain.

three forms of sensory endings and may be found in the papillæ or in the deeper connective tissue.

A somewhat smaller nerve-ending of long, oval, or cylindric form, known as the *cylindric end-bulb of Krause*, is found in various parts of the skin and oral mucous membrane, in striated muscle and in tendinous tissue. These corpuscles consist of a thin nucleated capsule, investing a semifluid core. The nerve-fiber, after losing its medullary sheath and fibrous sheath (the latter becomes continuous with the capsule), passes through the core, generally without branching, as a naked axis-cylinder, terminating at its end, usually in a small bulb. (Fig. 139.)

The majority of the sensory nerve-endings with well-developed

lamellated capsules are relatively large structures. We shall consider especially the Vater-Pacinian corpuscles, the neuromuscular end-organs, and the neurotendinous end-organs.

Vater-Pacinian Corpuscles.—These corpuscles are of oval shape and vary much in size, the largest being about 0.10 of an inch long and 0.04 of an inch broad. The greater portion of the corpuscle is made up of a series of concentric lamellæ, varying in number from twenty to sixty. These lamellæ are made up of

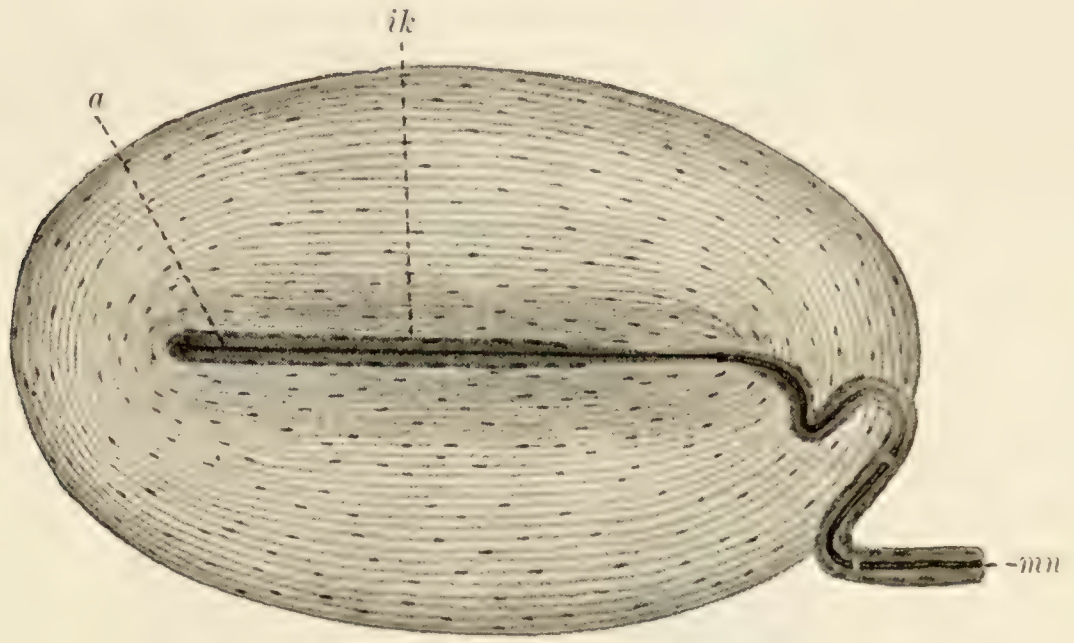

Fig. 140.—Vater-Pacinian corpuscle from the mesentery of a cat; × 45. The figure shows a general view of the corpuscle. *a*, Axis-cylinder in the core; *ik*, core; *mn*, medullated nerve-fibers entering the core ("Atlas and Epitome of Human Histology," Sobotta).

white fibrous tissue fibers, rather loosely woven, between which is found a small amount of lymph, containing usually a few leucocytes. The lamellæ are covered on both surfaces by a layer of endothelial cells (Schwalbe). Between two consecutive lamellæ there is found an interlamellar space, also containing lymph. The axis of the corpuscle is occupied by a core, consisting of a semifluid, granular substance, in the periphery of which oval nuclei are said to be found. Usually one large medullated nerve-fiber goes to each corpuscle. The fibrous tissue sheath of this nerve-fiber becomes continuous with the outer lamellæ of the capsule. The medullary sheath accompanies the axis-cylinder through the concentric lamellæ until the core is reached, where it disappears. The naked axis-cylinder usually passes through the core to its distal end, where it divides into three, four, or five branches which terminate in large, irregular end-discs. The axis-cylinder may, however, divide soon after it enters the core into two or three or even four branches, these passing to the distal end of the core before terminating in the end-discs above mentioned. Both Retzius and Sala state that the naked axis-cylinders, after entering the core, give off numerous short side branches, terminating in small knobs, which remind these observers of the fine side branches or thorns seen on the dendrites of Purkinje's cells and of the pyramidal cells of the cortex, when stained

after the Golgi method. In company with the large nerve-fibers here mentioned, Sala has described other nerve-fibers, quite independent of them and much finer, which after entering the corpuscle divide repeatedly, the resulting fibers forming a plexus around the central fiber. A small arteriole enters the corpuscle with the nerve-fiber, dividing into capillary branches found between the lamellæ of the capsule.

The Vater-Pacinian corpuscles have a wide distribution. They are numerous in the deeper parts of the dermis of the hand and foot, and also near the joints, especially on the flexor side. They have been found in the periosteum of certain bones and in tendons and intermuscular septa, and even in muscles. They are further found in the epineurial sheaths of certain nerve-trunks and near

Fig. 141.—Pacinian corpuscles from mesorectum of kitten: *A*, Showing the fine branches on central nerve-fiber; *B*, the network of fine nerve-fibers about the central fiber; methylene-blue preparation (Sala, "Anat. Anzeiger," vol XVI).

large vessels. They are numerous in the peritoneum and mesentery, pleura and pericardium. In the mesentery of the cat, where these nerve-endings are large and numerous, they are readily seen with the unaided eye as small, pearly bodies.

In the bill and tongue of water birds, especially of the duck, are found nerve-endings, known as the *corpuscles of Herbst*, which resemble the Vater-Pacinian corpuscles; they differ from the latter in having cubic cells in the core. (Fig. 142.)

Neuromuscular Nerve End-organs.—These nerve end-organs consist of a small bundle of muscle-fibers, surrounded by an invest-

ing capsule, within which one or several sensory nerves terminate. They are spindle-shaped structures varying in length from 0.75 to 4 mm., and in breadth, where widest, from 80 to 200 μ (Sherrington, 94). In them there is recognized a *proximal polar region*, an *equatorial region*, and a *distal polar region*. The muscle-fibers of this nerve-ending, known as the *intrafusal fibers*, which may vary in number from 3 or 4 to 20 or even more, are much smaller than the ordinary voluntary muscle-fibers and differ from them structurally, and result from a division of one or several muscle-fibers of the red variety. In the proximal polar region the intrafusal fibers present an appearance which is similar to that of voluntary muscle-fibers of the red variety; in the equatorial region they possess rela-

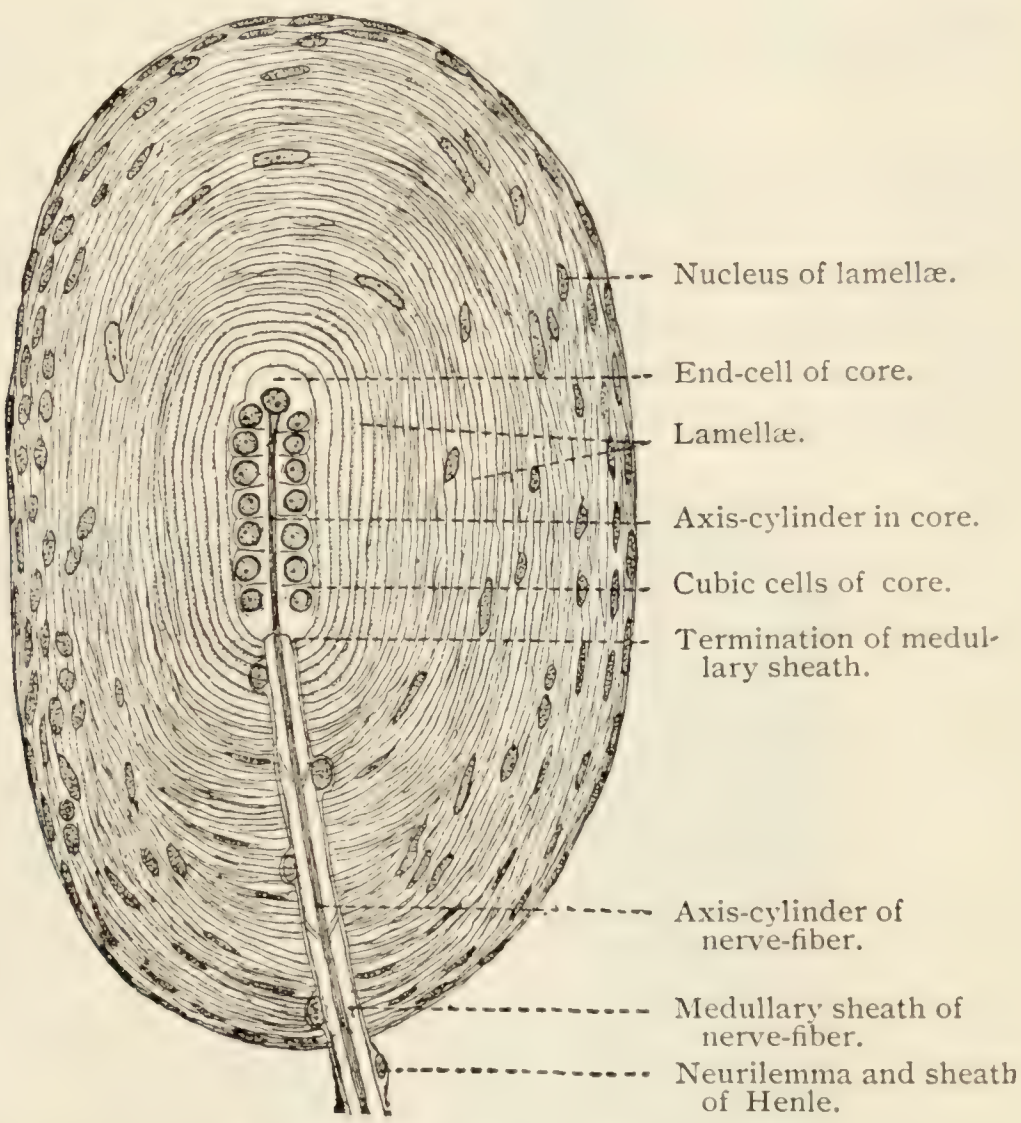

Fig. 142.—Corpuscle of Herbst from bill of duck; × 600.

tively few muscle-fibrils and are rich in sarcoplasm and the muscle-nuclei are numerous; the striation is here indistinct. In the distal polar region the intrafusal fibers are again more distinctly striated and, a short distance beyond the end-organ, become greatly reduced in size, and terminate as very small fibers, still showing, however, a cross-striation. In figure 143 is shown a single intrafusal muscle-fiber. Owing to the length of such a fiber it was necessary to represent it in several segments.

The intrafusal muscle-fibers are surrounded by a capsule consisting of from four to eight concentric layers of white fibrous tissue. At the proximal end this capsule is continuous with the connective

tissue found between the muscle-fibers—endo- and perimysium. It attains its greatest diameter in the equatorial region of the nerve end-organ, and becomes narrower again at its distal end, where it may end in tendon or become continuous with the connective tissue

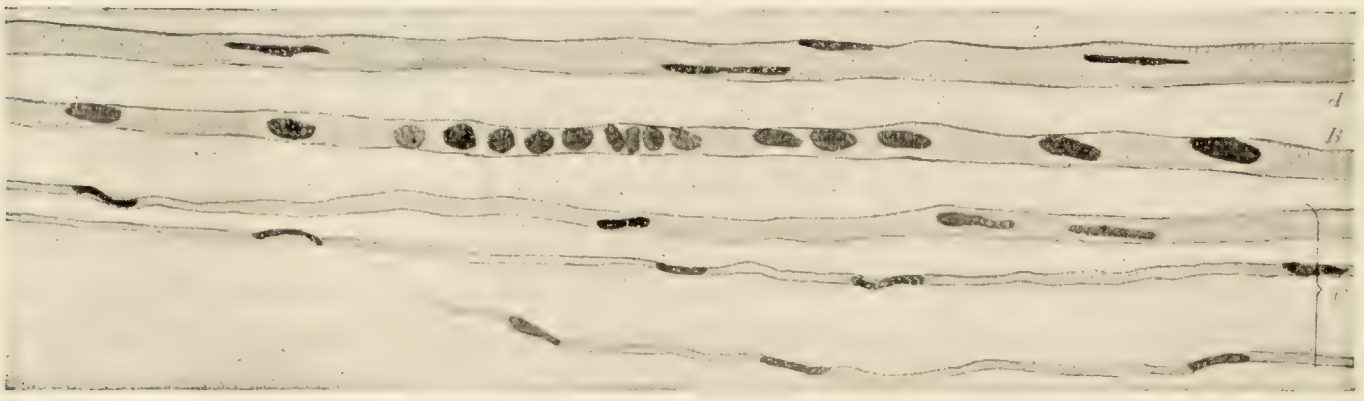

Fig. 143.—Intrafusal muscle-fiber from neuromuscular nerve end-organ of rabbit: *A*, From proximal polar region; *B*, equatorial region; *C*, distal polar region.

of the muscle. Immediately surrounding the intrafusal fibers is found another connective-tissue sheath known as the *axial sheath*, and between this and the capsule there is found a lymph-space bridged over by trabeculæ of fibrous tissue, to which the name *periaxial lymph-space* has been given. (Fig. 144.)

By degenerating the motor nerves going to a muscle, Sherrington

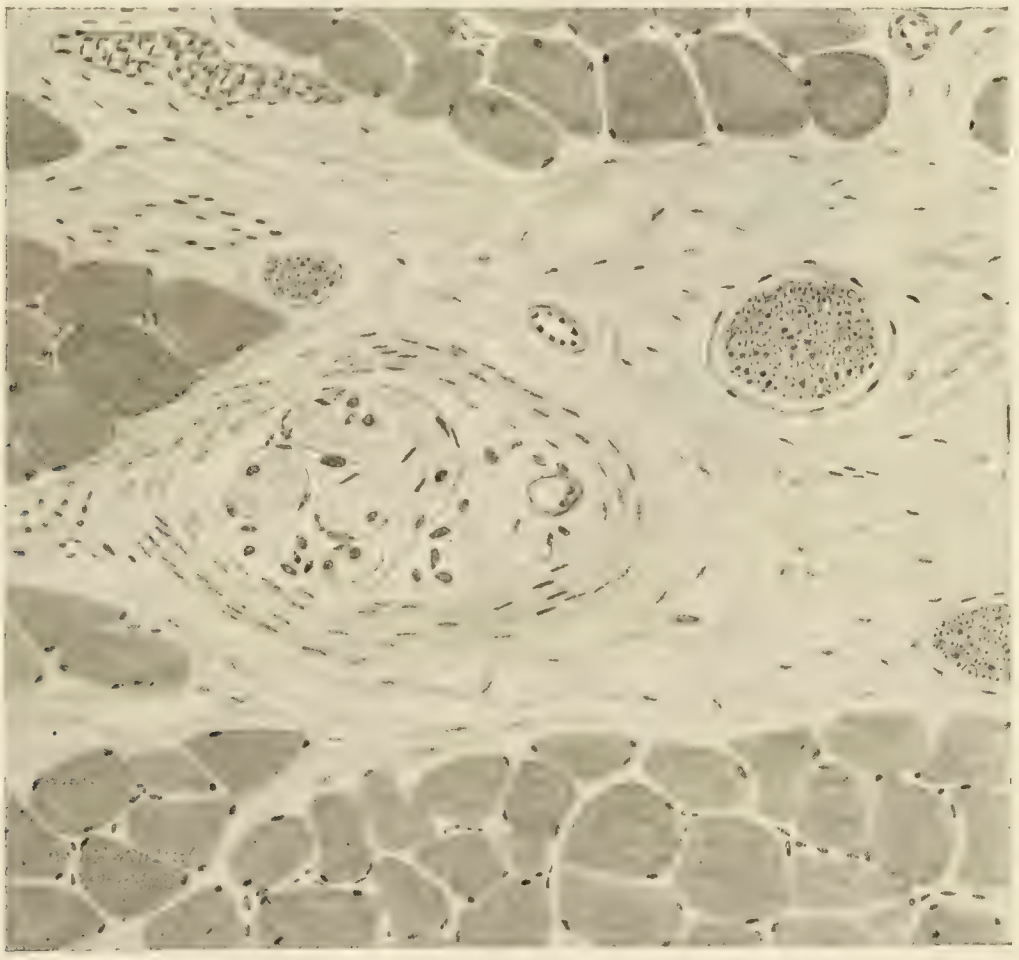

Fig. 144.—Cross-section of a neuromuscular nerve end-organ from interosseous (foot) muscle of man; fixed in formalin and stained in hematoxylin and eosin.

determined that the nerve-fibers ending in the neuromuscular nerve end-organs were sensory in character. The manner of termination in these end-organs of the nerve-fibers ending therein has been studied by Kerschner, Kölliker, Ruffini, Huber and DeWitt, Dogiel, and

others. One or several (three or four) large medullated nerves, surrounded by a sheath of Henle, terminate in each neuromuscular end-

Fig. 145.—Neuromuscular nerve end-organ from the intrinsic plantar muscles of dog; from teased preparation of tissue stained in methylene-blue. The figure shows the intrafusal muscle-fibers, the nerve-fibers and their terminations; the capsule and the sheath of Henle are not shown (Huber and DeWitt, "Jour. Comp. Neurol.," vol. VII).

organ. As these nerves enter the capsule, the sheath of Henle blends with the capsule. The medullated nerve-fibers now and

then divide before reaching the nerve end-organs, and divide several times as they pass through the capsule, periaxial space, and axial sheath. Within the axial sheath, the medullary sheath is lost, and the naked axis-cylinders terminate in one or several ribbon-like branches which are wound circularly or spirally about the intrafusal fibers (*annulospiral ending*) or they may terminate in a number of larger branches which again divide, these ending in irregular, round, oval, or pear-shaped discs (*flower-like endings*), which are also on the intrafusal fibers. These flower-like endings are usually at the ends of the annulospiral fibers. In the smaller end-organs only one area of nerve-termination has been observed; in the larger, two, three, or even four such areas may be found.

Fig. 146. — Neurotendinous nerve end-organ from rabbit; teased preparation of tissue stained in methylene-blue (Huber and DeWitt, "Jour. Comp. Neurol.," vol. x).

Neuromuscular nerve end-organs are found in nearly all skeletal muscles (not in the extrinsic eye muscles nor in the intrinsic muscles of the tongue), but they are especially numerous in the small muscles of the hand and foot. They are found in amphibia, reptilia, birds, and mammalia, presenting the same general structure, although the ultimate termination of the nerve-fibers varies somewhat in the different classes of vertebrates.

Neurotendinous Nerve End-organ (Golgi Tendon Spindle). — In 1880 Golgi drew attention to a new nerve end-organ found in tendon, describing quite fully its general structure and less fully the nerve termination found therein. These nerve end-organs are spindle-shaped structures, which in man vary in length from 1.28 mm. to 1.42 mm., and in breadth from 0.17 mm. to 0.25 mm. (Kölliker). Ciaccio mentions a neurotendinous nerve end-organ found in a woman, which was 2 or 3 mm. long. A capsule consisting of from 2 to 6 fibrous tissue lamellæ, and broadest at the equatorial part of the end-organ, surrounds a number of in-

trafusal tendon fasciculi. The capsule is continuous at the proximal and distal ends of the end-organ with the internal peritendineum of the tendon in which it is found. The number of the intrafusal tendon fasciculi varies from eight to fifteen or even more. They are smaller than the ordinary tendon fasciculi, from which they originate by division, and structurally resemble embryonic tendon, in that they stain more deeply and present many more nuclei than fully developed tendon. The intrafusal tendon fasciculi are surrounded by an axial sheath of fibrous tissue, between which and the capsule there is found a periaxial lymph-space.

Fig. 147.—Cross-section of neurotendinous nerve end-organ of rabbit; from tissue stained in methylene-blue: *m*, Muscle-fibers; *t*, tendon; *c*, capsule of neurotendinous end-organ; *m n*, medullated nerve-fiber (Huber and DeWitt, "Jour. of Comp. Neurol.," vol. X).

The termination of the nerve-fibers ending in these end-organs has been studied by Golgi, Cattaneo, Kerschner, Kölliker, Pansini, Ciaccio, Huber and DeWitt. One, two, or three large medullated nerve-fibers, surrounded by a sheath of Henle, end in each end-organ; as they pass through the capsule, the sheath of Henle blends with the capsule. The medullated nerve-fibers before entering the capsule usually branch several times, branching further within the capsule and axial sheath. Before the resultant branches terminate on the intrafusal tendon fasciculi, the medullary sheath is

lost, the naked axis-cylinder further dividing into two, three, or four branches, each of which runs along on the intrafusal fasciculi, giving off numerous short, irregular side branches, which partly enclasp the tendon fasciculi and end in irregular end-discs. Some of the terminal branches pass between the smaller fibrous tissue bundles of the fasciculi, ending between them.

In these end-organs, the larger nerve-branches are found near the center of the bundle of intrafusal tendon fasciculi, the terminal branches and the end-discs nearer their periphery. The neurotendinous nerve end-organs are widely distributed, being found in all tendons although not equally numerous in all. Like the neuromuscular nerve end-organs, they are especially numerous in the small tendons of the hand and foot. Sensory nerve end-organs, which resemble in structure the neurotendinous end-organs here described, though somewhat smaller than these, have been found in the tendons of the extrinsic eye-muscles.

In this brief account of the mode of ending of the telodendria of the dendrites of peripheral sensory neurones (sensory nerve-fibers) it has not been possible to discuss any but the more typical varieties of sensory nerve-endings. Other nerve-endings will be considered in connection with the several organs to be treated later. For a fuller discussion of this subject, the reader is referred to special works and monographs.

TECHNIC.

Fresh medullated nerve-fibers, when teased in an indifferent fluid, show the peculiar luster of the medullary sheath, and also the nodes of Ranvier, the neurilemma with its nuclei, and the segments of Lantermann. At the cut ends of the fibers, the typical coagulation of their medullary portions is seen in the form of drops of myelin. All these structures can also be seen after using 1% osmic acid. A nerve (not too thick) is placed in a 1% aqueous osmic acid solution, then washed for a few hours in distilled water, and finally carried over into absolute alcohol. After dehydration, small pieces are cleared with oil of cloves and the fibers teased apart upon a slide. The medullary sheath is stained black and hides the axial space, the nodes are clear, the neurilemma is sometimes seen as a light membrane, and the nuclei of the fibers are of a lenticular shape, and stained brown.

The nodes of Ranvier may also be demonstrated by means of silver nitrate solution. Fresh nerve-fibers are either teased in distilled water to which a trace of 1% silver nitrate solution has been added (the nodes of Ranvier appear after a short time as small crosses), or whole nerves are placed for twenty-four hours in a 0.5% aqueous solution of silver nitrate, washed for a short time with water, hardened in alcohol, after which they are imbedded in paraffin and cut longitudinally. Exposure to light will soon bring out the "crosses of Ranvier" at the nodes. The appearance of these crosses is due to the fact that the silver nitrate solution first penetrates at the nodes of Ranvier, and then passes by capillary attraction along the axial cord for some distance. After the reduction of the silver, the cruciform figures appear colored

black. Occasionally, a peculiar transverse striation is seen in the longitudinal portions of the crosses. These are known as Frommann's lines. Their origin and significance have not as yet been satisfactorily explained.

To demonstrate the fibrils of the axial cord a piece of a small nerve is stretched on a match or toothpick and fixed for four hours in a 0.5% osmic acid solution, after which it is washed in water for the same length of time and immersed in 90% alcohol for twenty-four hours. The preparation is now stained for another twenty-four hours in a saturated aqueous solution of fuchsin S and then placed for three days in absolute alcohol. Finally, the nerve is passed as rapidly as possible through toluol, toluol-paraffin, and then imbedded in paraffin. The proper orientation of the specimen is of the greatest importance, as is also the cutting of thin sections. In a longitudinal section red fibrils of almost uniform thickness and evenly distributed throughout the axial space are seen lying in the colorless neuro-

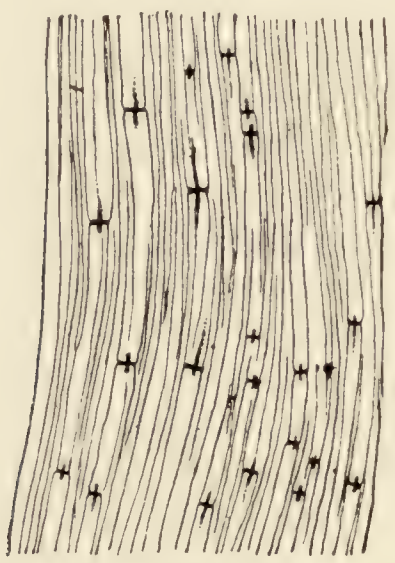

Fig. 148.—Ranvier's crosses from sciatic nerve of rabbit treated with silver nitrate solution; × 120. Frommann's lines can be seen in a few fibers.

Fig. 149.—Medullated nerve-fiber from sciatic nerve of frog. In two places the medullary sheath has been pulled away by teasing, showing the "naked axis-cylinder"; × 212.

plasm, and parallel to the long axis of the nerve-fiber. In cross-section the axial fibrils appear as evenly distributed dots. Attention must be called to the fact that the fibrils are not equally well stained in all cases (Kupffer, 83, II; compare also Jacobi and Joseph).

When the fiber is less carefully treated, the fibrils fuse with the neuroplasm to form the "axis-cylinder" of authors. As the appearance of the latter is due to a shrinkage of the contents of the axial space, it is easy to understand that one reagent may have a greater effect in this respect than another. The thinnest axis-cylinders are produced by chromic acid and its salts, while thicker ones are seen in nerve-fibers fixed in alcohol. These variations are best seen in cross-sections, in which the

axis-cylinders sometimes appear as round dots and again as stellate figures. The latter are due to pressure on the shrinking axial cord by the unevenly coagulated medullary sheath. As the medullary sheath in such preparations crumbles away in many places, large areas of the axis-cylinder may often be isolated by teasing (Fig. 149).

Sensory and motor nerve-endings may be stained after gold chlorid and chrome-silver methods (see methods of impregnation, page 47), or after the *intra vitam* methylene-blue method suggested by Ehrlich and variously modified by other investigators.

If freshly teased fibers be treated with glacial acetic acid, the axis-cylinders swell up and issue from the ends of the fibers in irregular masses showing fine longitudinal striation (Kölliker, 93). The structures of the axial space dissolve in 1% hydrochloric acid, as well as in a 10% solution of sodium chlorid (Halliburton).

For the isolation of ganglion cells, 33% alcohol, 0.1 to 0.5% chromic acid, or 1% solution of potassium bichromate may be used. Small pieces of the spinal cord and brain containing ganglion cells are treated with a small quantity of one of the above solutions for one or two weeks. After this interval the preparations may be teased and the isolated ganglion cells stained on a slide and mounted in glycerin. They may even be fixed *in situ* by injecting a 1% solution of osmic acid or 33% alcohol into the areas of the brain or spinal cord containing ganglion cells. The region thus treated is then cut out and teased.

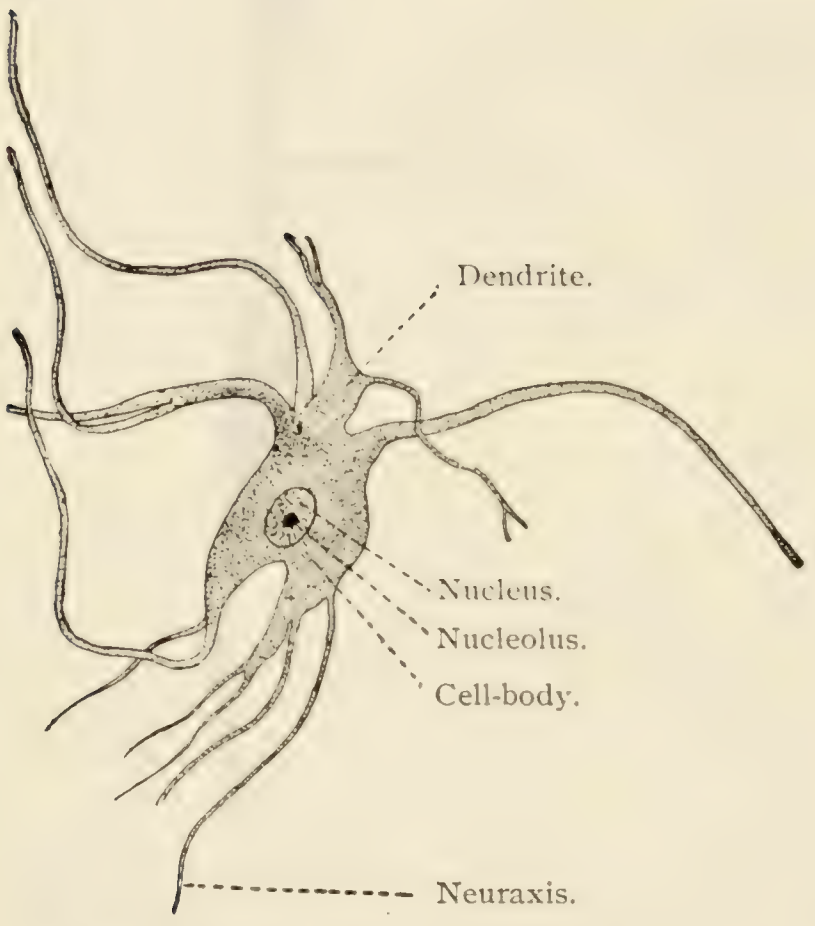

Fig. 150.—A ganglion cell from anterior horn of the spinal cord of calf; teased preparation; × 140. By this method only the coarsest ramifications of the dendrites are preserved; the rest are torn off.

The nonmedullated or "Remak's fibers" are obtained by teasing a sympathetic nerve, or, better, a piece of the vagus previously treated with osmic acid. Between the blackened medullated fibers of the pneumogastric are seen numerous unstained fibers of Remak.

The fibers of the olfactory nerve are stained brown by osmic acid.

Ehrlich's methylene-blue method consists in an *intra vitam* staining of ganglion cells, nerve-fibers, and nerve-endings. The method is much more applicable to the staining of peripheral ganglia (spinal and sympathetic ganglia), peripheral nerves, and nerve-endings than to staining the elements of the central nervous system, although the latter may also be stained by means of this method.

Two methods for bringing the stain in contact with the nerve-tissues are now in use: (1) injecting the methylene-blue solution into the living

tissues through the blood-vessels; (2) adding a few drops of the stain to small pieces of perfectly fresh tissues removed from the body. The solution used for injecting the tissues is prepared as follows: 1 gm. of methylene-blue[1] is mixed in a small flask with 100 c.c. of normal salt solution and heated over a flame until the solution becomes hot. It is then allowed to cool; when filtered, it is ready for use. A cannula is tied into the main artery of the part in which it is desired to stain the nerve elements, and sufficient of the foregoing methylene-blue solution injected to give the part a decidedly blue color. After the injection the part to be studied remains undisturbed for about one-half hour, after which time small, or at least thin, pieces of the tissue to be studied are removed to a slide moistened in normal salt solution, and exposed to the air. The tissues remain on the slide until the nerve-cells, nerve-fibers, or nerve-endings seem satisfactorily stained. After placing the tissues on the slide, they are examined under the microscope (without covering with a cover-glass) every two or three minutes, until such examination shows blue color in the neuraxes of the nerve-fibers and their terminations, or in the nerve-cells, if there be any in the tissues examined. Care should be taken not to miss the time when the staining has reached its full development, as the blue color usually fades again and only inferior preparations are obtained.

Tissues thus stained may be fixed by one of two methods (or modifications of these methods), the selection of the method depending somewhat on the results desired. If it is desired to gain preparations giving the general course of nerves, the formation of nerve-plexuses, the relations of afferent and efferent nerves to the nerve-cells in ganglia, or the general arrangement of the terminal branches of nerve-fibers in nerve end-organs, the tissues are placed in a saturated aqueous solution of ammonium picrate (Dogiel) in which the blue color of the tissues is in a short time changed to a purplish color. In this solution the tissues remain for from twelve to twenty-four hours, and are then transferred to a mixture consisting of equal parts of a saturated aqueous solution of ammonium picrate and glycerin, in which they remain another twenty-four hours; they may, however, without detriment remain in the mixture several days. The tissues are then mounted in this ammonium picrate-glycerin mixture.

If, on the other hand, it is desired to section tissues stained *intra vitam* in methylene-blue, the following method, slightly modified from that given by Bethe, is suggested. The following fixative is prepared: Ammonium molybdate, 1 gm.; distilled water, 10 c.c.; hydrochloric acid, 1 drop. The solution is prepared by grinding the ammonium molybdate to a fine powder, removing it to a flask, and adding the required quantity of water. The flask is now heated until the ammonium molybdate is entirely dissolved, when the hydrochloric acid is added. Before using this fixative it is necessary to cool it to 2°–5° C. It is, therefore, well to prepare it before the injection is made, and surround it with an ice mixture. In this fixative the tissues remain for from twelve to twenty-four hours. After the first six to eight hours it is not necessary to keep the fixative below ordinary room-temperature. After fixation the tissues are washed for an hour in distilled water. They are then hardened and dehydrated in absolute alcohol. It is advisable to hasten this step as much as possible, though not at the risk of imperfect dehydration.

[1] Methylenblau, rectificiert nach Ehrlich, Grübler, Leipzig.

The tissues are then transferred to xylol and imbedded in paraffin, sectioned, fixed to the slide or cover-glass with albumin fixative, and may be double stained in alum-carmin or alum-cochineal. After staining in either of these stains, the sections are thoroughly dehydrated and cleared in oil of bergamot. The oil is washed off with xylol and the sections are mounted in Canada balsam.

In staining nerve-fibers with methylene-blue by local application of the stain to the tissues, the tissues to be studied are removed from an animal which has just been killed, divided in small pieces, and placed on a slide moistened with normal salt solution. A few drops of a $\frac{1}{20}\%$ to $\frac{1}{10}\%$ solution of methylene-blue in normal salt solution are added from time to time—sufficient to keep the tissues moistened by the solution, but not enough to cover them. The preparations are examined from time to time, under the microscope, to see whether the nerve elements are stained. The length of time required for staining by this method varies. Sometimes the nerve elements are stained in half an hour; again, it may require two and one-half hours; on an average, about one hour. As soon as the tissues seem well stained they are fixed as previously directed. Dogiel has found that sympathetic ganglia and sensory nerve-fibers of the heart removed from the human body several hours after death may be stained by means of the foregoing method.

In order to obviate the necessity for the low temperature of the previous method, Bethe (96) has recommended the following procedure: According to the method of Smirnow and Dogiel, he first employs as a preliminary fixing agent a concentrated aqueous solution of ammonium picrate. In this he places the tissue, previously treated with methylene-blue, for from ten to fifteen minutes. Without further washing the larger objects are immersed in a mixture composed of ammonium molybdate (or sodium phosphomolybdate) 1 gm., distilled water 20 c.c., and pure hydrochloric acid 1 drop. The following mixtures may also be employed for the same purpose: ammonium molybdate (or sodium phosphomolybdate) 1 gm., distilled water 10 c.c., 2% solution of chromic acid 10 c.c., and hydrochloric acid 1 drop; or, for very thin gross specimens or sections, ammonium molybdate (or sodium phosphomolybdate) 1 gm., distilled water, 10 c.c., 0.5% osmic acid 10 c.c., and hydrochloric acid 1 drop. Small objects are permitted to remain no longer than from three quarters of an hour to one hour in either of the first two mixtures, and not more than from four to twelve hours in the third. After fixing, the specimens are washed with water, carried over into alcohol, then into xylol, and finally imbedded in paraffin. Subsequent staining with alum-carmin, alum-cochineal, or one of the neutral anilin dyes gives good results.

A very promising method recommended by Meyer (95) consists in injecting subcutaneously about 20 c.c. of normal salt solution containing from 1% to 4% of methylene-blue into a young rabbit, and repeating the operation in one to two hours. Within the next two hours the animal usually dies and the central nervous organs are then removed and small pieces fixed according to Bethe's method.

The method of Chr. Sihler may be recommended for demonstrating the nerve-endings in striated muscle: Muscle bundles of the thickness of a goose quill are first placed for eighteen hours in a solution composed of acetic acid 1 vol., glycerin 1 vol., and 1% solution of chloral hydrate 6 vols., and then teased in pure glycerin. Afterward they are placed in a

mixture of Ehrlich's hematoxylin 1 vol., glycerin 1 vol., and 1 % chloral hydrate solution 6 vols., in which the specimens are allowed to remain for from three to ten days. The pieces are now placed in glycerin acidified with acetic acid (solution No. 1), in which the color becomes differentiated, the nerves and nerve-endings in the muscles and vessels being deeply stained, while the remaining portion of the specimen becomes decolorized. After having stained with No. 2, the pieces may be preserved in pure glycerin, to be treated later with acetic acid (solution No. 1).

These methods are most successful in reptilia and mammalia, more difficult in the other classes of vertebrate animals.

SPECIAL HISTOLOGY.

I. BLOOD AND BLOOD-FORMING ORGANS, HEART, BLOOD-VESSELS, AND LYMPH-VESSELS.

A. BLOOD AND LYMPH.

1. FORMATION OF BLOOD.

Early in the development of the embryo there appear in a portion of the extra-embryonic area of the blastoderm, known as the *area vasculosa*, definite masses of cells, derived from the mesenchyme, and spoken of as *blood islands*, which are intimately connected with the formation of the blood. If these blood islands be examined at a certain stage, free cells are seen lying in their center, apparently derived from the central cells of the islands; the cells surrounding them represent the elements which later go to form the primitive vascular walls. The free elements are the first blood-cells of the embryo. The blood-cells thus developed enter the circulation by means of blood channels formed by the confluence of the blood islands. These grow toward the embryo and later join the large central vessels. The origin of these blood islands is still an open question. Some authors contend that they arise from the mesoblast (P. Mayer, 87, 93; K. Ziegler; van der Stricht, 92), others that they are of entodermic origin (Kupffer, 78; Gensch; Rückert, 88; C. K. Hoffmann, 93, I; 93, II; Mehnert, 96). At a certain period the embryonic blood consists principally of nucleated red cells, which proliferate in the circulation by indirect division. The colorless blood-cells, the development of which is not yet fully understood, appear later. It is possible that they also are elements of the blood islands, which do not contain any hemoglobin. In a later period of embryonic life the liver becomes a blood-forming organ. Recent investigations have, however, shown that it does not take a direct part in the formation of the blood, but only serves as an area in which the blood-corpuscles proliferate during their slow passage through its vessels. The blind sac-like endings of the venous capillaries seem to be particularly adapted for this purpose, as in them the blood current stagnates, and it is here that the greater number of blood-cells reveal mitotic figures. The newly formed elements are finally swept away by the blood stream and enter the general circulation (van der Stricht, 92; v. Kostanecki, 92, III). Many investigators believe that the red blood-cells

have an entirely different origin in the liver—namely, from the large polynuclear, giant cells, which are thought to arise either from the cells of the capillaries or from the liver-cells (Kuborn, M. Schmidt).

Late in fetal life and in the adult, the red bone-marrow and the spleen are the organs which form the red blood-cells. The lymphatic glands and the spleen produce the white blood-cells. In addition to the nucleated red corpuscles which are present up to a certain stage of development, nonnucleated red blood-cells also appear. The number of the latter increases, until finally they are found almost exclusively in the blood of the new-born infant.

The blood of the adult consists of a fluid, coagulable substance, the *blood plasma*, and of formed elements suspended in this intercellular substance. The fluid medium of the blood is of a clear yellowish color and of alkaline reaction, having a specific gravity of about 1030. It is made up of water, of which it contains about 90%, and various organic and inorganic substances. The formed elements are: (*a*) Red blood-corpuscles (erythrocytes); (*b*) white blood-corpuscles (leucocytes); and (*c*) the blood platelets of Bizzozero (82), hematoblasts of Hayem, or the thrombocytes of Dekhuysen. Besides these, there are present particles of fat, and, as H. F. Müller (96) has recently shown, also hemokonia.

2. RED BLOOD-CORPUSCLES.

In man and nearly all mammalia the great majority of the red blood-corpuscles are nonnucleated, biconcave circular discs with rounded edges. They have smooth surfaces, are transparent, pale yellowish-red in color, and very elastic. No method has as yet been devised to demonstrate a nucleus in these cells, and there is no doubt that the red blood-discs of the human adult and of mammalia are devoid, in the histologic sense, of a nucleus capable of differentiation (compare Lavdowsky; Arnold, 96). They are therefore peculiarly modified cells. They possess a somewhat more resistant external zone of exoplasm, which has been interpreted as a cell membrane by certain observers (Lavdowsky), but which does not present the characteristics of a true cell membrane.

If fresh blood be left for some time undisturbed, the blood-discs adhere to each other by their flattened surfaces, grouping themselves in *rouleaux*.

By certain reagents the clear and transparent contents of the blood-corpuscles can be separated into two substances—a staining and a nonstaining. The first consists of the blood pigment, or *hemoglobin*, which can be dissolved; the second of a colorless substance, the *stroma*, which presents itself in various forms (protoplasm of the cell). The stroma probably contains the hemoglobin in solution.

Hemoglobin is a very complex proteid which may be decomposed into a globulin and a pigment *hematin*. The hemoglobin of the majority of animals crystallizes in the form of rhombic prisms;

in the squirrel, however, in hexagonal plates, and in the guinea-pig in tetrahedra. Hematin combines with hydrochloric acid to form *hemin*, or *Teichmann's* crystals, of brownish color, rhombic shape, and microscopic size. They are of much value in lego-medical work, since they may be obtained from blood, no matter how old, and are characteristic of hemoglobin. They may be obtained from very small quantities of blood pigment.

If a small drop of blood pressed from a small puncture is placed on a slide and covered with a cover-glass, the red blood-cells soon become changed. This is due to the evaporation of water in the blood plasma, causing an increased concentration of the sodium chloride contained, which in turn draws water from the blood-cells The shrinkage which follows produces a characteristic

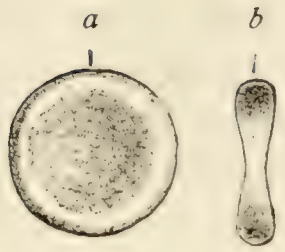

Fig. 151.—Human red blood-cells; × 1500: *a*, As seen from the surface; *b*, as seen from the edge.

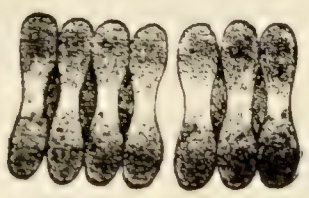

Fig. 152.—So-called "rouleau" formation of human erythrocytes; × 1500.

Fig. 153.—Hemin, or Teichmann's crystals, from blood stains on a cloth.

Fig. 154.—"Crenated" human red blood-cells; × 1500.

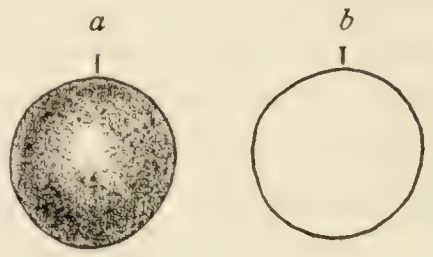

Fig. 155.—Red blood-corpuscles subjected to the action of water; × 1500: *a*, Spheric blood-cell; *b*, "blood shadow."

change in the form of the cells, which assume a crenated or stellate shape. The red blood-cells of blood mounted in normal salt become crenated in a short time for the same reason. Red blood-cells are variously affected by different fluids. In water they become spheric and lose their hemoglobin by solution. Their remains then appear as clear, spheric, indistinct *blood shadows*, which may, however, be again rendered distinct by staining with iodin. Dilute acetic acid has a similar but more rapid action, with this peculiarity, that before becoming paler the blood-cells momentarily assume a darker hue. Bile, even when taken from the animal furnishing the blood, exerts a peculiar influence upon the red blood-cells; they first become distended, and then suddenly appear to explode into

small fragments. Dilute solutions of tannic acid cause the hemoglobin to leave the blood-cells, and coagulate in the form of a small globule at the edge of the blood-cell. In alkalies of moderate strength the red blood-cells break down in a few moments.

Besides the disc-shaped red blood-cells, every well-made preparation shows a few small, spheric, nonnucleated cells containing hemoglobin. These, however, have received as yet but little attention.

M. Bethe makes the statement that human blood and the blood of mammalia contain corpuscles of different sizes, bearing a definite numerical relationship to each other. "If they be classified according to their size, and the percentage of each class be calculated, the result will show a nearly constant proportional graphic curve varying but slightly, according

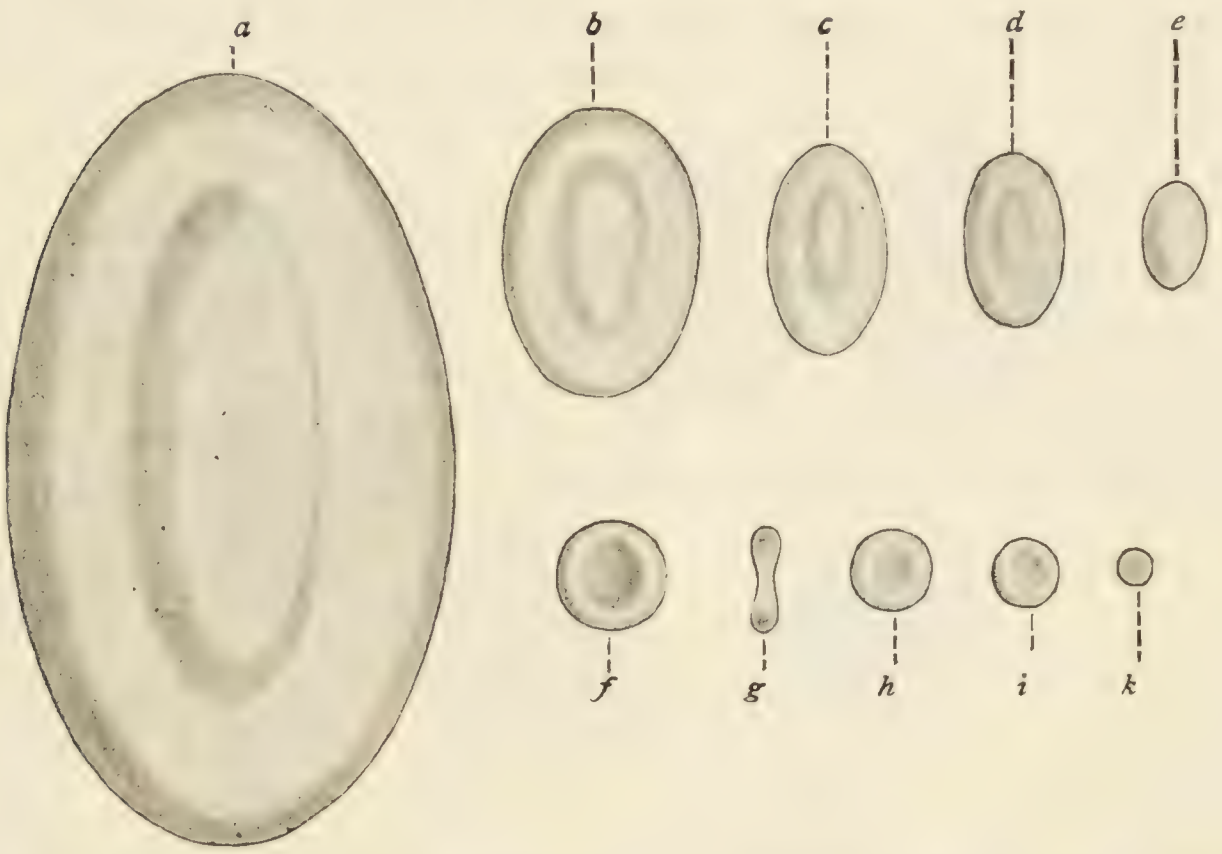

Fig. 156.—Red blood-corpuscles from various vertebrate animals; ×1000 (Welker's model): *a*, From proteus (Olm); *b*, from frog; *c*, from lizard; *d*, from sparrow; *e*, from camel; *f* and *g*, from man; *h*, from myoxus glis; *i*, from goat; *k*, from musk-deer.

to the animal species." According to M. Bethe, dry preparations of human and animal blood may be distinguished from each other, with the exception of the blood of the guinea-pig which presents a curve identical with that of human blood.

The red blood-cells of mammalia, excepting those of the llama and camel species, are in shape and structure similar to those of man. The red blood-cells of the llama and camel have the shape of an ellipsoid, flattened at its short axis, but also nonnucleated.

We have already made mention of the fact that the embryonal erythrocytes are nucleated; the question now arises as to how, in the course of their development, they lose their nuclei. Three possibilities confront us: First, either the embryonal blood-cells are destroyed and gradually replaced by previously existing nonnucle-

ated elements; or, second, the nonnucleated red cells are formed from the nucleated by an absorption of the nucleus (or what appears to be such to the eye of the observer, Arnold, 96); or, finally, the nucleus is extruded from the original nucleated cell. According to recent investigations (Howell) the third possibility represents the change as it actually takes place.

In all vertebrate animals except mammalia, the red blood-corpuscles are nucleated. They are elliptic discs with a biconvex center corresponding to the position of the nucleus. The blood-cells of the amphibia (frog) are well adapted for study on account of their size. They are long and, as a rule, contain an elongated nucleus with a coarse, dense chromatin framework, which gives them an almost homogeneous appearance. The cell-body may be divided, as in mammalia, into stroma and hemoglobin. When subjected to certain reagents, the contour of the cells appears double and sharply defined. This condition is, however, no proof of the existence of a membrane. The blood-cells of birds, reptiles and fishes are similarly constructed.

The diameter of the erythrocytes varies greatly in different vertebrate animals, but is constant in each species. The red blood-cells of man measure on the average 7.5 μ (7.2 μ to 7.8 μ), in their long diameter, and 1.6 μ to 1.9 μ in their short diameter. We append a table of their number in a cubic millimeter and size in man and certain animals as compiled by Rollett (71, II) and M. Bethe:

Species.		Size.	No. in Cubic Millimeter.
Man	(*Homo*)	7.2–7.8 μ	5,000,000
Monkey	(*Cercopith. ruber*)	7 μ	6,355,000
Hare	(*Lepus cuniculus*)	7.16	6,410,000
Guinea-pig	(*Cavia cob.*)	7.48	5,859,500
Dog	(*Canis fam.*)	7.2	6,650,000
Cat	(*Felis dom.*)	6.2	9,900,000
Horse	(*Equus cab.*)	5.58	7,403,500
Musk-deer	(*Moschus jav.*)	2.5	
Spanish goat	(*Capra his.*)	4.25	19,000,000
Domestic chaffinch	(*Fringilla dom.*)	Length, 11.9 Breadth, 6.8	
Dove	(*Columba*)	L. 14.7 B. 6.5	2,010 000
Chicken	(*Gallus dom.*)	L. 12.1 B. 7.2	
Duck	(*Anas bosch.*)	L. 12.9 B. 8.0	
Tortoise	(*Testudo græca*)	L. 21.2 B. 12.45	629,000
Lizard	(*Lacerta agil.*)	L. 15.75 B. 9.1	1,292,000
Snake	(*Coluber natr.*)	L. 22.0 B. 13.0	829,400
Frog	(*Rana temp.*)	L. 22.3 B. 15.7	393,200
Toad	(*Bufo vulg.*)	L. 21.8 B. 15.9	389,000
Triton	(*Triton crist.*)	L. 29.3 B. 19.5	103,000

Species.		Size.		No. in Cubic Millimeter.
Salamander	(*Salamandra mac.*)	Length,	37.8	80,000
		Breadth,	23.8	
	(*Proteus angu.*)	L.	58	35,000
		B.	35	
Sturgeon	(*Acipenser St.*)	L.	13.4	
		B.	10.4	
Carp	(*Cyprinus Gobio*)	L.	17.7	
		B.	10.1	

3. WHITE BLOOD-CORPUSCLES.

The white blood-cells contain no hemoglobin and are nucleated elements which, under certain conditions, possess ameboid movement. Their size varies from 5 μ to 12 μ, and they are less numerous than the red blood-corpuscles, one white blood-cell to from three hundred to five hundred red cells being a normal proportion.

Fig. 157.—From the normal blood of man; × 1200 (from dry preparation of H. F. Müller): *a*, Red blood-cell; *b*, lymphocyte; *c* and *d*, mononuclear leucocytes; *e*, transitional leucocyte; *f* and *g*, leucocytes with polymorphous nuclei.

Flemming ascribes a fibrillar structure to the protoplasm of white blood-cells, and was the first to observe a centrosome situated near the nucleus. M. Heidenhain made the observation that the white blood-cells possessed several centrosomes grouped to constitute a microcenter (microcentrum) about which the fibrillar structure of the protoplasm was arranged radially. The meshes of the fibrillar network are filled with a more fluid interfibrillar substance, in which are found the specific granules to be mentioned later. In the normal blood the white blood-cells vary in size and structure, and the following varieties are distinguished: (1) Small and large lymphocytes; (2) mononuclear leucocytes; (3) transitional leucocytes; (4) leucocytes, either polymorphonuclear or polynuclear.

The *lymphocytes* form about 20% of the white blood-cells.

They vary in size from 5 μ to 7.5 μ and possess a relatively large nucleus, the chromatin of which is in the form of relatively large granules, which stain rather deeply. The nucleus is surrounded by a narrow zone of protoplasm, often seen clearly only to one side of the cell in the form of a crescent. It does not stain readily in acid dyes.

The *leucocytes* vary in size from 7 μ to 10 μ. The *mononuclear leucocytes*, constituting about 2% to 4% of the white blood-cells, have a nearly round or oval nucleus, which usually does not stain very deeply, and which is relatively smaller than that of the lymphocytes. The *transitional leucocytes*, forming also about 2% to 4% of the white blood-cells, are developed from the mononuclear variety and represent transitional stages in the development of mononuclear leucocytes to those with polymorphous nuclei. The nucleus in the transitional form is similar in size and structure to that of the mononuclear variety, but of a more or less pronounced horse-shoe-shape. The *leucocytes with polymorphous nuclei*, developed from the transitional forms, are very numerous in the blood, forming about 70% of the entire number of white blood-cells. They are also the cells which show the most active ameboid movement when examined on the warm stage. They possess variously lobulated nuclei, the several nuclear masses often being united by delicate threads of nuclear substance. A leucocyte with a polymorphous nucleus becomes a polynuclear cell in case the bridges of nuclear substance uniting the several lobules of the nucleus break through. In the protoplasm of the transitional leucocytes, the polymorphonuclear, and the polynuclear forms are found fine and coarse granules. Our knowledge of these granules has, however,

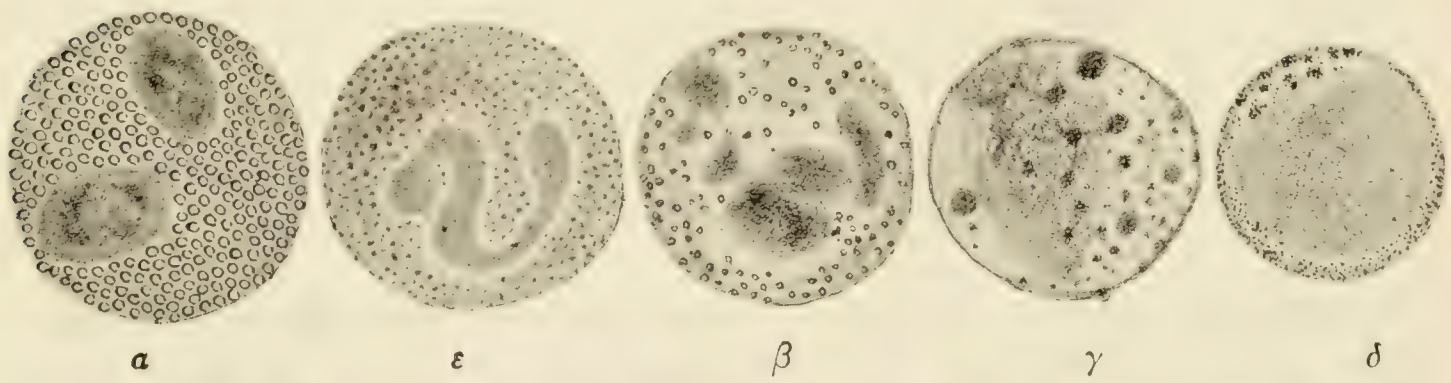

Fig. 158.—Ehrlich's leucocytic granules; × 1800 (from preparations of H. F. Müller): *a*, Acidophile or eosinophile granules, relatively large and regularly distributed; ε, neutrophile granules; β, amphophile granules, few in number and irregularly distributed; γ, mast cells with granules of various sizes; δ, basophile granules. (*a*, δ, and ε, From the normal blood; γ, from human leukemic blood; β, from the blood of guinea-pig.)

been greatly extended since Ehrlich has shown that the granules of leucocytes show specific reactions toward certain anilin stains, or combinations of such stains. He divides the granules of the leucocytes into five classes which he terms respectively α-, β-, δ-, γ-, and ε-granules. In human blood are found the α-granules, which show an affinity for acid-anilin stains, are therefore known as acidophile gran-

ules, and, since they are most readily stained in eosin, are generally spoken of as *eosinophile* granules. In normal blood from 1 % to 4 % of the polymorphonuclear leucocytes and now and then a transitional cell have eosinophile granules. The granules are coarse and stain bright red in eosin. Nearly all the leucocytes with granules (from 65 % to 68 % of all white blood-cells) have ε-granules or, since they are stained in color mixtures formed by a combination of acid and basic anilin stains, *neutrophile* granules. The neutrophile granules are much finer than the eosinophile and are not stained in acid stains. The γ- and δ-granules are stained in basic anilin stains, and are known as *basophile* granules. They are coarse and irregular, and the leucocytes containing them form from 0.5 % to 1 % of the white blood-cells.

It cannot at this time be definitely stated whether the different varieties of granules are to be looked upon as specific products of the protoplasm of the leucocytes, possibly of the nature of granules which may be likened to the secretory granules of glandular cells, or whether they are to be regarded as cell inclusions. It has also not been clearly shown whether one variety of granules may develop into another variety,—neutrophile into eosinophile,—although this has been suggested. According to Weidenreich, eosinophile granules are thought to represent fragments of erythrocytes, enclosed within the protoplasm of leucocytes.

The polymorphism of the leucocyte-nucleus has induced many investigators to advance the theory that a direct division takes place (fragmentation—Arnold, Löwit). Flemming (91, III), however, succeeded in demonstrating that true mitotic processes actually take place, so that in this respect there really exists no difference between leucocytes and other cells (compare also H. F. Müller, 89, 91). It is only in the formation of polynuclear leucocytes that the polymorphous nucleus sometimes undergoes a fragmentation process which results in several parts. But even in this case pluripolar mitoses have been observed. A division of the cell-body subsequent to that of the nucleus is lacking in the processes just described. As a result a single cell with several nuclei is formed (polykaryocyte). The fate of such cells is still in doubt.

The extraordinary motility which most leucocytes possess, is in great part responsible for their wide distribution, even outside of the vascular system. They have the power of creeping through the walls of the capillaries (diapedesis, Cohnheim 67, I), and of penetrating into the smallest connective-tissue clefts, between the cells of epithelia, etc., whence they either pass on (migratory cells) or remain stationary for a time. An important function falls to the lot of the leucocytes in the absorption of superfluous tissue particles or in the removal of foreign bodies from certain regions of the body. In the first case they take part in a process of tissue-disintegration; in the second, they take up the particles by means of their pseudopodia for the purpose either of assimilation or of removal (phago-

cytes). It may be readily understood that the latter function of the leucocytes is of the greatest importance in certain pathologic processes.

It is somewhat venturesome at the present state of our knowledge to make definite statements as to the origin in postembryonic life of the various forms of white blood-cells above described. The following statement, however, seems warranted from the evidence at hand.

The lymphocytes would seem to be developed in the meshes of adenoid tissue, especially in the so-called *germ centers* of Flemming, in the adenoid tissue of lymph-glands and lymph-follicles (see under these). Here the cells undergo active karyokinetic division, but where the cells which pass through the process originate is a matter concerning which there is a difference of opinion. Some investigators believe that they penetrate the germ centers with the lymph, and find there a suitable place for division. Again, others see in Flemming's germ centers permanent organs whose elements remain stationary and supply the blood with a continuous quota of lymphocytes. Be this as it may, the fact remains that the germ centers are the most important regions for the formation of lymphocytes. From these they pass out with the lymph current into the blood circulation, or directly into the blood-vessels, there to enter upon the functions which they are called upon to perform. The leucocytes with neutrophile granules are probably developed in the blood and lymph from mononuclear leucocytes which have their origin in the spleen pulp, possibly also in the bone-marrow. The leucocytes of circulating blood with eosinophile granules in all probability come from mononuclear cells with such granules found in bone-marrow. Under certain conditions it would seem that they also develop in connective tissue. The leucocytes with the basophile granules probably enter the circulation from the connective tissue of certain regions. The lymphocytes and leucocytes found in the blood are also found in the lymph-vessels and lymph-spaces.

4. BLOOD PLATELETS—THROMBOCYTES.

The third element of the blood is the *blood platelets* (Bizzozero) (*blood-placques*, Laker; *hematoblasts*, Hayem; *thrombocytes*, Deckhuysen). They are extremely delicate and transitory structures, whose existence in the living blood was denied for a long time by many investigators, but whose presence in the wing vessels of the living bat was conclusively demonstrated by Laker (84). They are free from hemoglobin, are of round or oval shape, and in mammals measure about 3 μ in diameter. Owing to the fact that they readily clump together when blood leaves the vessels, and undergo change, it is somewhat difficult to give an estimate of their number. They are said to be present in human blood to the extent of 200,000 to 300,000 in every cubic millimeter. By the exercise of great care

and the employment of special methods on the part of a number of recent observers (Detjen, Deckhuysen, Kopsch and Argutinsky), they have been able to show that these structures present a more complicated structure than was formerly thought. When examined in an isotonic salt solution (for mammals 0.9 to 0.95 sodium chlorid solution), they present an oval or short spindle-shaped form, and in them there can be made out a relatively large structure, which stains in certain basic aniline stains and is interpreted as a nucleus (Deckhuysen). When examined after a method suggested by Detjen (with a 1 per cent. agar solution there is mixed 0.6 per cent. sodium chlorid, 0.3 per cent. of sodium metaphosphate and dipotassium phosphate; a thin layer of this agar mixture is spread on the slide and a drop of blood mounted between it and the cover), the blood platelets or thrombocytes may be observed on the warm stage for several hours, and it may be seen that they present ameboid movement, in that short, thread-like processes pass out from the cell, which may alter their shape and position and which may be again withdrawn.

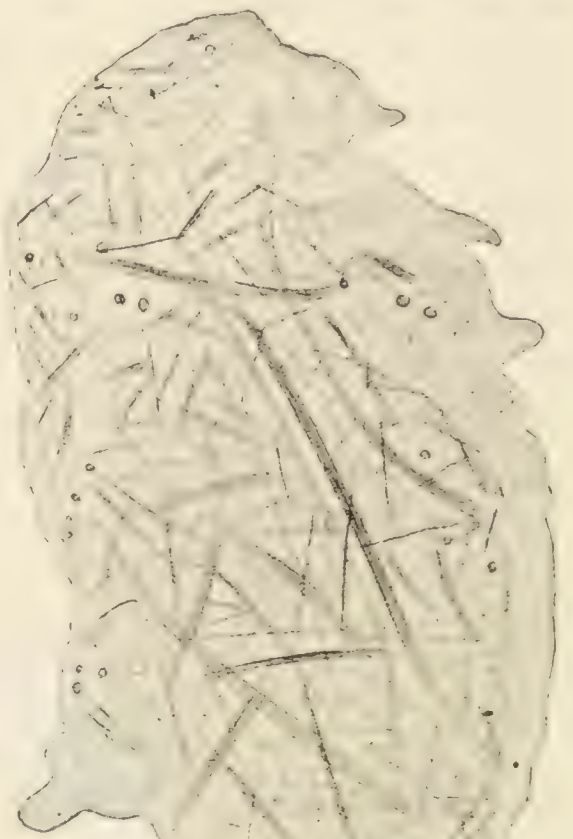

Fig. 159.—Fibrin from laryngeal vessel of child; × about 300.

When the blood leaves the blood-vessels, the blood platelets or thrombocytes break down very quickly, unless the above-mentioned methods are made use of, so that in ordinary fresh preparations or generally in dried films they are not to be observed in an unaltered state. The nuclei disappear and the protoplasm becomes granular or vacuolated. The breaking down of the blood platelets or thrombocytes is accompanied by the formation of fibrin (coagulation of the blood), the fibrin threads beginning at the borders or processes of the platelets, and radiating in all directions (Kopsch).

Hemokonia.—H. F. Müller (96) found in the blood of healthy and diseased individuals highly refractive, colorless, and round (seldom rod-like) bodies, which he terms "hemokonia." Their numbers vary, although they are normal constituents of the blood. Their nature and origin are obscure. They do not dissolve in acetic acid, nor are they blackened by osmic acid. The latter would seem to indicate that they do not consist of ordinary fat substance, although they are probably composed of a substance closely allied to fat. They are usually 1 μ in diameter.

5. BEHAVIOR OF BLOOD-CELLS IN THE BLOOD CURRENT.

In the circulating blood the behavior of the formed elements varies. The more rapid axial current contains very nearly all the erythrocytes, and as a consequence very few are found adjacent to the walls of the vessels. In the peripheral current, on the other hand, are found most of the leucocytes, and in a retarded circulation they are seen to glide along the walls of the vessels. At the bifurcations of the vessels, especially of the capillaries, the erythrocytes are sometimes caught and elongated by the division of the current, the one-half of the cell extending into the one and the other half into the other branch of the vessel, while the corpuscle oscillates back and forth. When again free the cell immediately resumes its original shape. From this it is seen that erythrocytes are very elastic structures. In the smaller vessels and capillaries, especially when the latter are altered by pathologic conditions, the leucocytes may be seen passing out of the vessels, and it would seem that they are able to penetrate through the walls and even through the endothelial cells lining the blood-vessels (compare also Kolossow, 93). First, they send out a fine process, which is probably endowed with a solvent action. This penetrates the wall of the vessel, after which the remainder of the cell pushes its way through slowly.

B. LYMPHOID TISSUE, LYMPH-NODULES, AND LYMPH-GLANDS.

As to the origin of lymphoid tissue, the lymph-glands, and the spleen, there is still considerable difference of opinion. Most authors believe that these structures are developed from the middle germinal layer (Stöhr, 89; Paneth; J. Schaffer, 91; Tomarkin). Others believe in an entodermic origin (Kupffer, 92; Retterer; Klaatsch; C. K. Hoffmann, 93, II).

The framework of lymphoid tissue is a reticular connective tissue (adenoid connective tissue—His, 61). This consists of a network of fine fibrils of reticular and white fibrous connective tissue and of cells (endoplasm and nuclei) which are situated on the reticulum, often at nodal points. Within its meshes the lymph-cells lie in such numbers and so densely arranged that on microscopic examination the network is almost entirely covered unless very thin sections are used. The cells may be removed from the meshes of the reticulum by stippling and brushing section with a fine brush or by placing sections in a test-tube partly filled with water and subjecting them to vigorous shaking, or, still better, by subjecting sections or pieces of lymphoid tissue to digestion with pancreatin.

Lymph tissue may be diffuse, as in the mucous membrane of the air-passages and as in that of the intestinal tract, uterus, etc. (*vid.* Sauer, 96). Lymphoid tissue may be also sharply defined in the

form of round nodules, *simple follicles* or *nodules*. These are either single, *solitary lymph-follicles*, or gathered into groups, *agminated lymph-nodules*. They are found scattered in the mucous membrane of the mouth, pharynx, and intestine. In lymph-nodules also we find the characteristic lymph-cells and the adenoid reticulum. As a rule, the former are arranged concentrically at the periphery; and in the center of the nodule the reticular tissue usually has wider meshes, and the lymph-cells are less densely placed. (Fig. 160.) In the center of the nodule the cells often show numerous mitoses, and it is here that an active proliferation of the cells takes place. The cells may either remain in the lymph-follicle or the newly formed cells are pushed to the periphery of the nodule, and are then swept into the circulation by the slow lymph current which circulates between the wide meshes of the reticular connective tissue. Flemming (85, II) has called that central part of the nodule containing the proliferating cells the *germ center* or *secondary nodule* (compare p. 194). The germ centers are transitory structures, and are consequently found in different stages of development. They may even be absent for a time.

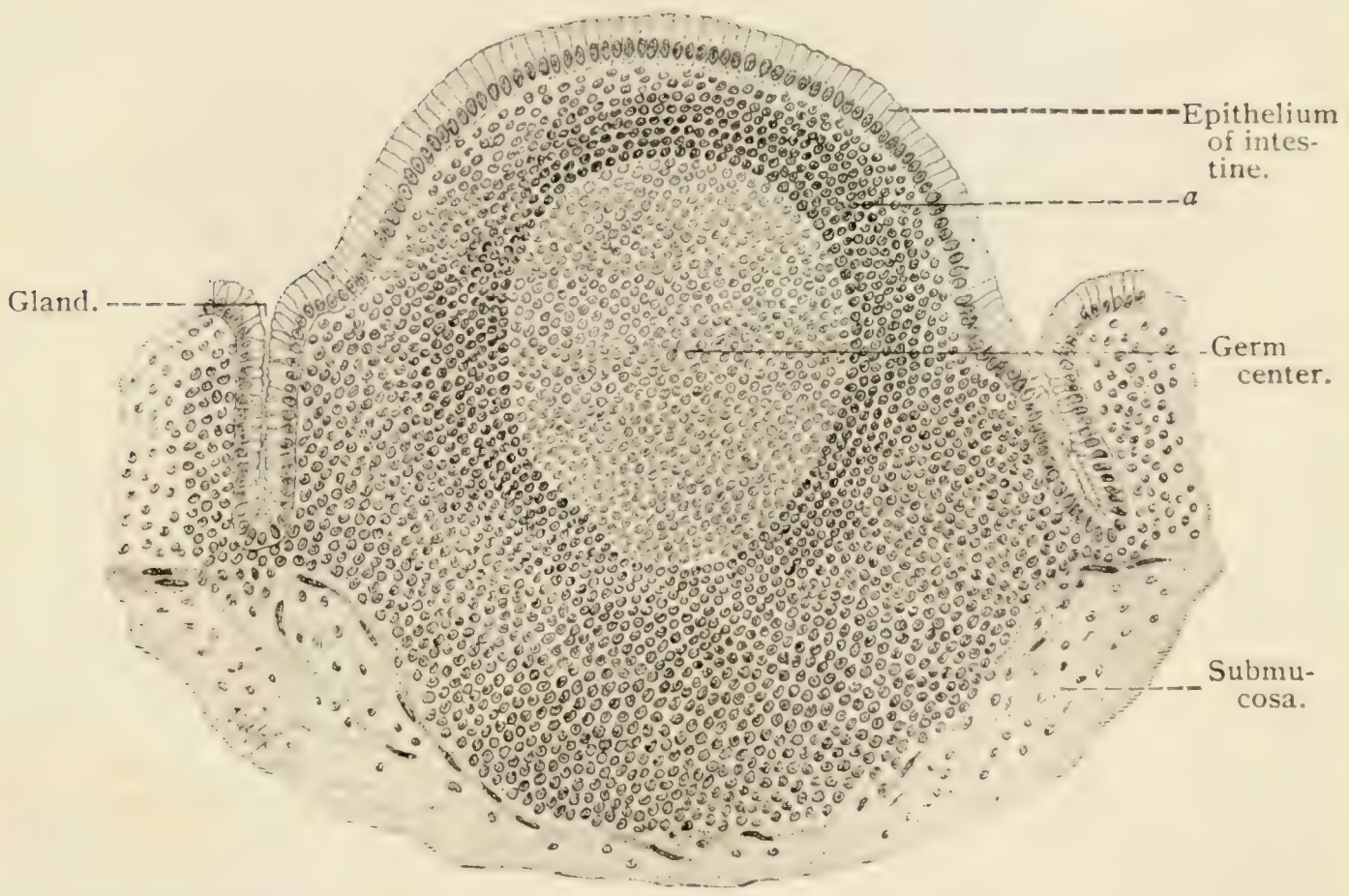

Fig. 160.—A solitary lymph-nodule from the human colon. At *a* is seen the pronounced concentric arrangement of the lymph-cells.

The *lymph-glands* are organs of a more complicated structure, but also consist of lymphoid tissue. They are situated here and there in the course of the lymph-vessel and are widely distributed. Their size varies greatly. In shape they are much like a bean or kidney, and the indentation on one side is known as the *hilum*. The afferent lymph-vessels, the *vasa afferentia*, enter at the convex surface of the organ, while the efferent vessels, the *vasa efferentia*, pass out

at the hilum. The whole gland is surrounded by a *capsule* consisting of two layers: the outer is made up of a loose, and the inner of a more compact, connective tissue in which elastic fibers and a few smooth muscle-fibers are imbedded. Portions of the inner layer pass into the substance of the gland to form septa, or *trabeculæ*, by means of which the organ is divided into a number of imperfectly separated compartments. These trabeculæ may be very well developed, as in the lymph-glands of the domestic cattle, or only

Fig. 161.—Transverse section of human cervical lymph-gland, showing the general structure of a lymph-gland; × 18. *bg*, Blood-vessels; *cf*, fibrous capsule; *h*, hilum; *kz*, germ-center; *nl*, lymph-nodule; *sc*, cortical substance; *gm*, medullary substance; *tr*, trabeculæ; *vla*, afferent lymph-vessels; *vle*, efferent lymph-vessels ("Atlas and Epitome of Human Histology," Sobotta).

poorly developed, as in the human lymph-glands, where they are often almost wanting. The lymphoid tissue of the gland is so distributed that at its periphery a large number of more or less clearly defined lymph-nodules are found, which are in part separated from each other by the trabeculæ just described, the *cortical nodules*. The nodules are structural units and have a typical blood supply, and are in structure like the lymph-nodules of simple and ag-

minated follicles above mentioned. They form a peripheral layer which is, however, not clearly defined in the neighborhood of the hilum. This layer is known as the cortex of the lymph-gland. (Fig. 161.) The lymphoid tissue of the interior of the gland, the medullary substance, is in the shape of cords—*medullary cords*—which are continuous with the lymphoid nodules of the cortical portion. These connect with each other and form a network of lymphoid tissue, in the open spaces of which lie the trabeculæ. At their periphery the nodules and medullary cords are bordered by a wide-meshed lymphatic tissue, the *lymph-sinus* of the gland, parts of which lie (1) between the capsule and the cortical substance, (2)

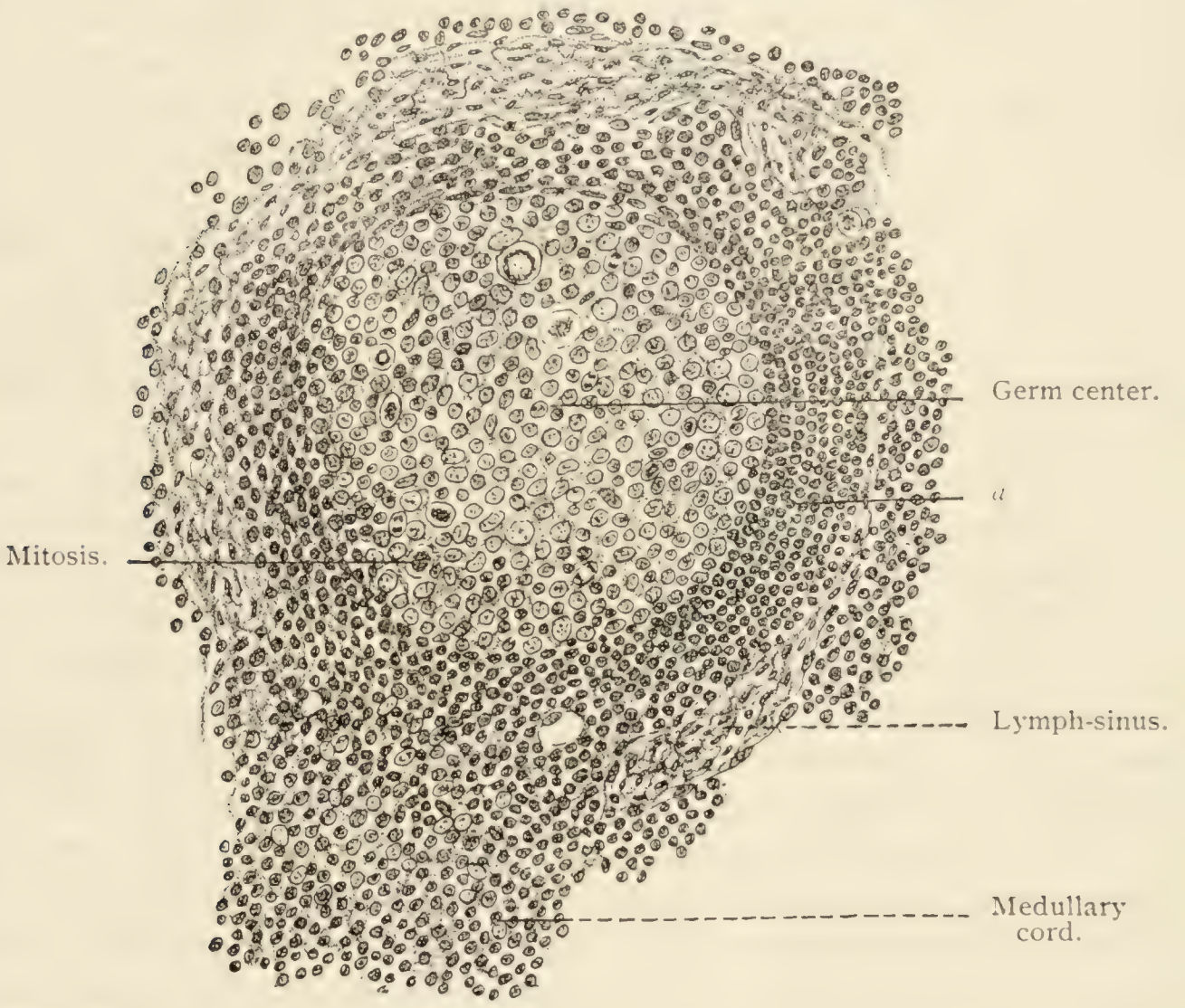

Fig. 162.—From a human lymph-gland; × 240. At *a* are seen the concentrically arranged cells of the lymph-nodules. (Fixation with Flemming's fluid.)

between the nodules of the latter and the trabeculæ, (3) between the medullary cords and the trabeculæ, and (4) between the medullary substance and the capsule at the hilum. At the hilum the loose lymphoid tissue represents a terminal sinus (Toldt). These sinuses are lined throughout by endothelial cells, which are continuous with those of the afferent and efferent lymph-vessels. The lymph flows into the gland through the afferent vessels, and passes along into the interior through the spaces offering the least resistance (sinuses). The latter represent those peripheral portions of the nodules and of the medullary cords in which the lymphoid tissue is present in loose arrangement. The lymph consequently envelops

not only the lymph-nodules of the cortical substance, but also the medullary cords, and finally streams into the terminal sinus and then into the efferent channels. As a result the lymph takes with it the newly formed cells of the lymph-nodules and the medullary cords, and passes out richer in cellular elements than on its entrance.

The lymph-glands receive their blood supply mainly through the hilum; relatively small arterial branches may penetrate the capsule. Generally, a number of arterial branches enter at the hilum, from whence they may pass directly into the medullary substance, or pass for a distance in trabeculæ. In their course branches are given off which pass to the medullary cords, in which they break up into capillary vessels situated in the periphery of the cords. These unite to form small veins which anastomose freely, and unite to form larger veins. The cortical nodules receive their blood supply from arterial branches which enter their proximal sides (side toward the hilum) and course through the center of the nodules, giving off capillary vessels which pass, without much anastomosis, to the periphery of the nodules, where they unite to form plexuses; the capillaries of these plexuses join to form the veins of the nodules, which are thus situated at their periphery. These veins unite to form larger veins, which leave the glands at the hilum (Calvert).

Medullated and nonmedullated nerves penetrate the lymph-glands accompanying the blood-vessels on which they terminate.

Hemolymph Glands.—A typical lymph-gland possesses afferent and efferent lymph-vessels and a closed blood-vascular system completely separated from the lymph-vascular system, as may have been seen from the foregoing description. Attention has, however, been called in recent years to certain lymph-glands in which the complete separation of the vascular and lymphatic systems does not obtain,—glands in which the formed elements of blood and lymph are intermingled in the meshes of the adenoid reticulum, and which contain blood-sinuses in place of the lymph-sinuses observed in the typical lymph-glands. These have been designated as hemolymph glands (*Blutlymphdrüsen*, hemal glands, hemal lymphatic glands). In the typical hemolymph glands there are no afferent and efferent lymphatic vessels; the glands are intercalated in the vascular system. Certain less clearly defined hemolymph glands possess afferent and efferent lymphatics and blood-sinuses, the two systems being not completely separated. These may be considered transitional forms.

Lymph-glands with blood-sinuses were first described by Gibbes, who found such glands in the region of the renal artery. They were further considered and more fully described by Robertson, to whom the term hemolymph glands is to be credited, and by Clarkson, Vincent and Harrison, Drummond, Warthin, Weidenreich and Lewis. It appears from their description that they are widely distributed among vertebrates, although not equally well developed

in the different types studied. Warthin has discussed more fully than other observers the hemolymph glands of man, and his account will here be followed in the main. It may be parenthetically stated that the hemolymph glands are numerous and well developed in the sheep (Warthin, Weidenreich); not so well differentiated in the dog and cat; on the other hand, well developed in the rat (Lewis).

We learn from the account of Warthin that the hemolymph glands are numerous in man, in the prevertebral retroperitoneal region, in the cervical region, and less numerous in the thorax. They vary in size from that of several millimeters to that of several centimeters. They present a variety of structure, depending mainly upon the arrangement of the lymphoid tissue and blood-sinuses. The great majority of these glands show a resemblance in structure to splenic tissue (splenolymph glands); others resemble more closely marrow-tissue (marrow lymph-glands). Between the two varieties of lymph-glands there are found transition forms, as also between these and lymph-glands (Warthin).

The hemolymph glands (splenolymph glands) are surrounded by a capsule varying in thickness and composed of white fibrous and elastic tissue and nonstriated muscle-cells. From it trabeculæ of the same structure pass into the gland, which after division are lost in the substance of the gland. Beneath the capsule there is found a continuous or discontinuous blood-sinus, bridged over by reticular fibers, from which anastomosing sinuses pass to the interior of the gland. These blood-sinuses are, in part at least, lined by endothelial cells. The sinuses in the gland substance are also bridged by trabeculæ and reticular fibers. The sinuses divide the lymphoid tissue into anastomosing masses and cords. This tissue consists of an adenoid reticulum, in the meshes of which are found white and red blood-cells. The small lymphocytes are numerous; next in frequency are found the mononuclear leucocytes; transitional and polymorphonuclear cells. Basophile and eosinophile cells are also found. According to Weidenreich, the eosinophile cells are numerous; he is also of the opinion that the eosinophile granules are derived from disintegrating red blood-cells. In the reticulum and in the blood-sinuses are found mononuclear phagocytes, the origin of which has not been fully determined. Certain observers (Schumacher, Weidenreich) trace their origin to the cells of the reticulum; Thoma regards them as developed from endothelial cells, while Drummond and others regard them as altered leucocytes. They contain disintegrating red blood-cells and pigment (according to Weidenreich, eosinophile cells). The majority of the hemolymph glands present a hilum through which the blood-vessels enter. The arteries, soon after entering the gland, divide into smaller branches, certain of which communicate directly through blood-capillaries with the blood-sinuses (Lewis); others pass to the adenoid tissue. The larger veins are in the trabeculæ

(at the hilum). On leaving the trabeculæ their walls are formed of endothelium and adenoid reticulum, which separates them from the blood-sinuses. They end (or begin) in lacunæ with thin walls which are perforated and communicate with the blood-sinuses (Weidenreich). Nerves have been traced to the hemolymph glands by Lewis (dog, rat). They probably end in the involuntary muscle of the capsule and trabeculæ. Typical hemolymph glands have no lymph-vessels. In certain glands both blood- and lymph-sinuses are found. In such glands there is apparently an intermingling of blood and lymph, so that red blood-cells may pass into the lymphatics.

The marrow lymph-glands are not so numerous. They have a thin capsule consisting of fibrous tissue but containing little elastic and muscular tissue. The blood-sinuses are not so well developed. In the lymphoid tissue the basophile and eosinophile cells are more numerous than in the splenolymph glands, and large cells similar to the large bone-marrow cells are now and then met with.

As appears from the accounts of the majority of observers who have studied hemolymph glands, they have a hemolytic function, in that the red blood-cells are destroyed in them. Robertson and Clarkson ascribe to them a blood-forming function. This has also been observed by Warthin in the case of marrow lymph-glands, under certain conditions. The hemolymph glands are seats of origin for the white blood-cells which appear also to be destroyed here (eosinophile cells, Weidenreich).

C. THE SPLEEN.

The spleen is a blood-forming organ, in which white blood-cells and, in embryonic life and under certain conditions in adult life also, red blood-cells are formed—the former in the adenoid tissue (Malpighian corpuscles) and spleen pulp, the latter only in the spleen pulp.

The spleen is covered by peritoneum, and possesses a capsule consisting of connective tissue, elastic fibers, and nonstriated muscle-cells. This capsule sends numerous processes or trabeculæ into the interior of the organ, which branch and form a framework in which the vessels, especially the veins, are imbedded. This connective-tissue framework breaks up to form the reticular tissue which constitutes the ground substance of the spleen.

On examining a section of the spleen with the low-power magnifying glass, sections of the trabeculæ, and round or oval masses of cells, having a diameter of about 0.5 mm., and in structure and appearance similar to the lymph-nodules (Malpighian corpuscles), are clearly defined; between and around these structures is a tissue rich in cells, blood-vessels and blood-corpuscles, known as the spleen pulp.

The organ has a very typical blood supply. Its arteries enter at the hilum, or indented surface, and its veins pass out at the same place. On the penetration of the vessels through the capsule, the latter forms sheaths around them (trabeculæ), but as soon as the arteries and veins separate, the trabeculæ envelop the veins alone. The arteries break up into smaller branches, which in turn divide into a large number of tuft-like groups of arterioles. Soon after their separation from the veins, the adventitia (outer fibrous tissue coat) of

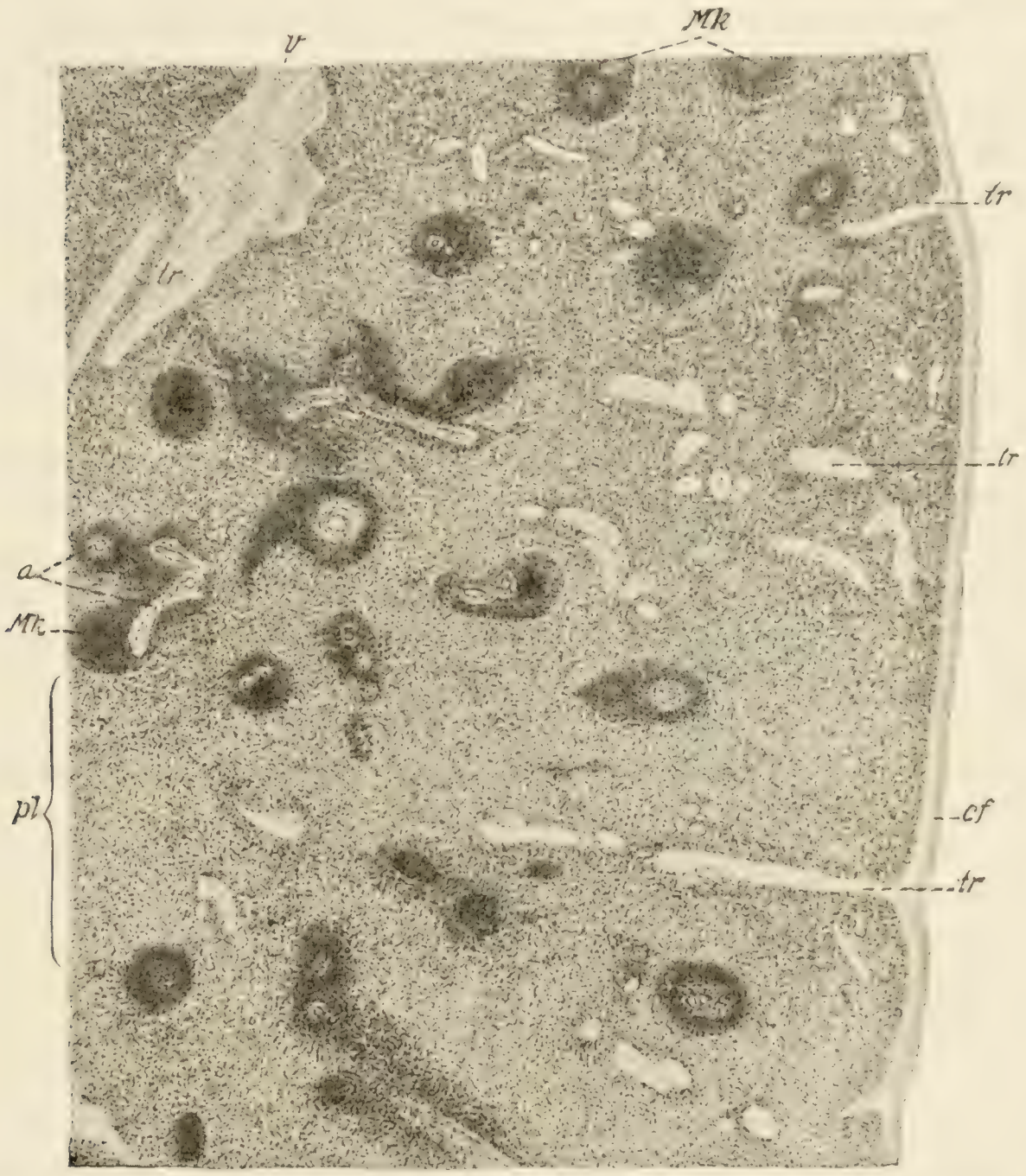

Fig. 163.—Portion of section of human spleen ; × 15. The figure gives a general view of the structure of the spleen: *a*, Arteries with lymphoid sheaths ; *cf*, fibrous capsule ; *Mk*, Malpighian corpuscle ; *pl*, spleen pulp ; *tr*, trabeculæ ; *v*, vein in trabecula ("Atlas and Epitome of Human Histology," Sobotta).

the arteries begins to assume a lymphoid character. This lymphoid tissue increases here and there to form true lymphoid nodules, possessing all the characteristics already mentioned—reticular tissue, germ centers, etc. These are the *Malpighian bodies*, or *corpuscles ;* they are not very plentifully represented in man. The Malpighian bodies with their germ centers are formative centers for the lymphocytes. The newly formed cells pass into the pulp and mix with its elements, which are then bathed by the blood emptying from the

arterial capillaries into the channels of the pulp. The lymphoid sheaths and nodules derive their blood supply from arteries which arise from the lateral branches of the splenic vessels, and which divide into capillaries inside of the lymph sheaths or nodules, and only assume a venous character outside of the lymphoid substance. These vessels constitute the nutritive vascular system of the spleen.

The small arterial branches above mentioned break up into very fine arterioles which gradually lose their lymphoid sheath, so that branches with a diameter of 0.02 mm. no longer possess a lymphoid sheath, but again assume an adventitia of the usual type. The smallest arterioles now pass over into capillaries which are for a time accompanied by the adventitia (capillary sheath), while the terminal branches have the usual structure of the capillary wall and are gradually lost in the meshes of the pulp. (See below.) On the other hand, the beginnings of the venous capillaries may be distinctly seen in the pulp spaces. Groups of these capillaries combine to form larger vessels, which, however, still retain a capillary structure, and these again form small veins which unite to form the larger veins.

F. P. Mall, whose recent contributions on the structure of the spleen have greatly extended our knowledge of the microscopic anatomy of this organ, states that the trabecular and vascular systems together outline masses of spleen pulp about 1 mm. in diameter, which he has named *spleen lobules.* Each lobule is bounded by three main interlobular trabeculæ, each of which sends three intralobular trabeculæ into the lobule which communicate with each other in such a manner as to divide the lobule into about ten smaller compartments. An artery enters at one end of the lobule and, passing up through its center, gives off a branch to the spleen pulp found in each of the ten compartments formed by the intralobular trabeculæ. The spleen pulp in these compartments is arranged in the form of anastomosing columns, or cords, to which Mall has given the name of *pulp cords.* The branches of the main intralobular artery, going to each compartment, divide repeatedly ; the terminal branches course in the spleen-pulp cords, and in their path give off numerous small side branches which end in small expansions known as the *ampullæ of Thoma.* An ampulla of Thoma may be divided into three parts. The first part, which is the ampulla proper, is lined by spindle-shaped cells, directly continuous with the endothelial cells of the artery. The second third, which often communicates with neighboring ampullæ, contains large side-openings. The remaining third, which is the intermediary segment of Thoma (*Thoma's Zwischenstück*), is difficult to demonstrate. It is bridged over by fibrils of reticulum, and its communication with the vein is not wide. The circulation through the spleen is therefore not a closed one, through a system of capillaries completely closed, but rather through spaces in the spleen-pulp, certain of which are more direct, leading from the terminal arteries to the veins. According to this view, then,

"the blood passes from the ampullæ into the pulp spaces, then through the pores into the walls of the veins to form columns of blood discs which are pushed from the smaller to the larger veins of the spleen." The pulp spaces usually contain very few blood-corpuscles, in preparations fixed and prepared in the usual way, since on removal from the animal the muscular tissue of the capsule and trabeculæ contracts and presses the blood from pulp spaces into the veins. If, however, the muscular tissue of the spleen is paralyzed before the tissue is fixed, numerous blood-corpuscles are found in the pulp spaces. In the above account of the ultimate distribution of the splenic vessels we have followed very closely the recent observations of F. P. Mall. The accompanying diagram (Fig. 164), slightly, though immaterially, modified from one given

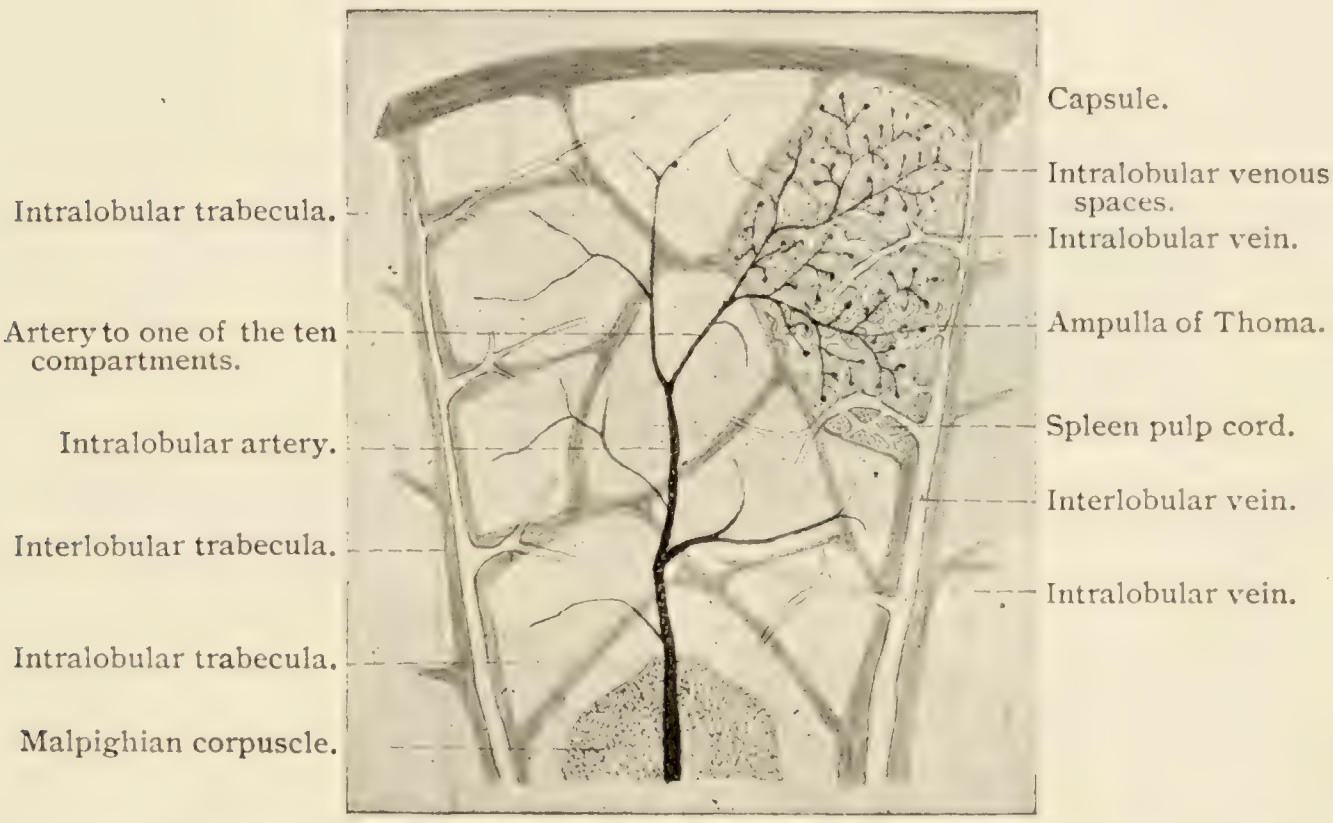

Fig. 164.—Diagram of lobule of the spleen (Mall, "Johns Hopkins Hospital Bulletin," Sept., Oct., 1898).

by F. P. Mall, shows clearly the trabecular and vascular systems of a spleen lobule. In larger spleens there may be some two hundred thousand of these lobules. In a dog weighing 10 kg. there are on an average some eighty thousand (F. P. Mall).

The splenic pulp consists of a reticulum, in the meshes of which are found (1) fully developed red blood-cells; (2) now and then nucleated red blood-cells; (3) in many animals giant cells; (4) cells containing red blood-corpuscles and the remains of such, with or without pigment; (5) the different varieties of white blood-cells, especially a relatively large proportion of mononuclear leucocytes. Pigment granules, either extra- or intracellular, also occur in the splenic pulp. The pigment probably originates from disintegrating erythrocytes. Besides these are found, especially in

teased preparations, long, spindle-shaped and flat cells, which are probably derivatives of the connective-tissue cells of the pulp and of the endothelium and muscular fibers of the vessels.

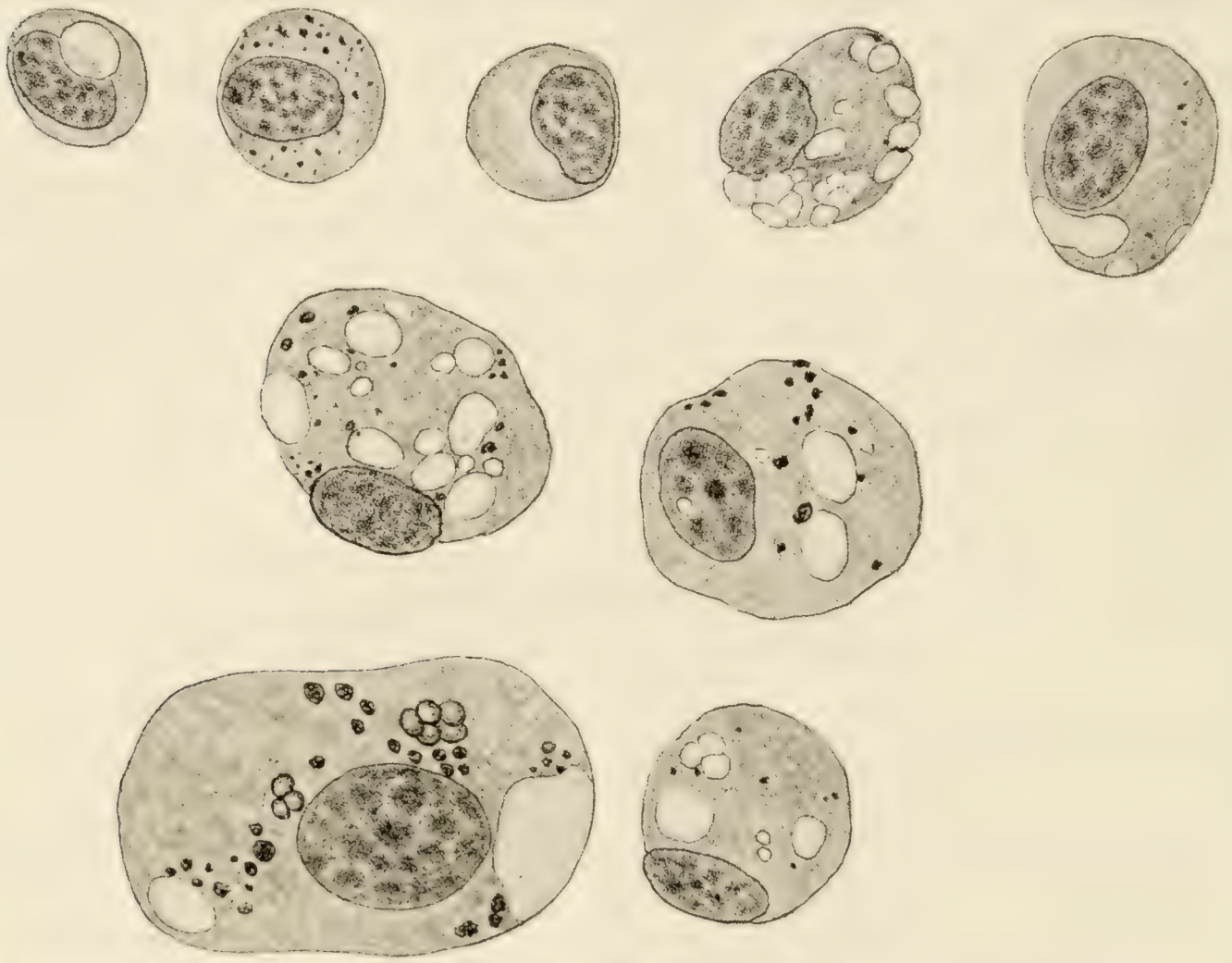

Fig. 165.—Cells containing pigment, blood-corpuscles, and hemic masses from the spleen of dog; × 1800 (from cover-glass of H. F. Müller).

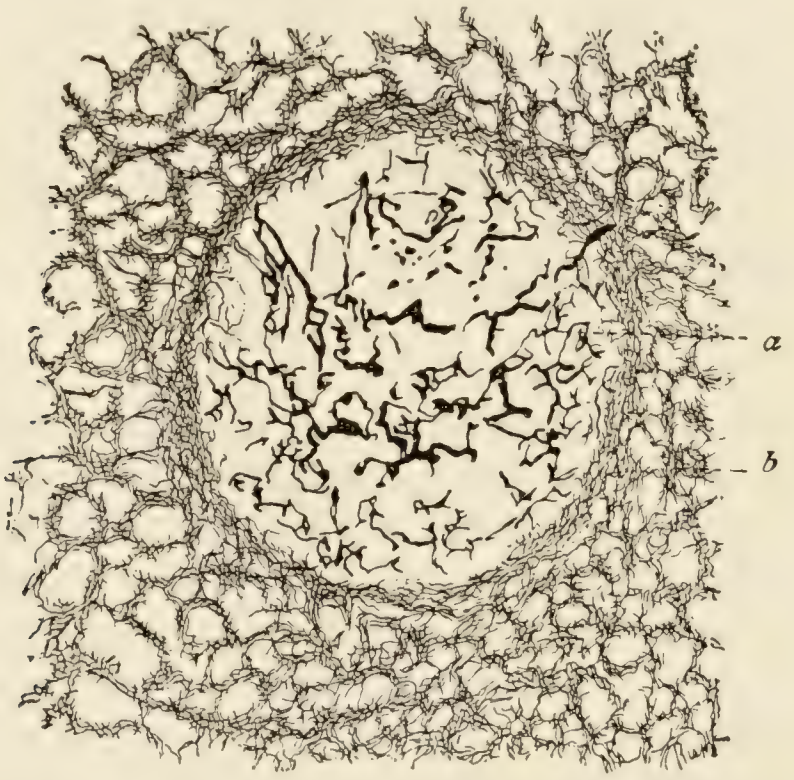

Fig. 166.—From the human spleen; × 80 (chrome-silver method): *a*, Larger fibers of a Malpighian body; *b*, reticular fibrils (Gitterfasern).

In embryonic life and under certain conditions in postembryonic life (after severe hemorrhage and in certain diseases) red blood-cells are developed in the spleen pulp. The nucleated red blood-cells

from which they develop may lose their nuclei in the spleen pulp or only after entering the circulation (compare Bone-marrow).

Lymphatic vessels have been observed in the capsule and trabeculæ, but not in the spleen pulp nor Malpighian corpuscles.

The spleen receives medullated and nonmedullated nerve-fibers; the latter are much more numerous. The medullated nerve-fibers are no doubt the dendrites of sensory neurones. Their mode of ending has, however, not been determined. It is probable that they will be found to terminate in the fibrous-tissue coat of the vessels, and in the trabeculæ and capsule. The nonmedullated nerve-fibers, no doubt the neuraxes of sympathetic neurones, are very numerous; they enter the spleen with the artery and mainly follow its branches. By means of the chrome-silver method, Retzius (92) has shown that in the rabbit and mouse these nerve-fibers follow the vessels, forming plexuses which surround them, the terminal branches of these plexuses terminating in free endings in the muscular coat of the arteries. Here and there a nerve-fiber could be traced into the spleen pulp. The mode of ending of such fibers could, however, not be determined. The nonstriated muscle-cells of the trabeculæ and capsule no doubt also receive their innervation from the nonmedullated nerves (neuraxes of sympathetic neurones).

D. THE BONE-MARROW.

The ingrowing periosteal bud which ushers in the process of endochondral ossification constitutes the first trace of an embryonal bone-marrow (compare p. 117). It consists mainly of elements from the periosteum which penetrate with the vascular bud and later form the entire adult bone-marrow. The *red bone-marrow* is formed first. This is present in embryos and young animals, and is developed from the above elements during the process of ossification. As Neumann (82) has shown, the red bone-marrow of the human embryo is first formed in the bones of the extremities and gradually replaced in a proximal direction, so that in the adult it is found only in the proximal epiphyses, in the flat bones and in the bodies of the vertebræ. In the remaining bones and parts of bones the red bone-marrow is replaced by the *yellow bone-marrow* (fat-marrow).

As a result of hunger and certain pathologic conditions the yellow bone-marrow changes into a gelatinous substance, which, however, may again assume its original character.

The red bone-marrow, surrounded by a delicate fibrous-tissue membrane, the *endosteum*, is a tissue consisting of various cellular elements imbedded in a matrix of reticular tissue, which has been demonstrated by Enderlen with the chrome-silver method, and which is similar to the adenoid reticulum. Aside from these cellular elements, the marrow contains numerous vessels (see below), fixed connective-tissue cells, etc.

The typical cellular elements of red bone-marrow are:

1. *The Marrow-cells, or Myelocytes.*—These are cells, slightly larger than the leucocytes, possessing a relatively large nucleus of round or oval shape, rarely lobular, containing a relatively small amount of chromatin. In the protoplasm of these cells are found (in man) neutrophile granules and now and again small vacuoles. They are said to contain various pigment granules. These cells are not found in normal blood, but are found in circulating blood in certain forms of leukemia, where they may be distinguished from the mononuclear leucocytes partly by their structure, more particu-

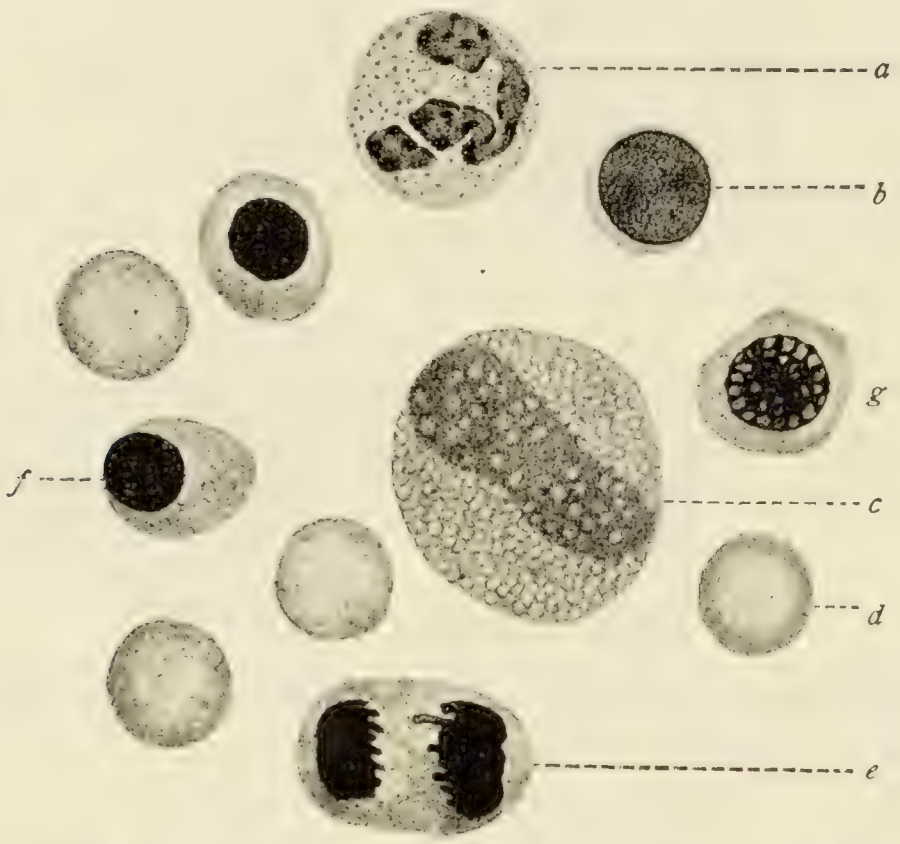

Fig. 167.—Cover-glass preparation from the bone-marrow of dog; × 1200 (from preparation of H. F. Müller): *a*, Mast-cell; *b*, lymphocyte; *c*, eosinophile cell; *d*, red blood-cell; *e*, erythroblast in process of division; *f*, *f*, normoblast; *g*, erythroblast. Myelocyte not shown in this figure.

larly by the presence of neutrophile granules not found in the mononuclear leucocytes.

2. *Nucleated Red Blood-cells containing Hemoglobin.* — Two varieties of these cells are recognized structurally, with intermediary stages, as one variety is developed from the other. The *erythroblasts*, being genetically the earlier cells, possess relatively large nuclei with distinct chromatin network, surrounded by a protoplasm tinged with hemoglobin, and are often found in a stage of mitosis. The other variety of nucleated red blood-cells, the *normoblasts*, are developed from the erythroblasts. They contain globular nuclei, staining deeply, in which no chromatin network is recognizable, and surrounded by a layer of protoplasm containing hemoglobin. The normoblasts are changed into the nonnucleated red blood-discs by the extrusion of the nucleus. This process occurs normally in the red bone-marrow, or in the venous spaces

of the bone-marrow (see below). In certain pathologic conditions, nucleated red blood-cells are found in the circulation.

3. *Cells with Eosinophile Granules.*—In the red bone-marrow are found numerous eosinophile (acidophile) cells, some with round or oval nuclei (mononuclear eosinophile cells), others with horse-shoe-shaped nuclei (transitional eosinophile cells), and still others with polymorphous nuclei. The latter, which are the most numerous, are no doubt the mature cells, and are identical with those elements of the blood having the same structure.

Fig. 168.—From a section through human red bone-marrow; × 680. Technic No. 216: *a*, *f*, Normoblasts; *b*, reticulum; *c*, mitosis in giant cell; *d*, giant cell; *e*, *h*, myelocytes; *g*, mitosis; *i*, space containing fat-cells.

4. *Cells with basophilic granules.* In the bone-marrow are found mononuclear cells in which basophile granules may be differentiated with special reagents.

5. The various forms of *leucocytes* and the *lymphocytes* found in blood and lymph.

6. The *giant cells* (myeloplaxes), which are situated in the center of the marrow, and contain simple or polymorphous nuclei, or lie adjacent to the bone in the form of osteoclasts, which are, as a rule, polynuclear (compare p. 120). The physiologic significance of the giant cells is still obscure. They probably originate from single leucocytes by an increase in size of the latter, and not, as many assume, from a fusing of several leucocytes. The giant cells are endowed with ameboid movement, and often act as phagocytes (the latter quality is denied them by M. Heidenhain, 94).

M. Heidenhain (94) has made a particular study of the giant cells. According to him the nuclei of these cells take the form of perforated hollow spheres whose thick walls contain "endoplasm." The latter is continuous with the remaining protoplasm of the cell, the "exoplasm" through the "perforating canals" of the nuclear wall. The exoplasm is arranged in three concentric layers, separated from each other by membranes, the external membrane of the outer zone being the membrane of the cell. The outer layer or marginal zone is of a transient nature, but is always renewed by the cell. Thus, the cell-membrane is replaced by the secondary membrane situated between the second and third zone. According to the same author the functions of the giant cells appear to consist in "the selection and elaboration of certain albuminoid substances of the lymph and blood currents, which are later returned to the circulation." The number of centrosomes occurring in the mononuclear giant cells of the bone-marrow is very large, and in some cases, as in a pluripolar mitosis, may even exceed one hundred in number.

The distribution of the blood-vessels in the bone-marrow is as follows: On entering the bone the nutrient arteries divide into a large number of small branches, which then break up into small arterial capillaries. The latter pass over into relatively large venous capillaries with relatively thin walls, which appear perforated in certain places, so that the venous blood pours into the spaces of the red bone-marrow where the current is very slow. The blood passes out by means of smaller veins formed by the confluence of the capillaries which collect the blood from the marrow. It is worth mentioning that the venous vessels, while inside of the bone-marrow, possess no valves; but, on the other hand, they have an unusually large number of valves immediately after leaving the bone.

Yellow bone-marrow is derived from red bone-marrow by a change of the marrow-cells into fat-cells. The gelatinous marrow, on the contrary, is characterized by the small quantity of fat which it contains. Neither the yellow nor the gelatinous bone-marrow is a blood-forming organ (compare Neumann, 90; Bizzozero, 91; H. F. Müller, 91; van der Stricht, 92).

E. THE THYMUS GLAND.

The thymus gland is usually considered as belonging to the lymphoid organs, although in its earliest development it resembles an epithelial, glandular structure. In the epithelial stage, this gland develops from the entoderm of the second and third gill clefts. Mesodermic cells grow into this epithelial structure, proliferate and then differentiate into a tissue resembling adenoid tissue. It retains this structure until about the end of the second year after birth, when it slowly begins to retrograde into a mass of fibrous tissue, adipose tissue, and cellular débris, which structure it presents in adult life.

By means of connective-tissue septa, the thymus is divided into larger lobes, and these again into smaller lobes, until finally a number of small, irregularly spheric structures are formed—the lobules of the gland. These are, however, connected by cords of lymphoid tissue, the so-called medullary cords. The lobules of the

Fig. 169.—A small lobule from the thymus of child, with well-developed cortex, presenting a structure similar to that of the cortex of a lymph-gland; × 60: *a*, Hilus; *b*, medullary substance; *c*, cortical substance; *d*, trabecula.

thymus gland consist of a reticular connective tissue much more delicate at the periphery than at the center of the lobule. The reticulum supports branched connective-tissue cells, with relatively large nuclei. In the meshes of the reticular tissue are cellular elements, in structure similar to the lymphocytes, which are more numerous at the periphery of the lobule than at its center, so that we may here speak of

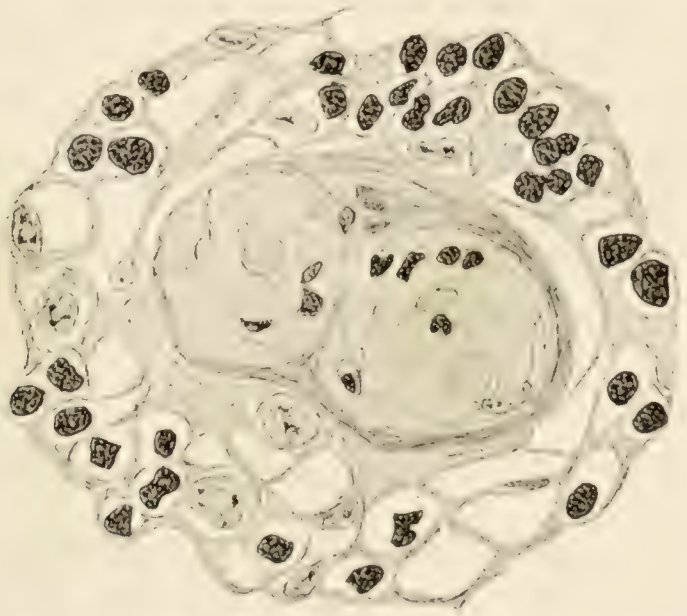

Fig. 170.—Hassal's corpuscle and a small portion of medullary substance, showing reticulum and cells, from thymus of a child ten days old.

the lobule as divided into a cortical and a medullary portion. Leucocytes with polymorphous nuclei, also leucocytes with eosinophile granules, are also found. The medullary portion is usually entirely surrounded by the cortical substance, but may penetrate to the periphery of the lobule, allowing the blood-vessels to enter and

leave at this point. In the cortical substance occur changes which result in the formation of structures closely resembling the cortical nodules of lymph-glands.

Until recently, little was known of the significance of this organ. A careful study revealed a similarity between certain cellular elements of the thymus and the constituents of the blood-forming organs,—a similarity still more striking from the presence of nucleated red blood-cells in the thymus. Logically, then, the embryonal thymus is to be regarded as one of the blood-forming organs (Schaffer, 93, I).

During embryonic life from the fourth month on and for some time after birth, there are found in the thymus peculiar epithelial bodies, known as the *corpuscles of Hassal.* They are spheric structures, about 0.1 mm. in diameter, whose periphery shows a concentric arrangement of the epithelial cells. In their central portions are found a few nuclear and cellular fragments. These bodies occur only in the thymus gland. They are remnants of the primary epithelial, glandular structure of the thymus, and are formed by an ingrowth of mesoderm which breaks down the epithelium into small irregular masses, mechanically compressed by the proliferating mesoderm.

The thymus gland has a relatively rich blood supply. Arterial branches enter the lobules usually near the medullary cords and form capillary networks at the boundaries of the medullary and cortical portions ; from this anastomosing capillaries radiate to the periphery of the lobules, joining to form a relatively dense capillary network under the connective-tissue covering. The veins arise from this capillary network and are situated mostly in the interlobular connective tissue. Certain of the veins are in the medullary portions of the lobules, where they accompany the arteries (Kölliker, v. Ebner).

The lymph-vessels are in the interlobular connective tissue in close apposition with the adenoid tissue.

Nerve-fibers accompanying the blood-vessels have been observed.

II. THE CIRCULATORY SYSTEM.

The walls of the blood-vessels vary in structure in the different divisions of the vascular system. All the vessels, including the heart, possess an inner endothelial lining. In addition to this, the larger vessels are provided with other layers, which consist, on the one hand, of connective and elastic tissue and, on the other, of non-striated muscle-fibers. The vessels are also richly supplied with nerves, that form plexuses in which ganglion cells are sometimes found, and in the larger vessels the outer layer is honeycombed by nutrient blood-vessels, called vasa vasorum. In the heart, the muscular tissue is especially well developed. According to the structure

of the vessels, we distinguish, in both arteries and veins, large, medium-sized, small, and precapillary vessels, and finally, the capillaries themselves. The latter connect the arterial and venous precapillary vessels. In the lymphatic system we must further distinguish between the larger lymph-vessels, the sinuses, and the capillaries.

A. THE VASCULAR SYSTEM.

1. THE HEART.

In the heart there are recognized three main coats—the endocardium, the myocardium, and the pericardium or epicardium.

The *endocardium* consists of plate-like endothelial cells, with very irregular outlines. Beneath this endothelial layer is a thin membrane composed of unstriped muscle-cells, together with a small number of connective-tissue and elastic fibers. Below this is a somewhat thicker and looser layer of elastic tissue connected externally with the myocardium. Between the two layers are found, here and there, traces of a layer of *Purkinje's fibers* (compare p. 147). Purkinje's fibers are found in the heart of many mammalia, although absent in the heart of the human adult.

The *auriculoventricular valves* of the heart represent, in general, a duplication of the endocardium. The layer of smooth muscle-fibers found in the latter is better developed on the auricular surface. At the points of insertion of the chordæ tendineæ the connective-tissue layer is strongly developed and assumes a tendon-like consistency. The *semilunar valves* of the aorta and pulmonary artery have a similar structure. In the nodules of these valves the elastic fibers are especially dense in their arrangement.

The *myocardium* is made up of the heart muscle-fibers already described (*vid.* p. 145). Between the heart muscle-fibers and bundles of such fibers are thin layers of fibrous connective tissue containing a network of capillaries. The myocardium of the auricles may be divided into two layers, of which the outer is common to both auricles, the fibers of which have a nearly circular arrangement, while the deeper layer is separate for each chamber. The arrangement of the heart muscle-fibers of the ventricles is complicated. With special methods of maceration J. B. MacCallum was able to show that "the superficial fibers are found to have origin in the auriculoventricular ring, to wind about the heart spirally, and to end in tendons of the papillary muscle of the opposite ventricle. The deep layers also begin in the tendon of one auriculoventricular ring, pass around to the interventricular septum, cross over backward or forward in this septum, and end in the papillary muscle of the other ventricle. In the light of this, the heart consists of several bands of muscles with tendons at each end, rolled up like a scroll or like the letter S." The musculature of the auricles is almost completely

separated from that of the ventricles by means of the *annulus fibrosus atrioventricularis*, or the auriculoventricular ring, which consists in the adult of connective tissue containing numerous delicate and densely interwoven elastic fibers.

The *pericardium* consists of a visceral layer, the *epicardium*, adhering closely to the myocardium, and a parietal layer (pericardium), loosely surrounding the heart and continuous at the upper portion of the heart with the visceral layer. Between the two layers is the pericardial cavity, containing a small quantity of a serous fluid—the pericardial fluid. In the visceral layer (the epicardium) we find a connective-tissue stroma covered by flattened mesothelial cells. A similar structure occurs also in the parietal layer, although here the connective-tissue stroma is considerably reinforced. Deposits of fat, in most cases in the neighborhood of the blood-vessels, are sometimes seen between the myocardium and the visceral layer of the pericardium.

According to Seipp, the distribution of the elastic tissue in the heart is as follows : The endocardium of the ventricles contains far more elastic tissue than that of the auricles, especially in the left ventricle, where even fenestrated membranes may be present. In the myocardium of the ventricles there are no elastic fibers aside from those which are found in the adventitia of the contained blood-vessels. In the myocardium of the auricles, on the contrary, such fibers are very numerous and are continuous with the elastic elements in the walls of the great veins. The epicardium also presents elastic fibers in the auricles continuous with those of the great veins emptying into the heart, and in the ventricles continuous with those in the adventitia of the conus arteriosus. In those portions of the heart-wall containing no muscular tissue the elastic elements of the epicardium are continuous with those of the endocardium. In the new-born the cardiac valves possess no elastic fibers, although they are present in the adult. They are developed on that side of each valve, which, on closing, is the more stretched—for instance, on the auricular side of the auriculoventricular valves.

The heart has a rich blood supply. The capillaries of the myocardium are very numerous, and so closely placed around the muscle bundles that each muscular fiber comes in contact with one or more capillaries. In the endocardium the vessels are confined to the connective tissue. The auriculoventricular valves contain blood-vessels, in contradistinction to the semilunar valves, which are non-vascular, while the chordæ tendineæ are at best very poorly supplied with capillaries.

The coronary arteries, which terminate in the capillaries above mentioned, are terminal arteries in the sense that " the resistance in the anastomosing branches is greater than the blood pressure in the arteries leading to those branches (Pratt, 98). This observer has further shown that the vessels of Thebesius (small veins which open on the endocardial surfaces of the ventricles and auricles and

communicate directly with all the chambers of the heart) "open from the ventricles and auricles into a system of fine branches that communicate with the coronary arteries and veins by means of capillaries, and with the veins, but not with the arteries, by passages of somewhat larger size"; so that, although the blood supply through the coronary arteries for a given area of the myocardium is cut off, the heart muscle of this area may receive blood through the vessels of Thebesius.

Lymphatic networks have been shown to exist in the endocardium, and their presence in the pericardium is not difficult to demonstrate. Little is known with regard to the lymph-channels of the myocardium.

The nerve supply of the heart includes numerous medullated nerve-fibers, the dendrites of sensory neurones, and numerous non-medullated fibers, the neuraxes of sympathetic neurones. Smirnow (95) described sensory nerve-endings in the endocardium of amphibia and mammalia, which he suggests may be the terminations of the depressor nerve. Dogiel (98) has corroborated and extended these observations, and has described complicated sensory telodendria situated both in the endo- and pericardium. The latter states that, after forming plexuses and undergoing repeated division, the medullated sensory nerves lose their medullary sheaths, the neuraxes further dividing in numerous varicose fibers, variously interwoven and terminating in telodendria, which vary greatly in shape and configuration. These telodendria are surrounded by a granular substance containing branched cells, probably connective-tissue cells, the interlacing branches of which form a framework for the telodendria. Similar sensory nerve-endings occur in the adventitia of the arteries and veins of the pericardium (Dogiel, 98); and Schemetkin has shown that sensory nerve-endings occur in the adventitia and intima, especially in the latter, of the arch of the aorta and pulmonary arteries. In the heart, under the pericardium on the posterior wall of the auricles and in the sulcus coronarius, are found numerous sympathetic neurones whose cell-bodies are grouped to form sympathetic ganglia. The neuraxes of these sympathetic neurones—varicose, nonmedullated nerve-fibers—form intricate plexuses situated under the pericardium and, penetrating the myocardium, surround the bundles of heart muscle-fibers. From the varicose nerve-fibers constituting these plexuses, fine branches are given off, which terminate on the heart muscle-cells in a manner previously described (see p. 166 and Fig. 132). The cell-bodies of the sympathetic neurones, the neuraxes of which thus terminate on the heart muscle-fibers, are surrounded by end-baskets, the telodendria of small medullated nerve-fibers which reach the heart through the vagi. The slowed and otherwise altered action of the heart-muscle, produced on stimulating directly or indirectly the vagus nerves is therefore due not to a direct action of these nerve-fibers on the heart muscle-cells, but to an altered functional activity

produced by vagus stimuli in at least some of the sympathetic neurones situated in the heart, the neuraxes of which convey the impulse to the heart muscle. The heart receives further nerve supply through sympathetic neurones, the cell-bodies of which are situated in the inferior cervical and stellate ganglia, the neuraxes of which enter the heart as the augmentor or accelerator nerves of the heart. The mode of ending of these nerve-fibers has not as yet been fully determined. It may be suggested as quite probable that they terminate on the dendrites of sympathetic neurones, the cell-bodies of which are not inclosed by end-baskets of nerves reaching the heart through the vagi, as above described. It is also possible that they end directly on the heart muscle-cells. The cell-bodies of the sympathetic neurones, the neuraxes of which form the augmentor nerves, are surrounded by the telodendria of small medullated fibers, forming end-baskets, which leave the spinal cord through the anterior roots of the upper dorsal nerves. Besides the nerves here described, nonmedullated nerves (whether the neuraxes of sympathetic neurones, the cell-bodies of which are situated inside or outside of the heart has not been fully determined), form plexuses in the walls of the coronary vessels, terminating, it would seem, on the muscle-cells of the media (vasomotor nerves).

2. THE BLOOD-VESSELS.

A cross-section of a blood-vessel shows several coats. The inner consists of flattened endothelial cells, and is common to all vessels. The second varies greatly in thickness, contains most of the contractile elements of the arterial wall, and is known as the media, or tunica media. Its elastic fibers have in general a circular arrangement and are fused at the inner and outer surfaces to form fenestrated membranes, the lamina elastica interna and externa. Outside of the media lies the adventitia or tunica externa, consisting in the arteries almost entirely of connective tissue and in the veins principally of contractile elements, smooth muscle-fibers. Between the internal elastic membrane and the endothelial layer is a fibrous stratum which varies in structure in the different vessels of larger caliber. This is the subendothelial layer, or the inner fibrous layer, and forms, together with the endothelium, the intima or tunica intima. Bonnet (96), as a result of his own investigations, suggests a somewhat different classification of the layers composing the arterial wall. According to him, the endothelium alone constitutes the intima. The elastic membranes, both internal and external, together with the tissue lying between them, and that between the internal elastic membrane and the intima, constitute the media. The tissue layers outside the external elastic membrane form the tunica externa (adventitia).

(*a*) **Arteries.**—In the *great arterial trunks*, such as the pulmonalis, carotis, iliaca, etc., the tunica media possesses a very typical

structure. It is divided by means of elastic fibers and membranes

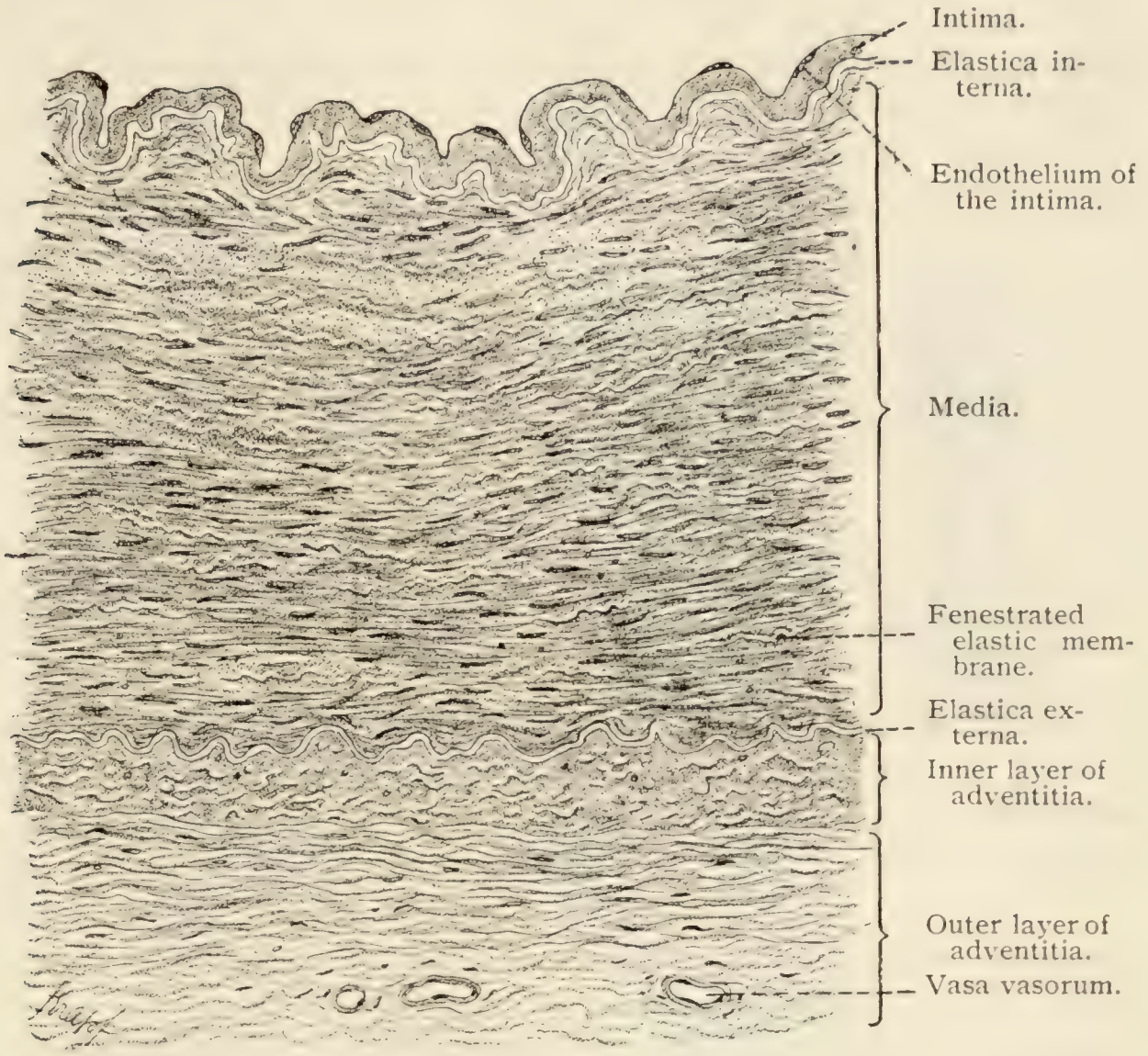

Fig. 171.—Cross-section of the human carotid artery ; × 150.

(fenestrated membranes) into a large number of concentric layers containing but few muscle-fibers. Here also the tunica media is separated from the intima by an elastic limiting membrane, the fenestrated membrane of Henle, or the lamina elastica interna. In the aorta this membrane as such is not recognizable. The intima presents three distinct layers—the inner composed of flattened endothelial cells, and the other two consisting chiefly of elastic tissue (fibrous layers). Of these latter the inner is the richer in cellular

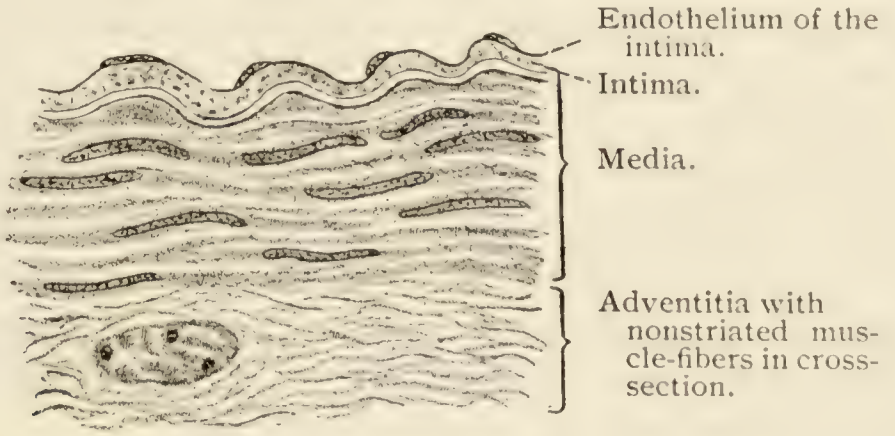

Fig. 172.—Section through human artery, one of the smaller of the medium-sized ; × 640.

elements and has a longitudinal arrangement of its fibers, while the

outer is the looser in structure, possesses few cellular elements, and shows a circular arrangement of its fibers. The adventitia is also made up of fibro-elastic tissue, but in this case with a still looser structure and a longitudinal arrangement of its elastic fibers. In the outer portion of the adventitia the white fibrous tissue is more abundant. The adventitia is rich in blood-vessels.

The *medium-sized arteries* differ in structure from the larger in that the elastic elements of the intima and media are replaced to a considerable extent by nonstriated muscular fibers. To this type belong the majority of the arterial vessels, ranging in caliber from the brachial, crural, and radial arteries to the supraorbital artery. In these the intima shows, besides its endothelium, only a single connective-tissue layer with numerous longitudinal fibers, the subendothelial layer, which is thin and is limited externally by the fenestrated membrane of Henle (lamina elastica interna). The media no longer gives the impression of being laminated, but consists of circularly arranged muscle-fibers separated from each other by elastic fibers and membranes and a small amount of fibrous connective tissue in such a way that the muscle-cells form more or less clearly defined groups. Here also the media is limited externally by the external elastic membrane. The adventitia, which becomes looser externally, is not so well developed as in the larger vessels, but presents in general the same structure. In certain arteries (renal, splenic, dorsalis penis) it shows in its inner layers scattered longitudinal muscle-cells, which, however, may also occur in other arteries at their points of division.

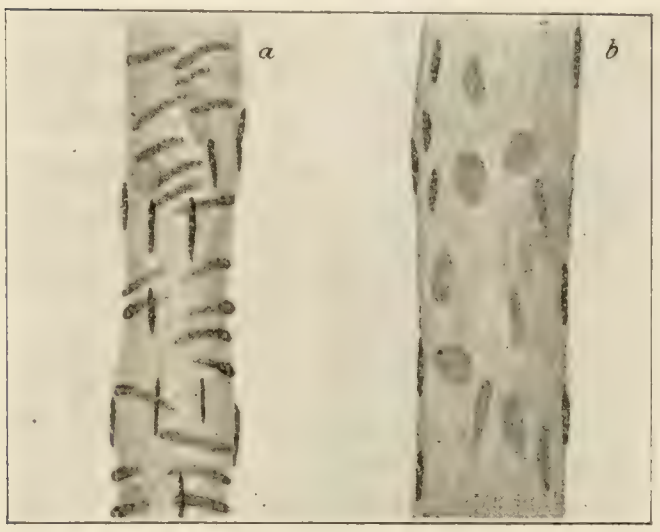

Fig. 173.—Precapillary vessels from mesentery of cat: *a*, Precapillary artery; *b*, precapillary vein possessing no muscular tissue.

With regard to the elastic tissues, the arteries of the brain differ to some extent from those of the remainder of the body. The elastica interna is much more prominent, the elastic fibers in the circular muscular layer are fewer, and the longitudinal strands are almost entirely lacking (H. Triepel).

The walls of the smaller arteries consist mainly of the circular muscular layer of the media. The intima is reduced to the endothelium, which rests directly on the elastic internal limiting membrane. Outside of the external limiting membrane is the adventitia, which now consists of a small quantity of connective tissue. The vasa vasorum have disappeared. To this type belong the supraorbital, central artery of the retina, etc.

In the so-called *precapillary* vessels the intima consists only of the endothelial layer. The internal elastic membrane is very delicate. The media no longer forms a continuous layer, but is

made up of a few circularly disposed muscular fibers. The adventitia is composed of a small quantity of connective tissue, and contains no vasa vasorum.

(*b*) **Veins.**—In the foregoing account of the structure of the arteries we have described the structure of their walls according to the caliber of the vessels. Such a differentiation in the case of the veins would be impossible, since sometimes veins of the same caliber present decided differences in structure in various parts of the body.

For the sake of convenience, we will commence with the description of a vein of medium size. Its intima consists of three layers: (1) Of an inner layer of endothelium; (2) of an underlying layer of muscle-cells, interrupted here and there by connective tissue; and (3) of a fibrous connective-tissue layer containing fewer elastic but more white fibrous connective-tissue fibers than is the case in the arteries. Externally, the intima is limited by an in-

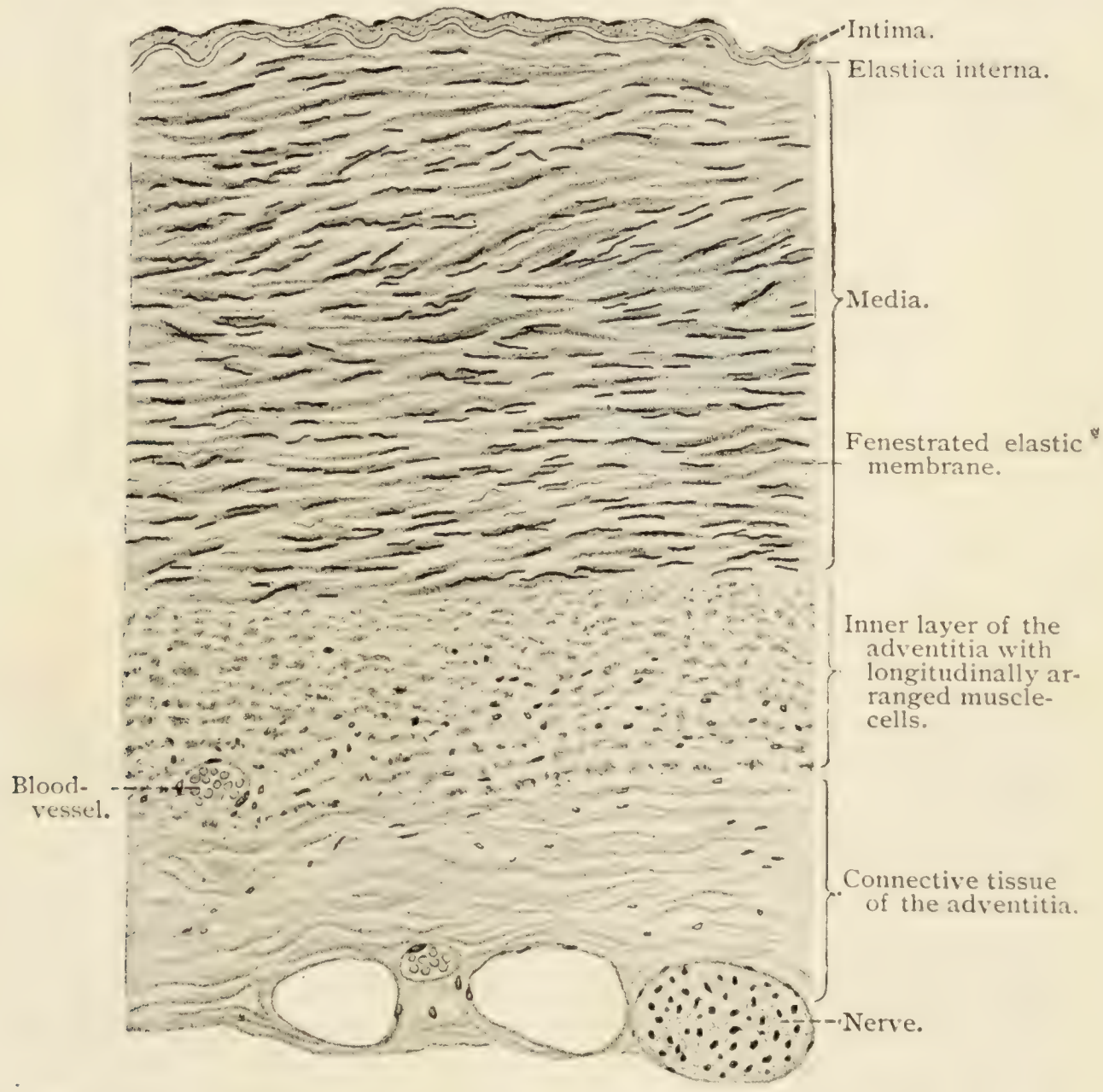

Fig. 174.—Cross-section of human internal jugular vein. At the left of the nerve are two large blood-vessels with a smaller one between them (vasa vasorum); × 150.

ternal elastic layer. The media is in general less highly developed than that of a corresponding artery, and contains muscle-cells which have a circular arrangement and in some veins form a continuous

layer, although they sometimes occur as isolated fibers. The adventitia shows an inner longitudinal muscular layer, which may be quite prominent and even form the bulk of the muscular tissue in the wall of the vein. Otherwise the adventitia of the veins belonging to this class corresponds in general to that of the arteries of the same size; but here also we have, as in the intima, a preponderance of white fibrous connective-tissue elements.

In the crural, brachial, and subcutaneous veins, the musculature of the media is prominent; while in the jugular, subclavian, and innominate veins, and in those of the dura and pia mater, the muscular tissue of the media is entirely wanting, and, as a consequence, the adventitia with its musculature, if present, is joined directly to the intima.

In the *smaller veins* the vascular wall is reduced to an endothelial lining, an internal elastic membrane, a media consisting of interrupted circular bands of smooth muscle-fibers (which may be absent), and an adventitia containing a few muscle-fibers. The *precapillary veins*, which possess in general thinner walls than the corresponding arteries, present a greatly reduced intima and adventitia, while the media has completely disappeared.

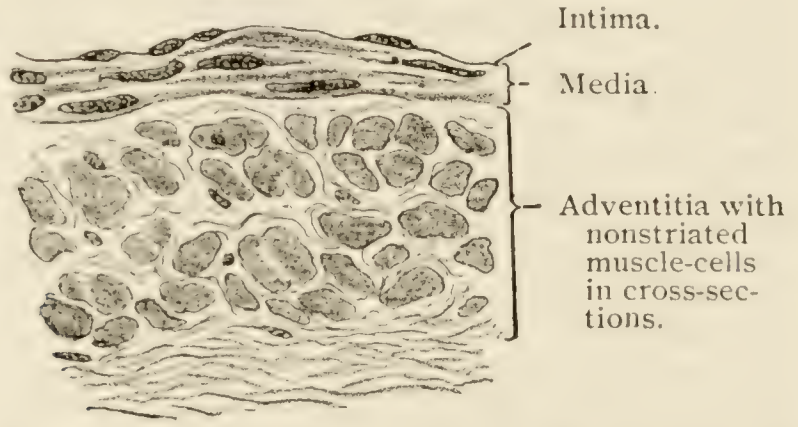

Fig. 175.—Section of small vein (human); × 640.

The *valves* of the veins are reduplications of the intima and vary slightly in structure at their two surfaces. The inner surface next to the blood current is covered by elongated endothelial cells, while the outer surface possesses an endothelial lining composed of much shorter cellular elements. The greater part of the valvular structure consists of white fibrous connective-tissue and elastic fibers. Flattened and circularly arranged muscle-cells are met with at the inner surface of many of the larger valves. The elastic fibers are more numerous beneath the endothelium on the inner surface of the valves (Ranvier, 89).

(*c*) **The Capillaries.**—The capillaries consist solely of a layer of endothelial cells, accompanied here and there by a very delicate structureless membrane, and rarely by stellate connective-tissue cells. The connective tissue in the immediate neighborhood of the capillaries is modified to such an extent that its elements, especially those of a cellular nature, seem to be arranged in a direction parallel with the long axis of the capillaries. When examined in suitable prepara-

tions, the endothelium of the capillaries is seen to form a continuous layer, the cells of which are, as a rule, greatly flattened and present very irregular outlines.

It is a well-known fact that a migration of the leucocytes occurs from the capillaries and smaller vessels (compare p. 193). In this connection arises the question as to whether or not the cells pass through certain preformed openings in the endothelium of these vessels, the so-called stomata, or through the stigmata and intercellular cement uniting the endothelial cells. The latter seems more probable, as stomata do not occur normally in the capillary wall. This subject will be further touched upon in the description of the lymphatic system.

The capillaries connect the arterial and venous precapillary vessels, and in general accommodate themselves to the shape of the elements of tissues or organs in which they are situated. In the

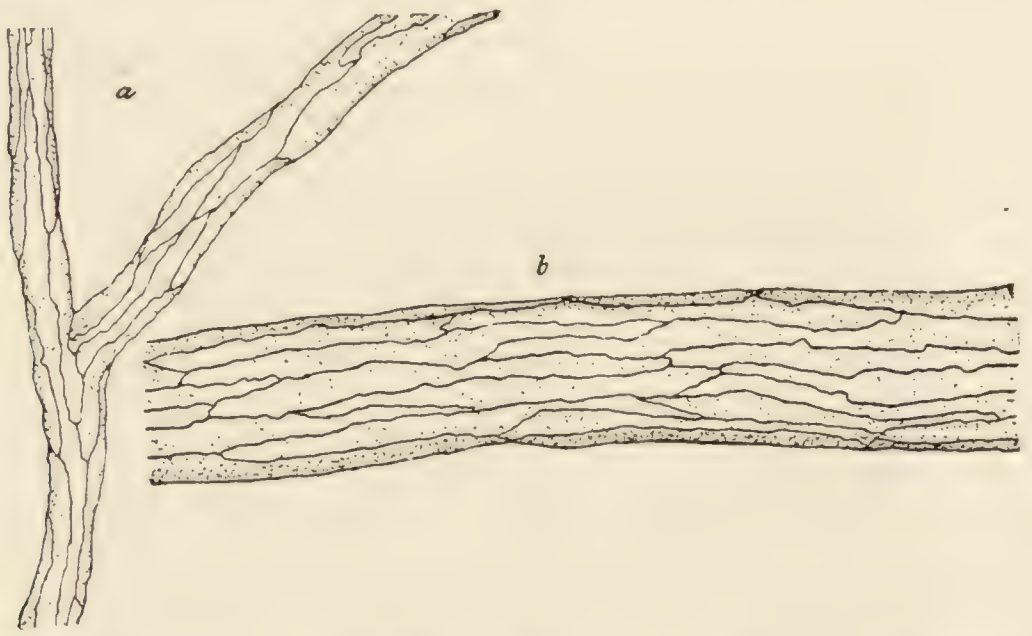

Fig. 176.—Endothelial cells of capillary (*a*) and precapillary (*b*) from the mesentery of rabbit; stained in silver nitrate.

muscles and nerves, etc., they form a network with oblong meshes, while in structures having a considerable surface, such as the pulmonary alveoli, the meshes are more inclined to be round or oval; such small evaginations of tissue as the papillæ of the skin contain capillaries arranged in the shape of loops. In certain organs—as, for instance, in the lobules of the liver—the capillaries form a distinct network with small meshes.

Sinusoids.—In connection with the description of capillaries we may here insert a brief account of another type of terminal or peripheral blood-channels, described by Minot under the name of sinusoids; his account is here followed. The sinusoids are also composed only of endothelial cells. They differ, however, from blood-capillaries in shape and size, in their relation to the cellular elements of the tissues in which they are found, and in their development. They are of relatively large size, and vary between wide extremes. They are of very irregular shape and anastomose freely. "A sinusoid has its endothelium closely fitted against the paren-

chyma of the organ," without the intervention of connective tissue; or, when this is present, usually only in small quantity, it is secondarily acquired, since in the early developmental stages of sinusoids no connective tissue intervenes between them and the parenchyma of the tissue. They develop by the intergrowth and intercrescence of the parenchyma of the organ and venous endothelium. Sinusoids are found in the following organs: liver, suprarenal, heart, parathyroid, carotid gland, spleen, and hemolymph glands.

(*d*) **Anastomoses, Retia mirabilia, and Sinuses.**—In the course of certain vessels, abrupt changes are seen to occur—as, for instance, when a small vessel suddenly breaks up into a network of capillary or precapillary vessels, which, after continuing as such for a short distance, again unite to form a larger blood-channel, the latter then dividing as usual into true capillaries. Such structures are known as *retia mirabilia*, and occur in man in the kid-

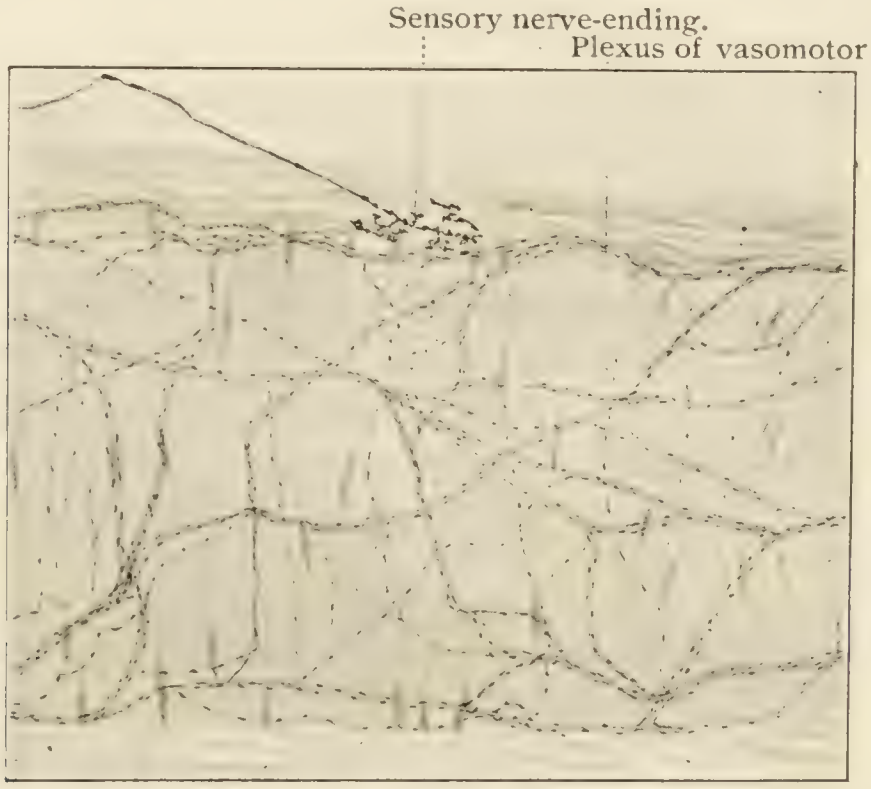

Fig. 177.—Small artery from the oral submucosa of cat, stained in methylene-blue, and showing a small portion of a sensory nerve-ending and the plexus of vasomotor nerves.

ney, intestine, etc. Again, instead of breaking up into capillaries, a vessel may empty into a large cavity lined by endothelial cells (blood sinus). The latter is usually surrounded by loose connective tissue and is capable of great distention when filled with blood from an afferent vessel, or when the lumen of the efferent vessel is contracted by pressure or otherwise. The cavernous or erectile tissue of certain organs is due to the presence of such sinuses (penis, nasal mucous membrane, etc.). If vessels of larger caliber possess numerous direct communications, a vascular plexus is the result; but if such communications occur at only a few points, we speak of anastomoses. Especially important are the direct communications between arteries and veins without the mediation of capillaries. Certain structural conditions of the tissue appear to favor such anomalies, which occur in certain exposed

areas of the skin (ear, tip of nose, toes) and in the meninges, kidney, etc.

The blood-vessels, and more particularly the arteries, possess a rich nerve supply, comprising both nonmedullated and medullated nerves. The nonmedullated nerves, the neuraxes of sympathetic neurones, the cell-bodies of which are situated as a very general rule in some distant ganglion, form plexuses in the adventitia of the vessel-walls ; from this, single nerve-fibers, or small bundles of such, are given off, which enter the media and, after repeated division, end on the involuntary muscle-cells in a manner previously described. (See p. 166 and Fig. 133.) Through the agency of these nerves, the caliber of the vessel is controlled. They are known as vasomotor nerves. Quite recently Dogiel, Schemetkin, and Huber have shown that many vessels possess also sensory nerve-endings. The medullated nerve-fibers terminating in such endings, branch repeatedly before losing their medullary sheaths. These nerve-fibers with their branches accompany the vessels in the fibrous tissue immediately surrounding the adventitia. The nonmedullated terminal branches end in telodendria, consisting of small fibrils, beset with large varicosities and usually terminating in relatively large nodules.

The branches and telodendria of a single medullated nerve-fiber (sensory nerve) terminating in a vessel are often spread over a relatively large area, some of the branches of such a nerve often accompanying an arterial branch, to terminate thereon. In the large vessels, the telodendria of the sensory nerves are found not only in the adventitia, but also in the intima, as has been shown by Schemetkin. (See p. 215.)

B. THE LYMPHATIC SYSTEM.

1. LYMPH-VESSELS.

The larger lymph-vessels—the thoracic duct, the lymphatic trunks, and the lymph-vessels—have relatively thin walls, and their structure corresponds in general to that of the veins. They possess numerous valves, and are subject to great variation in caliber according to the amount of their contents. When empty, they collapse and the smaller ones are not easily distinguished from the surrounding connective tissue. Timofeew and Dogiel (97) have shown that the lymph-vessels are supplied with nerves, which in their arrangement are similar to those found in the arteries and veins, though not so numerous. The latter, who has given the fuller description, states that the nerves supplying the lymph-vessels are varicose, nonmedullated fibers which form plexuses surrounding these structures. The terminal branches would appear to end on the nonstriated muscle cells found in the wall of the lymph-vessel.

2. LYMPH CAPILLARIES, LYMPH-SPACES, AND SEROUS CAVITIES.

The walls of the lymph capillaries consist of very delicate, flattened endothelial cells, which are, however, somewhat larger and more irregular in outline than those of the vascular capillaries. The two may also be further differentiated by the fact that the diameter of the lymph capillaries varies greatly within very short distances. From a morphologic standpoint, the relations of the lymph capillaries to the vascular capillaries and adjacent tissues are among the most difficult to solve. The distribution of the lymph-vessels and capillaries can be studied only in injected preparations, and it is easily seen that structures of such elasticity and delicacy are peculiarly liable to injury by bursting under this method of treatment. The resulting extravasations of the injection-mass then spread out in the direction of least resistance and still further obscure the picture, rendering it difficult to determine what spaces are preformed and what are the result of the injection. So much is, however, certain : that the more carefully and skilfully the injection is made, the greater are the areas obtained, showing the injection of true lymph capillaries. The recent work of W. G. MacCallum confirms this, since he has shown quite conclusively that the lymphatics form a system of channels, with continuous walls, and are thus not in direct communication with the so-called intercellular lymph-spaces—the lymph-canalicular spaces. Further confirmation of the fact that the lymphatics form a closed system of channels is found in the excellent contribution of Dr. Florence R. Sabin, dealing with the development of the lymphatic system. It is here shown that the lymphatic system begins as two blind ducts, guarded by valves, which bud off from the veins of the neck, and from two similar buds which arise from veins in the inguinal region. These buds grow and enlarge to form lymph-hearts, and from these ducts grow out toward the skin, which they invade and in which they spread out to form anastomosing plexuses. Ducts also grow toward the aorta to form the anlagen for the thoracic ducts, and from these grow out and invade the various organs.

In some regions very dense networks of lymph capillaries surrounding the smaller blood-vessels have been demonstrated. Larger cleft-like spaces, lined with endothelium and communicating with the lymphatic system, are also found surrounding the vessels, *perivascular spaces.* These are present in man in the Haversian canals of bone tissue, around the vessels of the central nervous system, etc., and are separated from the actual vessel-wall by flattened endothelial cells. As in the case of the so-called *perilymphatic spaces*, the walls of the perivascular spaces are joined here and there by connective-tissue trabeculæ covered by endothelium. Such structures exist in the perilymphatic spaces of the ear, the subdural spaces of the pia, the subarachnoidal space, the lymph-sinuses, etc. The perivascular spaces are better developed in the lower animals (amphibia, reptilia, etc.) than in mammalia.

Mention has been made of the migration of leucocytes and, under certain conditions, of red blood-cells through the walls of blood capillaries, and in the case of the former through the walls of lymph capillaries and lymph-vessels and spaces. This diapedesis of leucocytes probably takes place by a wandering of these cells through the intercellular cement uniting the endothelial cells lining these spaces. According to later investigations, it would seem that leucocytes may bore through endothelial cells, and thus migrate from the vessel or space in which they are found previous to such migration.

C. THE CAROTID GLAND (GLANDULA CAROTICA, GLOMUS CAROTICUM).

At the point where the common carotid divides, there lies in man a small oval structure about the size of a grain of wheat, known as the carotid gland or the glomus caroticum. It is imbedded in

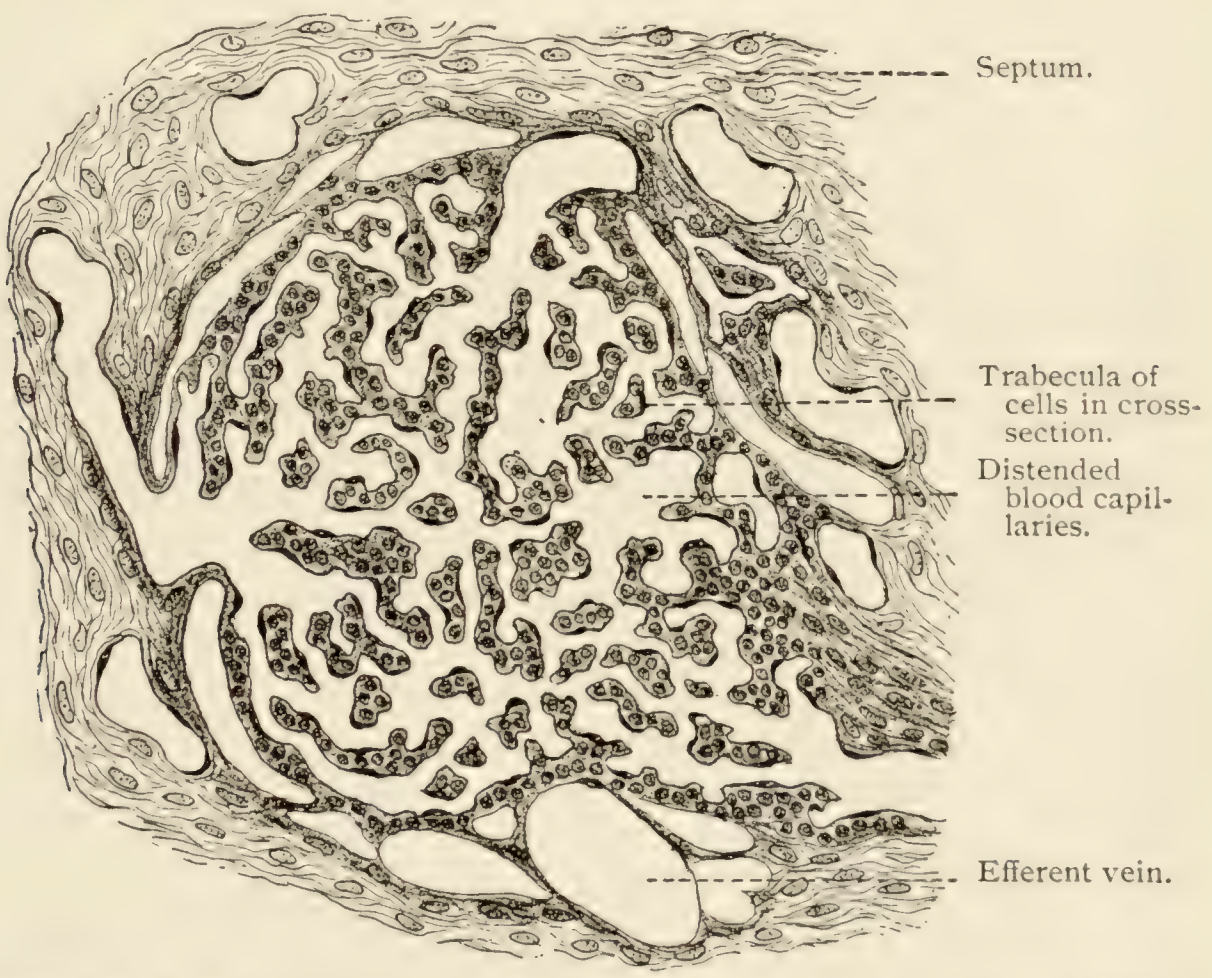

Fig. 178.—Section of a cell-ball from the glomus caroticum of man ; × 160. (Injected specimen, after Schaper.)

connective tissue, surrounded by many nerve-fibers, and on account of its great vascularity has a decidedly red color. The connective-tissue envelope of the gland penetrates into the interior in the form of septa, which divide its substance into small lobules, and these in turn into smaller round masses, the cell-balls. A small branch from the internal or external carotid enters the gland, where it branches, sending off twigs to the lobules, and these in turn still

smaller divisions to the cell-balls. The latter vessels break up into capillaries, which merge at the periphery of each cell-ball to form a small vein, from which the larger trunks that pass from the lobules are derived. Each lobule is thus surrounded by a venous plexus from which the larger veins originate that leave the organ at several points. The cell-balls are composed of cellular cords, or trabeculæ, the elements of which are extremely sensitive to the action of reagents. The cells are round or irregularly polygonal and separated from each other by a scanty reticular connective tissue. The capillaries already mentioned come in direct contact with the cells of the cell-balls. The organ contains a relatively large number of nerve-fibers and a few ganglion cells.

As the individual grows older, the organ undergoes changes which finally make it unrecognizable. The former belief that the carotid gland was developed as an evagination of one of the visceral pouches has been replaced by a newer theory which gives it an origin solely from the vessel-wall (*vid.* Schaper). The structure of the coccygeal gland is in general like that of the carotid gland here described.

TECHNIC (BLOOD AND BLOOD-FORMING ORGANS).

Red blood-corpuscles may be examined in the blood fluid without special preparation. The tip of the finger is punctured and a small drop of blood pressed out, placed upon a slide, and immediately covered with a cover-glass and examined. In such preparations the red blood-cells soon become crenated. The evaporation causing the crenation may be prevented by surrounding the cover-glass with oil (olive oil). A fluid having but slight effect upon the red blood-cells is **Hayem's solution,** which, however, is not adapted to the examination of leucocytes. It consists of sodium chlorid 1 gm., sulphate of soda 5 gm., corrosive sublimate 0.5 gm., and water 200 gm. The fresh blood is brought directly into this solution, the amount of which should be at least one hundred times the volume of the blood to be examined. The fixed blood-cells sink to the bottom, and after twenty-four hours the fluid is carefully poured off and replaced by water. The blood-corpuscles are then removed with a pipet and examined in dilute glycerin. They may be stained with eosin and hematoxylin.

Fresh red blood-corpuscles may also be fixed in osmic acid and other special fixing agents. This is done by dropping a small quantity of blood into the fixing fluid; the blood-cells immediately sink and allow the osmic acid to be decanted; they are then washed with water, drawn up with a pipet, and examined in dilute glycerin.

Cover-glass Preparations.—A method almost universally used consists in preserving the blood-corpuscles in dry preparations. A drop of fresh blood is placed between two thoroughly cleaned cover-glasses, which are then quickly drawn apart, leaving on the surface of each a thin film of blood which dries in a few moments at ordinary room temperature. The specimens are further dried for several hours at a temperature of 120° C. After they have been subjected to this process, they may be stained, etc. The same results may be obtained by treating specimens dried in the air

with a solution of equal parts of alcohol and ether for from one to twenty-four hours, after which they are again dried in the air, and are then ready for further treatment.

A cover-glass preparation of fresh blood may also be treated for a quarter of an hour with a concentrated solution of corrosive sublimate in saline solution, then washed with water, stained, dehydrated with alcohol and mounted in Canada balsam. A concentrated aqueous solution of picric acid may also be used, but in this case the specimen should remain in it for from twelve to twenty-four hours.

The elements of the blood may also be examined in sections. Small vessels are ligated at both ends, removed, fixed with osmic acid, corrosive sublimate, or picric acid, and imbedded in paraffin.

After fixation by any of the above methods the blood-cells may be stained. Eosin brings out very well the hemoglobin in the blood-cells, coloring it a brilliant red; the stain should be used in very dilute aqueous or alcoholic solutions (1% or less), or in combination with alum (eosin 1 gm., alum 1 gm., and absolute alcohol 200 c.c., E. Fischer). Eosin may also be used as a counterstain subsequent to a nuclear stain—for instance, hematoxylin. The preparation is stained for about ten minutes, then washed in water or placed in alcohol until the blood-cells alone remain colored; the cover-glass preparation should then be thoroughly dried between filter-paper and mounted in Canada balsam. Besides eosin, other acid stains—as orange G, indulin, and nigrosin—have the property of coloring blood-cells containing hemoglobin.

Blood platelets are best fixed with osmic acid, and may be seen without staining. They may also be stained and preserved in a sodium chlorid solution to which methyl-violet is added in a proportion of 1 : 20000 (Bizzozero, 82). Afanassiew adds 0.6% of dry peptone to the solution (this fluid must be sterilized before using).

Ehrlich's Granulations.—The leucocytes of the circulating blood and those found in certain organs possess granulations which were first studied by Ehrlich and his pupils, and which may be demonstrated by certain methods. The names given to these granulations are based upon Ehrlich's classification of the anilin stains, which differs from that of the chemist. This author distinguishes acid, basic, and neutral stains. By the acid stains he understands those combinations in which the acid is the active staining principle, as in the case of the picrate of ammonia. Among these are congo, eosin, orange G, indulin, and nigrosin. The basic stains are those which, like the acetate of rosanilin, consist of a color base and an indifferent acid. To these belong fuchsin, Bismarck brown, safranin, gentian, dahlia, methyl-violet, methylene-blue, and toluidin. Finally, the neutral anilins may be considered as those stains which, like the picrate of rosanilin, are formed by the union of a color base with a color acid. The granula may be demonstrated in dry preparations as well as in those fixed with alcohol, corrosive sublimate, glacial acetic acid, and sometimes even Flemming's solution. Five kinds of granules are distinguished, and designated by the Greek letters from alpha to epsilon.

The α-granules (**acidophile, eosinophile**) occur in leucocytes of the normal blood, in the lymph, and in the tissues, and are differentiated from the others by their peculiar staining reaction to all acid stains. They are first treated for some hours with a saturated solution of an acid

stain (preferably eosin) in glycerin, washed with water, subsequently colored with a nuclear stain (as hematoxylin or methylene-blue), and then dried and mounted in Canada balsam. Sections may be treated in the same way, with the exception that after being washed with water, they are first dehydrated with absolute alcohol before mounting in balsam.

Another method by which both nuclei and granules are stained consists in the use of Ehrlich's hematoxylin solution (see page 43), to which 0.5% eosin is added. Before using, the solution should be permitted to stand exposed to the light for three weeks. This mixture stains in a few hours, after which the preparation is washed with water, treated with alcohol, and then mounted in Canada balsam. The α-granules appear red, the nuclei blue.

The β-granules (**amphophile, indulinophile**) stain as well in acid as in basic anilins. They do not occur in man, but may be observed in the blood of guinea-pigs, fowl, rabbits, etc. They are demonstrated as follows: Equal parts of saturated glycerin solutions of eosin, naphthylamin-yellow, and indulin are mixed, and the dried preparations treated with this combination for a few hours, then washed with water, dried between filter-paper, and mounted in Canada balsam. The amphophile granules are stained black, the eosinophile granules red, the nuclei black, and the hemoglobin yellow.

The γ-granules, or those of the **mast-cells,** are found in normal tissues and also in small quantities in normal blood, and are found in larger numbers in leukemic blood. They may be shown by two methods: (1) A mixture is made consisting of concentrated solution of dahlia in glacial acetic acid 12.5 c.c., absolute alcohol 50 c.c., distilled water 100 c.c. (Ehrlich). The treatment is the same as for the amphophile granules; (2) Westphal's alum-carmin-dahlia solution (*vid.* Ehrlich). This mixture is used in staining dry preparations as well as sections of objects fixed for at least one week in alcohol. Alum 1 gm. is dissolved in distilled water 100 c.c., and carmin 1 gm. added. The whole is then boiled for one-quarter hour, cooled, filtered, and 0.5 c.c. of carbolic acid added (Grenacher's alum-carmin, see page 42). This solution is now mixed with 100 c.c. of a saturated solution of dahlia in absolute alcohol, glycerin 50 c.c., and glacial acetic acid 10 c.c., the whole stirred and allowed to stand for a time. The specimen is stained for twenty-four hours, decolorized in absolute alcohol for the same length of time, and finally mounted in Canada balsam. The γ-granules are colored a dark blue and the nuclei red. A simpler method of demonstrating the γ-granules consists in overstaining dry and fixed cover-glass preparations with a saturated aqueous solution of methylene-blue, decolorizing for some time in absolute alcohol, drying between filter-papers, and mounting in Canada balsam.

The δ-granules (**basophile**) occur in mononuclear leucocytes of the human blood. Their staining may be accomplished in a few minutes by treating fixed cover-glass preparations with a concentrated aqueous solution of methylene-blue, after which they are washed with water, dried between filter-papers, and mounted in Canada balsam.

The ε- or **neutrophile granules** which are found normally in the polynuclear leucocytes of man (as also in pus-cells), in some of the transitional cells, and in the myelocytes, are stained by Ehrlich as follows: 5 vols. of a saturated aqueous solution of acid fuchsin are mixed with 1 vol.

of a concentrated aqueous solution of methylene-blue. To this 5 vols. of water are added, and the whole allowed to stand for a few days, after which the solution is filtered. This mixture stains in five minutes, and the specimen is then washed with water, etc. The neutrophile granules are colored green, the eosinophile granules red and the hemoglobin yellow.

Neutrophile and eosinophile granules may also be stained in Ehrlich's neutrophile mixture:

Orange G, saturated aqueous solution, . .	130 to 135 c.c.
Acid fuchsin, " " " . .	80 to 120 "
Methyl-green, " " " . .	125 "
Distilled water, ...	300 "
Absolute alcohol, ...	200 "
Glycerin, ...	100 "

Mix the above quantities of orange G, acid fuchsin, water, and alcohol in a bottle and add slowly, while shaking the bottle, the methyl-green and finally the glycerin. The cover-glass preparations should be fixed in the ether and alcohol solution for about one hour, or fixed with dry heat at a temperature of 110° C. for from fifteen to thirty minutes. Float the preparation on a small quantity of the stain for about fifteen minutes, wash in water, dry and mount in balsam. The red blood-cells are stained a reddish-brown color (brick-color), all nuclei a light blue-green, the eosinophile granules a fuchsin-red, and the neutrophile granules a violet-red. Grübler, of Leipzig, has prepared a dry powder, known as the Ehrlich-Biondi-Heidenhain three-color mixture, which is prepared for use by making a 0.4% solution in distilled water, to 100 c.c. of which are added 7 c.c. of a 0.5% aqueous solution of acid fuchsin.

Wright's Method of Staining Blood Films.—This excellent and rapid method is especially recommended.

Stain.—Make a one-half per cent. aqueous solution of sodium bicarbonate in an Erlenmeyer flask and add to it one per cent. of methylene-blue. Steam for one hour in an Arnold steam sterilizer and allow mixture to cool, and when it is cold pour in a large dish. To 100 c.c. of this solution add about 500 c.c. of a one-tenth per cent. aqueous solution of eosin (Grübler's yellowish eosin, soluble in water). The quantity of the eosin solution can not be definitely given; it is added while constantly stirring until the solution becomes of purple color and a yellowish scum with metallic luster forms on the surface and a finely granular black precipitate appears in suspension. The precipitate is collected on a filter and allowed to dry thoroughly. Make a saturated solution in pure methylic alcohol (0.3 gm. of precipitate to 100 c.c. of methylic alcohol) and filter. To 80 c.c. of the filtrate 20 c.c. of methylic alcohol is added to complete the stain.

Staining of Blood Films.—Allow blood film to dry in the air and pour as much of the stain on the cover-glass or slide as it will hold, allowing it to remain in contact with the preparation for about one minute; then add, drop by drop, enough water to make the stain semi-transparent, and a reddish tinge appears at the borders and a metallic scum on the surface. This diluted stain remains on the preparation two or three minutes. The preparation is now washed in distilled water until the better parts have a yellowish or reddish color. Dry quickly between filter-papers and mount on balsam. Red cells are orange or

pink in color; the nuclei, of blue color of varying intensity, eosinophile granules red, neutrophile granules reddish-lilac, basophile granules dark blue or almost black.

The **hemoglobin** shows itself in the form of crystals. In certain teleosts the crystals are formed in the blood-corpuscles around the nuclei and often within a short time after death. In old alcoholic specimens, hemoglobin crystals (blood crystals) are found in the vessels and were first discovered here by Reichert in the blood of the guinea-pig. They have been found in large quantities in the splenic blood of a sturgeon which had been preserved for forty years in alcohol. The hemoglobin crystals belong to the rhombic series of crystallographic classification. The simplest method of demonstrating hemoglobin crystals is probably the following: The blood is first defibrinated by whipping or agitating with mercury, after which process sulphuric ether is added, drop by drop, until the mixture has been made laky; this change may be detected macroscopically by the sudden change from an opaque to a dark, transparent, cherry-red color. No red blood-cells should now be seen under the microscope. The preparation is placed on ice for from twelve to twenty-four hours after which a drop of the blood is placed on a slide. In half an hour it will be seen that the margin of the drop has begun to dry. A cover-slip is now applied and, after a few minutes, numerous crystals are seen to form at the margin of the drop, a process which may be followed under the microscope. Large hemoglobin crystals are obtained by Gscheidtlen as follows: Defibrinated blood is placed in a glass tube, which is then hermetically sealed. The blood is now subjected to a temperature of about 40° C. for two or three days; if then the glass be broken and the blood poured into a flat dish, large hemoglobin crystals are immediately formed. Crystals also appear if a drop of laky blood be placed in a thick solution of Canada balsam in chloroform and covered with a cover-slip.

Hemin crystals (Teichmann's crystals; hemin is hematin-chlorid) in the shape of rhombic plates are very easily obtained from the blood. A drop of the latter is placed on a slide and carefully mixed with a small drop of normal salt solution. This is then carefully warmed until the fluid evaporates and leaves a reddish-brown residue, after which a cover-glass is applied and glacial acetic acid added until the space between slide and cover-glass is filled. The preparation is now heated until the acetic acid boils. As soon as the latter evaporates, Canada balsam may be brought under the cover-glass, thus producing a permanent specimen. When fluids or stains suspected of containing blood are to be examined, the hemin crystals become of the utmost importance, as their demonstration is then a positive indication of the presence of blood. Fluids are evaporated and treated with glacial acetic acid as above directed. Suspected blood stains on cloth are treated as follows: Small pieces are cut from the cloth in the region of the stain, soaked in normal salt solution, and the resulting fluid treated as above. If the stain is on wood or other solid object, the stain is scraped off and dissolved in normal salt and then tested for hemin crystals. Hemin crystals are almost or entirely insoluble in water, alcohol, ether, ammonia, glacial acetic acid, dilute sulphuric acid, and nitric acid. They are, however, soluble in potassium hydrate.

A third form of crystals occasionally found in the blood and frequently in the corpora lutea and, under pathologic conditions, also in apo-

plectic areas, are the **hematoidin crystals** first discovered by Virchow. Masses of these crystals have an orange color. Microscopically, they appear as red rhombic plates. As they are soluble in neither alcohol nor chloroform, they are easily preserved in Canada balsam. Their artificial production has as yet never been accomplished. Hematoidin contains no iron.

The **fibrin** thrown down when the blood coagulates may be demonstrated upon the slide in the form of very fine particles and filaments. A drop of blood is brought upon the slide and kept for a time in a moist chamber or on the table until it begins to clot; after which a cover-slip is applied and the preparation washed with water by continued irrigation. In this manner most of the red blood-corpuscles are removed. Lugol solution may now be added, which stains brown the filaments of the fibrin network adherent to the slide. In order to see the fibrin network in sections, it is better to use specimens previously fixed in alcohol; the sections are stained for ten minutes in a concentrated solution of gentian-violet in anilin water (Weigert), rinsed in normal salt solution, treated for about ten minutes with iodo-iodid of potassium solution, and then spread upon a slide and dried with filter-paper. They are now placed in a solution consisting of 2 parts of anilin oil and 1 part of xylol until they become perfectly transparent. This solution is then replaced by pure xylol and finally by Canada balsam. The fibrin network is stained a deep violet.

Blood Current.—There are different methods and a variety of material at our disposal for the demonstration of the blood current through the vessels. The best object for this purpose is probably the frog. The procedure is as follows: The animal is immobilized by poisoning with curare. ½ gm. of a 1% aqueous solution injected into the dorsal lymph-sac will immobilize the frog in a short time. The exact dose can not, however, be given, as the commercial curare is not a uniform chemical compound; the dose must therefore be ascertained by experiment. As is well known, curare affects exclusively the nerve end-organs of striated voluntary muscle, but does not affect either the heart muscle or unstriated muscular tissue; hence the utility of curare for this purpose. In order to see the blood current, it is only necessary to stretch the transparent web between the frog's toes and fasten it with insect needles to a cork plate having a suitable opening. If the cork plate be large enough to accommodate the whole frog, it may be placed in such a position that its opening lies over that in the stage of the microscope. The web thus spread out may be examined with a medium magnification. The tongue of the frog is also used for the same purpose. As the latter is attached to the anterior angle of the lower jaw, it may be conveniently drawn out, suitably stretched, and then placed over the hole in the cork plate. A very good view of the circulation may be obtained by examining the mesentery of a frog. The migration of the leucocytes through the vessel-walls can also be studied in such preparations. An incision 0.5 cm. in length is made in the right axillary line through the skin of a frog (best in the male), care being taken not to injure any vessels (which can be seen through the skin in frogs possessing little pigment). The abdominal muscles are then incised and a pair of forceps introduced to grasp one of the presenting intestinal loops. The latter is then attached to the cork plate with needles, and the mesentery carefully stretched over the opening. On examining the specimen it is best to moisten it with normal salt solution and to cover the area to be

examined with a fragment of a cover-glass. The lung may also be examined, but here the incision must be farther forward.

Counting Blood-cells.—The instrument now generally used for this purpose is the *Thoma-Zeiss hemocytometer*. This apparatus consists of two parts: pipettes by means of which the blood is diluted 100 times, when counting red, or 10 times when white blood-cells are to be counted, and a glass slide, on which there is a small well of known depth, the bottom of the well being divided off into small squares. The pipette used when counting the red cells consists of a capillary tube, near the middle of which there is an ampullar enlargement. This is so graduated that the cubical contents of the capillary tube is just one-hundredth part of the cubical contents of the ampulla. The blood to be examined is drawn into the capillary tube to a line marked 1 (just below the ampulla); the end of the pipette is then inserted into the diluting fluid, and this is sucked up until the diluted blood reaches a line marked 101 (just above

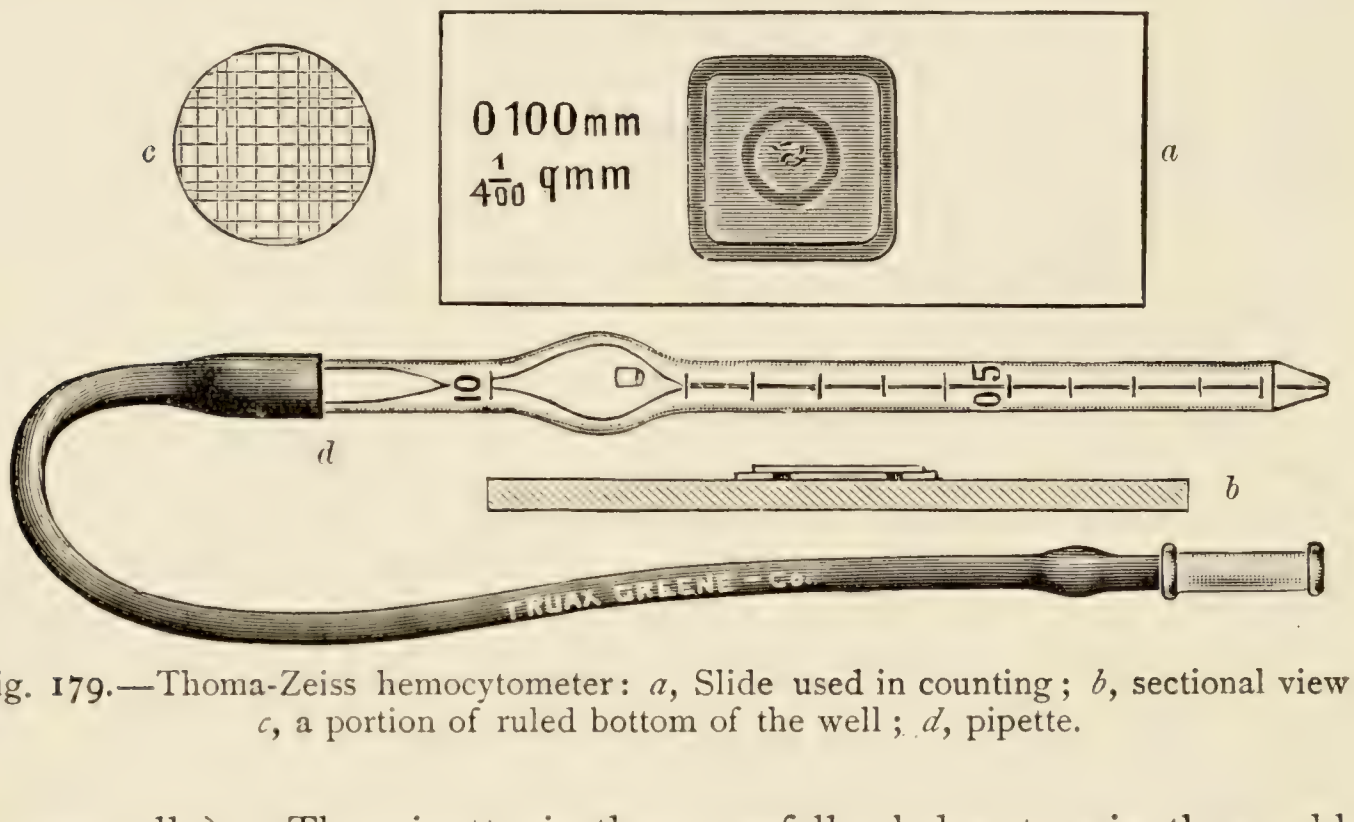

Fig. 179.—Thoma-Zeiss hemocytometer: *a*, Slide used in counting; *b*, sectional view; *c*, a portion of ruled bottom of the well; *d*, pipette.

the ampulla). The pipette is then carefully shaken to mix thoroughly the blood and the diluting fluid.

Either of the following two solutions may be used for diluting the blood:

Hayem's Solution:

Bichlorid of mercury	0.5 gm.
Sodium chlorid	1.0 gm.
Sodium sulphate	5.0 gm.
Distilled water	200.0 c.c.

Toison's Fluid (as given by V. Kahlden):

Methyl violet 5 B	0.025 gm.
Neutral glycerin	30.0 c.c.
Distilled water	80.0 c.c.

Mix the methyl violet with the glycerin and distilled water; to this solution is added—

Sodium chlorid (C. P.)	1.0 gm.
Sodium sulphate (C. P.)	8.0 gm.
Distilled water	80.0 c.c.

Filter, and the solution will be ready for use. The white blood-cells are stained violet, and may thus be counted with the red.

The diluting fluid contained in the capillary tube is then blown out, and a small drop of the diluted blood is placed on the center of the small glass disc. The small disc is surrounded by a ring of glass, cemented to the slide. This glass ring is 0.1 mm. thicker than the glass disc. When this small chamber is covered with a thick cover-glass, we have a layer of blood 0.1 mm. deep between the disc and the cover-glass. On the upper surface of the small glass disc (on which the drop of diluted blood was placed) there are marked off 400 small squares. The sides of the small squares are $\frac{1}{20}$ mm. long. It will be seen that the layer of blood over each of the squares would have a cubical contents of—

$$\frac{1}{4000} \text{ of a cubic millimeter } \left(\frac{1}{20} \times \frac{1}{20} \times \frac{1}{10} = \frac{1}{4000}\right).$$

The hemocytometer slide is now placed on the stage of the microscope, where it should remain undisturbed for several minutes before counting. The red blood-cells in 25 to 50 squares are then counted. To ascertain the number of red cells in a cubic millimeter the following formula may be useful :

$$\frac{4000 \left\{\begin{array}{l}\text{each mass of}\\ \text{blood counted,}\\ \frac{1}{4000}\text{ c.mm.}\end{array}\right\} \times \text{d} \left\{\begin{array}{l}\text{dilution,}\\ \text{here 100}\end{array}\right\} \times \text{n} \left\{\begin{array}{l}\text{red cells}\\ \text{counted}\end{array}\right\}}{\text{n (number of squares counted)}} = \left\{\begin{array}{l}\text{number of red}\\ \text{blood-cells in}\\ \text{1 c.mm.}\end{array}\right.$$

Or, ascertain the average of the red blood-cells in the squares counted, and multiply this number by 400,000.

In case it is desired to count only the white blood-corpuscles, a 1/3 per cent. solution of glacial acetic acid is used for diluting the blood. This solution bleaches the red cells, and brings out clearly the white corpuscles.

The blood is diluted only ten times, using for this purpose the Thoma-Zeiss pipette for counting white corpuscles. The formula then reads as follows :

$$\frac{4000 \times \text{d}(10) \times \text{n} \left\{\begin{array}{l}\text{the number of white}\\ \text{blood-corpuscles}\\ \text{counted.}\end{array}\right\}}{\text{n (number of squares counted).}} = \begin{array}{l}\text{the number of white}\\ \text{blood-cells found in}\\ \text{a cubic millimeter.}\end{array}$$

Or, multiply the average number of white corpuscles in each square by 40,000.

Lymph-glands.—To obtain a general idea of the structure of lymphatic glands, sections are made of small glands fixed in alcohol or corrosive sublimate. They are then stained with hematoxylin and eosin. In such preparations the cortical and medullary substances can be studied; the trabeculæ and blood take the eosin stain.

The flattened **endothelial cells** covering the trabeculæ are brought to view by injecting a 0.1% solution of silver nitrate into a fresh lymphatic gland. After half an hour the gland is fixed with alcohol and carried through in the regular way; the sections should be quite thick (not under 20 μ). After the sections have been mounted in Canada balsam and exposed to light for a short time, the endothelial mosaic will be seen wherever the silver nitrate has penetrated.

Fixing with Flemming's solution and staining with safranin is the best method for studying the germ centers of the lymph-follicles. Other fluids which bring out the mitoses may also be employed.

Reticular tissue is best demonstrated by sectioning a fresh gland with a freezing microtome, removing a section to a test-tube one-quarter filled with water, and agitating it. The lymphocytes are thus shaken out of the meshes of the reticulum, leaving the latter free for examination.

The same results can be obtained by placing a section prepared in the above-named manner upon a slide, wetting it with water, and carefully going over it with a camel's-hair brush. The lymphocytes adhere to the brush. Both methods (His, 61) may be applied to hardened sections which have lain in water for a day or so. In this case, however, the removal of the lymphocytes is not so easy as in fresh sections.

In thick sections the reticulum is hidden by the lymphocytes. If, on the other hand, very thin sections (not over 3 μ) be made, especially of objects fixed in Flemming's solution, the adenoid reticulum stands out clearly without any further manipulation.

The reticular structure may also be demonstrated by an artificial digestion of the sections with trypsin. The sections are then agitated in water, spread on a slide, dried, then moistened with a picric acid solution (1 gm. in 15 c.c. of alcohol and 30 c.c. of water), again dried, covered with a few drops of fuchsin S solution (fuchsin S 1 gm., alcohol 33 c.c., water 66 c.c.), and left to stand for half an hour. The fuchsin solution is then carefully removed, the section washed again for a short time in the same picric acid solution, then treated with absolute alcohol, xylol, and finally mounted in Canada balsam. The reticular tissue of both lymphatic glands and spleen are stained a beautiful red (F. P. Mall). (See also page 129.)

The treatment of splenic tissue is practically the same as that of the lymphatic glands.

In all these organs (lymph-glands, spleen, and bone-marrow) a certain amount of fluid may be obtained by scraping the surface of the fresh tissue. This may then be examined in the same manner as blood and lymph (see Technic of same). Sections of lymph-glands and spleen previously fixed in alcohol, mercuric chlorid, or even in Flemming's solution may be examined by the granula methods of Ehrlich.

By using the chrome-silver method a peculiar network of reticular fibers may be seen in the spleen. (Gitterfasern; Oppel, 91.)

The examination of the **bone-marrow** belongs also to this chapter. The marrow of the diaphysis is taken out by splitting the bone longitudinally with a chisel. With a little practice, it is easy to obtain small pieces of the marrow, which are then fixed by the customary methods and cut into sections. In the epiphysis the examination is confined either to the pressing out of a small quantity of fluid with a vice, or to the decalcification of small masses of spongy bone, containing red bone-marrow. In the first case, methods applicable to blood examination are employed; in the second, section methods (see also the petrification method, page 132) are used. The methods given for the preparation of lymph-glands and spleen are also applicable in many cases.

TECHNIC (CIRCULATORY SYSTEM).

To obtain a topographical view of the layers composing the heart and vessels, sections are made of tissues that have been fixed in Müller's fluid, chromic acid, etc. If the specimens are to be studied in detail, small pieces must be used, and are best fixed in chromic-osmic mixtures or corrosive sublimate. Celloidin imbedding is recommended for general topographic work. The further treatment is elective.

The endothelium of the intima may be brought to view by silver nitrate impregnation methods, by injecting silver solutions into the vascular system. The endothelial elements of the smallest vessels and capillaries are then clearly defined by lines of silver. Larger vessels must be cut open, the intima separated, and pieces of its lamellæ examined.

Elastic elements, plates and networks are best observed in the tunica media of the vessels, very small pieces of which are treated for some hours with 33% potassium hydrate.

The appropriate stains for sectionwork are those which bring out the elastic elements and the smooth muscle-cells. For the former, orcein is used.

For demonstrating the distribution of the capillaries, the reader is referred to the injection methods. The lymph-capillaries are injected by puncture; compare also the methods of Altmann.

III. THE DIGESTIVE ORGANS.

The intestinal canal with the glands derived therefrom originates from the inner layer of the blastoderm, the entoderm. The latter, however, does not extend to the external openings of the body, as the ectoderm forms depressions at these points which grow inward toward the still imperforate fore and hind gut to communicate finally with its lumen. This applies as well to the formation of the primitive oral cavity, which is separated only secondarily into oral and nasal cavities, as to the anus. The anterior boundary between the ectodermal and entodermal portions of the digestive tube consists of a plane passing through the opening of the posterior nares and continued downward along the palatopharyngeal arch. Everything lying anterior to this is of ectodermal origin, therefore the entire oral and nasal cavities with their derivatives. The lining of these cavities consists, however, of a true mucous membrane, closely resembling in its structure that of the intestinal tract.

A. THE ORAL CAVITY.

The epithelium of the oral mucous membrane is of the stratified squamous type, differing from the epithelium of the epidermis in that the stratum granulosum does not appear here as an independent layer. The stratum lucidum is also wanting, and the

cornification of the layer analogous to the stratum corneum of the skin is not complete (compare Skin). In the mucous membrane the cells of even the most superficial layers contain nuclei, which, although partly atrophied, still show chromatin, and as a consequence are easily demonstrated.

Beneath the epithelium lies a tissue of mesodermic origin, also belonging to the mucous membrane and known as the *mucosa* or *stratum proprium* (lamina propria, tunica propria), in which numerous glands are situated. The mucosa consists of a fibrillar connective tissue with few elastic fibers, and of adenoid tissue containing numerous lymphoid cells; essentially, therefore, a diffusely distributed adenoid tissue with occasional lymph-follicles imbedded in its substance. The mucosa presents numerous papillæ, which are either simple or compound (branched) elevations of the mucosa, varying in length and density, according to their location and extending for variable distances into the overlying epithelium. As in the papillary layer of the corium (see Skin), so also here the superficial layer of the stratum proprium contains very fine elastic and connective-tissue elements which contribute to the structure of the papillæ. All these papillæ contain capillaries and arterioles which are derived from an arterial network in the mucosa. The lymphatics are similarly arranged.

At the red margin of the lips the papillæ are unusually high and are covered at their summits by a very thin epithelial layer (Fig. 180). Besides the sebaceous glands which lie at the angles of the mouth, and whose ducts open at the surface, there are here no other glandular structures. In the mucosa of the mucous membrane of the lips and cheeks the papillæ are low and broad; here also open the ducts of compound lobular, alveolar glands, the *glandulæ labiales* and *buccales* whose structure is similar to that of the large salivary glands (see these). The gums possess very long and attenuated papillæ, covered by a very thin layer of epithelium, therefore bleeding at the slightest injury. That part of the gum covering the tooth has no papillæ. The gums contain no glands. The papillæ of the hard palate are arranged obliquely, with their points directed toward the opening of the mouth. The papillæ of the soft palate are very low and may even be absent. They are somewhat higher on the anterior surface of the uvula. On the posterior surface of the latter occur ciliated epithelia distributed in islands between the areas of stratified squamous epithelium. In the soft palate and uvula are found small mucous glands.

Under the mucous membrane there is a layer consisting principally of connective tissue and elastic fibers, the *submucosa* (stratum submucosum, tela submucosa). In the mucous membrane of the mouth the transition of the tissue of the mucosa into that of the submucosa is very gradual. The submucosa of the hard palate is closely connected with the periosteum and contains, especially at its posterior portion, numerous glands. In other regions of the

mouth (lip) the glands extend also into the submucosa. The mucosa and epithelium lining the mouth cavity are richly supplied with nerves which terminate either in special sensory nerve-endings or in free sensory nerve-endings, or on the blood-vessels. In the papillæ of the mucosa are found corpuscles of Krause. (See p. 169.) The nerves terminating in free sensory endings are the dendrites of sensory neurones (medullated sensory nerves), which, while yet medullated, branch and form plexuses with large meshes, situated in the submucosa and deeper portion of

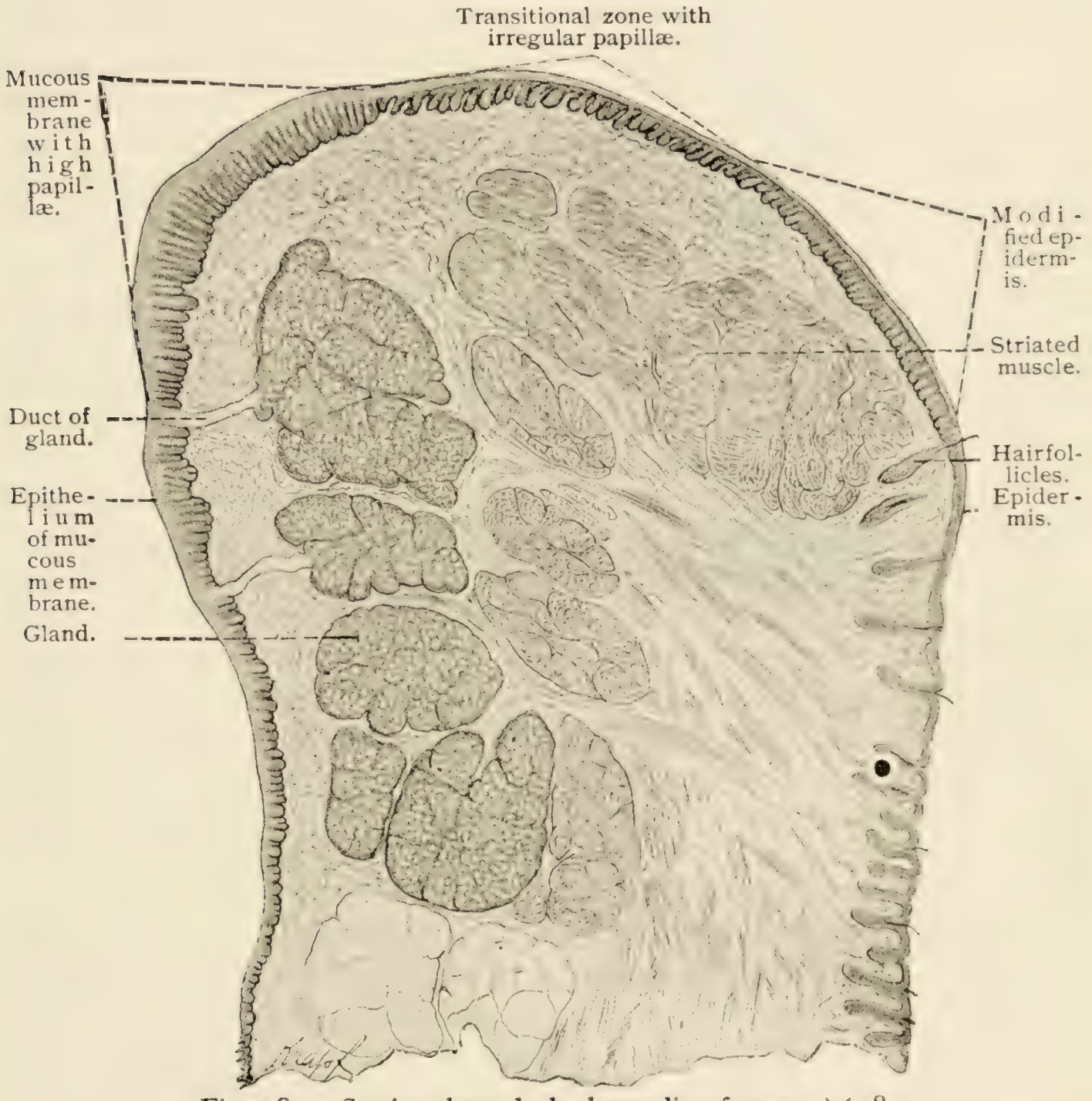

Fig. 180.—Section through the lower lip of man; × 18.

the mucosa. The medullated branches of the nerve-fibers constituting these plexuses proceed toward the epithelium, dividing further in their course. Immediately under the epithelium the medullated branches lose their medullary sheaths, divide further, and form the subepithelial plexuses. The nonmedullated branches enter the epithelium, where they form telodendria (end-brushes), the terminal branches of which surround the epithelial cells, between which they end either in very fine granules or in small groups of such, or, again, in variously shaped end-discs. (See Fig. 135.) The blood-

vessels are richly supplied with vasomotor nerves, the neuraxes of sympathetic neurones, which terminate on the muscle-cells of the vessels. In the adventitia are also found free sensory nerve-endings. (See Fig. 177.)

1. THE TEETH.

The human dentition comprises twenty temporary or milk teeth, namely, above and below, four incisors, two canines, and four molars, which are replaced by thirty-two permanent teeth, consisting of four incisors, two canines, four premolars, and six molars for each jaw. Each tooth consists of a crown, which projects above the gums, a relatively short and narrowed portion known as the neck, and a portion which fits accurately into the alveolus and is known as the root. For the variations in shape which the different kinds of teeth present, the reader is referred to the text-books of anatomy or to special works dealing with this subject.

Structure of the Adult Tooth.—The adult tooth is made up of three substances—the enamel, the dentin, and the cementum. The latter covers that part of the tooth within the alveolar process of the jaw and also the root of the tooth. The enamel caps that part of the tooth projecting into the oral cavity, the crown of the tooth. The neck of the tooth is the region where the cementum and enamel come in contact. The greater part of the tooth consists of dentin, which is present in the crown as well as in the root. All the substances of the tooth just mentioned become very hard from the deposition of lime-salts. Every tooth contains a cavity surrounded by dentin, the pulp cavity, or dental cavity. This is filled with a soft tissue, the pulp, consisting of white fibrous tissue, vessels, and nerves. That part of the pulp cavity lying in the axis of the fang is called the root-canal; by an opening in the latter (foramen apicis dentis) the pulp is connected with the periosteal connective tissue of the dental alveolus.

The **enamel** is a very hard substance, the hardest in the body, and may be compared to quartz. In uninjured teeth the enamel is covered by an exceedingly thin, structureless membrane, the cuticula dentis or Nasmyth's membrane, which varies in thickness, measuring from 0.9 μ to 1.8 μ. It is very resistant to acids and alkalies. On its under surface it often shows small pits, into which project the ends of the enamel prisms. The enamel contains very little organic substance (from 3 % to 5 %), in consequence of which it is soluble in acids with scarcely any residue. The elements composing it are prismatic columns, the *enamel prisms*, which probably occupy the whole thickness of the enamel from the superficial membrane to the dentin. They are slightly thicker at the surface of the tooth than at the dentin, and in transverse section show a hexagonal or polygonal shape, and measure from 3 μ to 6 μ in diameter. They often show quite regular

transverse markings which express, however, no structural peculiarity, but are due to irregularities in the prisms. They are joined to each other by a cement-substance which is somewhat more resistant than the substance of the prisms themselves. In the adult they are entirely homogeneous, but in embryos and even in the new-born they show a (fibrillar) longitudinal striation. In their course through the thickness of the enamel they change their direction by a series of symmetrical curves, and cross each other in groups in a typical manner. There are also seen in the enamel the parallel lines known as the *lines of Retzius* (see Fig. 181), which pass obliquely through the enamel and which are to be regarded as traces of the strata caused by the periodic deposition of lime-salts; they are very variable, as their structure depends on the nutritive condition during the deposition of the lime-salts (Berten). Another series of parallel or nearly parallel stripes or lines, known as *Schräger's lines*, are also observed. Those in the lateral portions of the enamel have a direction nearly perpendicular to the surface. They are thought to be due to a difference in the refraction of the light, presented by bundles or layers of enamel prisms so disposed as to be cut in different directions.

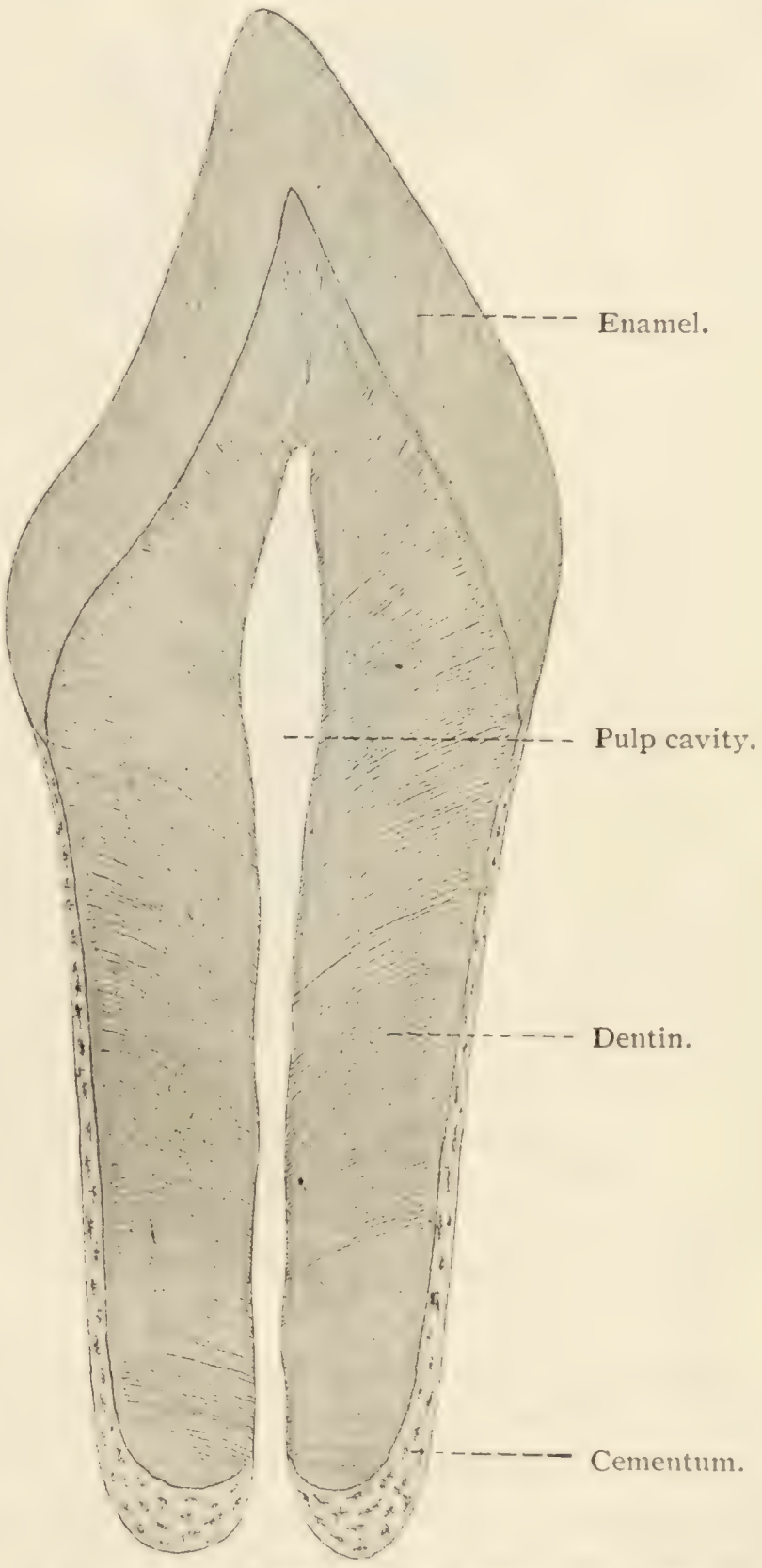

Fig. 181.—Scheme of a longitudinal section through a human tooth. In the enamel are seen the "lines of Retzius."

The **dentin** is, next to the enamel, the hardest tissue of the tooth. After decalcification it presents a ground substance in which are found numerous very fine fibrils, which do not branch nor anastomose, and are in their behavior toward acids and alkalies like the fibrils of white fibrous (collagenous) tissue. They yield gelatin on boiling. The fibrils are separated by

an interfibrillar substance, in which the mineral salts are deposited. The course of the fibrils is, in the main, parallel to the surface of the dentin. They are often grouped in small bundles (v. Ebner). The dentin is permeated by a system of canals having usually a transverse direction, the so-called *dentinal tubules*, which are from 1.3 μ to 4.5 μ in diameter. These originate in the pulp cavity, and during their course become slightly curved, like the letter S. The dentinal tubules usually present several dichotomous divisions near their origin, then pass to the outer third of the dentin without conspicuous divisions; here they again branch, becoming constantly smaller. In their course they give off numerous side twigs which

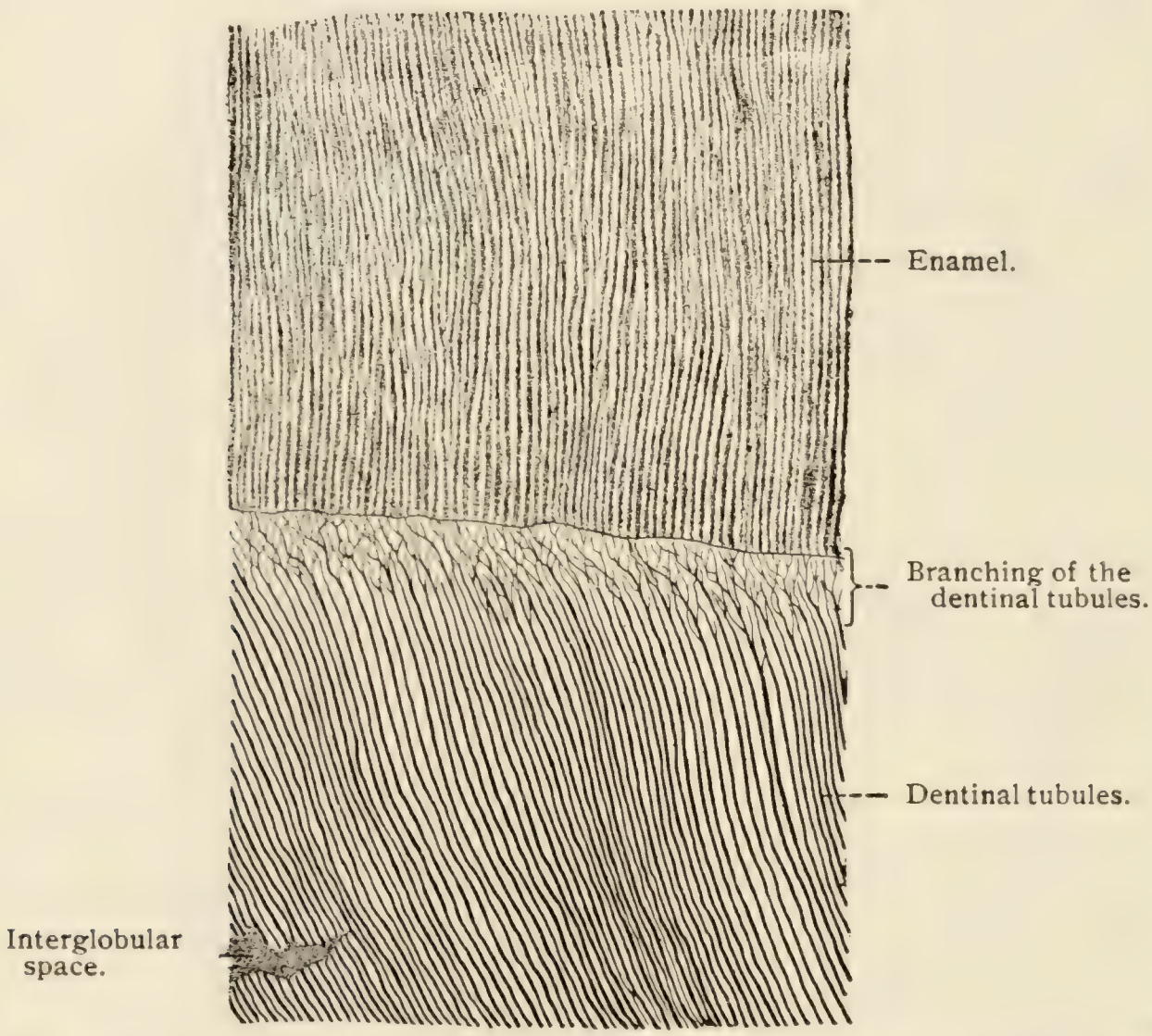

Fig. 182.—A portion of a ground tooth from man, showing enamel and dentin; × 170.

anastomose with those of neighboring tubules. The general course of these tubules is shown in figure 181. Certain of the tubules pass for a short distance into the enamel, where they are found between the prisms. In the human tooth the majority end just before reaching the enamel. In the root of the tooth they end near the surface, or in the interglobular spaces (see below), or, again, they may be joined to form loops. The dentinal tubules possess sheaths, the sheaths of Neumann, which may be isolated, analogous to the sheaths of the canaliculi of bone. They may be regarded as differentiated and more resistant ground substance. The dentinal tubules contain throughout their entire length filiform prolongations of certain pulp-cells (odontoblasts), the *dentinal fibers*. Peculiar, irregu-

larly branched spaces are often seen in the dentin. These are the *interglobular spaces* of Czermak. They represent areas in which calcification has not taken place. Their number is variable; when relatively small and numerous, they appear, in dry preparations seen under low magnification, as a granular layer—the granular layer of Tomes.

The **cementum** is closely adherent to the dentin, and consists of

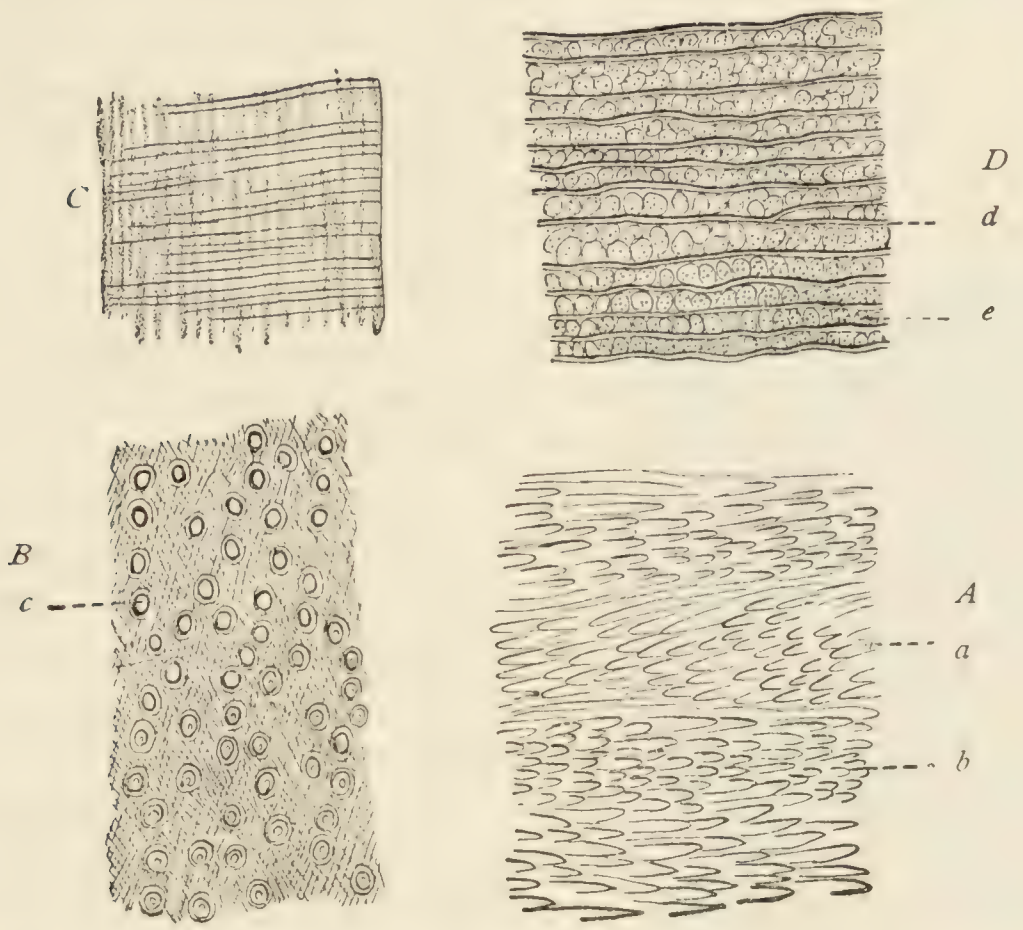

Fig. 183.—*A*, Longitudinal section through a human molar from the center of the enamel layer, decalcified with dilute hydrochloric acid; *B*, tangential, *C*, radiate, and *D*, transverse section through the dentin of a human tooth, showing the fibrillar structure of the ground-substance (taken from v. Ebner, 91): *a* and *b*, Two layers in which the direction of the enamel prisms changes; in *c* is seen a dentinal fiber with its sheath; *e*, groups of fibrils; *d*, dentinal tubules.

bone tissue, the parallel lamellæ of which contain, as a rule, no Haversian canals. There occur, however, cement lamellæ, which in places lose their bone-cells. A peculiarity of the cementum is the presence of a large number of Sharpey's fibers, which are especially abundant in those areas containing no bone-corpuscles. These fibers are usually found in an uncalcified condition.

The **tooth-pulp** is a tissue resembling embryonic connective tissue, consisting of connective-tissue fibrils, branched connective-tissue cells, and a semifluid, interfibrillar ground-substance. It is characteristic of this tissue that the fibrils never join to form connective-tissue fibers. It is probable that the fibrils are similar to those of white fibrous (collagenous) connective tissue (possibly reticular fibers), although there is a difference of opinion as concerns this point, by observers who have given it special attention (see v. Ebner, Röse). At the surface of the pulp is a continuous layer of cells, the *odontoblasts*. These are columnar cells with basal

nuclei and two or three processes extending into the canaliculi of the dentin, forming here the dentinal fibers already described. As a rule, the odontoblasts also send a single fiber into the pulp. These may intertwine and give rise to a network within its substance.

Peridental Membrane, Alveolar Periosteum.—The tooth is joined to the alveolus by a fibrous tissue membrane, the peridental membrane or alveolar periosteum, which represents the periosteum of the alveolus and the cementum of the tooth. This consists of bundles of connective tissue (elastic fibers are here absent) directly continuous with Sharpey's fibers in the cementum and the alveolus. Between these coarser bundles of fibers, which have a direction nearly horizontal in the upper portions of the peridental membrane and incline toward the lower end of the tooth in its lower portion, there is found a looser connective tissue, containing numerous nerve-fibers, blood-vessels, and peculiar masses of epithelial cells representing the remains of the enamel organs, to be described later. These epithelial remains have by some observers been regarded as glandular in nature; further observation is, however, needed before this can be accepted as proved. At the apex of the root there is found a less dense connective tissue, continuous with that of the tooth pulp. At the neck of the tooth the peridental membrane disappears in the submucosa of the gum.

The *blood-vessels* of the teeth have been fully described by Lepowsky, who has studied them in a number of mammals, and in man in embryos and in full development; his account is here followed. The artery, accompanied by the veins, enters through the apical foramen, passes up through the pulp, dividing into branches as it reaches the upper portion of the pulp cavity; these branches are spread out fan-shaped and after further division and the formation of capillaries, end in capillaries which are situated between the layer of odontoblasts and the dentin, forming here a capillary plexus which presents narrow meshes, in regions where the odontoblasts are most active.

There are in all probability no lymphatic vessels in the pulp.

Numerous *medullated nerve-fibers* (dendrites of sensory neurones) enter the pulp cavity through the apical foramen. Some of these lose their medullary sheaths soon after entering, or just before entering, the pulp, and divide into long, fine, varicose fibers which interlace to form a loose plexus under the odontoblasts. Other medullated fibers, grouped into small bundles, ascend in the pulp for variable distances; the nerve-fibers of the bundles then separate and as single fibers approach the superficial portion of the pulp, and, after losing their medullary sheaths, divide into fine varicose fibers forming under the odontoblasts a plexus continuous with the plexus above mentioned. From the varicose nerve-fibers

of this plexus small terminal branches are given off which terminate between the odontoblasts, or pass through the layer of odontoblasts, to end between these and the dentin (Retzius, 94; Huber, 98; Rygge, 1902). Medullated nerve-fibers also terminate in free endings in the peridental membrane.

Development of the Teeth.—In the second month of fetal life the first traces of the teeth are seen in the development of a groove along the inner edge of the fetal jaw, the dentinal or enamel groove. From the floor of the latter an epithelial ridge is formed constituting the anlage of the enamel organs and known as the dentinal ridge, or enamel ledge. At those points at which the milk-teeth later appear, the enamel ledge develops solid protuberances corresponding in number to the temporary teeth. These are known as the dentinal bulbs or *enamel germs*. In their first stage of development the enamel germs are knob-like, but later their bases spread, and they become flattened and finally cup-shaped by the pushing up into them of connective-tissue projections, the *dentinal papillæ*. At the same time they gradually sink deeper into the underlying tissue, but still remain connected, by means of a thin cord, with the epithelium of the enamel ledge, which now lies on the inner side of the enamel germs. The enamel germs now differentiate into enamel organs. In this stage they consist of an outer layer of columnar epithelial cells, which are to be regarded as a direct continuation of the basal cells from the epithelium of the oral mucous membrane, or still better, of the enamel ledge; the epithelium in the interior of the organ is derived from the stratum Malpighii of the oral epithelium. The cells of this layer, however, undergo a change in shape and structure, in that an increased quantity of lymph-plasma or intercellular substance collects in the interspinous spaces between the cells, pushing the cells apart, and allowing their processes to develop until the cells finally assume a stellate shape. In this way the enamel pulp is gradually formed. The next stage is characterized by a vertical growth of the dentinal papillæ, which soon become surrounded on all sides by the cap-like enamel organs. The cylindric cells (enamel cells) of the enamel organs lying next to

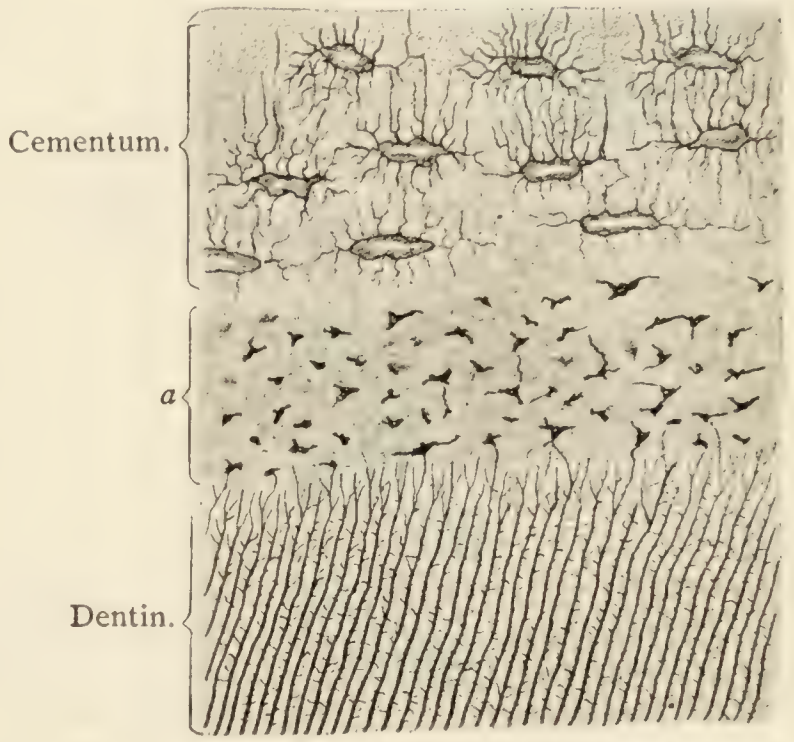

Fig. 184.—Cross-section of human tooth, showing cement and dentin; × 212. At *a* are seen small interglobular spaces (Tomes' granular layer).

the papillæ become lengthened, and after passing through further changes, finally develop into the enamel prisms of the teeth. At the periphery of the dentinal papillæ, there is differentiated a layer of columnar cells, the *odontoblasts*, which have a connective-tissue origin, and later form the dentin. During these processes a connective-tissue mantle, the *dental sac*, rich in cellular and fibrous elements, is formed around each tooth anlage.

The earliest appearance of the enamel is in the form of a cuticular membrane, developed from the ends of the enamel cells resting on the dentinal papilla, this cuticular membrane appearing in the form of a thin layer covering the top of the dentinal papilla. Some time later, short striated processes—*Tomes' processes*—appear on the

Fig. 185.—Nerve termination in the pulp of a rabbit's molar, stained in methylene-blue (*intra vitam*) : *a*, Odontoblasts seen in side view ; *b*, a number of odontoblasts seen in end view, showing a terminal branch of a nerve-fiber situated between the odontoblasts and the dentin (Huber, "Dental Cosmos," October, 1898).

lower end of each of the enamel cells (the end toward the dentinal papilla). These are imbedded in a cement-substance, forming a continuous layer. The Tomes' processes are regarded as the beginnings of the enamel prisms. Calcification begins in the middle of these processes ; they thicken at the expense of the cement-substance surrounding them, which later also calcifies. The enamel as a whole thickens by the elongation of the Tomes' processes of the enamel cells and by their subsequent calcification. The process ends finally in the death and partial absorption of the enamel cells and the remaining elements of the enamel organs ; these structures persist for a short time after the eruption of the tooth as a cuticular sheath.

The dentin is developed by the odontoblasts by a process analogous to that observed in the formation of bone by the osteoblasts. These epithelioid cells secrete at their outer surfaces a homogeneous substance which fuses to form a continuous layer, the *membrana præformativa*. The further development of the dentin is as follows : Its ground-substance is deposited at the cost of the lateral portions of the odontoblasts (under the membrana præforma-

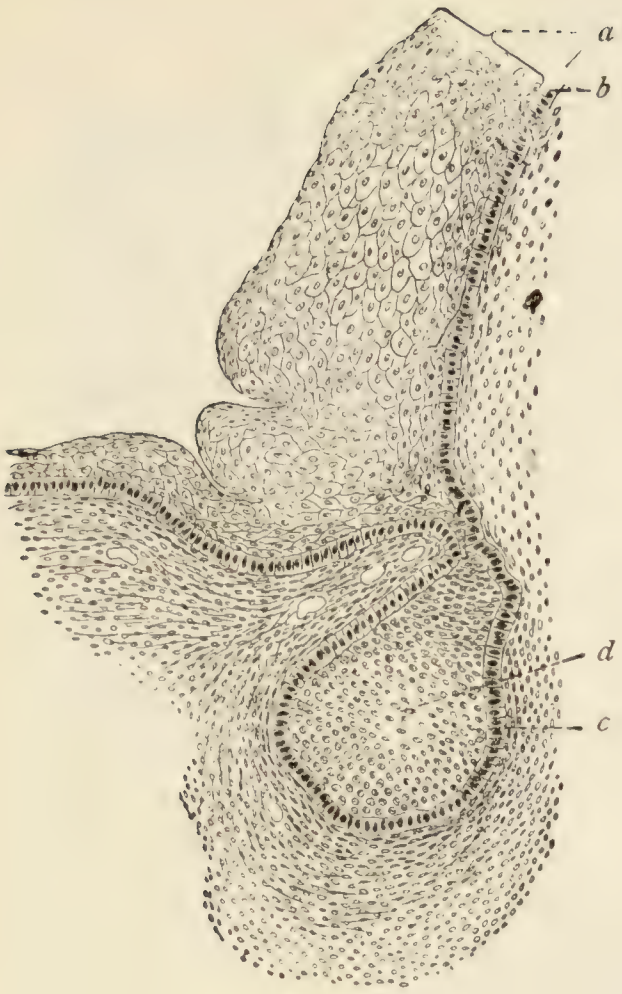

Fig. 186.

Fig. 187.

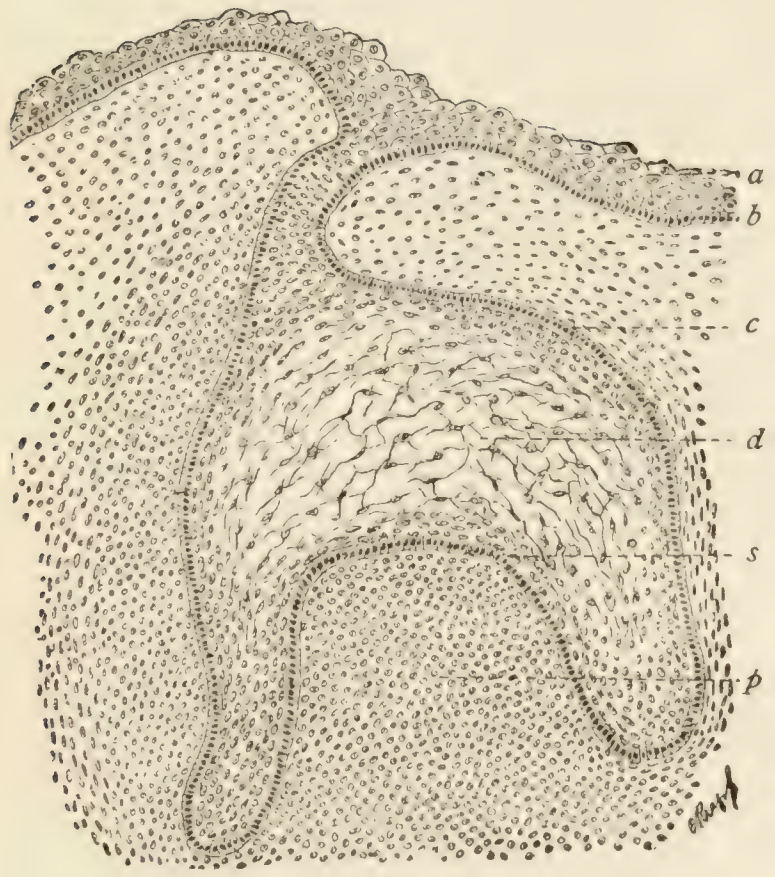

Fig. 188.

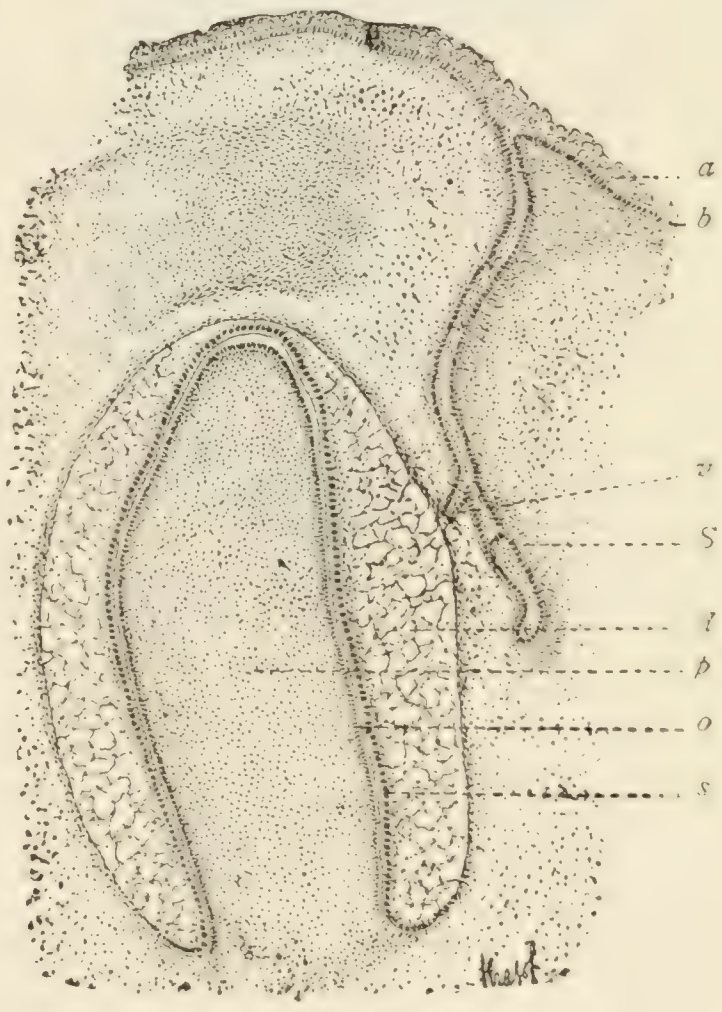

Fig. 189.

Figs. 186–189.—Four stages in the development of a tooth in a sheep embryo (from the lower jaw); Fig. 186, Anlage of the enamel germ connected with the oral epithelium by the enamel ledge; Fig. 187, first trace of the dentinal papilla; Fig. 188, advanced stage with larger papilla and differentiating enamel pulp; Fig. 189, budding from the enamel ledge of the anlage of the enamel germ, which later goes to form the enamel of a permanent tooth; at the periphery of the papilla the odontoblasts are beginning to differentiate. Figs. 186, 187, and 188, × 110; Fig. 189, × 40. *a*, *a*, *a*, *a*, Epithelium of the oral cavity; *b*, *b*, *b*, *b*, its basal layer; *c*, *c*, *c*, the superficial cells of the enamel organ; *d*, *d*, *d*, *d*, enamel pulp; *p*, *p*, *p*, dentinal papilla; *s*, *s*, enamel-forming elements (enamel cells); *o*, odontoblasts; *S*, enamel germ of the permanent tooth; *v*, part of the enamel ledge of a temporary tooth; *u*, surrounding connective tissue.

tiva), the axial portion of the cells remaining intact as the dentinal fibers; the basal portions of the cells containing the nuclei persist, later constituting the odontoblasts of the adult pulp. By the fusion of the segments of the ground-substance formed by each cell, it becomes a homogeneous mass, but soon displays connective-tissue fibrils which gradually undergo a process of calcification. The membrana præformativa has no fibers and calcifies much later. It lies immediately beneath the enamel or the cementum, and in the normal tooth always contains small interglobular spaces. In the adult tooth this membrane in its entirety is known as *Tomes' granular layer.*

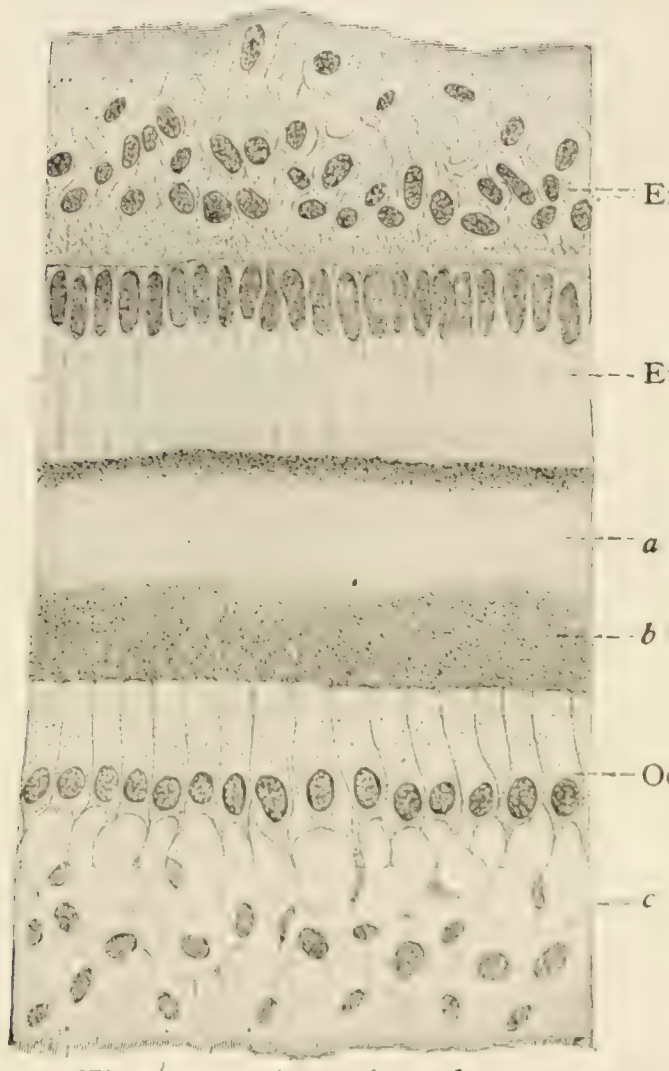

Fig. 190.—A portion of a cross-section through a developing tooth (later stage than in Fig. 189); × 720: The dentin is formed, but has become homogeneous from calcification. Bleu de Lyon differentiates it into zones (*a* and *b*). At *c* is seen the intimate relationship of the odontoblasts to the tissue of the dental pulp.

The *cementum* is merely a periosteal growth of bone originating in the tissue of the dental sac and adhering to the dentin. Although at first the enamel organ almost entirely surrounds the dentinal papilla, later a portion of that part of it in the region of the fang is absorbed in order to allow the cementum to reach the surface of the dentin. Remains of this regressive portion persist as the epithelial nests of the dental root (compare p. 242).

The contents of the dentinal papillæ change into the tissue of the dental pulp.

As early as the third month outgrowths appear on the inner side of the enamel ledge next to the partly developed milk-teeth, which represent the anlagen of the enamel organs of the permanent teeth. Their further development is similar to that of the milk teeth. The enamel organs of the molars are also developed from an enamel ledge which is practically a backward continuation of the embryonic enamel ledge. With their crowns presenting, the temporary teeth at last break through the epithelium of the gums. When the development of the permanent teeth is so far advanced that they are ready to perforate, regressive processes begin at the roots of the

milk-teeth, which are due, as in like conditions of the bone, to the action of certain cells, which are here known as "odontoclasts." The crowns of the milk-teeth are then thrown off, one by one, by the growing permanent teeth.

For further information as to the teeth and their development, see the articles by v. Ebner (Scheff's "Handbuch der Zahnheilkunde" and in Kölliker's "Handbuch der Gewebelehre," Bd. iii), whose studies we have to a great extent followed on this subject.

2. THE TONGUE.

The Lingual Mucous Membrane and its Papillæ.—The mucous membrane of the tongue differs in general very little from

Fig. 191.—Fungiform papilla from human tongue.

that lining the rest of the oral cavity. It must, however, be borne in mind that in the greater part of the tongue the submucosa is poorly developed, and as a consequence the mucous membrane on the upper surface and base of the tongue is scarcely movable. Other peculiarities of the lingual mucous membrane are the absence of glands in the mucosa on the upper surface of the tongue,—although glands are found in the musculature of the tongue, their ducts passing through the mucosa,—the presence of epithelial papillæ, and of lymph-follicles at the base of the tongue.

The upper surface of the tongue is roughened by the presence of epithelial projections, the *lingual papillæ*. The latter are almost entirely epithelial structures, and should not be confused with those papillæ which are composed exclusively of connective tissue. There

are several classes of lingual papillæ—the filiform, the fungiform, and the circumvallate papillæ. The most numerous are the thread-like or *filiform papillæ* (from 0.7 to 3 mm. long). These are scattered over the entire upper surface of the tongue, and consist of conic projections of the epithelium and of the mucosa. The connective-tissue portions of these papillæ are very thin and long. The basal layers of the epithelium can not be distinguished from the same layers covering the surrounding mucosa, but the more super-

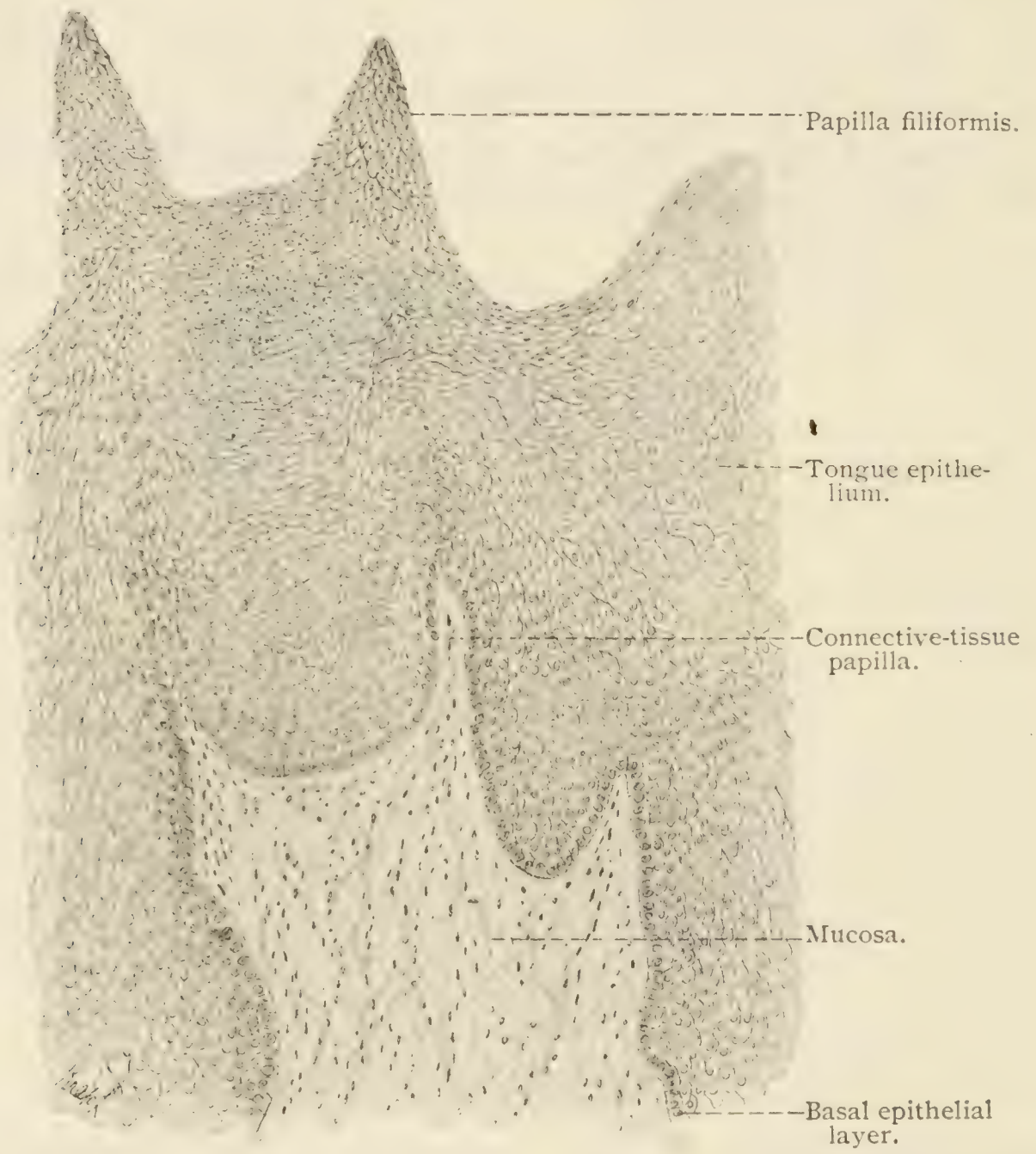

Fig. 192.—From a cross-section of the human tongue, showing short, thread-like papillæ (filiform) ; × 140.

ficial layers are differentiated, in that their cells are arranged parallel to the long axes of the papillæ and overlap each other like tiles (Fig. 192). Their free ends are often continued into several spine-like processes. Less numerous than the filiform are the *fungiform papillæ* (from 0.7 to 1.8 mm. in height) scattered here and there between the former. They are nearly hemispheric in shape, and are joined to the surface of the tongue by a slightly constricted base. At times they are even partly sunk into the mucous membrane. The mucosa is raised under the epithelium to form connective-tissue papillæ (Fig. 191). On the free surface of the fungiform papillæ

are sometimes found taste-buds, or taste-goblets, which lie imbedded in the epithelium and extend through its entire thickness. The *circumvallate papillæ* occupy a definite region on the upper surface of the tongue, and are arranged in two rows, forming almost a right angle, with the apex directed backward and situated just in front of the foramen cæcum (Morgagni). These papillæ are few in number, about eight to fifteen in all. In shape they are similar to those of the fungiform type, but are much larger (about 1 or 2 mm. in diameter), and sunk so deeply into the mucous membrane that the latter forms a wall around their sides. Here also the mucosa passes up into the papillæ and forms connective-tissue papillæ of its own at the upper surface, while at the sides it merely adheres to the smooth inner surface of the epithelial layer. Taste-buds are found in the epithelium at the sides of the papillæ, and also in that of the ridges surrounding the papillæ. At the sides of the human tongue and near its base are the so-called *fimbriæ linguæ*. These are irregular folds of mucous membrane,

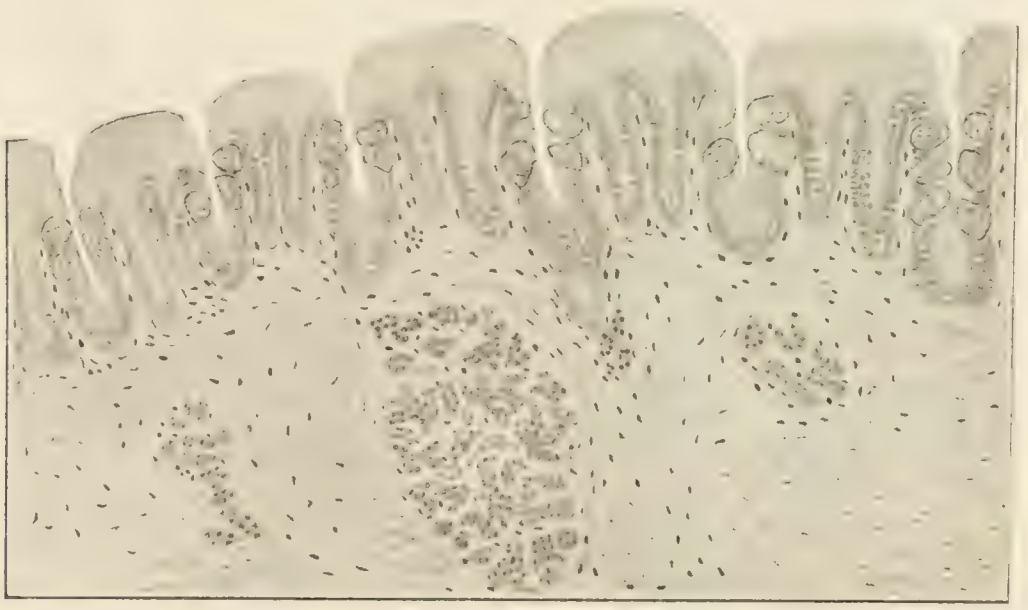

Fig. 193.—Longitudinal section of foliate papilla of rabbit, showing taste-buds.

the sides of which also contain taste-buds. In the rabbit they are more regular in structure and consist of parallel folds of mucous membrane thickly dotted with taste-buds, and are termed the *foliate papillæ*. In place of the circumvallate papillæ, the guinea-pig possesses structures similar to the foliate papillæ of the rabbit.

Into the depressions in which the circumvallate papillæ lie and into those between the folds of the fimbriæ linguæ open the ducts of numerous serous glands, the glands of v. Ebner (see below).

The Taste-buds.—The gustatory organs in the form of *taste-buds* are found on the surface of the tongue, principally on the lateral surfaces of the circumvallate papillæ and the fimbriæ linguæ (foliate papillæ). They are also occasionally met with in the epithelium of the fungiform papillæ and the soft palate, and on the posterior surface of the epiglottis. They always lie imbedded in the epithelium and extend through its entire thickness ; they are ovoid in form, with base downward and the smaller pole at the

surface. The whole structure is surrounded by the epithelium of the mucous membrane of the regions in which they occur, except at the attenuated outer end of the taste-bud, where, by means of a small opening, the *taste-pore*, it communicates with the oral cavity. Most of the cells constituting the taste-buds are elongated, spindle-shaped structures, extending from one end of the organ to the other, with spaces between them. There are four varieties of these cells : (1) The *outer sustentacular* or tegmental cells, lying at the periphery of the organ with a nucleus in their center, and having a short, cone-shaped cuticular projection ; (2) the *inner sustentacular* or rod-shaped cells, which are more slender structures with basally situated nuclei and without a cuticular projection ; between the latter are (3) elongated, spindle-shaped, neuro-epithe-

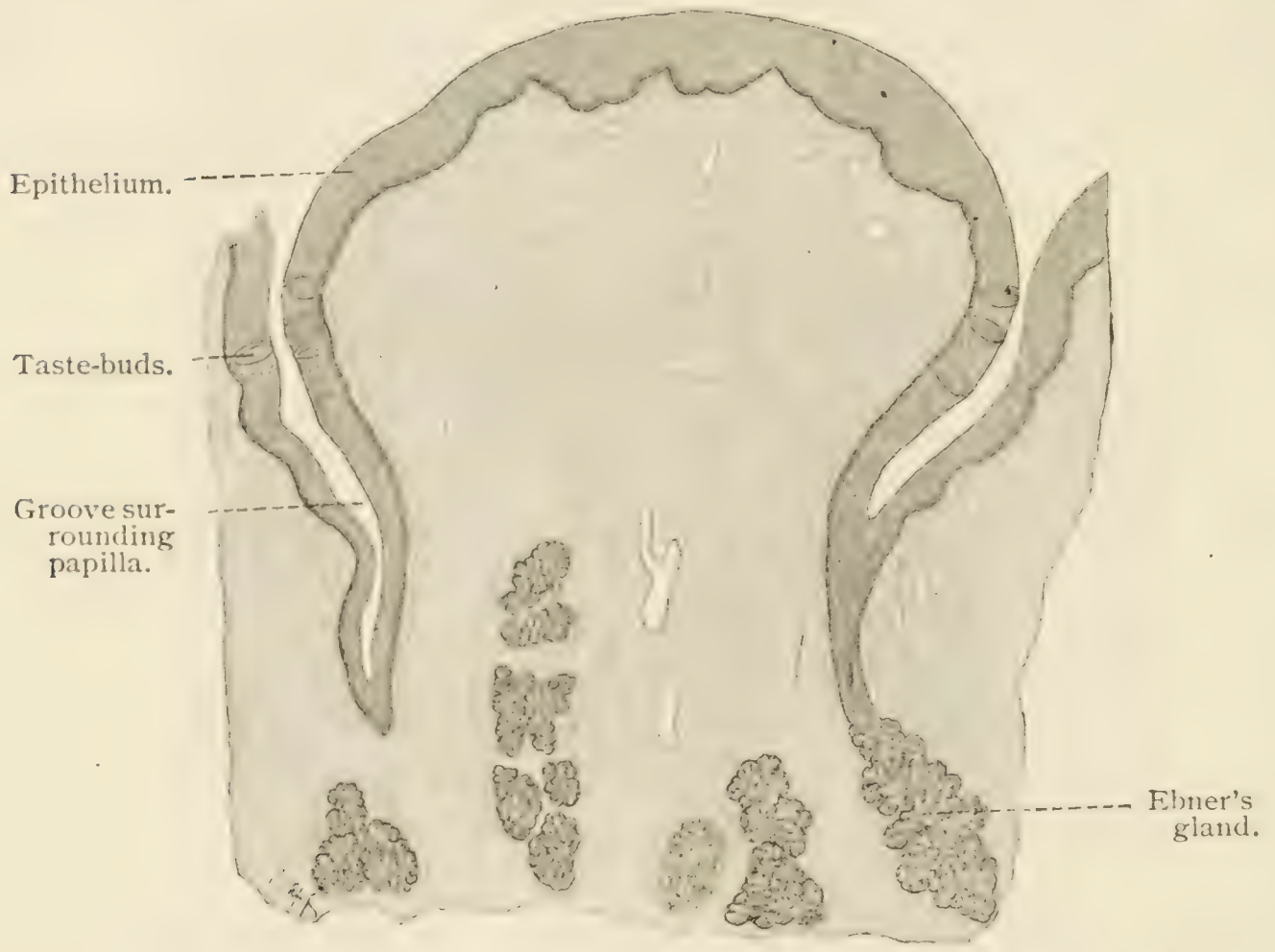

Fig. 194.—Longitudinal section of a human circumvallate papilla ; × 20.

lial cells, with the nucleus of each in the thickest portion of the cell, and with slender, stiff processes projecting into the taste-pore ; (4) a few broad basal cells, communicating with each other as well as with the sustentacular cells by numerous processes. We have, therefore, in the cells of the first, second, and probably fourth varieties, elements which belong exclusively to the sustentacular apparatus of the organ (Hermann, 85, 88).

Von Ebner found in the taste-buds of the circumvallate papillæ of man, monkey, and cat, as well as of the papillæ foliatæ of the rabbit, an open space situated between the taste-pore and the tip of the taste-bud (Fig. 195). These spaces vary according to the species, and are bounded above by the summits of the tegmental cells and laterally and below by the more centrally situated sus-

tentacular cells. The cavities are often 10 μ in depth, and are filled with a fluid apparently in communication with the fluid of the depression into which the circumvallate papillæ are sunk. The processes of the neuro-epithelial cells project into the cavity from its floor and lateral walls, but do not extend as far as the taste-pore.

The circumvallate papillæ are differentiated from the adjacent surface of the tongue by the development of a solid encircling epithelial ridge. Numerous taste-buds appear on the surface quite early in the history of the embryo. These, however, disappear completely when the permanent taste-buds develop from the basal cells of the epithelial ridge. Similar phenomena occur in the fungiform papillæ (Hermann, 88).

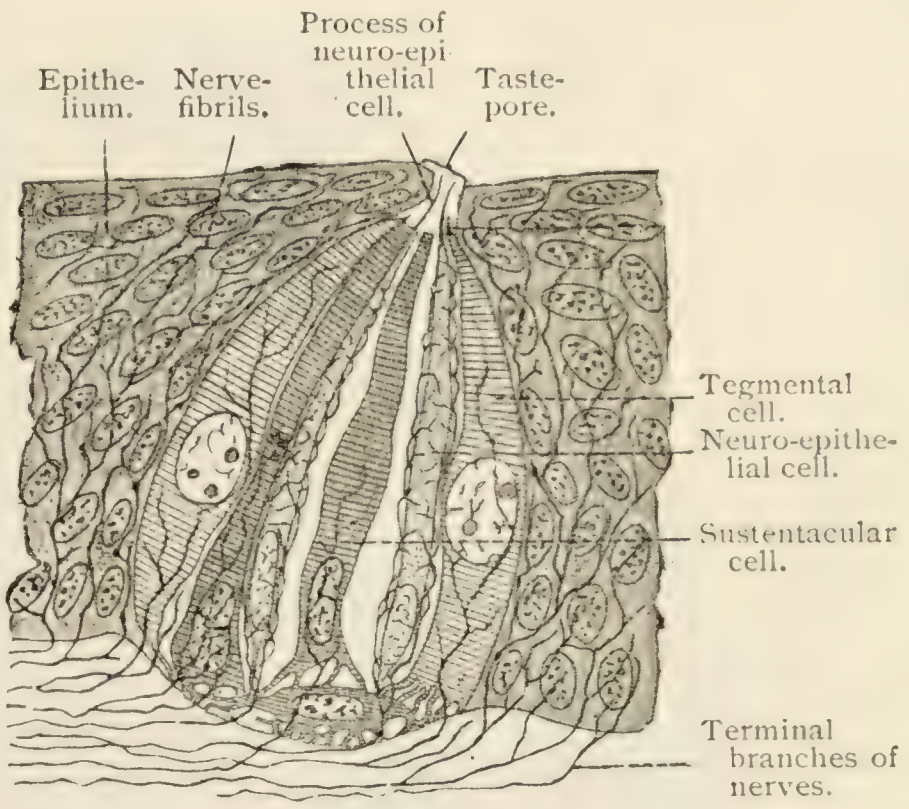

Fig. 195.—Schematic representation of a taste-goblet (partly after Hermann, 88).

The neural epithelia of the taste-goblets were formerly regarded as directly connected with the nerve-fibers by means of long processes, but the latest researches have shown that dendrites of sensory neurones (sensory nerves) enter the taste-buds and end free in telodendria. The latter surround the neuro-epithelial and, to some extent, the sustentacular cells, their relations depending upon contact.

The Lymph-follicles of the Tongue (Folliculi linguales) and the Tonsils.—At the root of the tongue, and especially at its sides, are numerous elevations due to the increased quantity of lymphoid tissue found in the mucosa of these regions, the lingual tonsils, or lingual follicles. In the center of each follicle is a cavity communicating with the exterior and caused by an invagination of the epithelium. The lymphoid tissue contains a number of more or less distinctly defined lymph-nodules, some even showing germ centers (*vid.* p. 197). The whole structure is surrounded by a connective-tissue capsule. The epithelial walls of the follicular cavities often show extensive degenerative changes, which are accompanied by increased migration of leucocytes into the oral cavity. These leucocytes change (according to Stöhr, 84) into the so-called mucous or salivary corpuscles of the saliva.

Pharyngeal Tonsil.—The pharyngeal tonsils may be regarded

as clusters of small lymph-follicles, similar to those found in the tongue. The pharyngeal tonsil presents numerous irregularly formed crypts, lined by stratified pavement epithelium. These crypts are often widened at the base and are provided with irregular saccular enlargements. The crypts are all surrounded with lymphoid tissue, which may be regarded as diffuse lymphoid tissue in which are found numerous lymphoid follicles, often showing germ-centers. The lymphoid tissue is bounded externally by fibrous tissue, septa of which pass into the lymphoid tissue surrounding the crypts.

Fig. 196.—Section through the pharyngeal tonsil of man; × 6½: *agp*, Arcus glosso-palatinus; *ep*, epithelium; *ft*, crypt; M, striated muscle; *nl*, lymphoid nodules; *S*, connective tissue septa; *st*, remains of tonsillar sinus.

The epithelium lining the crypts or cavities of the tonsils shows, as in the lingual follicles, extensive degenerative changes, resulting mainly in the formation of variously shaped communicating spaces filled with lymphocytes and leucocytes. (See Fig. 197.)

Besides the nerves terminating in the taste-buds, the tongue is richly supplied with sensory nerves which terminate in free sensory endings, which may be traced into the epithelium, and which are especially numerous in the fungiform and circumvallate papillæ; or in smaller or larger end-bulbs of Krause found in the mucosa of

the fungiform papillæ. The motor nerves of the tongue terminate in motor endings.

GLANDS OF THE ORAL CAVITY.

The glands of the oral cavity comprise numerous branched tubulo-alveolar glands situated in the mucosa and submucosa of the lips, cheek, and tongue; branched tubular glands in the region of the circumvallate papillæ; of a pair of compound branched alveolar glands, the parotid; and of two pairs of compound branched tubulo-alveolar glands, the submaxillary and sublingual. These are classified according to their secretions into those secreting principally mucus (human sublingual and many of the smaller oral glands), and known as mucous glands; those secreting a fluid albuminoid substance containing no mucus, the serous glands (parotid glands and the small glands near the circumvallate papillæ);

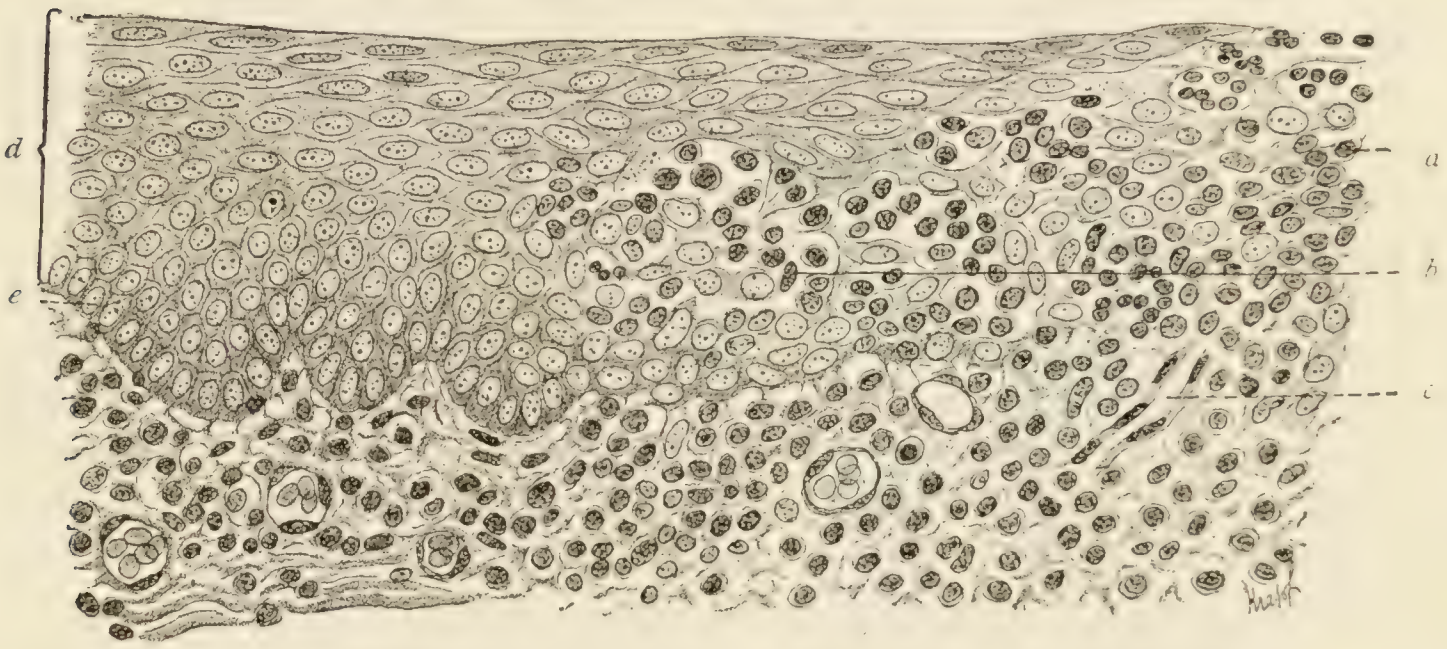

Fig. 197.—The area designated by *a* in the previous illustration, shown by a higher magnification; × about 150: *a*, Leucocytes in the epithelium; *b*, one of the spaces in the epithelium filled with leucocytes and more or less changed epithelial cells; *c*, blood-vessel; *d*, normal epithelium; *e*, basal cell of the same.

and those having a mixed secretion, mucous and serous glands (human submaxillary). The ducts of all these glands open into the cavity of the mouth. The ducts of the smaller oral glands are, as a rule, short and pass up through the mucosa and the epithelium to open on the free surface. The principal excretory ducts of the large salivary glands are Steno's ducts (Stenson's ducts), passing from the parotid glands to the mouth; Wharton's ducts, the ducts of the submaxillary glands, and Bartholin's ducts for the sublingual glands. The salivary glands consist of numerous lobules and small lobes of glandular tissue, surrounded by a thin fibrous-tissue capsule which sends septa and trabeculæ between the lobules and lobes. The duct of each gland on reaching the gland divides into smaller ducts, which penetrate the gland between the lobes and lobules, dividing and redividing in their course; the terminal

branches enter the lobules and join the tubules and alveoli. The ducts of the human submaxillary glands have been carefully investigated by Flint; his account is here followed. The submaxillary duct (Wharton's duct) generally divides into three *primary ducts*, which extend in various directions and are usually relatively short, dividing into the *interlobular ducts*, which often run for relatively long distances before giving off individual branches. They run in the connective tissue between the lobules, and give off branches and end in ducts which ramify between the lobules and are known as *sublobular ducts*, which in turn give rise to *lobar ducts*, which generally ramify through three or four divisions which follow in close succession, forming the *intralobular ducts*. These radiate from the centre toward the periphery of the lobules, without, however, reaching the periphery. The terminal branches of the intralobular ducts are the *intermediate ducts* (intercalary), which are in communication with the secretory compartment, the tubules.

The epithelium lining the different portions of the large excretory ducts varies somewhat. For a short distance from their oral end they are lined by a stratified columnar epithelium consisting of two layers of cells (Wharton's ducts are now and then lined for a short distance by a stratified pavement epithelium continuous with that lining the mouth). Beyond this stratified columnar epithelium, which extends for a variable distance along the large excretory ducts, the interlobular ducts and the sublobular ducts are lined by a pseudostratified columnar epithelium, possessing two rows of nuclei (Steiner). The intralobular ducts are lined by a single layer of columnar cells, the basal half of each cell showing a distinct striation. The intermediate portions of the ducts are lined by a low, cubic, or flattened epithelium. The epithelium of the ducts rests on a basement membrane, consisting of very fine, closely woven connective-tissue fibrils (Flint). External to this there is a sheath of areolar connective tissue, which shows external to the basement membrane a layer of closely woven elastic fibers. The larger divisions of the duct have nonstriated muscle-cells in their walls.

Between the membrana propria and the secreting epithelium of the tube, and more especially in the acini, are branched cells which anastomose with each other, the so-called *basket cells*. The origin of these cells has not been fully determined; their existence even has been questioned. Their processes penetrate between the glandular cells and form a supporting structure for them. The membrana propria surrounding the entire glandular tube is in close relationship to these cells.

We shall now consider more in detail the structure of the alveoli, tubules, and of the salivary glands.

SALIVARY GLANDS.

The Parotid Gland (Serous Gland).—The parotid glands may be classed as compound branched alveolar glands. The gland is made up of distinct lobes and lobules. The secreting compartments consist of irregular, convoluted tubules, which are joined by a narrow intermediate duct to the intralobular ducts. The epithelial cells lining the acini of this gland are short, irregularly columnar or cubic cells, with round or oval nuclei, situated nearer the basal portions of the cells, the protoplasm presenting different

Fig. 198.—Section through salivary gland of rabbit, with injected blood-vessels; × 70.

appearances according to their physiologic condition. When at rest, the cells are filled with fine granules, which are to be regarded as consisting of a substance from which the specific secretion is formed, a substance known as *zymogen*, the granules being known as zymogen granules. These granules are in the paraplasm of the cells, from which they are probably developed. As secretion proceeds the outer portion of the cell becomes free from granules, these being used up in the formation of the secretion (Langley).

The Sublingual Gland (Mucous Gland).—The sublingual glands are compound branched tubulo-alveolar glands. These

glands may be regarded as made up of numerous smaller glands. The ducts divide and redivide, as above described, with this exception, that the secreting compartments are not joined to the intralobular ducts, with striated epithelium, by means of narrow intermediate ducts, as these divisions of the duct system are lacking in these glands (Maziarski). The general arrangement of the secreting compartments in a small portion of a sublingual gland is shown in Fig. 199. The size of the tubules and alveolar enlargements varies. In the tubules and alveoli there are two varieties of cells: cells which form mucus and cells which have a serous secretion. The cells which form mucus, appear clear in preparations treated after the ordinary methods used in the laboratories. In fresh

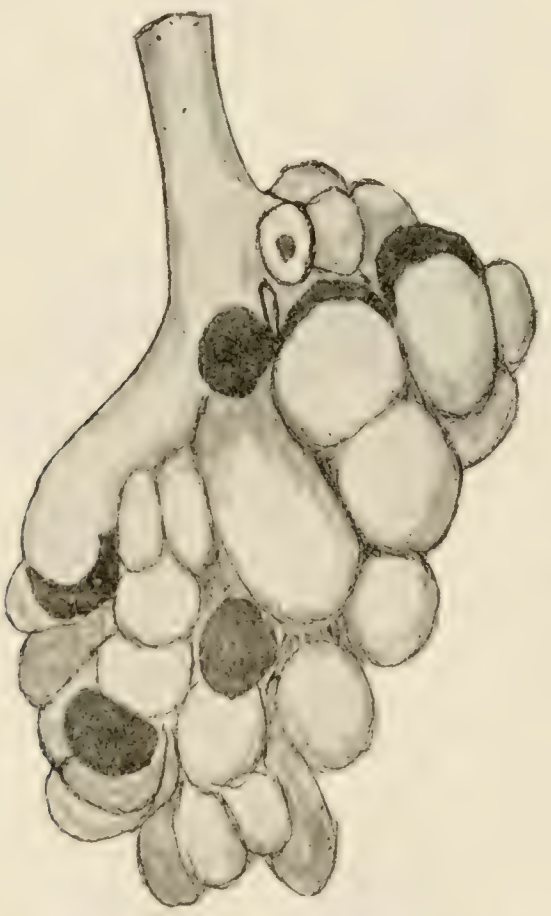

Fig. 199.—Model of a small portion of a sublingual gland of man; × 140. The demilunes of Heidenhain are more deeply shaded (Maziarski, "Anatomische Hefte," 1901).

preparations teased in serum or in 2% to 5% sodium chlorid solution (Langley), or when fixed and stained after special methods, it may be seen that the secretion is first formed in the form of large granules, consisting of a substance known as mucigen, which breaks down to form the mucus, much as described for mucous or goblet cells (see page 87). In preparations the cells of which are stored with mucigen the nuclei are situated at the periphery of the tubules and alveoli, near the basement membranes. The cells with serous secretion are situated in close apposition to the basement membrane; they resemble in structure serous cells, and are found either singly or in groups of crescentic shape. These groups are known as the *crescents of Gianuzzi* or the *demilunes of Heidenhain.* The margins of the individual cells composing the crescents are

often so faintly outlined that the whole structure has the appearance of a large polynuclear giant cell.

The demilunar cells have been variously interpreted by different observers. They have been regarded as permanent cells with a special secretion, as transitional structures, and again as cells destined to replace the degenerated mucous cells. Stöhr (87) believes that the cells of the acini are never destroyed in the process

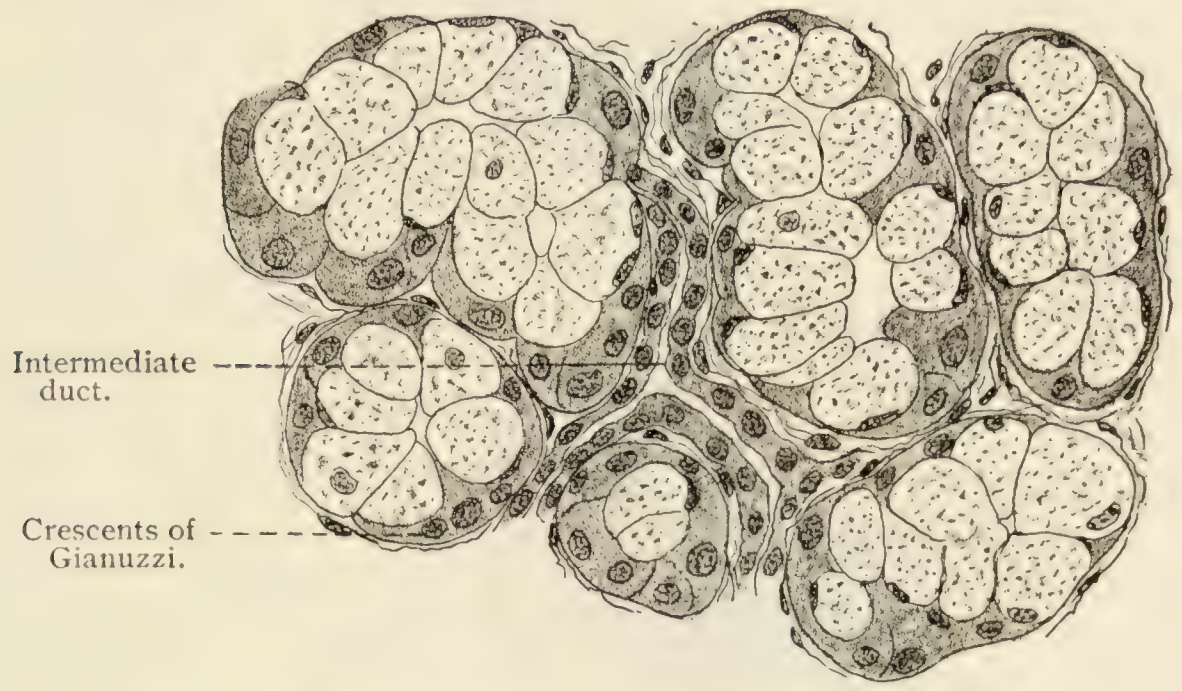

Fig. 200.—From section of human submaxillary gland.

of mucous secretion, and that the crescents of Gianuzzi are therefore merely a complex of cells containing no secretion, which have been crowded to the wall by the adjacent enlarged and distended cells. Solger (96), on the other hand, does not regard the demilunes as transitional structures whose function is to replace the destroyed cells, but considers them to be permanent secreting cells —an opinion which he bases on the results of special methods of

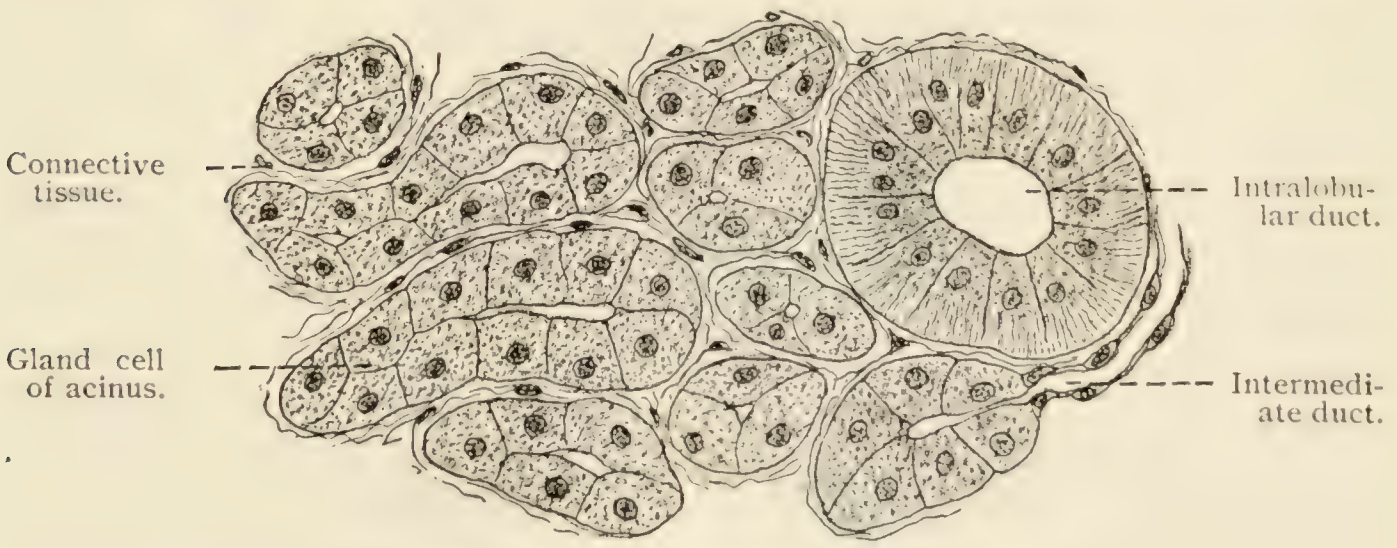

Fig. 201.—Section from parotid gland of man.

investigation. According to him, then, the mucous salivary glands are mixed glands, in that the demilunes consist of cells of a serous type, while the remaining elements are mucous in character. The destruction of mucous cells during secretion is not admitted by him (compare also R. Krause). This latter view seems more in accord with recent observations.

The Submaxillary Gland (Mixed Gland).—The submaxillary gland of man is a gland composed of tubules similar in shape and structure to those found in the parotid gland, having a serous secretion, and of tubules with alveolar enlargements, lined with cells

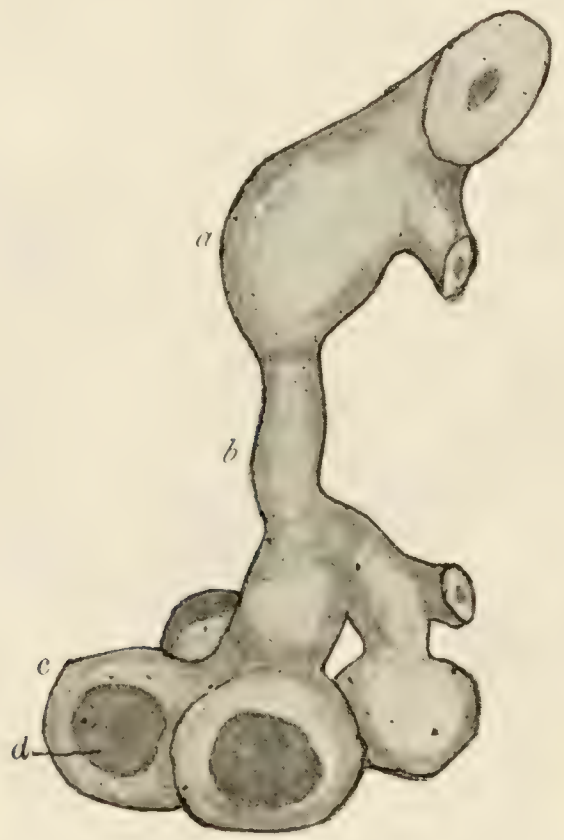

Fig. 202.—Portion of a model of a salivary gland with mucous secretion : a, intralobular duct ; b, intermediate duct ; c, tubules and alveoli lined by mucous cells ; d, demilunes of Heidenhain (from Böhm and Davidoff, third German edition).

which form mucus. These mucus-secreting tubules are joined to intermediary ducts which are branches of intralobular ducts with striated epithelium. The mucus-forming tubules show the demilunes of Heidenhain. The submaxillary glands of man are there-

Fig. 203.—A number of alveoli from the submaxillary gland of dog, stained in chrome-silver, showing some of the fine intercellular tubules.

fore mixed glands, with both serous and mucous secretion, the respective tubules or groups of tubules showing the characteristics of mucous and serous glands. In Fig. 202 is shown a portion of a model of a salivary gland, with mucous secretion.

By means of various methods the existence of a network of tubules surrounding the glandular cells may be demonstrated both in the serous and mucous glands. The same arrangement may be observed in the case of the cells forming the demilunes. The course of these tubules may be followed to their junction with the lumen of the secreting portion of the gland tubule, and the whole structure would seem to indicate that the entire surface of the cells is concerned in the act of secretion (Erik Müller, 95; Stöhr, 96, II).

As to the part that the intermediate tubules and the intralobular tubes play in the process of secretion, Merkel's (83) theory is of interest. He believes that the former yield a part of the water in the saliva, while the salts are furnished by the rod-shaped epithelium of the intralobular tubes. These views of Merkel have been questioned, as it has been shown by chemic analysis that the relative quantity of water and salts in the secretion of the salivary glands is not at all proportionate to the number of the intermediate tubules and intralobular tubes. For example, Werther finds that although a great many intermediate tubules are present in the parotid gland of the rabbit and none at all in the submaxillary gland of the dog, nevertheless the secretions of these glands contain equal quantities of water. Furthermore, the secretions of the parotid of the rabbit and of the sublingual of the dog show equal quantities of salts, in spite of the fact that in the former there are large numbers of intralobular tubes with rod-shaped epithelium and in the latter none at all.

THE SMALL GLANDS OF THE MOUTH.

Besides the larger glands, there are in the oral cavity numerous small lobular, tubulo-alveolar and simple branched tubulo-alveolar glands. They are mostly glands with mucous secretion. In many of them demilunes of Heidenhain may be made out, most clearly in those of the lips (J. Nadler). They are known, according to their location, as glandulæ labiales, palatinæ, and linguales. The absence of intralobular tubes and well-defined intermediate tubules is characteristic of all the smaller glands of the oral cavity. As a consequence the secreting tubules are composed almost entirely of those parts corresponding to the acini of the larger glands. Branched tubular glands, with serous secretion, known as v. Ebner's glands, occur in the tongue, their ducts opening into the depressions of the circumvallate and foliate papillæ, while the secreting tubules extend into the muscular portion of the tongue. The general character of v. Ebner's glands is shown in Fig. 204.

The salivary glands and smaller glands of the mouth have a rich *blood supply*. In the salivary glands the arteries follow the ducts through their repeated branching, ultimately ending in capillaries which form a network inclosing the acini and the terminal

portions of the system of ducts. The blood-vessels for each lobule are quite distinct, forming only few anastomoses with those of neighboring lobules.

The Lymphatics.—In the connective tissue surrounding and separating the acini there are found clefts, which contain lymph. These clefts are in part between the blood-capillaries and the basement membranes. Lymph-vessels are found in the connective tissue separating the lobules and lobes of the gland, in which they follow the duct system. Lymph-vessels have not been found in the lobules.

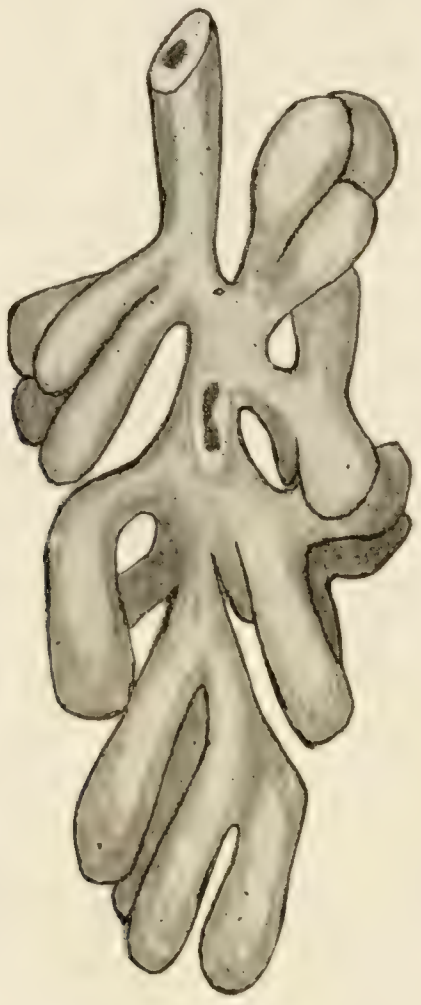

Fig. 204.—Model of a gland of v. Ebner, from a boy fourteen years old; × 170. (Maziarski, "Anatomische Hefte," 1901.)

The *nerve supply* of the salivary glands, may, owing to the importance of these structures, receive somewhat fuller consideration. Their nerve supply is from several sources. That of the sublingual and submaxillary glands will be considered first. Sensory nerve-fibers (no doubt the dendrites of sensory neurones, the cell-bodies of which are situated in the geniculate ganglion) terminate in free sensory endings in the large excretory ducts and their branches. These medullated fibers accompany the ducts in the form of small bundles. From place to place one or several fibers leave these bundles and, after dividing a number of times, lose their medullary sheaths. After further division the nonmedullated branches form plexuses under the epithelial lining of the ducts. From the fibers of these plexuses terminal fibrils are given off, which enter the epithelium, to end, often near the free surface, on the epithelial cells (Arnstein, 95; Huber, 96). The secretory cells of the acini receive

their innervation from sympathetic neurones. The cell-bodies of those supplying the sublingual glands are grouped in a number of small, sympathetic ganglia situated in a small triangle formed by the lingual nerve, the chorda tympani and Wharton's duct, the chorda-lingual triangle. These ganglia may be known as the sublingual ganglia (Langley). The cell-bodies of the sympathetic neurones supplying the secretory cells of the submaxillary glands are grouped in small ganglia situated on Wharton's duct just before it enters the gland, in the hilum of the gland, and on the interlobar and interlobular ducts ; they may be spoken of collectively as the submaxillary ganglia. In the glands under discussion, the neuraxes of the sympathetic neurones are grouped to form small bundles, which divide repeatedly, the resulting divisions joining to form plexuses situated in the outer portion of the walls of the ducts, and as such may be followed along the ducts, the bundles of nerve-fibers becoming smaller and the division of the bundles of fibers and the individual fibers occurring oftener as the smaller divisions of the system of ducts are reached. On reaching the acini, the terminal branches of the nerve-fibers form a plexus outside of the basement membrane, *epilamellar plexus ;* from this branches are given off which penetrate the basement membrane, some forming a *hypolamellar plexus*, others ending on the gland-cells in small granules or clusters of granules (Arnstein). Throughout their entire course the neuraxes of the sympathetic neurones are varicose, nonmedullated nerve-fibers. The nerve-fibers of the chorda tympani end in terminal end-baskets, inclosing the cell-bodies of the sympathetic neurones found in the sublingual and submaxillary ganglia, and not in the glands, as generally stated by writers. The increase of secretion from the submaxillary and sublingual glands on direct or indirect stimulation of the chorda tympani is due, therefore, not to a direct stimulation of the gland-cells by the fibers of this nerve, but to a stimulation of the sympathetic neurones of the sublingual and submaxillary ganglia, the neuraxes of which convey the impulse to the gland-cells. These glands have a further nerve supply from the superior cervical ganglia of the cervical sympathetic. The neuraxes of sympathetic neurones, the cell-bodies of which are situated in the superior cervical ganglia, accompany the blood-vessels to the sublingual and submaxillary glands ; their mode of termination is, however, not as yet determined. The cell-bodies of the sympathetic neurones here in question are surrounded by end-baskets of nerves which leave the spinal cord through the second, third, and fourth dorsal spinal roots. The blood-vessels of the salivary glands are also richly supplied with vasomotor nerves, the neuraxes of sympathetic neurones, which terminate on the muscle-cells of their walls. The nerve supply of the parotid glands is, in the main, like that of the other salivary glands here described, although it has not been worked out with the same detail. The cell-bodies of the sympathetic neurones, the neuraxes of which innervate the gland-cells, are, it

would appear, situated in the otic ganglia. The nerve-ending in the smaller glands of the mouth is similar to that given for the salivary glands, as has been shown by Retzius and other observers.

It is very probable that the cell-bodies of the sympathetic neurones, the neuraxes of which innervate the glands of the tongue, are situated in the small sympathetic ganglia found on the lingual branches of the glossopharyngeal and lingual nerves.

B. THE PHARYNX AND ESOPHAGUS.

Pharynx.—The epithelium of the pharynx is of the stratified squamous variety, and also contains prickle cells and keratohyalin. (See Skin.) A stratified ciliated epithelium is present only in the fornix in the region of the posterior nares. The area covered by this type of epithelium is more extensive in the fetus and new-born, and extends over the whole nasopharyngeal vault. In the human embryo the superficial epithelial cells of the esophagus possess cilia up to the thirty-second week (Neumann, 76). The papillæ of the mucosa are loosely arranged and are in the form of slender cones. The mucosa of the pharynx contains diffuse adenoid tissue rich in cells which in some places forms accessory tonsils (*vid.* p. 251); it is bounded externally by a well-developed layer of elastic fibers which occupies the same relative position as does the muscularis mucosæ in the esophagus. External to this elastic layer, there is found a muscular coat consisting of striated muscle-fibers.

Esophagus.—The esophagus is lined by a stratified pavement epithelium, which rests on a papillated mucosa, consisting of fibrous tissue which contains few elastic fibers and is bounded externally by a muscularis mucosæ, the majority of the cells of which show a longitudinal arrangement. External to the muscularis mucosæ there is found a well-developed submucosa, consisting of loosely woven fibro-elastic connective tissue. Outside of the submucosa there is found a muscular layer, consisting of an inner circular and an outer longitudinal layer. These muscular layers consist in the upper half of the esophagus mainly of striated muscle-fibers, while in the lower half they consist almost wholly of nonstriated muscular tissue. There is, however, no sharply defined line of demarcation between the two types of muscular tissue, as the fibers of the unstriped variety penetrate for some distance upward into the substance of the striated muscle, giving the tissue here a mixed character.

The esophagus contains two varieties of glands: (1) Mucous glands of the type of branched tubulo-alveolar glands. The secreting portions of these glands are situated in the submucosa, while the ducts pass through the muscularis mucosæ to the surface. The secreting tubules and alveoli are lined by mucous cells; demilunes are absent. The ducts, which often show cystic dilations,

are lined for the greater part by a single layer of columnar cells; at their termination they often possess a lining of stratified pavement epithelium. (2) The other variety of glands are found in two zones, the one situated at the upper end of the esophagus, in a region opposite the cricoid cartilage to the fifth tracheal cartilage (superficial glands of esophagus, Hewlett; upper cardiac gland, Schaffer), the other at the end of the esophagus, just before it enters the stomach—the esophageal cardiac glands. These glands are situated above the muscularis mucosæ, and are of the branched

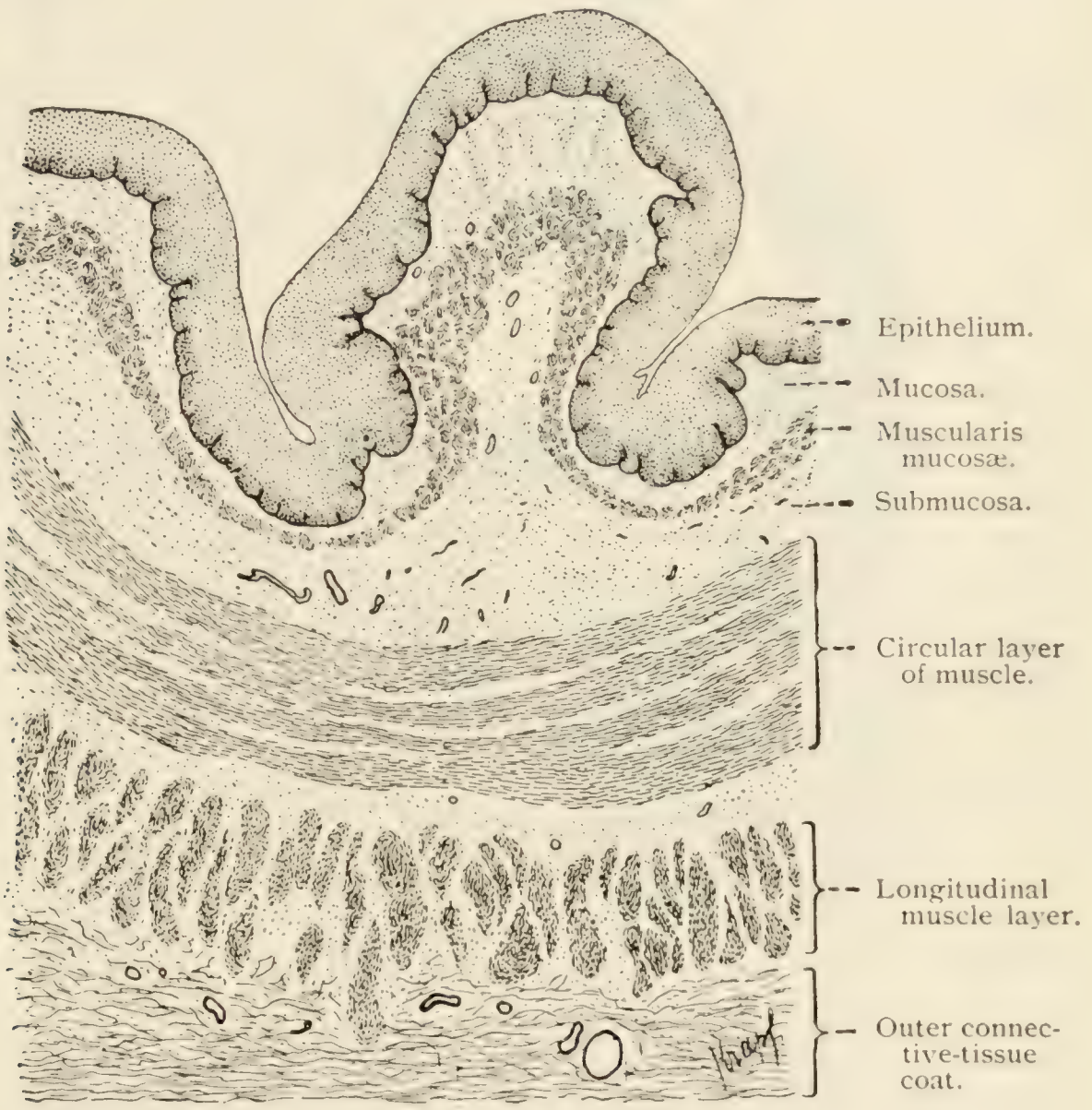

Fig. 205.—Section of esophagus of dog; × 18.

tubular variety. The ducts of these glands, which reach the surface through the apices of the connective tissue papillæ, are lined by a single layer of columnar epithelial cells. The secreting portions of the tubules are lined by shorter columnar cells. Here and there cells like the parietal cells of the fundus glands of the stomach, to be described later, are also found, as also cells showing a mucous secretion. The cardiac glands of the esophagus are similar to the glands of the same name found at the cardiac end of the stomach, with which they may be said to be continuous, and which will receive further consideration.

C. THE STOMACH AND INTESTINE.

1. GENERAL STRUCTURE OF THE INTESTINAL MUCOUS MEMBRANE.

The mucous membrane of the stomach and intestine, unlike that of the esophagus and oral cavity, possesses an epithelium of the simple columnar variety with elongated cells (about 22 μ in

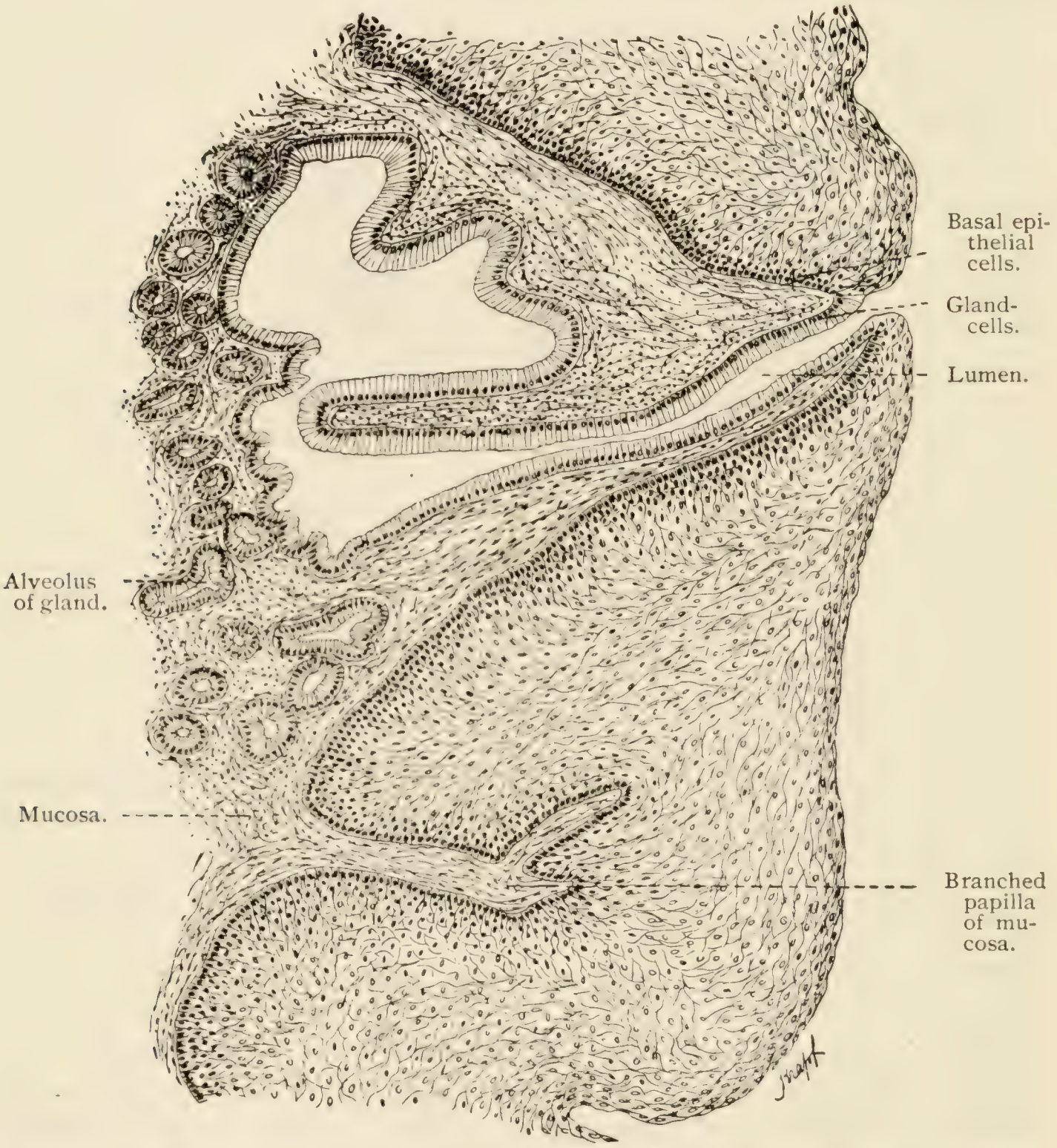

Fig. 206.—Part of section of human esophagus, showing a cardiac gland with a dilated duct; × 120.

height). At the cardia the stratified squamous epithelium of the esophagus terminates abruptly, the basilar layer of the esophageal epithelium being continued as the simple columnar epithelium of the stomach. In the intestine the epithelium shows a well-marked striated cuticular border, striated protoplasm in the outer ends of the cells, extending to the immediate vicinity of the nuclei, which

are situated in the basal portions of the cells. The basal portion of each cell consists of nonstriated protoplasm, ending in a longer or shorter process which extends to the basement membrane, or possibly even penetrates it. The epithelial cells have the power of producing mucus, a phenomenon which, in the normal condition, rarely embraces whole areas of epithelium ; these cells (goblet cells) are usually surrounded by others which are unchanged (for details about goblet cells see General Histology, p. 87). Throughout the entire intestinal tract the epithelium forms simple, branched, and compound tubular and alveolar glands. These are depressions lying in the mucosa, and only in the duodenum extend beyond it into the submucosa.

The mucosa consists of adenoid tissue, consisting of reticular fibers and a fine network of elastic fibers, containing relatively few cells. It fills the interstices between the glands, and often forms a thin but continuous layer (granular layer of F. P. Mall) below the glands. It is therefore obvious that the development of the mucosa is inversely proportionate to the number and the density of arrangement of the glands ; when the latter are present in large numbers, as, for instance, in the stomach, the mucosa is reduced to a minimum. In the small intestine it forms not only the permanent folds, but also certain leaf-like and finger-like elevations known as villi, which are covered with epithelium and project into the lumen of the intestine, thus increasing to a considerable extent the surface area of the mucous membrane. In the mucosa are found small nodules of adenoid tissue. These are spoken of as lenticular glands when occurring in the stomach, as solitary glands when found in the upper portion of the small intestine and in the large intestine. In the lower portion of the small intestine they are grouped to form the agminated glands, or Peyer's patches, which, when large, extend into the submucosa. In the external portion of the mucosa there is found a thin, somewhat denser layer, known as the stratum fibrosum (F. P. Mall), consisting mainly of white fibrous tissue (Spalteholz) ; and external to this is a layer consisting of two or three strata of unstriped muscle-fibers, the *muscularis mucosæ*. As a rule, it is composed of an inner circular and an outer longitudinal layer. This arrangement is interrupted only where the larger glands and follicles penetrate into the submucosa. The epithelium with the glands, the mucosa with its lymph-nodules, and the muscularis mucosæ form together the *mucous membrane*, or *tunica mucosa*.

Below the mucous membrane is the connective-tissue *submucosa*. This is characterized by its loose structure, and consequently affords considerable mobility to the mucous membrane. In the small intestine it forms a large number of permanent transverse folds known as *valvulæ conniventes* (Kerkring). In the submucosa of the duodenum occur the secreting portions of *Brunner's glands* (glandulæ duodenales), and in the small intestine the larger lymph-nodes and Peyer's patches.

External to the submucosa is the muscular coat, which generally consists of two layers of unstriped muscle-tissue. The inner layer is composed of circular fibers (stratum circulare) ; the outer layer, of longitudinal fibers (stratum longitudinale). In the colon the longitudinal layer forms definite bands, the *tæniæ coli.* In some regions the circular fibers are also considerably reinforced, particularly in the *plicæ sigmoideæ* which lie between the tæniæ coli. At these points the longitudinal layer also is thickened. In the rectum the circular fibers form the internal sphincter ani muscle. In the stomach a third layer is added to the two already mentioned, with fibers running obliquely. It lies internal to the circular fibers, but does not form a continuous layer.

According to Legge, elastic fibers are present throughout the entire digestive tract of all adult mammalia and vary only in minor details in the different species. In regions in which the tunica muscularis is prominent the elastic fibers attain a considerable size. There is also a difference in their development in carnivora and herbivora. In general, they form a dense network, present not only in the serous layer, but also in the submucosa and mucosa. These fibers preserve the elasticity of the intestinal walls and resist any hyperextension of the glands and follicles.

The intestine is covered externally by the peritoneum, forming the serous coat, which consists of an inner, very thin connective-tissue layer (subserosa) and an outer layer of mesothelial cells.

2. THE STOMACH.

The general structure of the gastric mucous membrane is essentially the same as that of the intestinal canal. It consists of a relatively coarse adenoid reticulum, the spaces of which contain lymphocytes and leucocytes, and plasma cells. Thin strands or bundles of nonstriated muscle cells may be traced from the muscularis mucosæ to various levels in the mucosa. It presents depressions or infoldings known as crypts (foveolæ, stomach-pits, gland ducts) into which the glands open. In the fundus the crypts attain a depth of from one-fifth to one-sixth the thickness of the mucous membrane. In the pylorus they are deeper, many of them here extending through half the mucous membrane and some even reaching to near the muscularis mucosæ. The epithelium of the crypts and

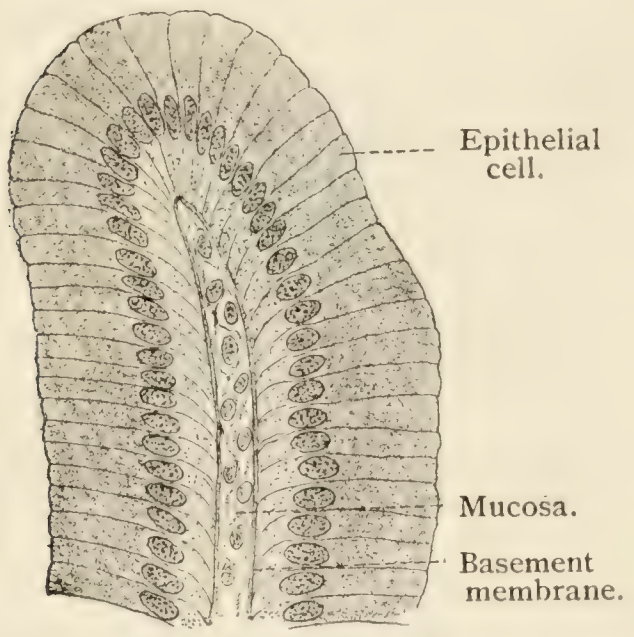

Fig. 207.—Epithelium of human stomach, covering the fold of mucosa between two gastric crypts ; × 700.

that of the folds between them is composed of long, slender cells, with basally situated nuclei. That portion of the cell-body near its free margin contains very little protoplasm, but presents a well-developed mucous plug or theca, occupying the outer one-fourth or one-third of the cell; the region of the cell containing the nucleus possesses more protoplasm. This part of the cell extends downward in a curved process of diminishing size, which assumes a position parallel to the corresponding parts of the neighboring cells, and nearly parallel to the basement membrane.

Three varieties of glands occur in the stomach: (1) Cardiac glands; (2) fundus glands; (3) pyloric glands.

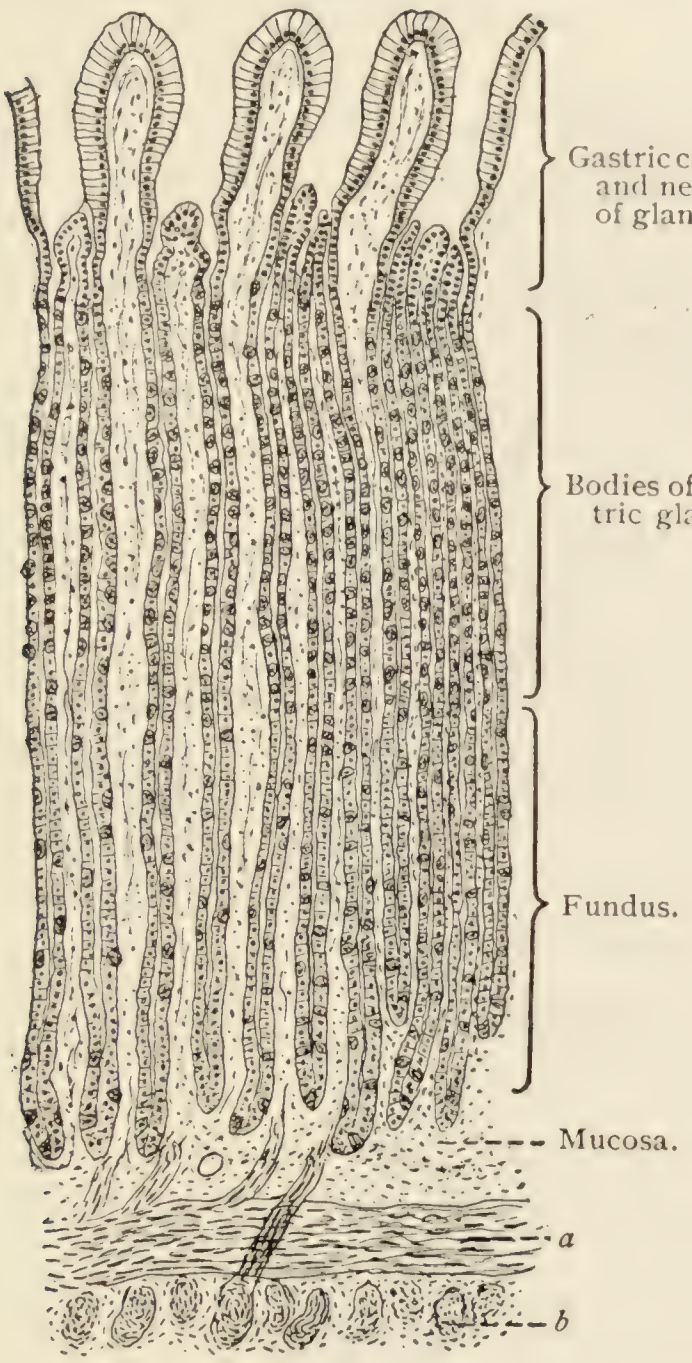

Fig. 208.—From vertical section through fundus of human stomach; × 60: *a* and *b*, Interlacing fibers of the muscularis mucosæ; from *a* and *b* muscular fibers enter the mucosa. The fibers of the layer *b* penetrate those of layer *a*.

Fig. 209.—A number of fundus glands from the fundus of the stomach of young dog, stained after the chrome-silver method, showing the system of fine canals surrounding the parietal cells and communicating with the lumen of the glands.

1. The *cardiac glands* have recently been subjected to careful investigation by Bensley; his account is here followed. They occur in the region of the junction of the esophagus and stomach, occupying a zone varying somewhat in width, but may be as wide as 4.3 cm. The glands are of the type of branched tubulo-alveolar glands. The tubules and alveoli are not of uniform structure. The majority of the lining cells are mucus secreting cells, and

may be recognized as such in suitably stained preparations, cells with zymogen granules, similar to the chief cells of the body of the fundus glands (see these), are also found, as also the parietal cells, as found in the latter glands. The cardiac glands may be regarded as decadent structures.

2. The *fundus glands* (peptic glands) consist of a crypt or foveola, into which empty three to five, or even more, unbranched and branched tubules, which often show irregular terminal enlarge-

Fig. 210.—From a section through the junction of the human esophagus and cardia; × 50.

ments. The tubules vary in length, measuring from 0.4 to 2.2 mm. The upper end of a fundus tubule is slightly narrower and presents structural peculiarities, and is known as the neck of the gland. The main portion of the gland is called its *body*, and the region at its distal blind end the *fundus*.

The fundus glands, as their name suggests, are found in the fundus or cardiac end of the stomach, and are lined by two kinds of cells: parietal (border cells, acid, oxyntic, or delomorphous cells—R. Heidenhain, 69; Rollet, 70) and chief, central, peptic, or adelomor-

phous cells. The parietal cells lie against the walls of the gland—that is, they rest on its basement membrane—and are particularly numerous in the neck and body of the gland, but not so numerous in its fundus. Their bodies often extend more or less beyond the even line of the remaining cells, thus forming, together with the membrana propria, a protuberance (particularly noticeable in the pig, where almost the entire cell may be enveloped by the basement membrane, giving it an appearance of being entirely extraglandular). Toward the lumen of the gland the contour of these cells is modified by pressure on the part of the adjacent cells belonging to the other variety, and they are indented according to the number of the latter. Occasionally, a process is seen extending from a parietal cell to the lumen of the gland. The parietal cells are larger than the cells of the other variety and richer in protoplasm ; they are of an irregular oval or triangular shape and possess, as a rule, a single nucleus, although in man numerous parietal cells with two nuclei are found. The parietal cells are clearer in fresh preparations than are the chief cells, while in fixed preparations the reverse is generally the case. They stain deeply in Heidenhain's iron-lac-hematoxylin, are darkened by osmic acid, and show an affinity for acid stains, especially for eosin, also for congo-red and for neutral carmine solutions.

According to Erik Müller and Golgi (93), there exists in the peripheral protoplasm of each parietal cell a system of canals in the form of a network communicating with the lumen of the gland and varying in structure according to the physiologic condition of the cell—wide-meshed in a state of hunger and fine-meshed during digestion. A peripheral zone differing from the rest of the cell-body may occasionally be demonstrated in the parietal cells (mouse) by using the method of von Altmann.

The chief cells are short, irregular, columnar structures whose narrower portions point toward the lumen of the gland. They are situated either directly between the lumen and the basement membrane of the gland, or their basilar surfaces border on a delomorphous cell. They are found throughout the tubule of the gland and occupy the spaces between the delomorphous cells. The chief cells of the fundus glands are of two varieties, as has been shown by Bensley. The chief cells of the body of the gland are characterized by the possession of relatively large zymogen granules, which are found in the inner portion of the cells. These granules are used up during secretion. The outer or basal portion of the cells contains a prozymogen, not in granular form but recognized by its staining reaction. The chief cells of the neck are slightly smaller than those of the body, and differ from these in that they do not possess zymogen granules and prozymogen only in small amounts, but show by their reaction to certain stains that they are mucus-secreting cells.

The structure of the *pyloric* region of the stomach differs in some respects from that of the cardiac end and fundus. There

is, however, no sharply defined boundary between fundus and pylorus, but a transitional zone in which changes gradually take place. Toward the pylorus the gastric crypts gradually become deeper and the parietal cells decrease in number. Here also the glands branch more freely. In the pylorus itself the crypts frequently extend half-way through the thickness of the mucous membrane, often even penetrating nearly to the muscularis mucosæ, in which case the corresponding tubules become tortuous and arch over the muscularis mucosæ. The glands of the pyloric region are therefore to be classified as branched tubular glands (De Witt).

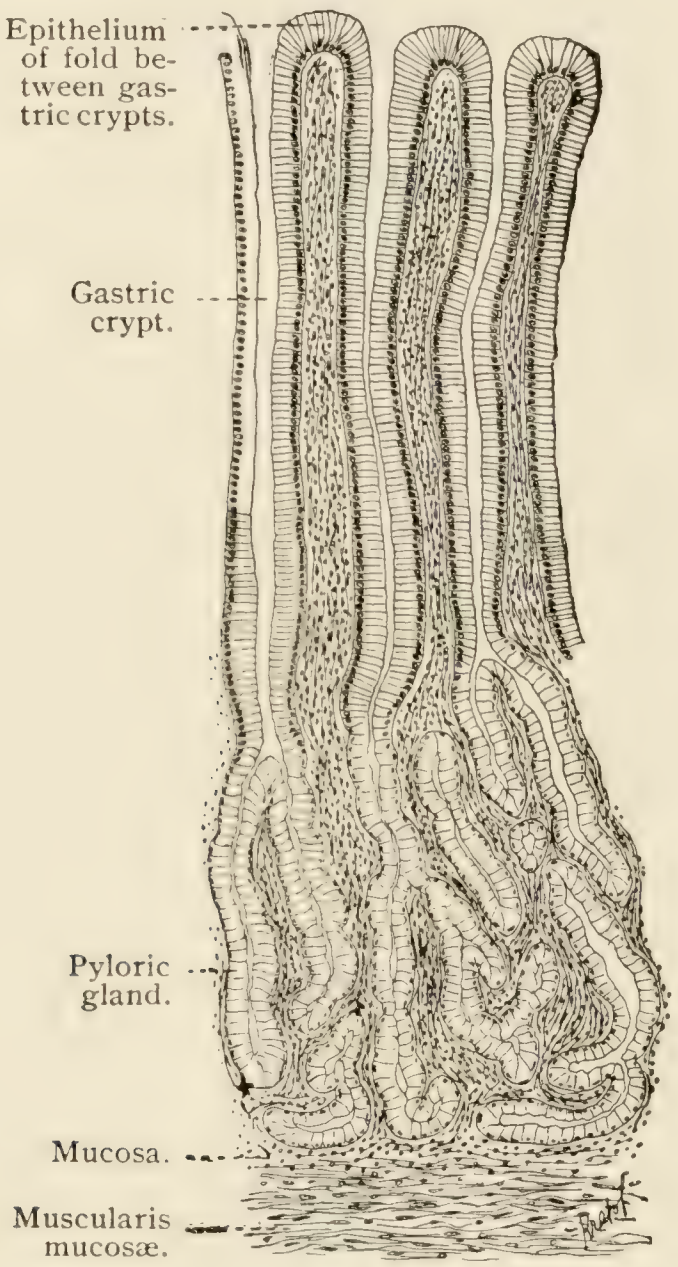

Fig. 211.—From vertical section through human pylorus; × about 60.

Among the branched pyloric glands are found glands which show no distinct branching. The most important feature is that in the great majority of the tubules only a single variety of cell is present in the pyloric gland. (Only here and there are found parietal cells in the pyloric glands of the human stomach.) These cells may be compared with the chief cells of the neck regions of the fundus glands, in that they show no zymogen granules, and prozymogen only in small quantity, and on staining with special stains, it can be shown that their secretion is mucus. They are of columnar shape, and more uniformly so than the chief cells of the fundus

glands—a condition probably due to the general absence of delomorphous cells. In the immediate vicinity of the gastroduodenal valve the pyloric glands become shorter, and other glands, which extend into the submucosa, and which are identical in structure with the glands of Brunner in the duodenum, make their appearance. In this portion of the pylorus are also a few scattered villi, which from their structure may be considered as belonging to the duodenum (*vid.* Fig. 218).

In the normal condition the mucosa of the stomach contains solitary lymph-nodules (lenticular glands) in the fundus region; they are, however, more frequent in the pyloric region; well-defined lymph-nodules are constantly present in the immediate vicinity of the pylorus.

The muscularis mucosæ is usually composed of three layers, the fibers of the individual layers forming distinct interlacing bundles. Individual muscle-fibers very frequently branch off from the inner layer, assume a vertical position and disappear among the glands. This arrangement is especially well seen in the muscularis mucosæ of the fundus of the stomach (Fig. 208).

Only the inner and middle layers of the muscular coat of the stomach enter into the formation of the sphincter pylori (Fig. 218). The fibers of the outer layer, however, penetrate through the sphincter pylori and may even be traced into the submucosa. When these alone contract, the muscular bundles of the sphincter act somewhat as pulleys, and a moderate dilatation of the lumen of the pylorus is the result (dilatator pylori, Rüdinger, 97). (For further particulars about the stomach, compare Oppel, 96.)

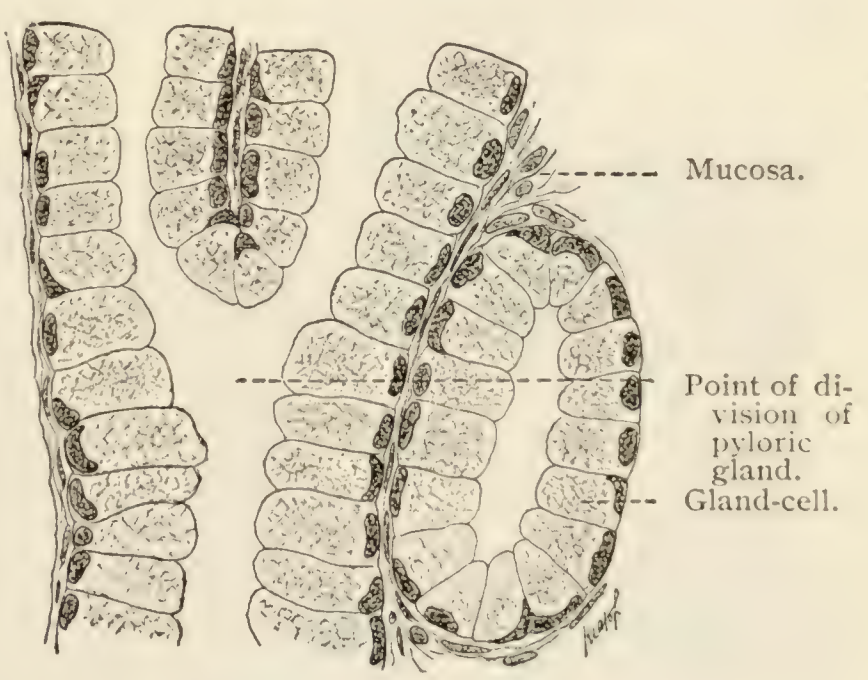

Fig. 212.—From section through human pylorus; × 600.

The changes which the epithelium and the secretory cells of the stomach undergo during secretion are of special importance. These relations have been carefully studied in animals by R. Heidenhain (83). As far as our present knowledge goes, it would seem that the same processes also occur in man. In a state of hunger the chief cells of the fundus are large and contain numerous zymogen granules, while the parietal cells are small; in certain cases the parietal cells abandon their mural position and, like the chief cells, border upon the lumen of the gland. During the first few hours of digestion the chief cells remain large, while the parietal cells increase in

size. In the dog, from the sixth to the ninth hour of digestion, the chief cells diminish in size and contain fewer zymogen granules, while the parietal cells remain large and even increase in size. From the fifteenth hour on, the process becomes reversed; the

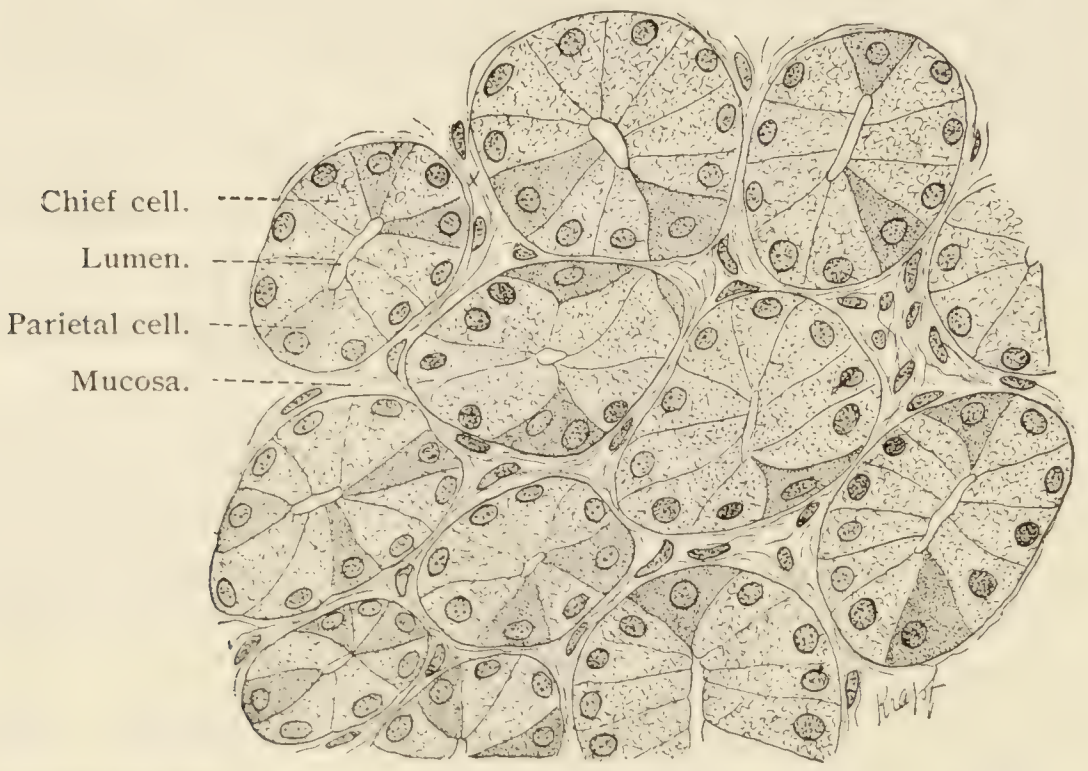

Fig. 213.—Section through fundus of human stomach in a condition of hunger; × 500.

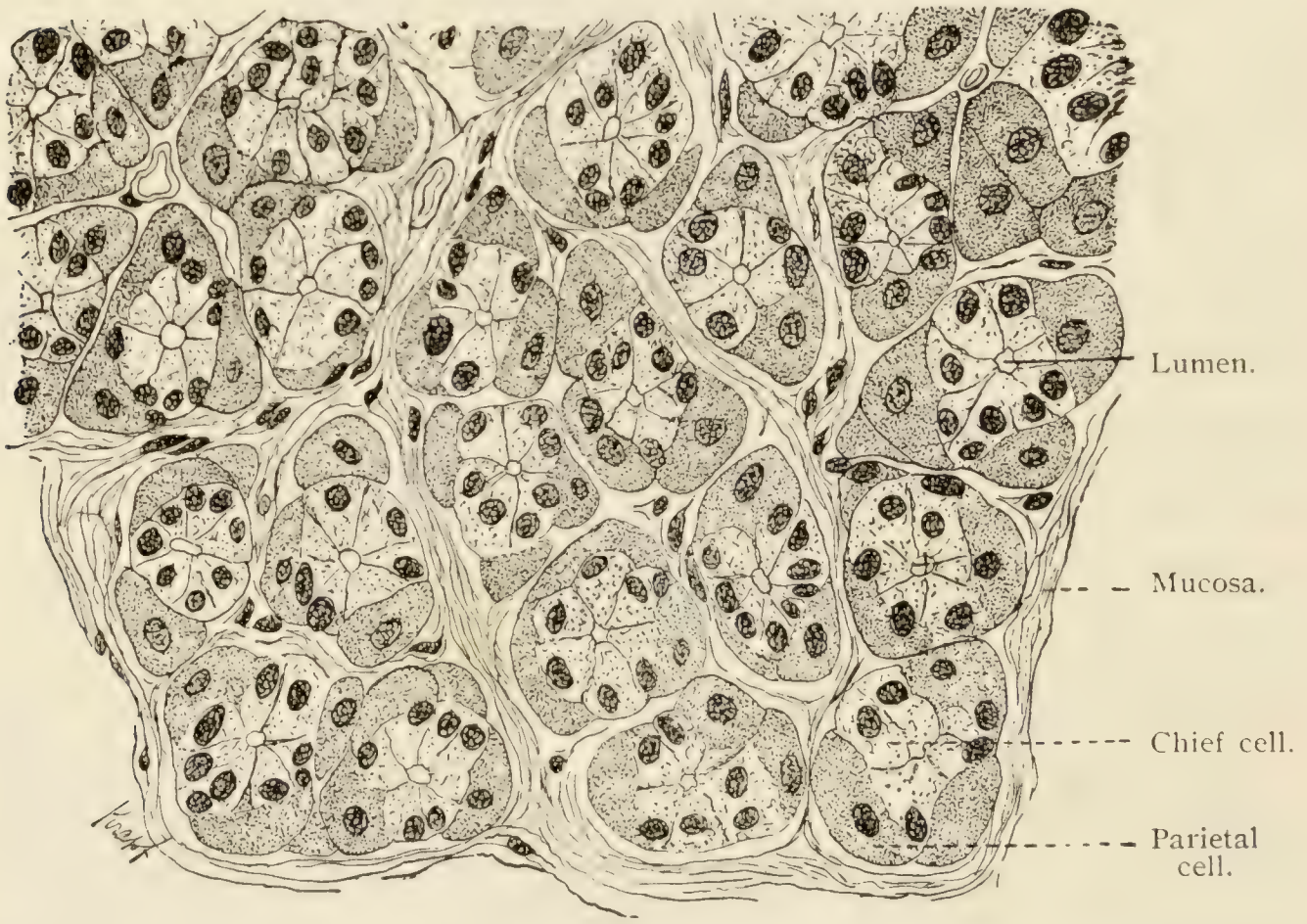

Fig. 214.—Section through fundus of human stomach during digestion; × 500.

chief cells enlarge and the parietal cells diminish in size. In a condition of hunger the cells of the pylorus are clear, of medium size, and do not begin to enlarge until six hours after feeding. From the fifteenth hour on, the cells become smaller and more turbid,

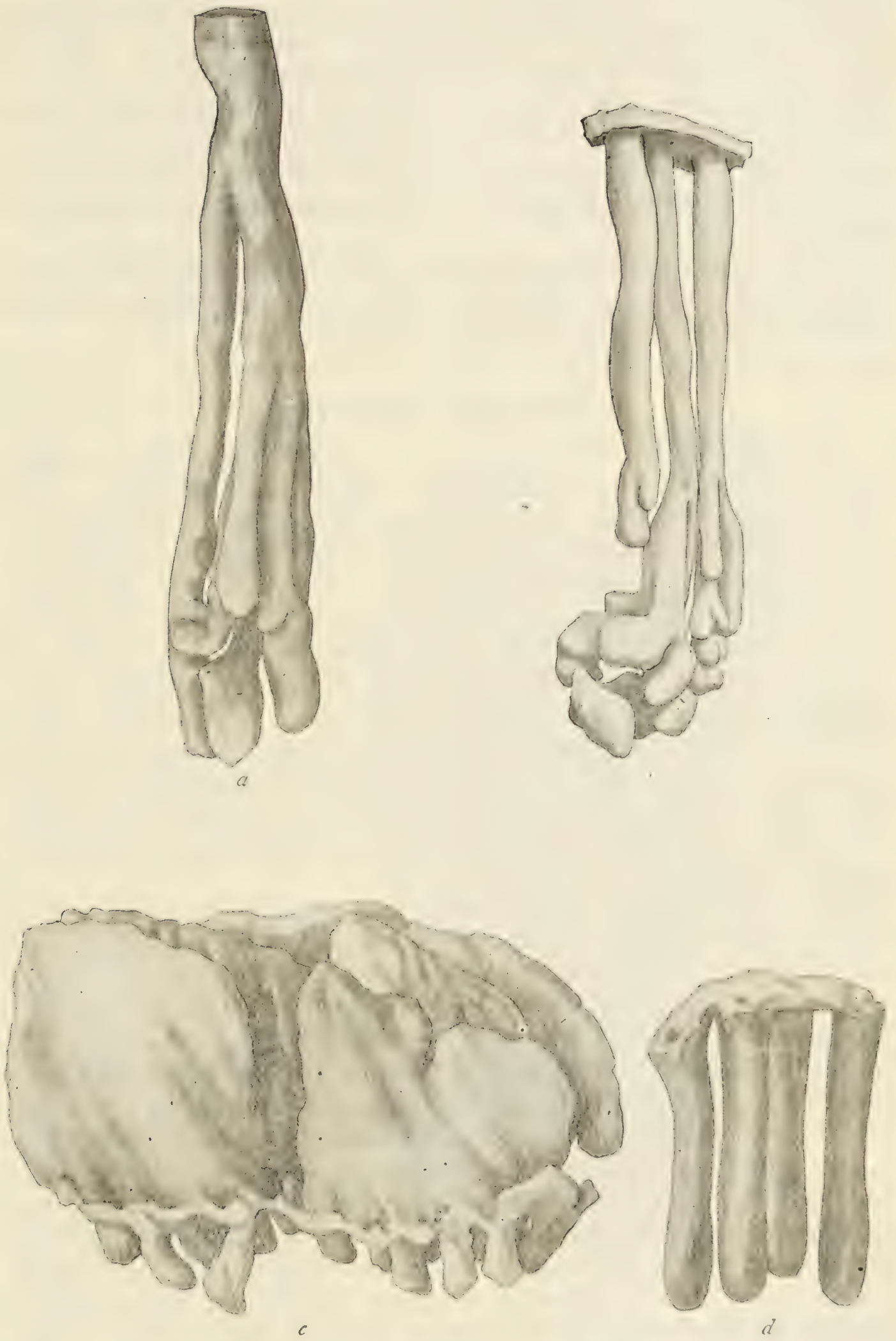

Fig. 215.—Illustrations of models, made after Born's wax-plate reconstruction method, of glandular structures and duodenal villi of the human intestine ; × 100 : *a*, Fundus gland ; *b*, three pyloric glands ; the one at the left is a simple tubular gland, the middle one a branched tubulo-alveolar gland ; the one at the right a typical pyloric gland of the branched tubular variety ; *c*, leaf-shaped villi and crypts of Lieberkühn of the duodenum ; *d*, crypts of Lieberkühn of the large intestine.

while the nuclei return to the center of the cells. Since chemic examination has shown that the amount of pepsin found in the gastric mucous membrane increases with the enlargement of the chief cells of the body of the fundus glands, and decreases with their diminution in size, there can be hardly any doubt that this ferment is elaborated by these cells. It is assumed that the parietal cells secrete the acid of the gastric juice, although, in spite of all efforts, it has not yet been definitely proved that these cells possess an acid reaction.

The vascular and lymph-vessels of the stomach, and also its nerve supply, will be considered in a general discussion of these structures pertaining to the entire intestinal canal.

3. THE SMALL INTESTINE.

The mucous membrane of the small intestine is characterized by the presence of *villi*. The villi vary in size and shape in the different mammals. In man, in the upper portion of the small intestine, they are distinctly leaf-shaped, being three to four times as broad in one direction as they are in the other, often showing a narrowing at their bases. This has been shown by reconstruction of the mucosa and a number of villi from the duodenal region of a well-preserved human intestine. The villi are of columnar shape in the jejunum, and club-shaped in the ileum. The mucous membrane also forms permanent folds in both the duodenum and the remainder of the small intestine, the valvulæ conniventes (Kerkring). Upon these the villi rest, and, indeed, it is probable that the very existence of the plicæ is due to the blending of the basilar ends of the villi.

The epithelium of the intestinal mucous membrane covers the villi in a continuous layer, and penetrates into the mucosa to form the glands. Its structure is essentially the same in all regions of the small intestine, the cells being of the high columnar variety with free surfaces covered by wide, striated cuticular borders. The basilar portions of these cuticular borders are nearly always homogeneous, and upon vertical section give the appearance of a fine line. The cuticular borders of adjacent cells blend with each other, forming a continuous membrane, large areas of which may be detached from the villi (cuticula). The body of the cell consists of a fine fibrillar structure (spongioplasm) with the main threads parallel to long axis of the cell. This is more distinct in the free portions of the cell. In the interfibrillar substance are found fine granules. The nuclei lie usually in the basilar third of the cells, and only where they show mitoses, as, for instance, in the tubular intestinal glands, do they pass to the free ends of the cells. The basal ends of the epithelial cells in the small intestine are also seen to be pointed, and the probability is that they rest upon the basement membrane. The question has, however, not been fully settled.

The epithelial cells undergo a special metamorphosis, after which, by an increased production of mucus, they change into goblet cells. From recent investigations it would seem that any epithelial cell, whether it be situated upon the upper surface of a villus or deep down in one of the tubules of the intestinal glands, is capable of transformation into a goblet cell. The number of goblet cells is subject to great variation; they are found singly in small numbers, or are very numerous, according to the stage of digestion and quantity of food in the intestine. The manner in which an ordinary epithelial cell changes into a goblet cell is very easily explained if the mechanical action on the cell caused by an accumulation of secretion be taken into consideration. As the secretion increases in quantity the upper portion of the cell becomes distended, and the remains of the protoplasm, together with the nucleus, are pushed toward the narrow base of the cell; the cuticular zone is stretched, bulges into the lumen of the intestine, and is finally perforated, and perhaps even thrown off. In this way the cell loses its mucous secretion, collapses, and then appears as a thin, almost rod-like structure, with a long nucleus. It is the generally accepted theory that such an empty goblet cell may again assume the shape of an ordinary epithelial cell and repeat the process just described.

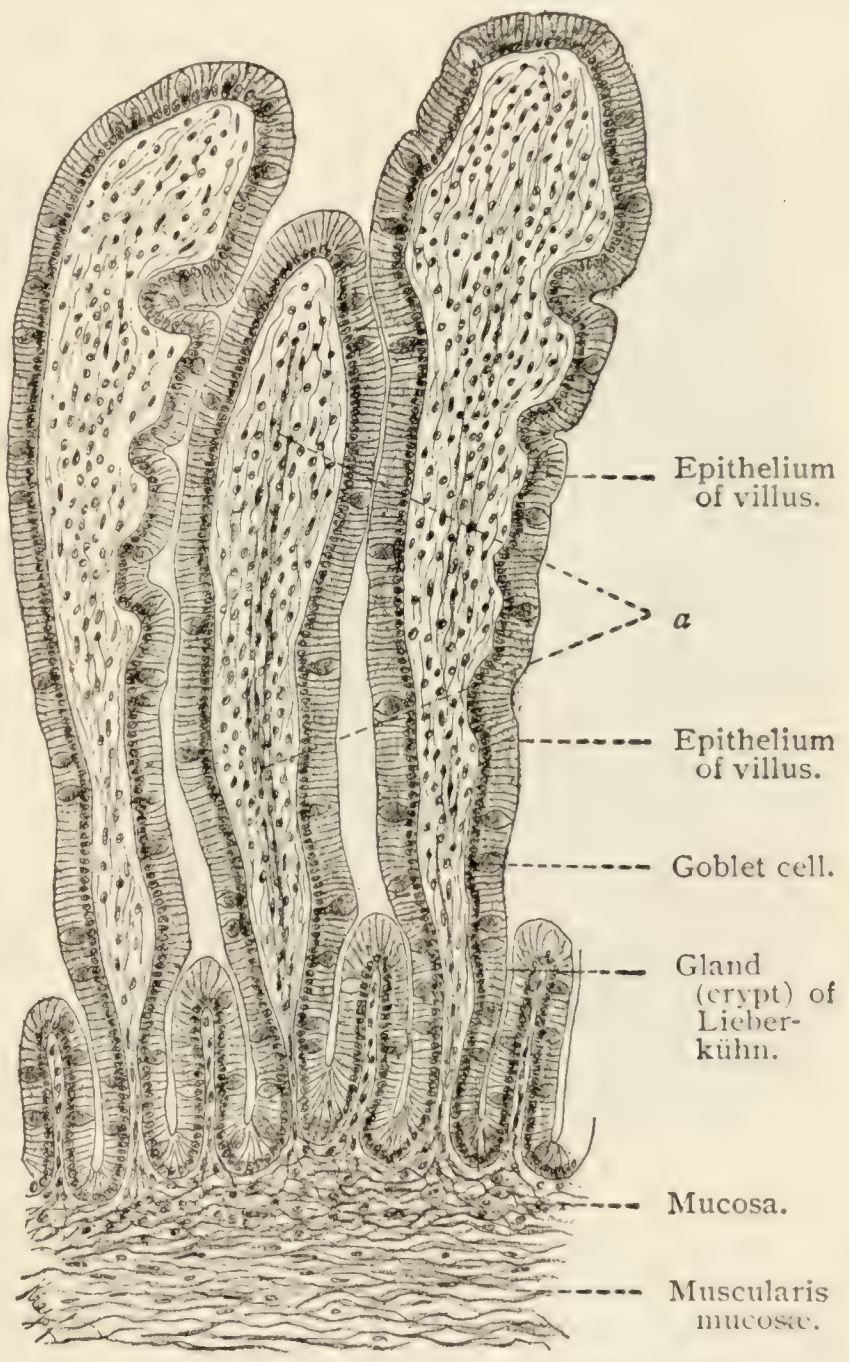

Fig. 216.—Section through mucous membrane of human small intestine; × 88. At *a* is a collapsed chyle-vessel in the axis of the villus.

Leucocytes are sometimes found within the epithelial cells, but more usually between them, and according to Stöhr (84, 89, 94), when seen in these positions, are in the act of migrating into the lumen of the intestine. That some of these cells actually pass into the lumen is probably true; but as yet no leucocytes have ever been observed in the cuticula itself, and neither is the number

of cells found in the lumen of the intestine proportionate to the leucocytes present in the epithelium. Since many are seen in the epithelium undergoing karyokinetic division, it is more probable that a part of them actually wander into the epithelium for the purpose of division (chemotaxis ?), only to return to the mucosa after the completion of the process (compare p. 61).

Into the spaces between the villi open numerous tubular glands. These are seldom branched, and are known as *Lieberkühn's glands*, or *crypts*. Their length varies from 320 μ to 450 μ. They are regularly arranged in a continuous row, and often have an ampulla-like widening of their lumina extending almost to the muscularis mucosæ, but never quite reaching it. They are uniformly distributed not only throughout the small intestine, but also throughout the large intestine and rectum. The cells lining the crypts of the small intestine are about one-half as long as those covering the villi; a cuticular border is seen on the cells lining the upper part of the glands, but is absent in the cells lining the fundus of the glands. The cells are conical in shape,—a condition probably due to the curvature of the glandular wall,—the base of each cone lying toward the basement membrane, the apex toward the lumen of the gland—a condition opposite to that found in the villi. Numerous goblet cells are also present. They vary only slightly in shape during mucous secretion, and do not, as in the villi, assume the form of goblets with distinct pedicles. Mitoses are always seen in the intestinal glands, especially in cells which do not contain mucin. They are readily distinguished, since the nuclei in process of division, as we have seen, lie outside of the row formed by the remaining nuclei. The plane of division in these cells lies horizontal to the long axis of the gland, so that an increase in the number of cells results in an increase in the area of the glandular walls. Mitoses are very rarely observed in the epi-

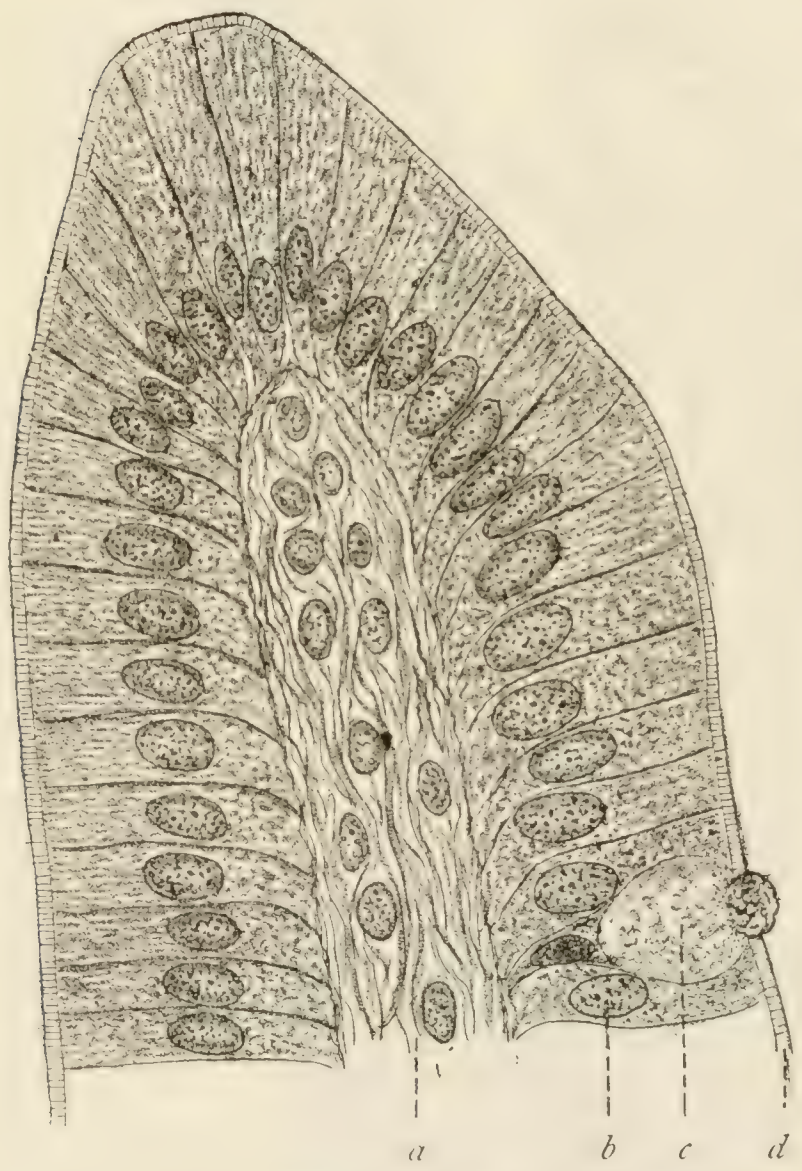

Fig. 217.—Longitudinal section through summit of villus from human small intestine; × 900 (Flemming's solution): At *a* is the tissue of the villus axis; *b*, epithelial cells; *c*, goblet cell; *d*, cuticular zone.

thelium covering the villi. If, therefore, any cells be destroyed on the surface of the villi, it must be assumed that the loss is replaced by new elements pushed up from the glands below (Bizzozero, 89, 92, I).

In the fundus of the crypts of Lieberkühn of the small intestine are also found a variety of cells first described by Paneth, and known as the cells of Paneth. These cells contain granules which stain readily in eosin and in iron-lac-hematoxylin, and are no doubt cells which contain zymogen granules, cells which elaborate an enzyme. In the opossum the cells of Paneth are found not only in the crypts but also in epithelium of the villi intermixed with the columnar cells and goblet cells (Sidney Klein).

The entire duodenum, as well as that part of the pylorus in the immediate vicinity of the pyloric valve, is characterized by the presence of glands of a second type. In the duodenum these are seen intermingled with the glands of Lieberkühn, and in the pylorus with the pyloric glands. These glands, *Brunner's glands*, have a diameter of from 0.5 to 1 mm., and are branched tubulo-alveolar glands, with tubules provided with alveoli, especially along their lower portions. The bodies of the glands are situated principally in the submucosa, although a part may be in the mucosa. In the stomach they open into the gastric crypts, in the intestine either independently between the villi, or into the glands of Lieberkühn. Here the glandular cells are in general similar to those of the pyloric glands, although, as a rule, somewhat smaller than the latter. The secretion of these glands is mucus (Bensley). Just as the duodenal glands extend into the stomach, so also the pyloric glands of the latter are found in the upper portion of the duodenum. Besides short villi, there are also present in the duodenum depressions of the mucous membrane analogous to the gastric crypts. The glands of Lieberkühn begin at a certain distance from the pylorus ; at first they are short, and do not attain their customary length until a point is reached at which the pyloric glands extending into the duodenum finally disappear (*vid.* Fig. 218). It is therefore obvious that a transition zone exists between pylorus and duodenum, and that a distinct boundary line can not be drawn between the two, at least so far as the mucous membrane is concerned. The duodenal glands, as their name would indicate, are present only in the duodenum. Between the jejunum and ileum there is no distinct boundary, not even when microscopically examined. The differences are mostly of a quantitative nature ; in the jejunum the valvulæ conniventes are more numerous than in the ileum, and the villi more slender and closer together. The glands of Lieberkühn also appear to be more numerous in the jejunum.

The mucosa of the small intestine consists of reticular adenoid tissue containing mononuclear lymphocytes, polymorphonuclear leucocytes, and leucocytes with granular protoplasm. It supports the glands and extends into the villi whose axes it

forms. The mucosa is separated from the glands, from the epithelium of the villi, as well as from that of the remaining surface of the intestine by a peculiar *basement membrane.*

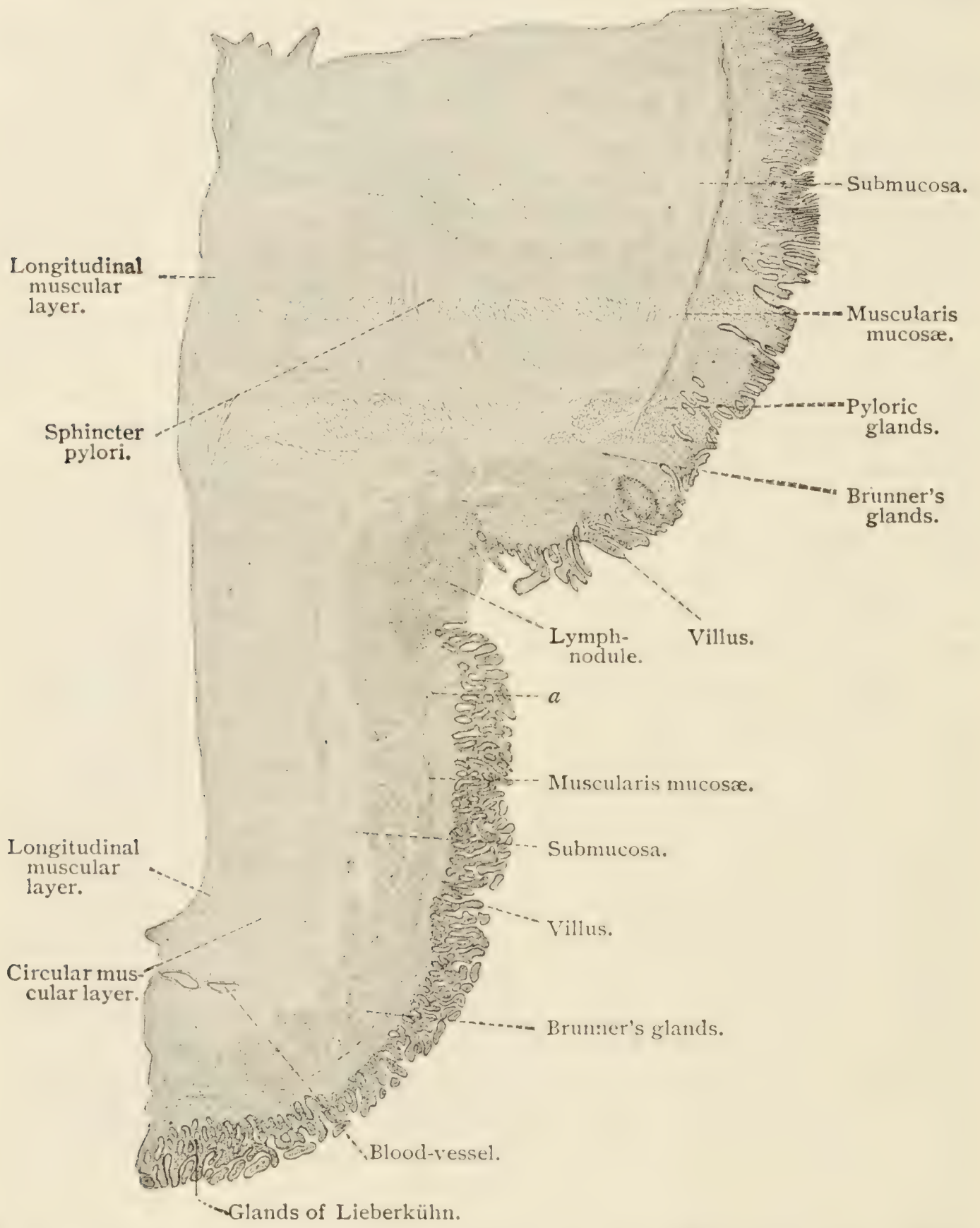

Fig. 218.—Section through the junction of the human pylorus and duodenum; × about 15: At *a* the pyloric glands extend into the duodenum.

The latter somewhat complicates a proper histologic analysis, and as a consequence opinions regarding its structure and significance vary considerably. By some it has been described as a homogeneous, hyaline, and exceedingly fine membrane containing nuclei, by others as a lamella consisting entirely of endothelial cells. At all events, there are certainly nuclei in the basement membrane. Beneath the basement membrane is a marginal layer of a more fibrillar character. This is closely associated with the mucosa, and

may be regarded as a differentiation of the latter. Toward the muscularis mucosæ the mucosa is terminated by a reticulated elastic membrane (F. P. Mall, in the dog), containing openings for the entrance of vessels, nerves, and muscle-fibers.

The *muscularis mucosæ* consists of two layers of unstriped muscular fibers arranged in a manner similar to that in the external muscular tunic—*i. e.*, having an inner circular and an outer longitudinal layer. The fibers are frequently gathered into bundles, which appear to be separated from each other by connective tissue. From both layers, but more especially from the inner, muscle-fibers are given off at right angles, which enter the tunica propria and pass between the glands of Lieberkühn, and even into the villi. In the latter these muscle-fibers are arranged in bundles, and lie

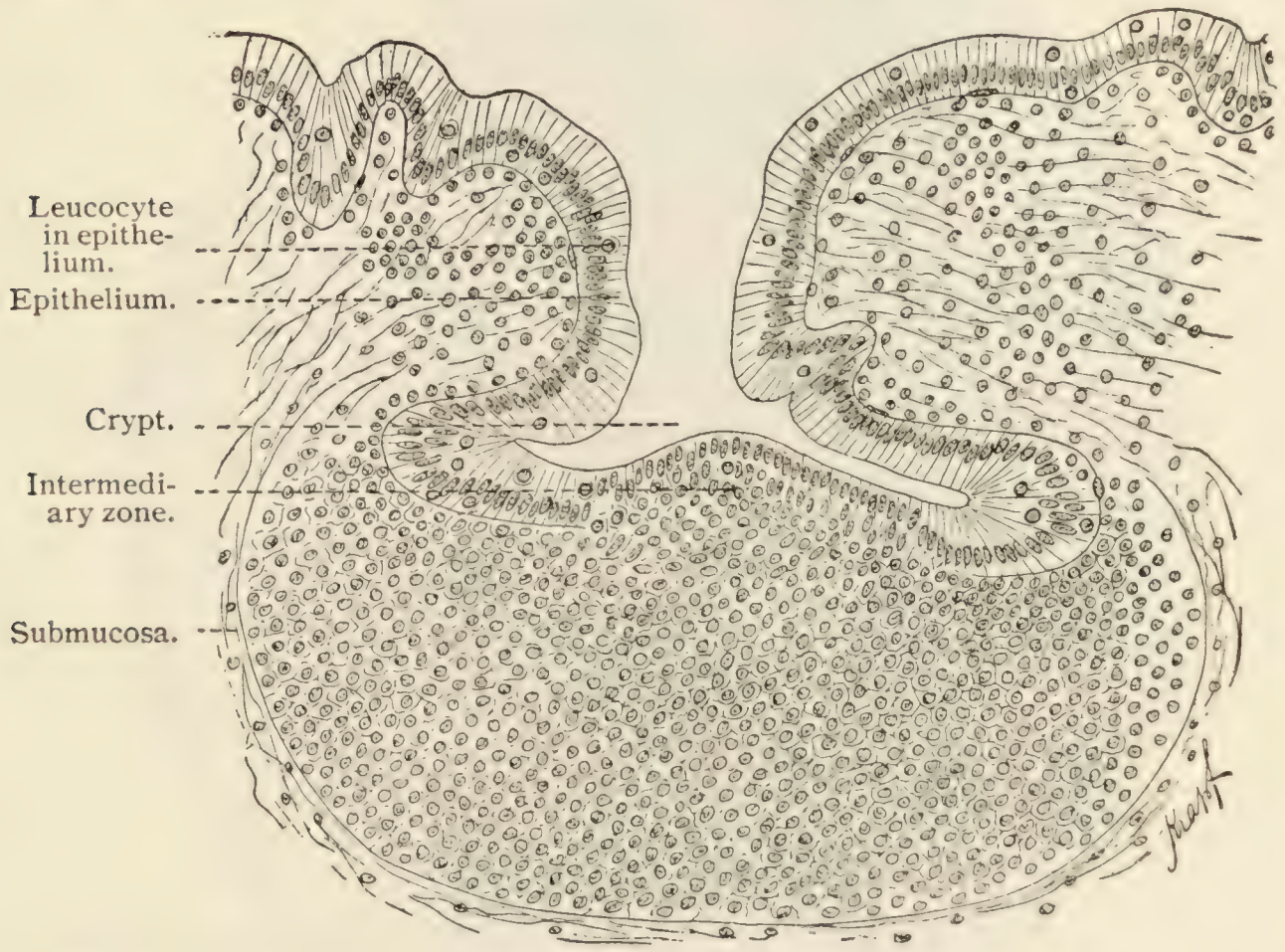

Fig. 219.—Section of solitary lymph-nodule from vermiform appendix of guinea-pig, showing crypt; × about 400 (Flemming's fluid).

near their axes around the lacteal vessels. The contraction of these fibers causes a contraction of the entire villus.

Lymph-nodules are distributed throughout the mucosa of the small intestine, occurring either singly, as solitary follicles, or aggregated, as Peyer's patches. At the points where they occur, the villi are absent and a lateral displacement of the glands of Lieberkühn is observed. The lymph-nodule is usually pyriform in shape. The thinner portion protrudes somewhat in the direction of the lumen of the intestine, while the thicker portion extends outward to the muscularis mucosæ, the latter being frequently indented or even perforated if the lymph-nodules be markedly developed. Their structure is similar to that of the lymph-follicles (see under these), and consists of reticular adenoid tissue, supporting

lymph-cells. It should be remembered that every nodule may possess a germ center. Peyer's patches are collections of these lymph-follicles. The surface of the nodule presenting toward the lumen of the intestine is covered with a continuous layer of intestinal epithelium. In man the summit of that portion of the

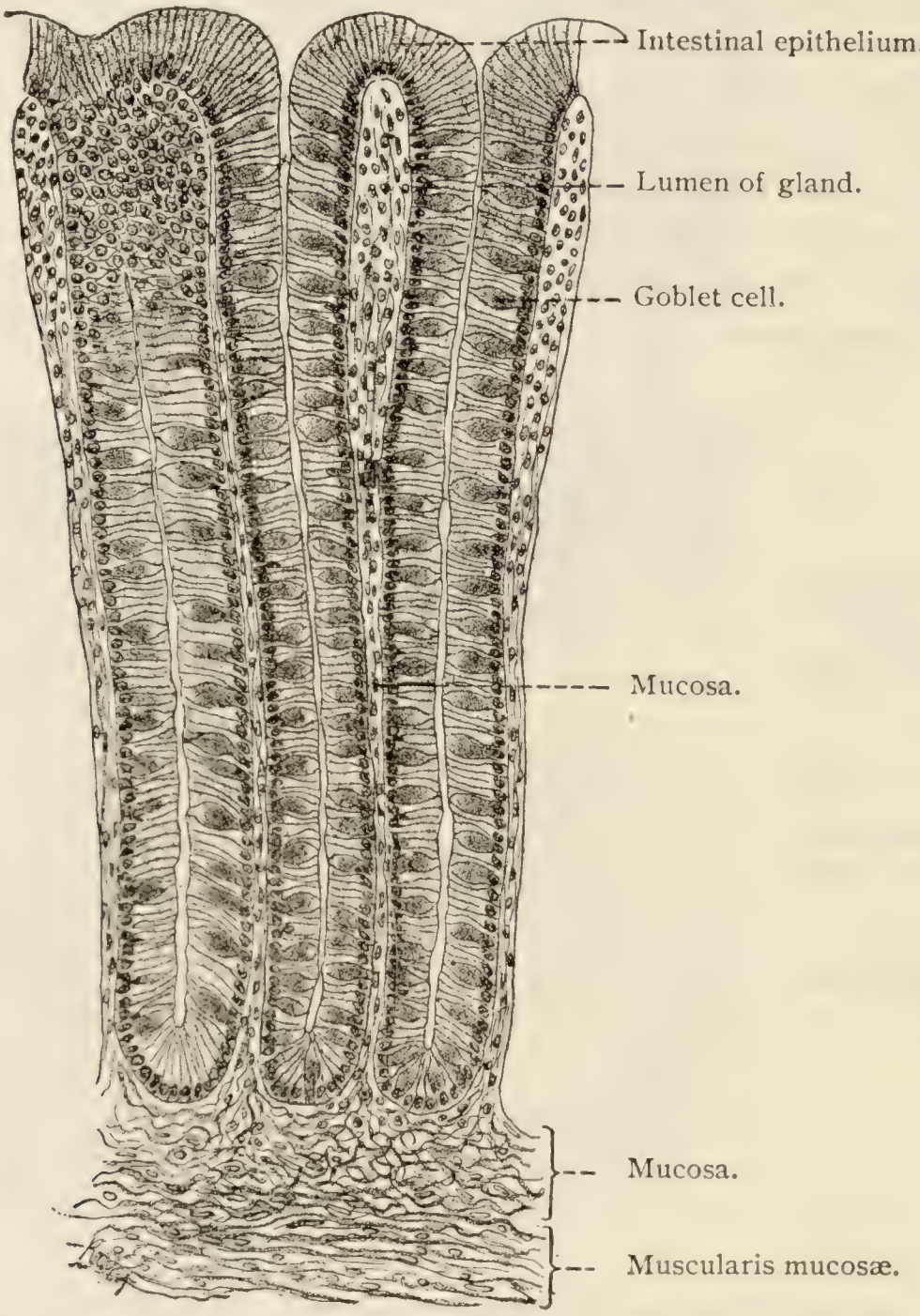

Fig. 220.—From colon of man, showing glands of Lieberkühn ; × 200.

nodule projecting into the lumen of the intestine presents but a slight depression of the intestinal epithelium, while in some animals (guinea-pigs), and especially in the nodules composing Peyer's patches, there is a deeper depression, even leading to the formation of a so-called "crypt" or "lacuna" (*vid.* Fig. 219). At the summit, the intestinal epithelium where it comes in contact with the lymph-nodule, is peculiarly altered. In most cases there is an absence of a basement membrane, the epithelium resting directly upon the lymphoid tissue. No clearly defined boundary between the two is distinguishable (intermediate zone of v. Davidoff); they are therefore in the closest relationship to each other. The basal surfaces of the epithelial cells are fibrillar, the fibrils seeming to penetrate into the adenoid reticulum of the follicles.

4. THE LARGE INTESTINE, RECTUM, AND ANUS.

The small intestine ends at the ileocecal valve. At some distance from the margin of the valve the villi of the ileum become broad and low. In the immediate vicinity of the valve their basilar portions become confluent, forming a honeycomb structure which supports a few villi. At the base of the honeycomb open the glands of Lieberkühn. On the cecal side of the valve the villi become fewer in number and finally disappear, while the folds which give the honeycomb appearance persist for a considerable distance. In

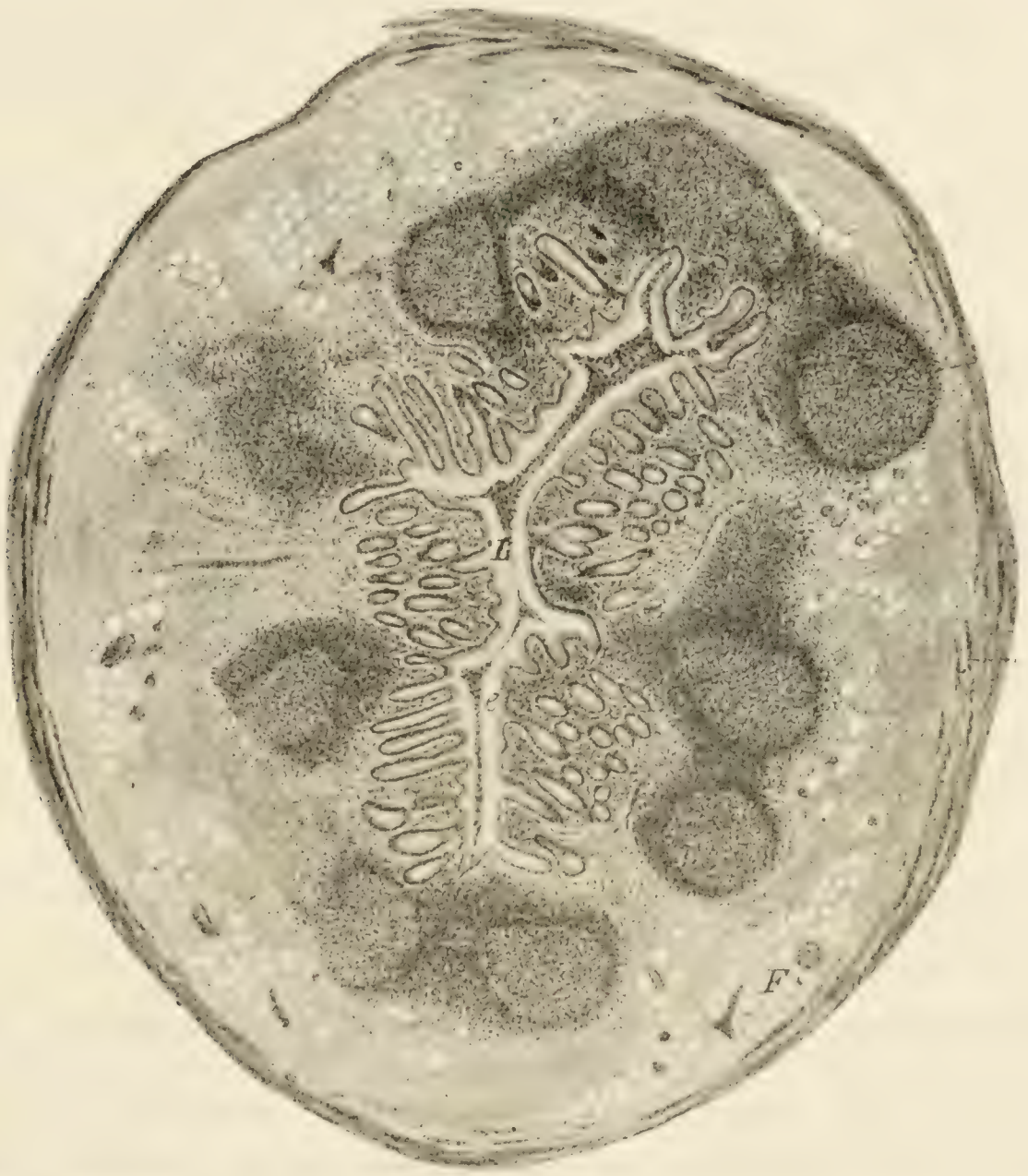

Fig. 221.—Transverse section of human vermiform appendix; × 20. Observe the numerous lymph nodules. The clear spaces in the submucosa are adipose tissue.

the adult cecum the villi are absent. The mucosa and glands present a structure similar to that of the remainder of the large intestine. In the mucosa of the *vermiform appendix* is found a relatively large number of solitary lymph-follicles, occasionally forming a continuous layer. The marked development of the lymph-follicles encroaches upon the glands of Lieberkühn, so that many are obliterated; they are penetrated by the adenoid tissue, the epithelial cells of the glands mingling with the lymph-cells. What finally becomes of the secretory cells has not been definitely ascertained (Rüdinger, 91).

In the colon the villi are wanting, while the glands of the mucosa are densely placed and distributed with regularity.

The glands of Lieberkühn in the colon are somewhat longer, and as a rule contain many more goblet cells than those in the small intestine. Only the neck and fundus of the glands show cells devoid of mucus. Transitional stages between the latter and the goblet cells have been observed in man (Schaffer, 91). Solitary lymph-follicles are found throughout the colon. They are situated in the mucosa, only the larger ones extending into the submucosa. The glands of Lieberkühn are displaced in the regions of the lymph-follicles.

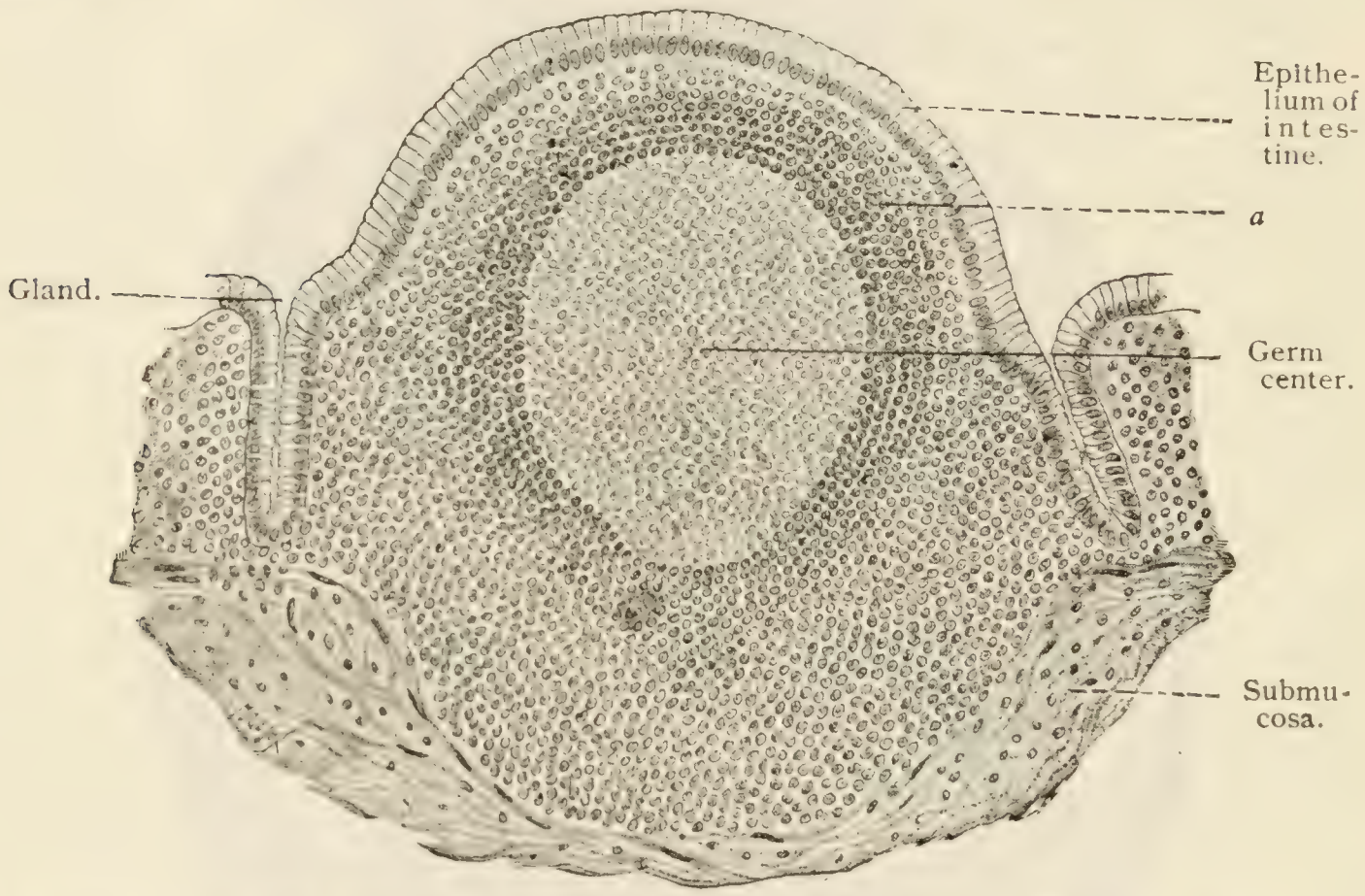

Fig. 222.—A solitary lymph-follicle from the human colon: At *a* is seen a pronounced concentric arrangement of the lymph-cells.

The *tæniæ* and *plicæ semilunares* cease at the sigmoid flexure, and are replaced in the rectum by the *plicæ transversales recti.* Permanent longitudinal folds, the so-called *columnæ rectales Morgagni,* are present only in the lower portion of the rectum. Here the intestinal glands are longest but disappear simultaneously with the rectal columns. At the anus the mucous membrane of the rectum forms a narrow ring devoid of glands, covered by stratified pavement epithelium, and terminating in the skin in an irregular line. The transition from the mucous membrane to the skin is gradual, yet reminding one of the appearance presented at the junction of the esophagus with the cardiac end of the stomach.

External to the anus, and at a distance of about one centimeter from it, are numerous highly developed sweat-glands, *the circumanal glands* of Gay, which are almost as large as the axillary glands; also sweat-glands of a peculiar type, in that they show a branching of the tubules (see Sweat-glands, under Skin).

5. BLOOD, LYMPH, AND NERVE SUPPLY OF THE INTESTINE.

In general, the following holds true with regard to the blood-vessels of the intestinal tract (further details will be discussed in dealing with the vessels of the various regions of the intestine): The arteries enter along the line of the mesenteric attachment and penetrate the longitudinal muscular layer. Between the two muscular layers branches are given off which form an intermuscular plexus, from which, in turn, smaller branches pass out to supply the muscles themselves. The arterial trunks penetrate the circular muscular layer and form an extensive network of larger vessels in the deeper layer of the submucosa. This is known as *Heller's plexus* (F. P. Mall). From this, radiating branches are

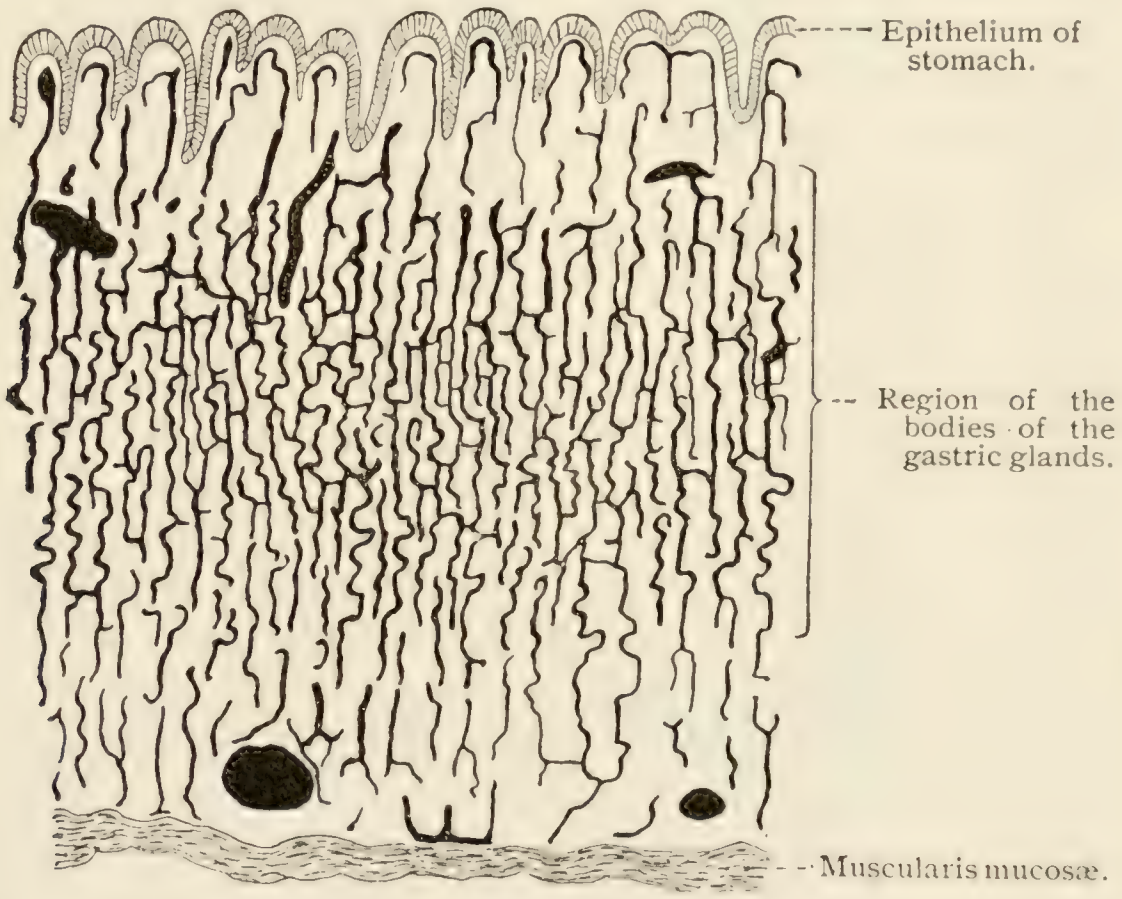

Fig. 223.—Section through fundus of cat's stomach. The blood-vessels are injected; × 60.

given off which supply the muscularis mucosæ, forming under the latter a close network of finer vessels. This plexus, together with that of Heller, gives rise to vessels which penetrate the muscularis mucosæ and break up into capillaries in the mucous membrane. The veins of the mucous membrane form beneath the muscularis mucosæ a plexus with small meshes, giving off many radiating branches; these in turn unite to form an extensive network of coarser vessels. Veins extend from the latter and unite to form larger trunks, which then lie side by side with the arteries. According to F. P. Mall, delicate retia mirabilia occur here and there in the venous network in the submucosa of the intestine of the dog.

In the esophagus the arteries end in a capillary network situated

in the mucosa and extending into the connective-tissue papillæ of the mucosa.

The vessels of the stomach are arranged in plexuses in the muscular coat, submucosa, and beneath the muscularis mucosæ, as previously described. From the plexus beneath the muscularis mucosæ, small branches are given off which pass through this layer and in the mucosa form a capillary network, consisting of relatively small capillaries, which surround the gastric glands, this plexus being particularly well developed in the region around the body and neck of the glands, where the parietal cells are most numerous. The capillaries of this network are continuous with capillaries of a much larger size, forming a network surrounding the gastric crypts and situated immediately under the epithelium lining the mucosa of the stomach. The blood is collected from this capillary plexus by small veins which pass nearly perpendicularly through the mucosa, forming a plexus above the muscularis mucosæ, from which small veins pass through the muscularis mucosæ to the venous plexus in the submucosa.

The blood-vessels of the mucosa of the small intestine may be divided into (1) the arteries of the villi and (2) the arteries of the intestinal glands. The former arise principally from the deep arterial network in the submucosa, then penetrate the muscularis mucosæ and give off branches at acute angles which continue without further branching into the summits of the villi. Within the villi themselves the arteries lie in the axes. The broader villi may contain two arteries. The circular muscle-fibers of the arteries gradually disappear inside of the villi (dog), and at the summit of the latter the vessels break up into a large number of capillaries. These form a dense network extending beneath the basement membrane and into its marginal layer. These networks give rise to venous capillaries which unite to form small vessels and finally end in two or more larger veins inside of the villi. These latter are connected with the venous network in the mucosa.

The glandular arteries, derived principally from the superficial network of the submucosa, also pass through the muscularis mucosæ and break up internally into capillary nets which encircle the intestinal glands; these give rise to small veins which empty into the venous plexus of the mucosa. The veins of the plexus in the mucosa unite to form larger branches, which connect with the plexus in the submucosa (compare Fig. 224). In the dog these trunks inside of the muscularis mucosæ are encircled by bundles of muscle-fibers (sphincters, F. P. Mall). The capillaries of the solitary lymph-nodules do not always penetrate into the centers of the latter, but often leave a central nonvascular area.

The blood-vessels of the mucosa of the large intestine are, in their distribution, similar to the glandular vessels of the small intestine and stomach.

The lymph-vessels begin in the mucosa near the epithelium, pass

down between the glands, and are arranged in the form of a network just above the muscularis mucosæ, but with coarser meshes than that formed by the blood-vessels. Here the valves begin to make their appearance. The lymph-vessels pass through the muscularis mucosæ and in the outer portion of the submucosa form a plexus with open meshes, from which are derived the efferent vessels which penetrate the muscular coat and thus gain access to the mesentery. In their course through the muscular coat they communicate with the branches of a plexus of lymph-vessels situated between the two muscular layers, and also with lymph-vessels found in the serous coat.

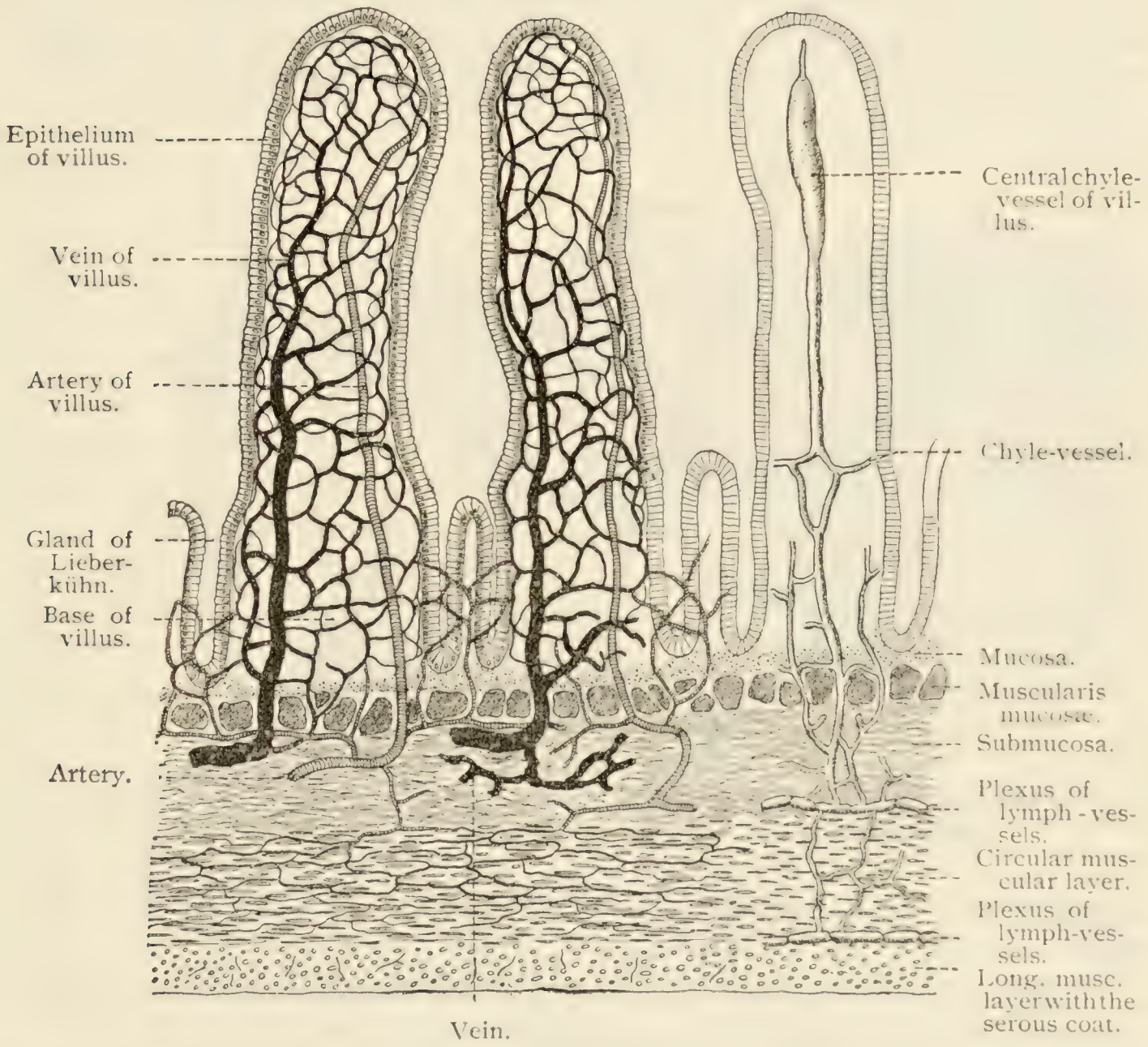

Fig. 224.—Schematic transverse section of the human small intestine (after F. P. Mall).

The lymphatics of the small intestine begin in the axes of the villi. When filled, these lymph-vessels are conspicuous, irregularly cylindric capillary tubules, lined by endothelial cells, and known as the *axial canals*, the *chyle-vessels*, or the *lacteals* of the villi. They are hardly discernible when collapsed. If the villus be broad, it may contain two chyle-vessels, which then join at the apex of the villus, and may also be connected with each other by a few anastomoses. At the base of the villus the chyle-vessel enters a lymphatic capillary network, the structure of which is due to the confluence

of similar canals. Numerous lymph-vessels from this network penetrate the mucous membrane in a vertical direction, uniting at the bases of the intestinal glands to form a second plexus—subglandular plexus of the mucosa. A few of the lymph-vessels penetrating the mucous membrane directly perforate the muscularis mucosæ to join the lymphatic network of the submucosa. The subglandular plexus also communicates with the submucous lymphatic plexus by means of small radiating branches (*vid.* Fig. 224). The solitary lymph-nodules themselves contain no lymphatic vessels, but are encircled at their periphery by a network of lymph capillaries. The same is true of the nodules in Peyer's patches. It is an interesting fact that in the rabbit lymph-sinuses exist around Peyer's patches, giving to the latter a still greater similarity to the nodules of lymph-glands. The solitary nodules of the same

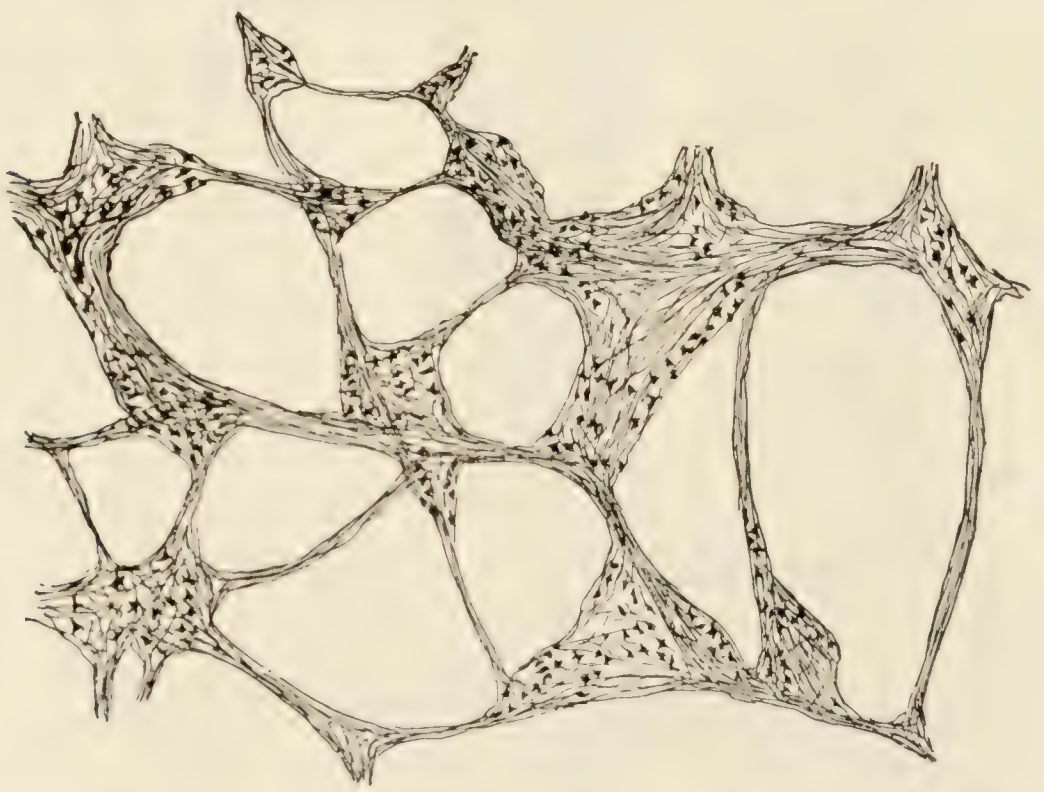

Fig. 225.—A portion of the plexus of Auerbach from stomach of cat, stained with methylene-blue (*intra vitam*), as seen under low magnification.

animal are not surrounded by the sinuses just mentioned (Stöhr, 94).

The structures of the alimentary canal receive their innervation mainly from sympathetic neurones, the cell-bodies of which are grouped to form small ganglia, located at the nodal points of two plexuses, one of which is situated between the two layers of the muscular coat, the other in the submucosa. These two plexuses are found in the entire digestive tract, although not equally well developed in its different regions. The outer plexus, the more prominent of the two, situated between the two layers of the muscular coat, is known as the *plexus myentericus*, or the *plexus of Auerbach.* It consists of innumerable small sympathetic ganglia, united by small bundles of nonmedullated fibers, containing here and there a much smaller number of medullated nerve-fibers. The cell-bodies of the sympathetic neurones of this plexus are grouped to form the

sympathetic ganglia. The dendrites, the number of which varies for the different cells, divide and redivide in the ganglia, some extending into the nerve bundles uniting the ganglia. The neuraxes of the sympathetic neurones of the ganglia form nonmedullated nerve-fibers, which leave the ganglia by one of the several roots possessed by each ganglion, and, after repeated division and forming intricate plexuses in the circular and longitudinal layers of the muscular coat, terminate on the involuntary muscle-cells of these layers.

The plexus in the submucosa, known as the *plexus of Meissner*, is similarly constructed, although it contains fewer and much smaller ganglia and the meshes of the plexus are much finer. It communicates by numerous anastomoses with the plexus of Auerbach. The neuraxes of the sympathetic neurones of this plexus have not been traced, with any degree of certainty, to their terminations. Numerous nonmedullated nerves enter the muscularis mucosæ and, according to Berkley (93, I), form in the dog terminal bulbs and nodules which perhaps represent the endings of motor (sympathetic) nerves in this layer. Nerve-fibers have also been traced into the mucosa, and in the vicinity of the glands and in the villi are found numerous exceedingly fine nerve-fibers which interlace, but in the greater portion of the intestinal tract the endings of these fibers have not been fully worked out. That they end on the gland-cells seems very probable from observations made by Kytmanow (96), who was able, by means of the methylene-blue method, to stain plexuses of fine nerve-fibrils surrounding the gastric glands of the cat, some of these fibrils being traced through the basement membrane of the glands and to and between the gland-cells, where they terminated in clusters of small nodules on both the chief and parietal cells. The plexus of Meissner is not so well developed in the esophagus as in the remaining portions of the digestive tract.

Fig. 226.—From thin section of esophagus of cat, showing the epithelium and a portion of the mucosa and the terminal nerve-fibrils in the epithelium (from preparation of Dr. DeWitt).

That the cell-bodies of many of the sympathetic neurones of Auerbach's and Meissner's plexuses are capable of being stimulated by cerebrospinal nerves seems certain from observations made by Dogiel (95), who has shown that many small medullated nerve-fibers which enter the digestive tract through the mesentery (small and large intestines) terminate after repeated division in terminal end-baskets which surround the cell-bodies of many of the sympathetic neurones of these plexuses. Similar nerve-fibers ending in

baskets have also been observed in the ganglia of the plexuses of the stomach and esophagus. Large medullated nerve-fibers, the dendrites of sensory neurones, have also been traced to the alimentary canal. In the esophagus these pass to the mucosa, where, after repeated division, they lose their medullary sheaths, the non-medullated terminal branches forming a subepithelial plexus from which terminal, varicose branches, further dividing, enter the stratified epithelium and may be traced to near the surface of the epithelium.

Large medullated nerve-fibers may be traced through the ganglia of Auerbach's and Meissner's plexuses in the stomach and intestinal canal and through the nerve bundles uniting these ganglia (Dogiel, 99), but the termination of these fibers has not been determined. In the large intestine of the cat they have been traced to the epithelium and between the epithelial cells covering the mucosa (Huber).

6. THE SECRETION OF THE INTESTINE AND THE ABSORPTION OF FAT.

The cells of Brunner's glands are similar in many respects to those of the pyloric glands. They form, as has been shown, a mucous secretion, and present in their various physiological activities, structural changes which are similar to the structural changes presented by the cells of other mucous glands under similar conditions (Bensley). It is well known that the goblet cells of the intestinal glands are very numerous during starvation, and that they nearly disappear after continued functional activity; furthermore, they entirely disappear in certain portions of the rabbit's intestine after pilocarpin-poisoning. It would therefore appear that the principal physiologic function of the glands of Lieberkühn is to secrete mucus, although the possibility of the production of another secretion, especially in the small intestine, must not be excluded (compare R. Heidenhain, 83), especially since it has been shown that the cells of Paneth probably elaborate an enzyme.

Until recently it was believed that the fat contained in the food was emulsified in the intestine, and furthermore that the bile acted upon the cuticular margins of the epithelial cells in the villi in such a manner that an assimilation of the emulsified fat by the cells of the villi (not by the goblet cells) was made possible. It has been repeatedly observed that the epithelial cells contained fat granules during absorption. Hence a mechanism was sought for which would account for an assimilation of globules of emulsified fat on the part of the cells. It seemed most probable that protoplasmic threads (pseudopodia) were thrown out from each cell through its cuticular zone, which, after taking up the fat, withdrew with it again into the cell. But when it was shown that, after feeding with fatty acids or soaps, globules of fat still appeared in the epithelial cells as before, and that the chyle also contained fat, the hypothesis was

suggested that the fat is split up by the pancreatic juice into glycerin and fatty acids, and that the fatty acids are then dissolved by the bile and the alkalies of the intestinal juice, only again to combine with the glycerin to form fat within the epithelial cells. It remains for the histologist to ascertain the exact mechanism in the cell which changes the fatty acids into fat. Altmann (94) claims that certain granules of the cells (elementary organisms) offer a solution to this problem. The manner in which the fat globules gain access to the lacteal vessels of the villi is a question which has not as yet been settled definitely; it would appear, however, that the leucocytes play an important part in this transfer, since in preparations of the intestinal mucosa, taken from an animal fed on a diet rich in fat—milk diet—and stained in osmic acid, numerous leucocytes containing black granules or globules may be observed in the lacteal vessels and in the spaces of the adenoid reticulum of the villi.

D. THE LIVER.

In the adult the liver is a lobular, tubular gland with anastomosing tubules. When viewed with the unaided eye or under low magnification the liver is seen to be composed of a large number

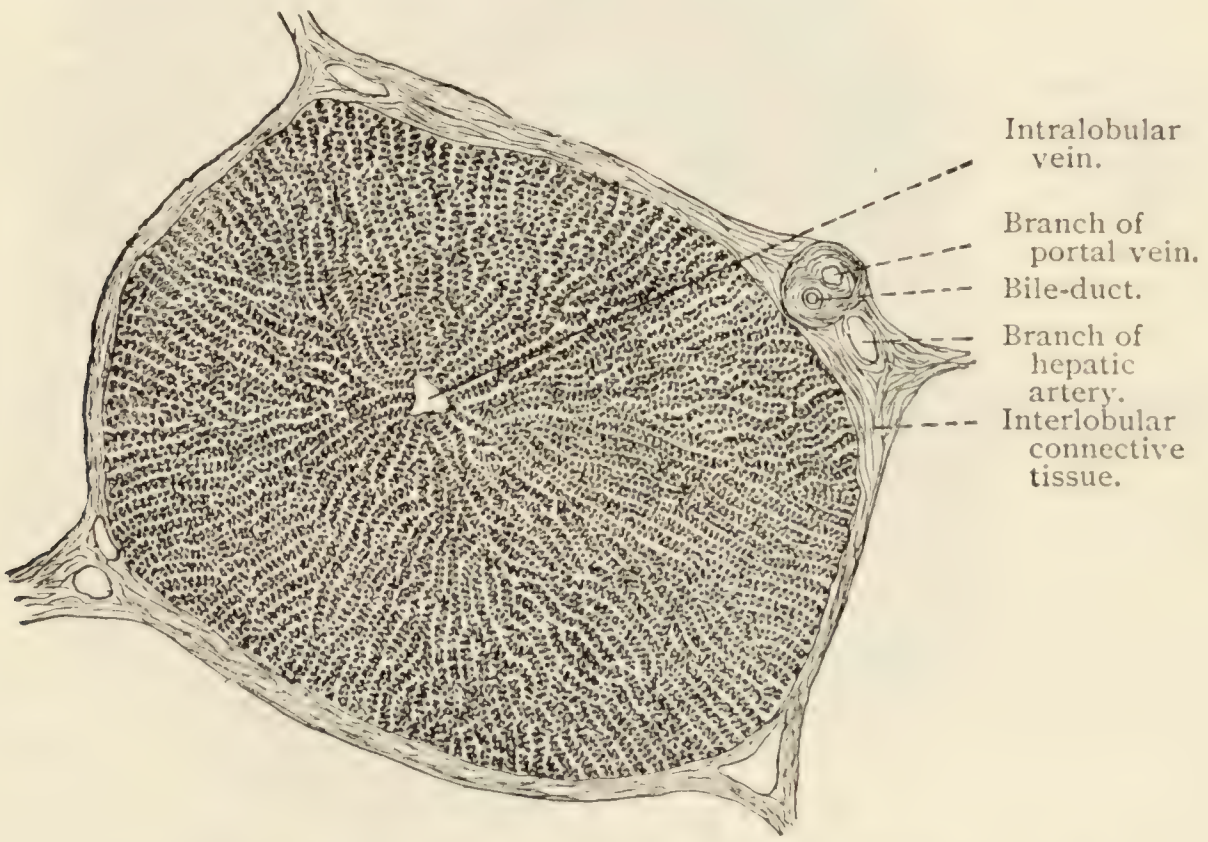

Fig. 227.—Section through liver of pig, showing chains of liver-cells; × 70.

of nearly spheric divisions of equal size; this is particularly noticeable in some animals, especially in the pig. These divisions are the *liver lobules* and have a diameter of from 0.7 to 2.2 mm. They are separated from each other by a varying amount of interlobular connective tissue, which is a continuation of the *capsule of Glisson*, a fibro-elastic layer surrounding the entire liver and covered for the greater portion by a layer of mesothelium. In the interlobular septa are found the larger blood-vessels, bile passages, nerves and

lymph-vessels. On examining a thick section of the liver with a low power, a radiate structure of the lobule is noticeable, and an open space is seen in its center, which according to the direction of the section, is either completely surrounded by liver tissue or connected with the periphery of the lobule by a canal. This open space represents the *central* or *intralobular vein* of the lobule which belongs to the system of the inferior vena cava. From the center of the lobule toward its periphery extend numerous radiating strands of cells, which branch freely and anastomose with each other, and are known as the *trabeculæ*, or *cords of hepatic cells*. Between the latter are small, clear spaces occupied partly by blood capillaries and partly by the intralobular connective tissue. The above description is in some respects not a true statement of the appearance presented by the human liver, as in the latter one or more lobules may blend with each other, thus rendering the individual lobules less distinct.

The *hepatic cords* consist of rows of hepatic cells. The cells

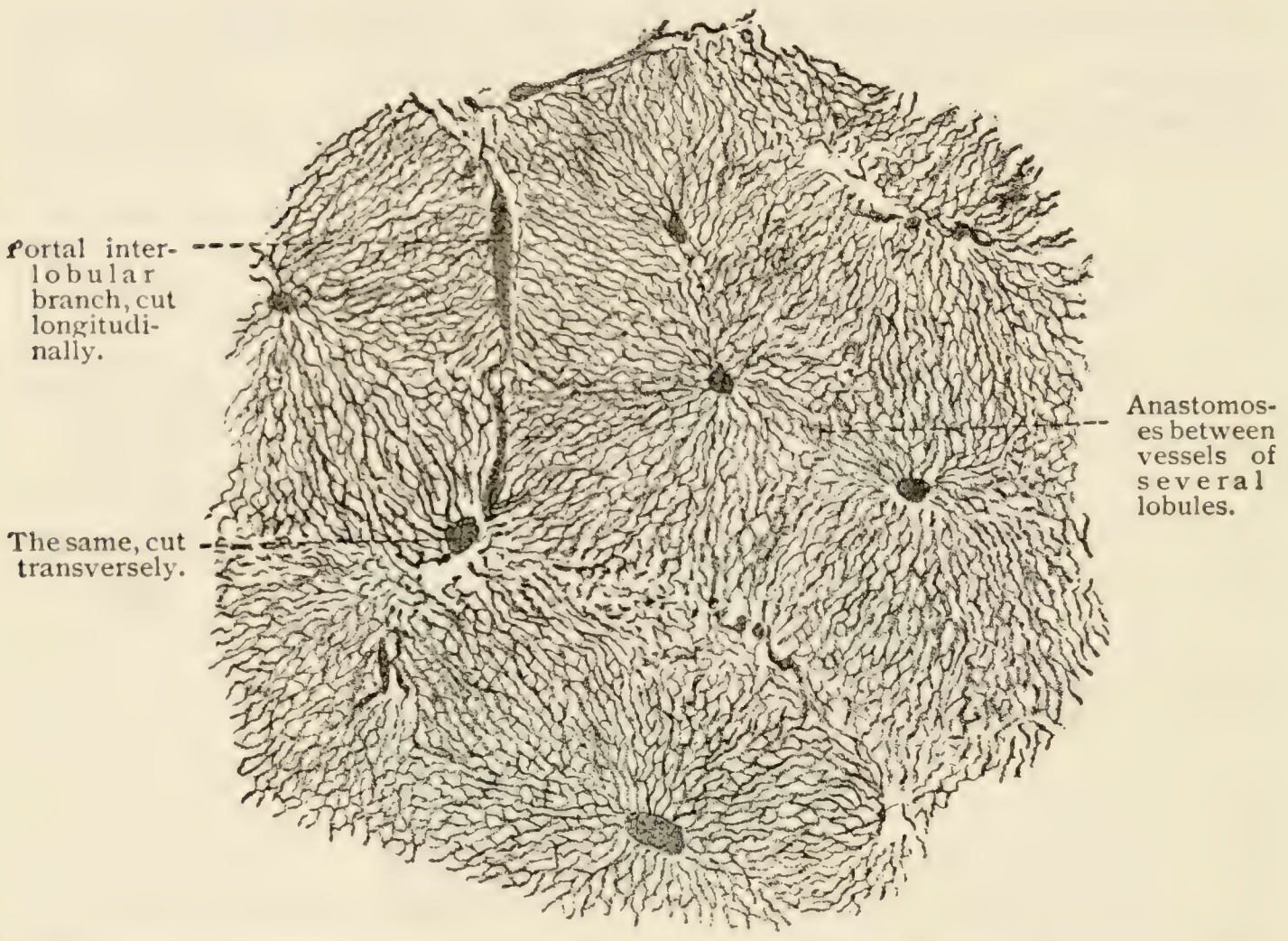

Fig. 228.—Section through injected liver of rabbit. The boundaries of the lobules are indistinct; × about 35.

are usually polyhedral in form, with surfaces so approximated that a cylindric capillary space, known as the *bile capillary* remains between them. The angles of the cells also show grooves which join those of the neighboring cells to form canals in which lie the blood capillaries. A closer examination of the hepatic cells reveals the fact that they possess no distinct membrane, and, in a resting state, usually contain a single nucleus, although some possess two. It is an interesting fact that nearly all the hepatic cells of some

animals—as, for instance, the rabbit—contain two nuclei. The cell-bodies of the hepatic cells, which average from 18 μ to 26 μ in diameter, show a differentiation into protoplasm and paraplasm. This is especially manifest in a state of hunger. In this condition it is seen that the network of protoplasm around the nucleus is unusually dense, and becomes looser in arrangement as it extends toward the periphery of the cell-body. The paraplasm is slightly granular, and contains glycogen and bile drops during the functional activity of the cell (secretion vacuoles). The vacuoles in the paraplasm play an important part in the secretion of the cell, and are

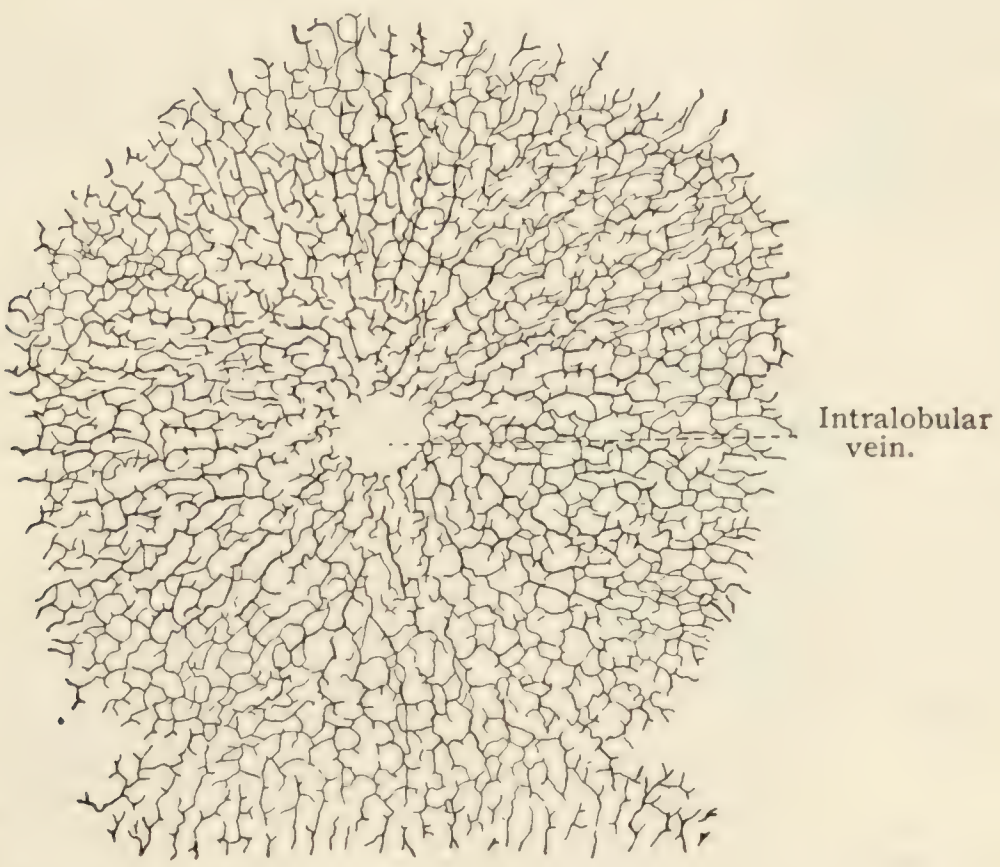

Fig. 229.—Human bile capillaries. The capillaries of one lobule are seen to anastomose with those of the adjoining lobule (below, in the figure); × 110 (chrome-silver method).

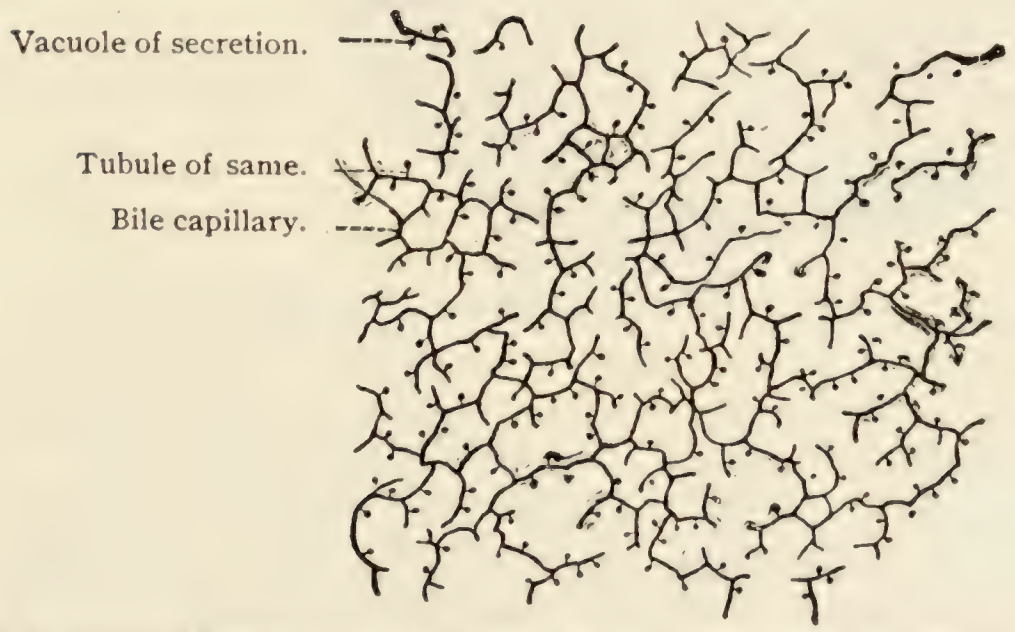

Fig. 230.—Human bile capillaries as seen in section; × 480 (chrome-silver method).

due to the confluence of minute drops of bile into a large globule. As soon as the vacuole has attained a certain size it tends to empty

its contents into the bile capillary through a small tubule connecting the vacuole with the bile capillary (Kupffer, 73, 89).

The *bile capillaries* are, as we have remarked, nothing but tubular, capillary spaces between the hepatic cells, with no distinct individual walls, although the outer portions of the liver cells (exoplasm) are somewhat denser than the remainder of the cells, and serve to form a wall for the bile-capillaries. They may be compared to the lumen of a tubular gland, although in the human liver their walls consist of only two rows of hepatic cells. In the lower vertebrates the walls of the bile capillaries appear in transverse section to consist of several cells (in the frog generally three, in the viper as many as five). The bile capillaries naturally follow the course of the hepatic cords—*i. e.*, in man extending radially. They form networks, the meshes of which correspond to the size of the hepatic cells. At the periphery of the lobule the hepatic cells pass directly over into the epithelial cells of the smaller interlobular bile-ducts. The epithelium of the latter is of the cubical variety, its cells being considerably smaller than the hepatic cells. At the point where the hepatic cells become continuous with the walls of the smaller passages we find a few cells of gradually decreasing size which represent a transition stage from the cells of the bile capillaries (hepatic cells) to those of the interlobular bile passages.

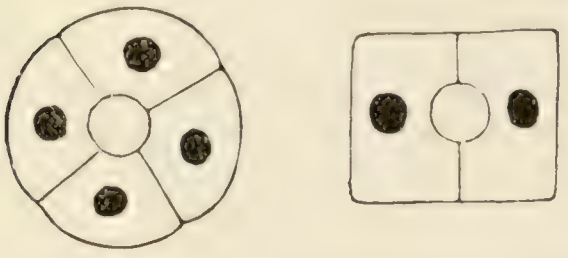

Fig. 231.—Schematic diagram of hepatic cord in transverse section. At the left the bile capillary is formed by four cells, at the right by two; the latter type occurs in the human adult.

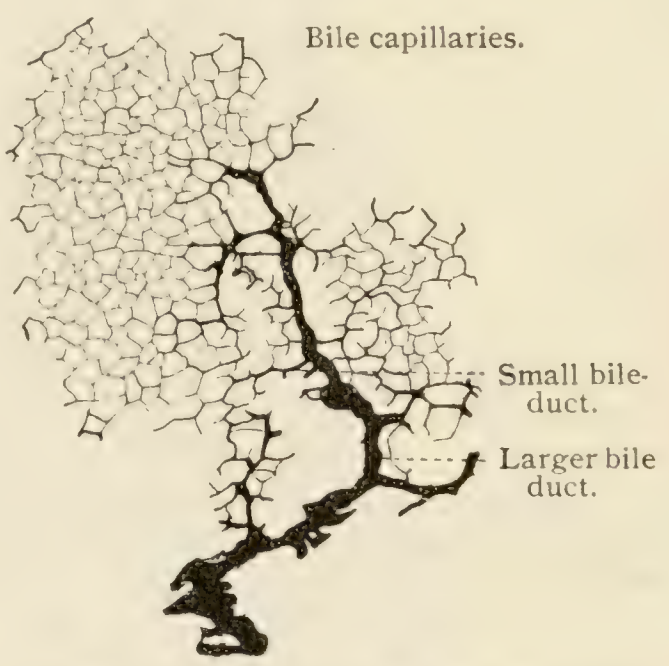

Bile capillaries.

Fig. 232.—From the human liver, showing the beginning of the bile-ducts; × 90 (chrome-silver).

The vascular system of the liver is peculiar in that, besides the usual arterial and venous vessels common to all organs, there is found another large afferent vein—the *portal vein.* It arises from a confluence of the superior and inferior mesenteric, the splenic, coronary veins from the stomach, and cystic veins. It divides into two branches, the right supplying the right lobe of the liver, the left the remaining lobes. These branches again divide into numerous smaller branches, the smallest of which finally reach the individual lobules. Along its whole course through the inter-

lobular connective tissue the portal vein and its branches are accompanied by divisions of the hepatic artery and bile passages. In a transverse section of the liver the arrangement of these structures in the interlobular tissue is such that the cross-sections of the vessels belonging to the hepatic vein are seen to be at some distance from the closely approximated branches of the portal vein and bile passages. Branches of the portal vein encircle the liver lobules at different points, and while they remain within the interlobular connective tissue, are known as *interlobular veins*. From these, small offshoots are given off to the lobules which, on entering, divide into capillaries and form a closely reticulated network between the hepatic cords. The meshes of this network are about as large as an hepatic cell, each cell coming in repeated contact with the blood capillaries. All of these capillaries pass toward the central or intralobular vein of the lobule, which during its efferent passage through the lobule continues to receive capillaries from the portal

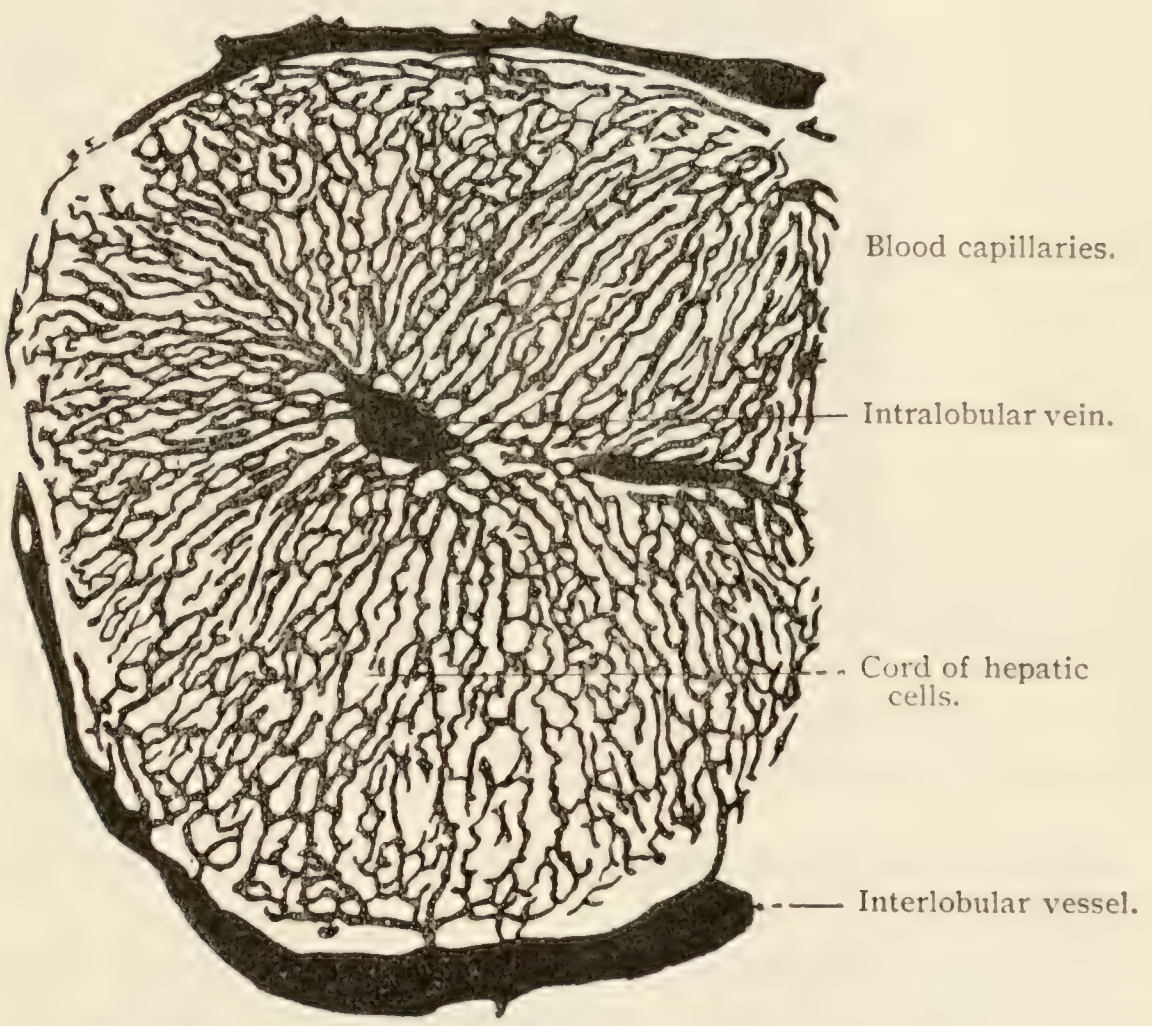

Fig. 233.—Injected blood-vessels in liver lobule of rabbit; × 100.

system. The intralobular veins unite to form the sublobular veins, situated in the interlobular connective tissue, and these unite to form the larger hepatic veins which empty into the inferior vena cava. The *hepatic artery* is of much smaller size than the portal vein. It is distributed in the main to the connective tissue of the liver and to the bile-ducts, breaking up into branches which are situated in the interlobular connective tissue. The terminal capillaries form small venules which communicate with the interlobular

branches of the portal system. Whether the capillaries of the hepatic artery pass as such into the hepatic lobules is difficult to say, since injection masses forced into the hepatic artery pass over into the terminal branches of the portal vein and vice versa. This question needs, therefore, further investigation. The smaller divisions of the hepatic artery constitute, therefore, internal radicals of the portal vein, since they are within the liver itself. The relations of the various blood-vessels within the lobule are in themselves somewhat difficult of comprehension, but the whole becomes still more complicated when the reciprocal relations of the vessels and bile capillaries are taken into consideration. In order to understand the structure of the liver lobule, with its hepatic cords, vessels, and bile capillaries, the following points should be borne in mind : The course of the bile capillaries is along the surfaces, and that of the blood-vessels along the angles of the hepatic cells ; every cell comes in contact with a bile capillary and a blood

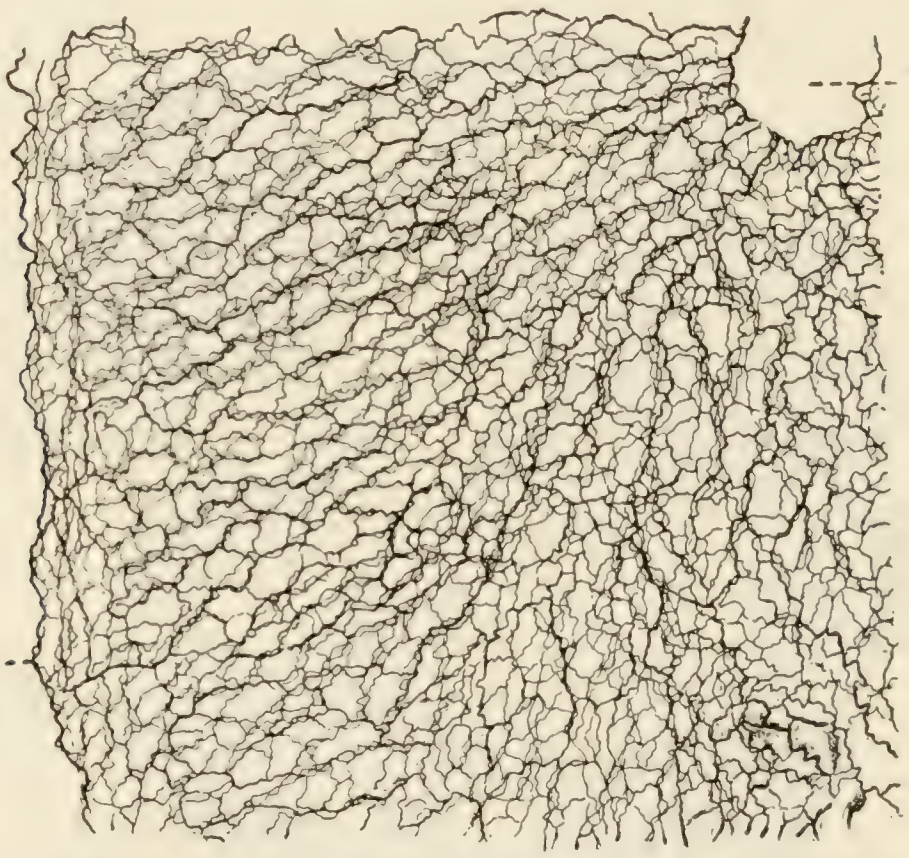

Fig. 235.—Reticulum (Gitterfasern) of dog's liver; × 120 (gold-chlorid method).

capillary. The latter, however, do not come in contact with the former, but in man are separated by at least half the breadth of a hepatic cell. In animals in which the bile capillaries are bounded by more than two cells, the blood-vessels extend along the outer sides of the hepatic cells ; here the bile and blood capillaries are separated from each other by the breadth of a whole cell.

The connective tissue within the hepatic lobules presents points of interest which, however, are not demonstrable in organs treated by ordinary methods. But when the liver tissue is treated by a certain special method (see page 307), an astounding number of fibers are seen extending in regular arrangement from the periphery toward the central vein. These fibers are extremely delicate, of nearly

equal size, and intermingle in such a manner as to form an enveloping network about the blood capillaries (Gitterfasern ; Kupffer ; Oppel, 91 ; *vid.* Fig. 235). A few coarser fibers (radiate fibers, Kupffer, 73) seem to enter in a less degree into the formation of the sheath around the blood capillaries ; they also extend from the periphery toward the center of the lobule and form a coarse reticulum, the meshes of which are drawn out radially. The radiate fibers are less prominent in man, but are numerous and well developed in animals (rat, dog). With what exuberance the intralobular connective tissue may develop, is seen in the accompanying sketch of a sturgeon's liver, which is taken from one of Kupffer's prepara-

Fig. 236.—Connective tissue from liver of sturgeon. At *a* is an open space from which the hepatic cells were mechanically removed during treatment.

tions. The Gitterfasern of Kupffer are, as has been shown by F. P. Mall, reticular fibrils, presenting the same characteristics as similar fibrils found in other regions.

Certain peculiar cells—the so-called *stellate cells* of Kupffer (76)—occur in the lobule, and are seen only after a special method of treatment. They are uniformly distributed, of different shapes, elongated, and end in two or three pointed projections. They are smaller than the hepatic cells, and contain one or two nuclei.

In a recent communication Kupffer (99) states that the stellate cells belong to the endothelium of the intralobular capillaries of the portal vein. These capillaries, which are, according to their development, sinusoids (Minot), form in all probability a syncytial lining (Kupffer) consisting of thin continuous lamellæ, the protoplasm appearing as a network of threads, with nucleated masses of protoplasm at nodal points of this network. In places where this protoplasm is present in larger quantity and contains round or

oval nuclei it is more readily brought out with special stains, and appears in such preparations in the form of structures to which the name stellate cells has been given. In such cells blood corpuscles and fragments of such were often found. The endothelium of these capillaries possesses, therefore, a phagocytic function, taking up particles of foreign matter, blood-corpuscles, etc.

The efferent ducts of the liver, the *bile-ducts*, are lined by columnar epithelium, varying in height in direct proportion to the caliber of the passage. The smallest ducts possess a low, the medium sized a cubical, and the larger a columnar epithelium. The smaller bile-ducts have no clearly defined external walls other than the membrana propria; the larger ones, on the other hand, possess a connective-tissue sheath which may even present two layers in the larger passages. Unstriped muscular fibers occur in the large

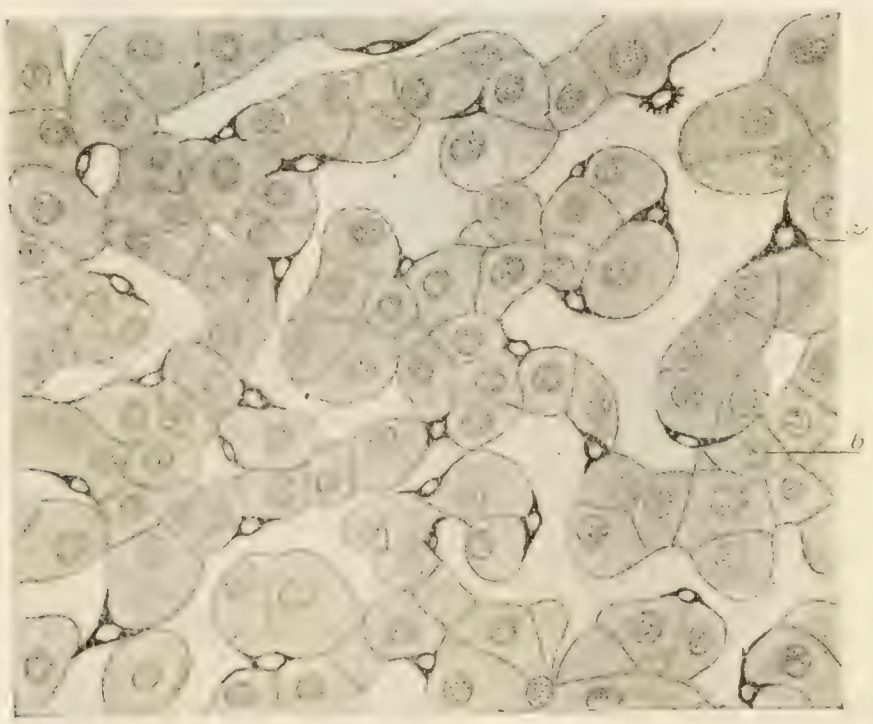

Fig. 237.—From preparation from the liver of a rabbit, showing the so-called stellate cells of Kupffer: *a*, Stellate cells; *b*, liver cells.

ducts, and also small mucous glands. The gall-bladder consists of a mucous, fibro-muscular, and, where covered by the peritoneum, of a subserous and serous coats, as has recently been shown by Sudler, whose account is here followed.

The mucous coat is covered by a single layer of columnar epithelium, with nuclei situated in the basal portions of the cells. The epithelial cells rest on a poorly developed muscularis mucosæ. The mucosa presents folds, covering ridges of connective tissue of the fibro-muscular layer, and contains small lymph-nodules, and a varying number of small mucous glands. The fibro-muscular layer consists of interlacing bands of nonstriated muscle and fibrous connective tissue, and is not arranged in distinct layers. The subserous and serous coats present the same appearance as in other regions of the peritoneum. The artery or arteries going to the gall-bladder divide into branches which form capillaries in the mucosa under the epithelium; these are most numerous in the

folds above mentioned. The lymphatics form a subserous and submucous plexus.

The *lymphatics* accompany the portal vein and hepatic artery, also the branches of the hepatic vein (Wittich). They form a network in the interlobular connective tissue. The lymphatics form further a superficial network in subserous layer of the peritoneum. The superficial lymphatics and the lymphatics accompanying the vessels are in communication.

Within the lobules, the lymphatics occur as perivascular spaces, as was first shown by MacGillavry. F. P. Mall, who has recently studied the origin of the lymphatics in the liver, summarizes his results as follows: The lymphatics of the liver arise from perilobular lymph-spaces, and these communicate directly with perivascular lymph-spaces; the lymph reaches these spaces by a process of filtration through openings which are normally present in the capillary walls of the liver.

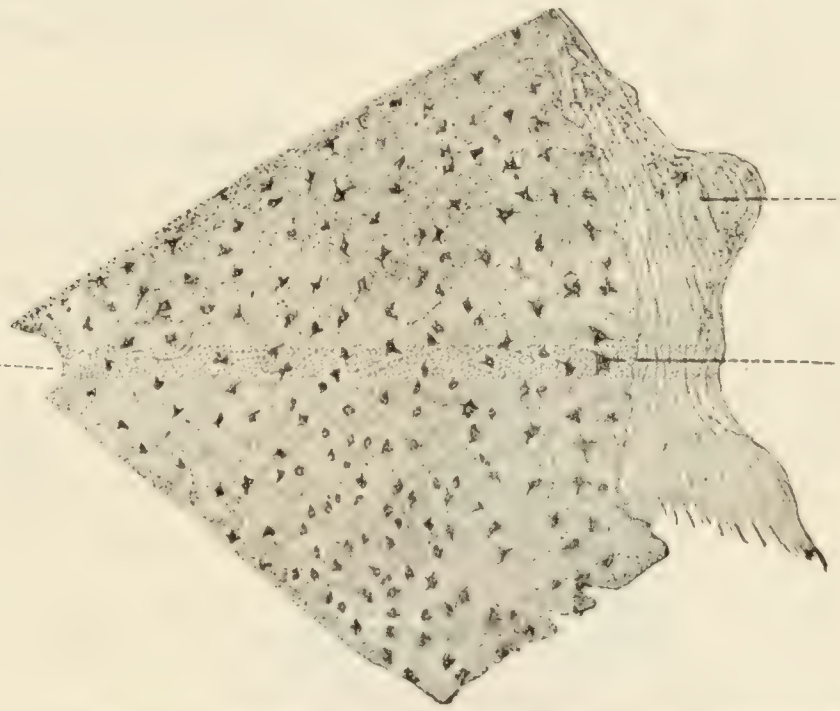

Fig. 238.—Part of a section through liver lobule from dog, showing stellate cells; × 168.

Berkley (94) has described several divisions of the intrinsic nerves of the liver, all connected and morphologically alike. These nerves are no doubt the neuraxes of sympathetic neurones, the cell-bodies of which are located in ganglia outside of this organ. No medullated fibers were found by him, although it seems probable that the nerve-fibrils terminating between the cells of the bile-ducts (see below) are terminal branches of sensory nerve-fibers. The nerves of the liver accompany the portal vessels, the hepatic arteries, and the bile-ducts. The first division of the nerves, embracing the larger number of the intrinsic hepatic nerves, accompany the branches of the portal vessels, form plexuses about them, and end in interlobular and intralobular ramifications, the latter showing here and there knob-like terminations on the liver-cells, and, in their course, give off here and there branches which end on the portal vessels.

The nerve-fibers following the hepatic arteries are in every respect like the vascular nerves in other glands. Some of the terminal branches seem, however, to end on hepatic cells. The nerve-fibers following the bile-ducts may be traced to the smaller and medium-sized ducts, forming a network about them, and ending here and there in small twigs on the outer surface of the cells, and occasionally, it would seem, between the epithelial cells lining the ducts. The suggestion seems warranted that these terminal fibrils are the endings of sensory nerves. Some of the nerve-fibers following the bile-ducts may be traced into the hepatic lobules. The intralobular plexus is formed, therefore, by the terminal branches of the non-medullated nerve-fibers accompanying the portal and hepatic vessels and the bile-ducts. In the wall of the gall-bladder are found numerous small sympathetic ganglia formed by the grouping of the cell-bodies of sympathetic neurones (Dogiel). The neuraxes of these innervate the nonstriated muscle of this structure. Large, medullated nerve-fibers may be traced through these ganglia which appear to end in free sensory endings in and under the epithelium lining the gall-bladder (Huber).

In the human embryo the liver originates from the intestine during the second month as a double ventral diverticulum. Later solid trabecular masses are developed which then unite and become hollow. At this stage the whole gland is uniform in structure, as a division into lobules does not take place until later. The bile capillaries are surrounded by more than two rows of cells. In this stage the embryonal liver suggests a condition which is permanent during the life of certain animals. Only later when the venæ advehentes, which later represent the branches of the portal vein, penetrate the liver, is there a secondary division into lobules (about the fourth month), by which process the primitive type gradually changes to that characteristic of the adult.

E. THE PANCREAS.

Like the liver, the pancreas is an accessory intestinal gland, and originates as a diverticulum of the intestine. It remains in permanent communication with the intestine by means of its duct—the *pancreatic* or *Wirsungian duct*. The pancreas is composed of numerous microscopic lobules, surrounded by connective tissue which penetrates into the lobules and between the alveoli and is accompanied by vessels and nerves. The secretory portion of the organ may be regarded as a compound, branched alveolar gland, the general structure of which is shown in Fig. 240, the alveoli forming the principal portion of the gland. The epithelial walls of the alveoli consist of a number of secretory cells, whose appearance varies according to the functional state of the organ. The basilar portions of the cells present

a homogeneous protoplasm, while those parts of the cells bordering upon the lumen are granular. The relation of these zones to

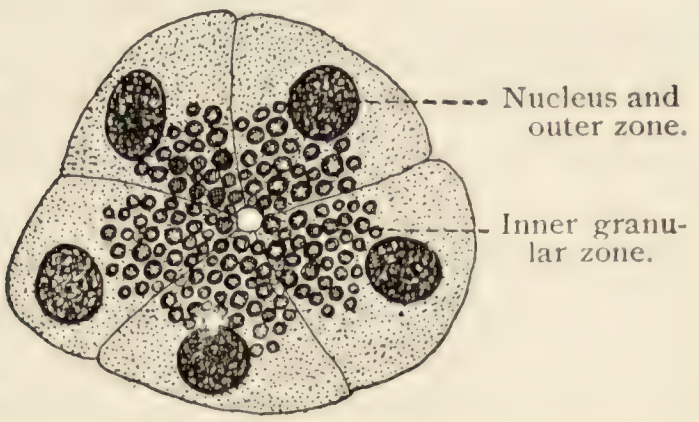

Fig. 239.—Transverse section through alveolus of frog's pancreas.

each other depends upon the physiologic condition of the gland; during starvation the internal or granular zone is wide and prominent; after moderate secretion the cells become as a whole somewhat smaller, the granules decrease in number, and the outer or protoplasmic zone increases in size. After prolonged secretion there is an entire absence of the granules, and the whole cell apparently consists of homogeneous protoplasm. It is therefore probable

Fig. 240.—Model of lobule of human pancreas (Maziarski, "Anatomische Hefte," 1901).

that during a state of rest peculiar granules (zymogen granules) are formed at the expense of the protoplasm, and that these granules represent a preliminary stage of the finished secretion. During the

functional activity of the gland the granules gradually disappear, while the fluid secretion simultaneously makes its appearance in the lumen, although the granules have as yet never been observed in the lumen itself. After secretion the cell grows again until it reaches its original size, only again to begin the formation of zymogen granules. Whether the cells of the gland are destroyed or not during secretion is still a matter of uncertainty, but does not seem probable.

An *intermediate tubule* similar to those of the salivary glands connects with each alveolus, and then passes over into a short *intralobular duct.* This is lined, as in the salivary glands, with columnar epithelial cells, which are not, however (at least in man), striated at their basal ends. The intralobular ducts merge

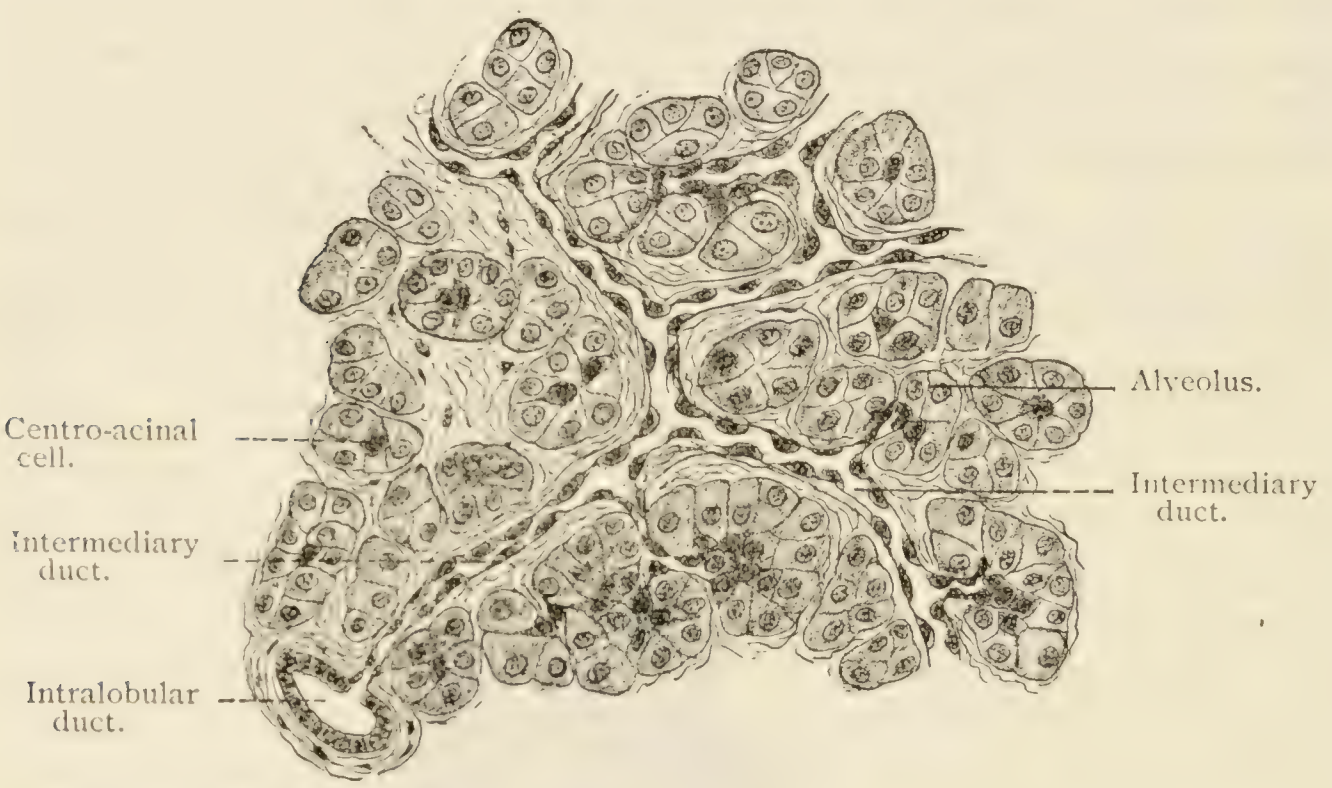

Fig. 241.—From section through human pancreas ; × about 200 (sublimate).

into excretory ducts, which finally empty into the pancreatic duct. The epithelium of the excretory ducts is simple columnar in type. Goblet cells are seen only in the pancreatic duct.

In the secreting alveoli small protoplasmic, polygonal, and even stellate cells are often seen, the so-called *centro-acinal cells*, or *cells of Langerhans.* The significance of these structures is not fully understood. Langerhans himself supposed that they belonged to the walls of the excretory ducts. This interpretation seems warranted by the fact that it has been found that the secreting cells of the alveoli are directly joined to the low cells of the intermediate tubules. When the alveoli lie closely packed together, the adjoining intermediate tubules fuse and are reduced to one or, at most, a few cells. As a result a condition is seen within the alveolar complexus, especially when the excretory ducts are in a collapsed state, closely resembling the structures seen by Langer-

hans. Peculiar cells, wedged in here and there between the secretory cells, but resting on the membrana propria, have also been observed. They undoubtedly are sustentacular cells of the gland (cuneate cells, Podwyssotzki, 82).

The *membrana propria* of the alveoli is probably homogenous. Immediately adjoining it is another delicate but firm membrane, consisting of fibrils whose structure in many respects resembles that of the reticular fibers (Gitterfasern) in the liver and spleen, but which are here in relation to the alveoli (Podwyssotzki, 82).

In warm- and cold-blooded animals, groups of cells differing in arrangement, size, and structure from the secretory cells, are found among the gland tubules and alveoli of the pancreas; these are known as the *intertubular cell-masses*, or *areas of Langerhans*. They are most numerous in the splenic end of the pancreas (Opie). They

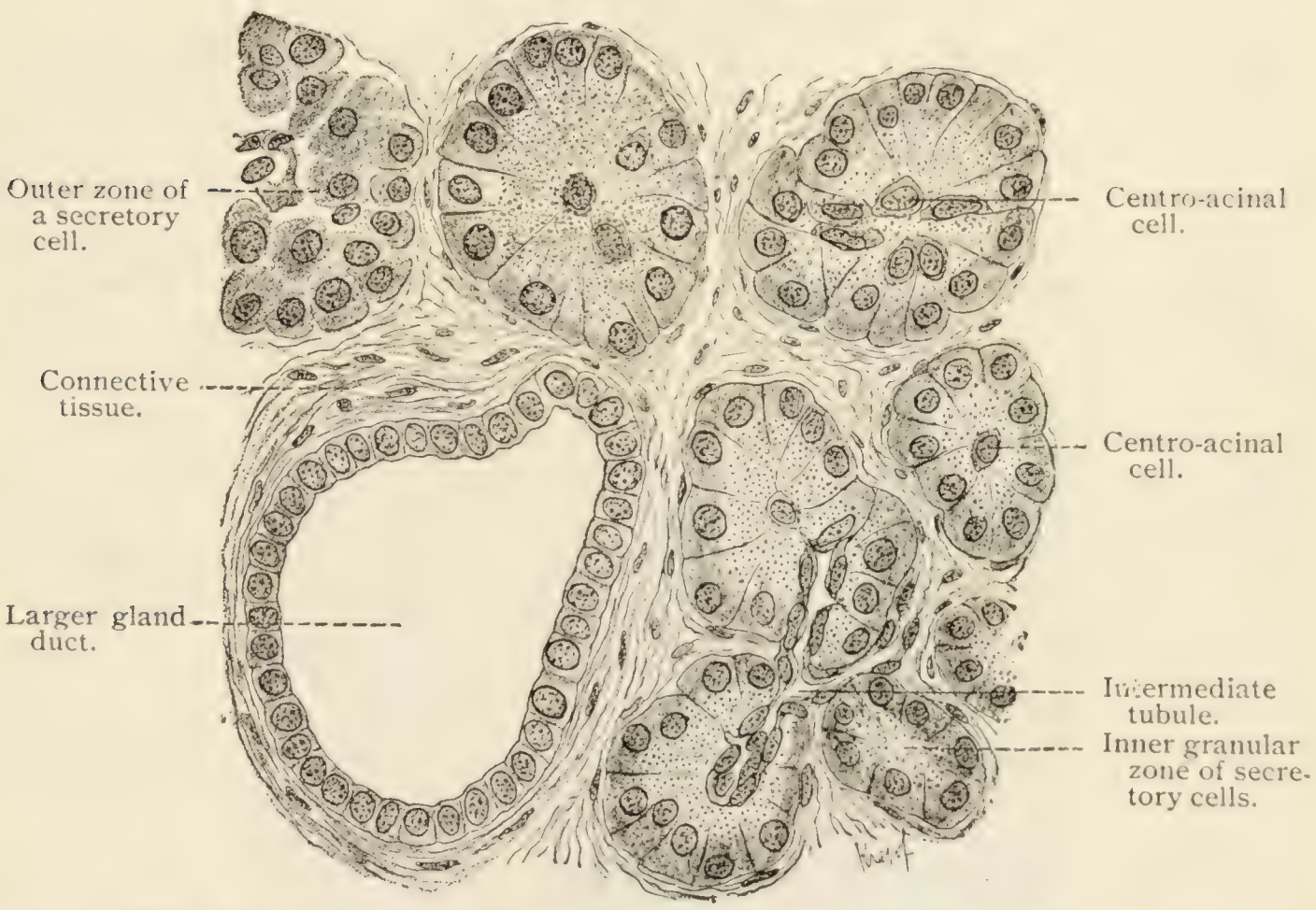

Fig. 242.—From section through human pancreas; × 450 (sublimate).

consist of slightly granular cells, smaller than the secretory cells of the alveoli, arranged in the form of anastomosing trabeculæ, with irregular spaces, varying in size, separating the trabeculæ. Dogiel (93) has shown that in a well-preserved human pancreas treated by the chrome-silver method, in which the gland ducts even to their finest intra-alveolar branches were well stained, no ducts were found in the areas of Langerhans. Such areas are, in the human pancreas, usually separated from the surrounding gland tissue by a small amount of connective tissue. They possess a blood supply, consisting of relatively large capillaries found in the spaces formed by the trabeculæ of cells above mentioned. The areas of Langerhans have been variously interpreted. They have been looked upon as small areas of gland tissue in process of degeneration, or

again as areas of embryonic gland tissue. From their structure and distinct blood supply, and the fact that no ducts have been traced into these areas, it seems probable that they are small masses of cells forming a secretion which passes into the blood-vessels—internal secretion.

The blood-vessels after entering the gland, divide into smaller branches in the lobules, and finally break up into capillaries which

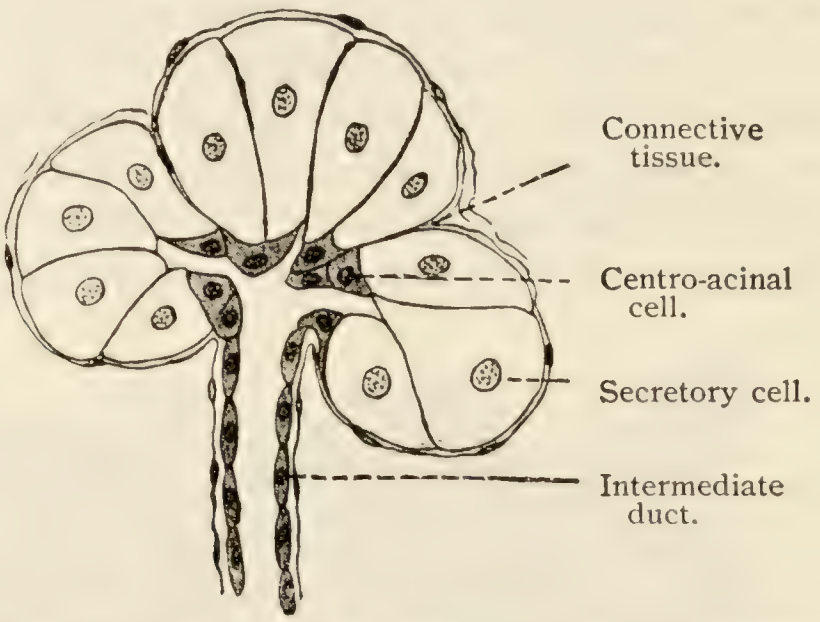

Fig. 243.—Scheme showing relation of three adjoining alveoli to excretory duct, illustrating origin of centro-acinal cells.

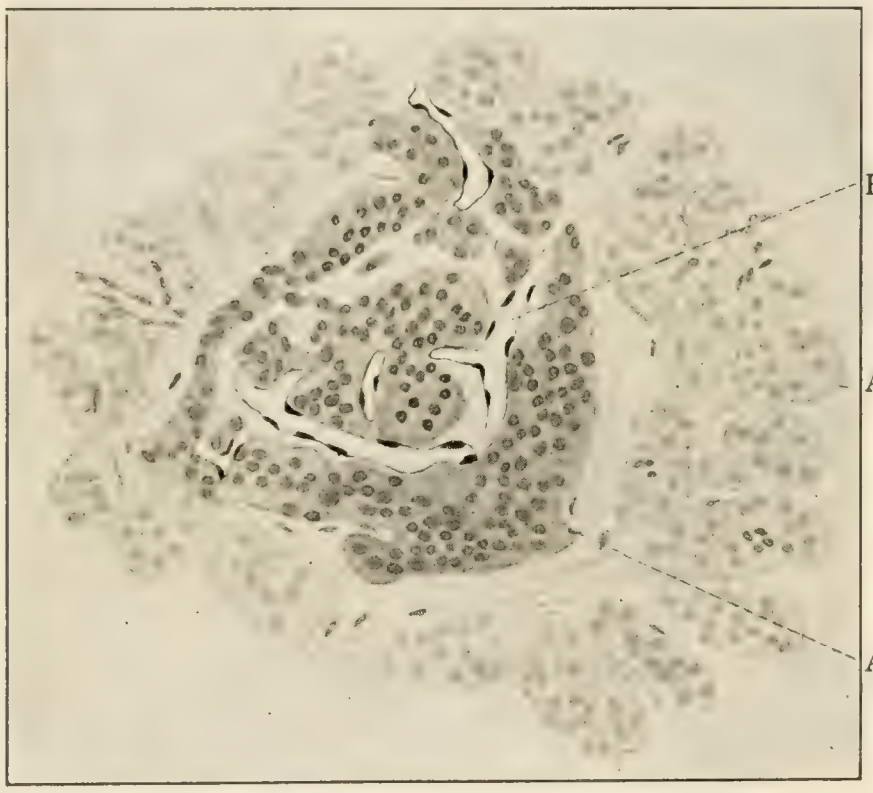

Fig. 244.—From section of human pancreas, showing gland alveoli surrounding an area of Langerhans.

encircle the secreting alveoli. The blood-vessels do not follow the course of the ducts so regularly as in the salivary glands (Flint). The meshes of the capillary network are not all of the same size. In some regions they are so wide that quite large areas of the alveoli are without blood-vessels.

The nerves of the pancreas have been investigated by Cajal and Sala (91) and Erik Müller (92), who find in this gland large numbers of nonmedullated nerve-fibers, some coming from sympathetic

ganglion cells situated in the pancreas and others entering from without. The nonmedullated nerve-fibers form plexuses surrounding the excretory ducts and end in periacinal networks. Fibrils from the network about the alveoli were traced to the secretory cells. A portion of the nonmedullated nerves in the pancreas form perivascular plexuses.

The development of the pancreas is peculiar in that the larger portion, together with the duct of Santorini, originates from the dorsal intestinal wall, and a smaller portion from the ductus choledochus. The latter part, with its accessory pancreatic duct, fuses with the former, after which there is a gradual retrogression of the duct of Santorini, so that finally the entire secretion of the pancreas almost invariably flows into the pancreatic or Wirsungian duct.

TECHNIC.

The *oral mucous* membrane may be fixed with corrosive sublimate or alcohol, stained in bulk, and examined in cross-section. If special structures, such as glands, nerves, or the distribution of mitoses, are to be examined, special methods must be adopted.

Teeth.—In order to obtain a general view of the structure of the teeth, the latter must be macerated and ground as in the case of bone.

The relations of the hard and soft parts in undecalcified teeth are best studied by the use of Koch's petrifaction method.

The teeth may also be examined in section, and when decalcified are treated as bone. Hydrochloric acid, dilute chromic acid, and picric acid dissolve the enamel prisms, their cement-substance being the first to disappear (von Ebner, 91).

The enamel of young teeth stains brown in a solution of chromic acid or its salts, and blackens in osmic acid. In the enamel cells, globules are seen, which are stained in osmic acid. If longitudinal sections of the enamel be corroded with hydrochloric acid, the cruciform arrangement of the enamel prisms is plainly seen.

The fibrils of the dentin may be demonstrated by decalcifying a tooth in the fluid recommended by von Ebner, the teeth of young individuals being well adapted for this purpose. Occasionally carious teeth also show the fibrils plainly. Corrosion with hydrochloric acid produces the same result.

The cementum, especially that part lacking in cells, contains a large number of Sharpey's fibers.

The development of the teeth is studied in the embryo; the jaw-bone is fixed, decalcified, and cut in serial sections. The most convenient material is a sheep embryo, which can almost always be had from the slaughter-house.

Taste-buds.—To study the taste-buds of the tongue and the relations which their constituent cells bear to each other, fixation in Flemming's fluid is recommended. The orientation of the taste-buds must be very carefully done, after which exactly longitudinal or transverse serial sections are made (not thicker than 5 μ) and stained with safranin-gentian-violet.

The nerves in the taste-buds are brought out either by Golgi's method, the methylene-blue method, or by the use of gold chlorid. If the last be used the procedure is as follows: A papilla foliata of a rabbit is removed with a sharp razor and placed for ten minutes in lemon juice, then in gold chlorid for from three-quarters of an hour to one hour, after which the specimen is placed in water weakly acidulated with acetic acid (5 drops to 100 c.c. of water) and exposed to the light. As soon as reduction has taken place the specimen is treated with alcohol and cut in vertical sections. These may be treated for a short time with formic acid (in which they swell slightly), washed with water, and mounted in glycerin.

In certain objects, such as the nictitating membrane of the frog, certain lobules of the rabbit's pancreas (the latter being so thin as to be especially well adapted for microscopic examination), etc., the glandular structure may be examined in normal salt solution.

Glands of the Digestive Tract.—Microscopically, the glands present varying pictures according to the phase of secretion in which they are fixed. Specimens in the different stages may be obtained either by feeding and then killing the animal after a definite period, or by irritating certain nerves, or finally by the use of certain poisons especially adapted to this purpose, such as atropin and pilocarpin. In the rabbit, for instance, 1 c.c. of a 5% solution of pilocarpin hydrochlorate or 1 c.c. of a 0.5% solution of atropin sulphate is used for each kilogram of the animal's weight. In atropin-intoxication secretion is suppressed, while in pilocarpin-poisoning it is increased. By this method cells are obtained either full of secretion or containing no secretion at all.

Sections should be made from carefully selected material which has been fixed either in Flemming's solution or corrosive sublimate, although fixation with strong alcohol also gives instructive pictures.

In preparations fixed with Flemming's solution the crescents of Gianuzzi stain somewhat more deeply than the remaining cells of the alveoli, and in objects that have been treated with alcohol or corrosive sublimate and then stained with hematoxylin the crescents take on a very deep color. The intermediate tubules of the salivary glands also assume a deeper stain with hematoxylin and carmin. The intralobular tubes are particularly well defined by certain stains, as for instance when Congo red is used after staining with hematoxylin; other acid anilin stains may also be used. The intralobular tubes of most salivary glands (not, however, of the parotid of the rabbit nor of the sublingual of the dog) are stained a dark-brown color (calcareous reaction) by agitating small, fresh pieces of tissue in order to facilitate the entrance of air, and then treating them with a dilute aqueous solution of pyrogallic acid. The stain persists for some time in specimens preserved in alcohol. Sections made by free hand from tissues treated by this method give excellent results.

Mucin is soluble in dilute alkalies, as for instance lime-water, and may be precipitated from these solutions by the addition of acetic acid, although the precipitate does not redissolve in an excess of acetic acid; mucin is also precipitated by alcohol, but not by heat. Mucinogen does not stain with hematoxylin, as does mucin. By this latter test a gland in a state of functional activity may be differentiated from one at rest (R. Heidenhain, 83). After treatment with alcohol, safranin

stains mucin orange-yellow. For the demonstration of mucin, more especially in alcoholic preparations, H. Hoyer (90) has recommended thionin or its substitute, toluidin-blue. Indeed, the basic anilin dyes in general seem to have a particular affinity for mucin.

P. Mayer (96) recommends the following two solutions for the staining of mucin: (1) Mucicarmin—Carmin 1 gm., aluminium chlorid 0.5 gm., and distilled water 2 c.c. are stirred together and heated over a small flame till the mixture becomes quite dark. As soon as the mixture has attained the consistency of thick syrup, 50% alcohol is added and the whole transferred to a bottle in which it is shaken after the addition of more alcohol. Finally, still more 50% alcohol is added until the whole amounts to 100 c.c. Before using, this stock solution is diluted tenfold with tap-water rich in lime-salts. (2) Muchematein: (*a*) Aqueous solution—0.2 gm. of hematein is ground in a mortar containing a few drops of glycerin; to this are added 0.1 gm. aluminium chlorid, 40 c.c. glycerin, and 60 c.c. distilled water. (*b*) Alcoholic solution—0.2 gm. hematein, 0.1 gm. aluminium chlorid, 100 c.c. 70% alcohol, and 1 or 2 drops of nitric acid. Both of these solutions are used for staining mucin in sections and thin membranes. By the use of these methods the mucous acini of mixed glands are shown with ease and precision. Under favorable conditions the whole secretory and excretory system of the gland may be brought out by Golgi's method (see this).

In order to obtain a general structural view of the esophagus a small animal may be selected, in which case small pieces of tissue are fixed and imbedded in paraffin. If a large animal is used, the tissue is imbedded in celloidin.

The mucous membrane of the stomach should be fixed while still fresh and warm, the best fixative for this purpose being corrosive sublimate. Mixtures of osmic acid are also serviceable, but fixing with corrosive sublimate increases the staining power of the tissue. In order to preserve the stomach and intestine in a dilated condition, they should be filled with the fixing fluid and after ligation placed whole in the fixing agent.

In *gastric mucous membrane* that has been fixed either with corrosive sublimate or alcohol, the parietal cells are easily differentiated from the chief cells by staining. The most reliable and convenient method is as follows: Sections fastened to the slide by the water-albumin fixative method are stained with hematoxylin and then placed in a dilute aqueous solution of Congo red until they assume a red color (minutes); they are then washed with dilute alcohol until the parietal cells appear red and the chief cells bluish (Stintzing). Almost all acid anilin dyes have an affinity for the parietal cells; hence the red stains may be combined with hematoxylin and the blue ones with carmin. The chief cells then take the color of the carmin or hematoxylin, and the parietal cells that of the anilins.

An accurate fixation of that portion of *the small intestine* possessing villi is attended with great difficulty, since the axial tissue of the villi shows a tendency to retract from the epithelial layer surrounding it (the latter becoming fixed first); and as a consequence spaces are formed at the summits of the villi which undoubtedly represent artefacts. A good method is to cut pieces from tissue while still warm and fix in osmic acid. If portions of the intestine be filled with alcohol or corrosive sublimate and thus dilated, both the glands and villi are shortened. The

methods above mentioned for staining mucin may be used to stain the goblet cells. The villi may also be examined in a fresh condition in one of the indifferent fluids. For this purpose the intestine of the mouse is especially well adapted.

The absorption of fat is best studied in preparations fixed in osmic acid, and especially in those treated by Altmann's method.

The technic for the solitary lymph-follicles and Peyer's patches is the same as that for lymph-glands. For this purpose the cecum of a rabbit or guinea-pig is the best material.

The nerves of the intestinal mucous membrane are best demonstrated by means of the methylene-blue method or Golgi's method (*vid.* Technic), and the coarser filaments of Auerbach's and Meissner's plexuses may also be stained by the gold method (Löwit's procedure, p. 48). Good results are also obtained by staining with hematoxylin such specimens as have been previously fixed and distended with alcohol. The plexuses then appear somewhat darker than the remaining tissue of the isolated mucous membrane or muscular layer.

Liver.—The arrangement of the liver lobules is best seen in the pig's liver. In the human liver and in most domestic animals the lobules are not sharply defined, two or three adjacent lobules merging into each other. In the liver of the fetus, of the new-born, and of children, the lobules are seen indistinctly or not at all, although the perivascular spaces of the blood-vessels are better seen than in the adult.

The liver-cells are best examined by treating small pieces of tissue with 1% osmic acid or osmic mixtures; in the latter case subsequent treatment with pyroligneous acid is necessary. Good results can also be obtained by fixing with corrosive sublimate and staining with hematoxylin (after M. Heidenhain).

In order to see the glycogen in the liver-cells Ranvier (89) proceeds as follows: A dog is fed on boiled potatoes for two days, after which sections of its liver are cut with a freezing microtome and examined in iodized serum. In a short time the glycogen is stained a wine-red. If the preparation be now exposed to osmic acid vapor, the stain will remain fixed for from twenty-four to forty-eight hours. Glycogen is insoluble in alcohol and ether, and stains a port wine-red in iodin solutions; the color disappears when the specimen is warmed, but returns again on cooling.

The distribution of the hepatic blood-vessels is usually demonstrated by injection of the portal vein, as the injection of the hepatic artery does not, as a rule, give such satisfactory results.

The injection method is also employed for the demonstration of the bile capillaries. Chrzonszczewsky recommends the following so-called physiologic autoinjection: A saturated aqueous solution of indigo-carmin is injected into the external jugular vein three times in the course of one and one-half hours (dog 50 c.c. each time, cat 30 c.c., full-grown rabbit 20 c.c.). The animal is then killed and small pieces of its liver fixed in absolute alcohol or in potassium chlorate; in the latter case a saturated solution of the salt may be injected into the blood-vessels. A subsequent injection of the blood-vessels with carmin-gelatin may also be employed and the whole liver then hardened in alcohol. By

this method the bile capillaries finally become filled with the indigo-carmin by a gradual elimination of the substance from the blood- and lymph-vessels and passage through the cells into the biliary system, while the blood-vessels themselves are distended by the carmin-gelatin. In the frog, the demonstration of the biliary passages is more easily accomplished by injecting 2 c.c. of the indigo-carmin solution into the large lymph-sac and killing it after a few hours. The liver is then fixed in the manner described above and is then ready for further treatment.

The bile passages may also be injected directly through the hepatic duct or the ductus choledochus. For this purpose it is best to use a concentrated aqueous solution of Berlin blue (Berlin blue that is soluble in water). The results obtained by this method are not, however, always satisfactory, and even in the best of cases only the peripheral portions of the liver lobules are successfully injected.

The bile capillaries may be impregnated with chrome-silver. Fresh pieces of liver tissue are placed for two or three days in a potassium bichromate-osmic acid solution (4 vols. of a 3% bichromate of potassium solution and 1 vol. of 1% osmic acid) and then transferred to a 0.75% aqueous solution of silver nitrate. After rinsing in distilled water the specimens are cut with a razor, the sections again washed with distilled water, placed for a short time in absolute alcohol, cleared in xylol, and finally preserved in hard Canada balsam. Both celloidin and paraffin imbedding are admissible, but either process must be hurried, as the preparation always suffers under such treatment. In the finished specimen, the bile capillaries appear black by direct light.

Another method which brings to view more extensive areas of the bile capillaries is as follows: A piece of liver tissue from a freshly killed animal is fixed in rapidly ascending strengths of potassium bichromate solution (from 2% to 5%). After three weeks the specimen is placed in a 0.75% silver nitrate solution, when after a few days (very marked after eight days) the bile capillaries, if examined in sections, will appear black by direct light (Oppel, 90).

Sometimes the bile capillaries are brought out in preparations treated by the method of R. Heidenhain, although only small areas are colored and these not constantly. The application of other stains, as for instance the method of M. Heidenhain following the gold chlorid treatment, often results in the staining of small areas of bile capillaries.

In all the methods used for the demonstration of the bile capillaries, whether physiologic autoinjection, direct injection, or impregnation, the secretion vacuoles of the liver-cells are clearly brought to view.

By treating pieces of liver tissue according to the method of Kupffer (76) the connective tissue of the liver, especially the reticular structure (*Gitterfasern*), is shown. Fresh liver tissue is cut with the double knife and the thinnest sections placed for a short time in a 0.6% sodium chlorid solution or in a 0.05% solution of chromic acid. From this they are transferred to a very dilute solution of gold chlorid (Gerlach) (gold chlorid 1 gm., hydrochloric acid 1 c.c., water 10 liters), and kept for one to several days in the dark until they assume a reddish or violet color. If the staining has been satisfactory (which is by no means always the case), the reticular fibers, and occasionally also the stellate cells, are

seen. Instead of the double knife the freezing microtome may be used and the method continued as stated (Rothe).

The *reticular fibers* are seen under more favorable conditions by using the following method, recommended by Oppel (91): Fresh pieces of tissue fixed in alcohol are placed for twenty-four hours in a 0.5% aqueous solution of yellow chromate of potassium (larger pieces in stronger solutions up to 5%), then washed with a very dilute solution of nitrate of silver (a few drops of a 0.75% solution to 30 c.c. distilled water), and transferred to a 0.75% solution of silver nitrate. In twenty-four hours the intralobular network surrounding the blood capillaries will have become stained. The best areas lie at the periphery of the specimen, and extend about 1 mm. into the parenchyma. Free-hand sections are made, or the specimens are quickly imbedded in celloidin or paraffin, to be cut afterward by means of the microtome. The same results are obtained by placing small fresh pieces of the tissue for two or three days in a 0.5% chromic acid solution and then one or two days in a 0.5% solution of silver nitrate. The further treatment is as in the preceding method.

The method of F. P. Mall is also employed in the examination of the hepatic connective tissue.

The following method is recommended by Berkley for demonstrating the nerves of the liver: Small pieces of liver tissue from 0.5 to 1 mm. in breadth are placed in a half-saturated aqueous solution of picric acid for from fifteen to thirty minutes, and then in 100 c.c. of potassium bichromate solution that has been saturated in the sunlight and to which 16 c.c. of 2% osmic acid has been added. The specimens now remain in this fluid for forty-eight hours in a dark place, and at a temperature of 25° C. After this the tissue is treated with a 0.25% to 0.75% aqueous solution of silver nitrate for five or six days, washed (quick imbedding may be employed), cut, cleared in oil of bergamot, and mounted in xylol-Canada balsam.

The cellular elements of the pancreas may be examined without further manipulation in very thin lobules from the rabbit (Kühne and Lea).

There are various methods of differentiating the inner and outer zones of the cells. In sections of the tissue fixed in alcohol, carmin stains the outer zone of the cells more intensely than the inner (R. Heidenhain, 83). For the staining of the inner zone, fixation in Flemming's fluid is to be recommended, then staining with safranin, and finally washing in an alcoholic solution of picric acid. The granules of the inner zone (zymogen granules) appear red. These also stain red with the Biondi-Ehrlich mixture. The simplest and most precise method of demonstrating the zymogen granules is that of Altmann. The secretory and excretory ducts of the pancreas are shown, as in the case of the salivary glands, by the chrome-silver method.

IV. ORGANS OF RESPIRATION.

A. THE LARYNX.

THE greater portion of the laryngeal mucous membrane is covered by a stratified columnar ciliated epithelium containing goblet cells, and resting on a thick basement membrane. The epithelium covering the free margin of the epiglottis, the true vocal cords, and

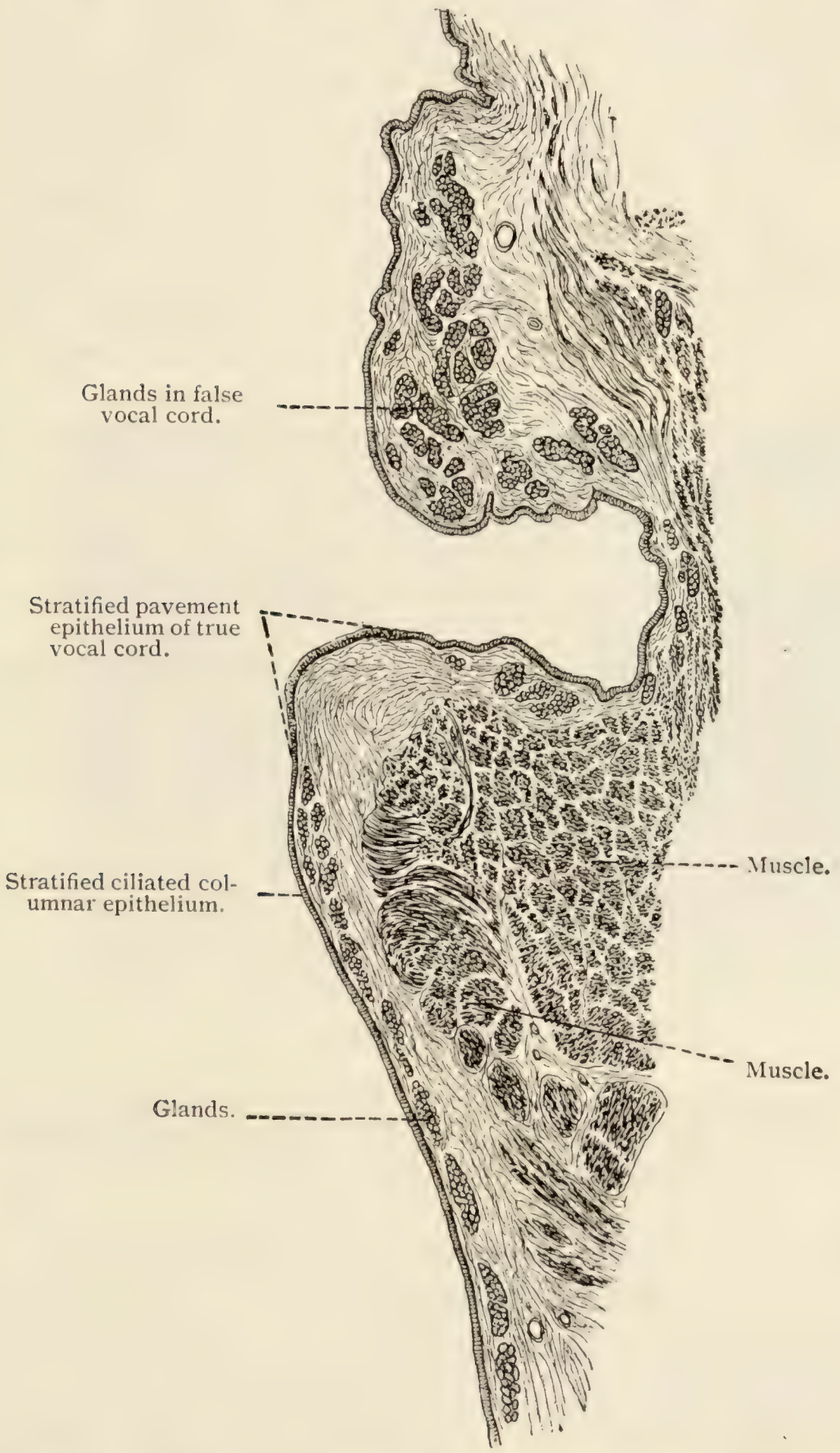

Fig. 245.—Vertical section through the mucous membrane of the human larynx; ×5.

part of the arytenoid cartilage as far as the cavity between these cartilages, is of the stratified squamous variety, and is provided with connective-tissue ridges and papillæ. The mucosa consists of fibrous connective tissue, contains many elastic fibers, which become larger and more prominent as the deeper layers of the mucosa are approached, and is rather firmly connected with the structures underneath it, but is somewhat more loosely connected in the regions supplied with squamous epithelium. The mucosa contains numerous lymphocytes and leucocytes, which now and then, especially in the region of the ventricles, form simple follicles. In it are found branched tubulo-alveolar glands, which may be single or arranged in groups. These are found at the free posterior portion of the epiglottis, in the region of the latter's point of attachment—*i. e.*, in the so-called cushion of the epiglottis. Larger collections of glands are found in the false vocal cords, and on the cartilages of Wrisberg (cuneiform cartilages), which appear almost imbedded in the glandular tissue and in the ventricles. In the remaining parts of the larynx glands are found only at isolated points. The true vocal cords have no glands. The glands of the larynx are of the mucous variety, containing crescents of Gianuzzi.

The cartilages of the larynx are of the hyaline variety, with the exception of the epiglottis, the cartilages of Santorini (the latter are derivatives of the epiglottis, Göppert), the cuneiform cartilages, the processus vocalis, and a small portion of the thyroid at the points of attachment of the vocal cords, which consist of elastic cartilage.

The vascular supply of the larynx is arranged in three superimposed networks of blood-vessels. The capillaries are very fine, and lie directly beneath the epithelium. The lymphatic network is arranged in two layers, the superficial being very fine and directly beneath the network of blood capillaries.

The nerves of the laryngeal mucous membrane will be described in connection with those found in the trachea.

B. THE TRACHEA.

The trachea is lined by a stratified ciliated columnar epithelium containing goblet cells and resting on a well-developed basement membrane. The mucosa is rich in elastic tissue. In the superficial portion of the mucosa the elastic fibers form dense strands, which usually take a longitudinal direction. The deeper layer of the mucosa is more loosely constructed, and passes over into the perichondrium of the semilunar cartilages of the trachea without any sharp line of demarcation. Numerous leucocytes are scattered throughout the mucosa, and are also frequently found in the epithelium. Connecting the free ends of the semilunar cartilages, which are of the hyaline variety, are found bundles of nonstriated muscle tissue, the direction of which is nearly transverse.

The trachea contains numerous branched tubulo-alveolar glands of the mucous variety containing here and there crescents of Gianuzzi. The glands are especially numerous where the tracheal wall is devoid of cartilage.

The larynx and trachea receive their nerve supply from sensory nerve-fibers and sympathetic neurones. These have been described by Ploschko (97) working in Arnstein's laboratory. According to this observer, the sensory fibers divide in the mucosa, forming subepithelial plexuses from which fibrils are given off which enter the epithelium of the larynx and trachea and, after further division, end on the epithelial cells in small nodules, or small clusters of nodules. In the trachea of the dog, such fibrils were traced to the ciliary border of the columnar ciliated cells before terminating. Numerous sympathetic ganglia are found in the larynx and trachea. In the latter they are especially numerous in the posterior wall. The neuraxes of the sympathetic neurones forming these ganglia were traced to the nonstriated muscular tissue of the trachea. The cell-bodies of these sympathetic neurones are surrounded by end-baskets of small medullated fibers terminating in the ganglia. Medullated

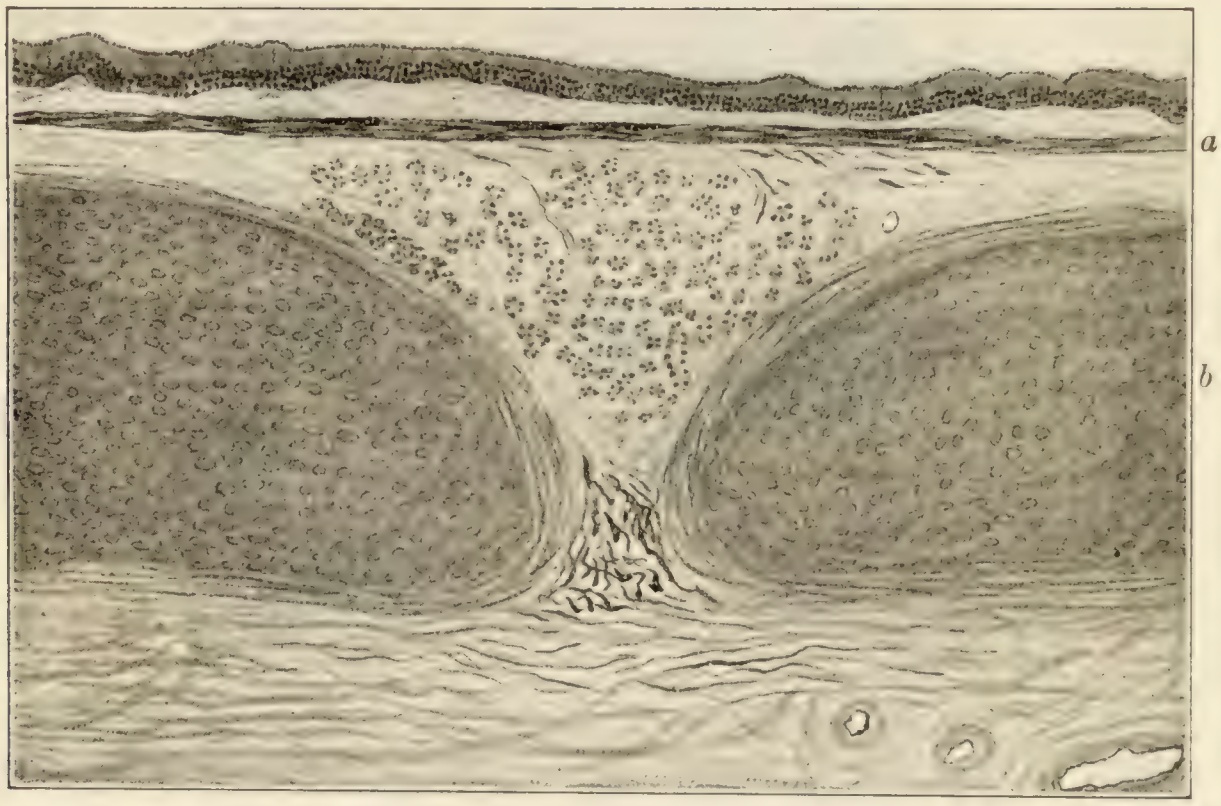

Fig. 246.—From longitudinal section of human trachea, stained in orcein: *a*, Layer of elastic fibers; *b*, cartilage.

nerve-fibers, ending in the musculature of the trachea in peculiar end-brushes, were also described by Ploschko.

C. THE BRONCHI, THEIR BRANCHES, AND THE BRONCHIOLES.

The primary bronchi and their branches show the same general structure as the trachea, showing, however, irregular plates and platelets of cartilage instead of half-rings, which surround the bronchi. The cartilage is absent in bronchial twigs of less than

0.85 mm. in diameter. The epithelium of the bronchi of medium size (up to 0.5 mm. in diameter) consists of a ciliated epithelium having three strata of nuclei. Kölliker (81) distinguishes a deep layer of basilar cells, a middle layer of replacing cells, and a superficial zone consisting of ciliated and goblet cells. The number of the last varies greatly. Glands are found only in bronchial twigs that are not less than 1 mm. in diameter; as in the trachea, they are branched tubulo-alveolar glands of the mucous variety. In these structures the mucosa contains a large number of elastic fibers, the greater part of which have a longitudinal direction. Furthermore, numerous lymph-cells are found, and here and there a lymph-nodule. The muscularis presents, as a rule, circular fibers, which do not, however, form a continuous layer.

The smaller bronchi subdivide into still finer tubules of less than 0.5 mm. in diameter (bronchioles), which contain neither car-

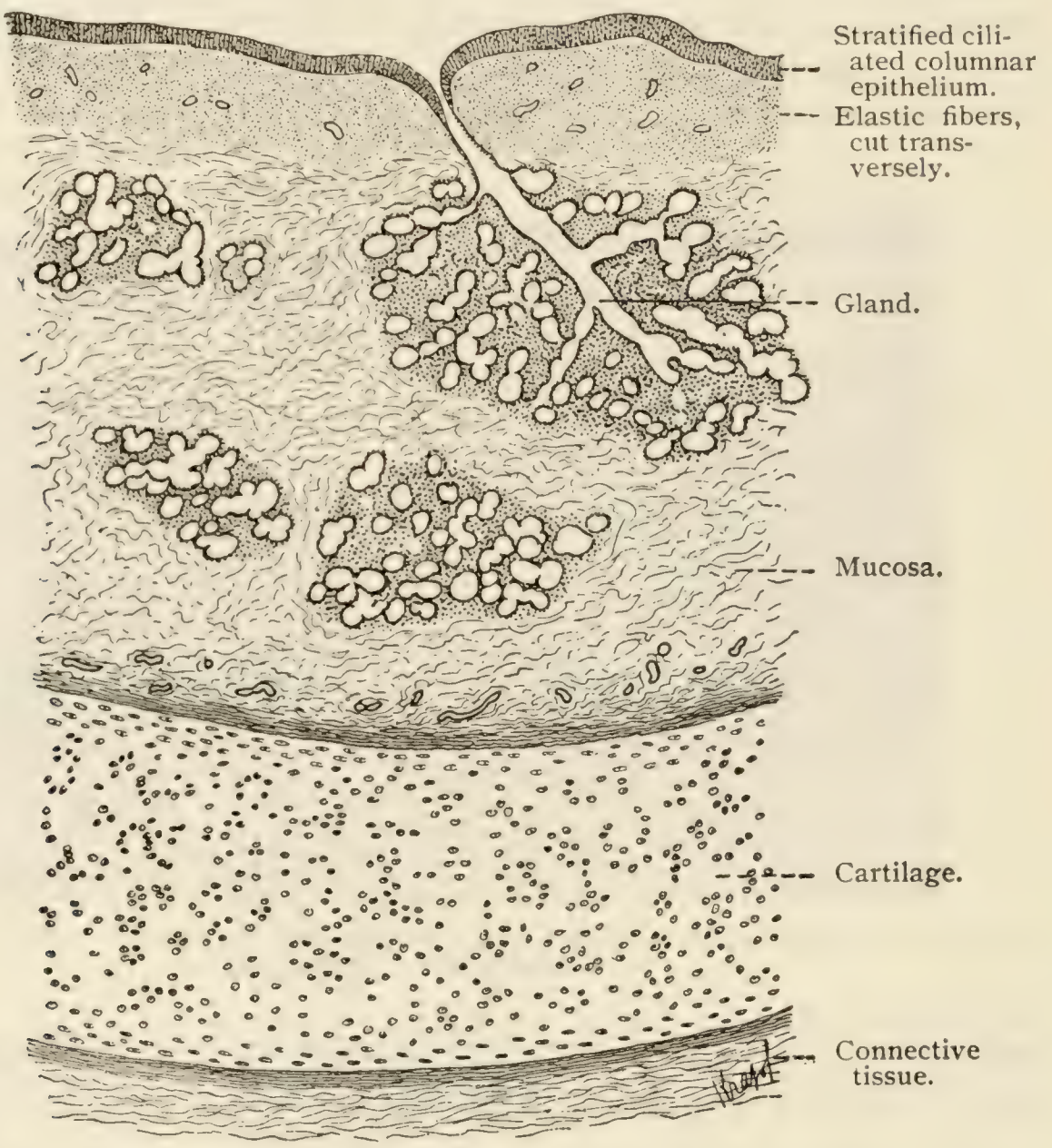

Fig. 247.—Transverse section through human bronchus; × 27.

tilage nor glands. The stratum proprium, as well as the external connective-tissue sheath, becomes very thin; and the epithelium now consists of but one layer, but is still ciliated.

D. TERMINAL DIVISIONS OF BRONCHI AND ULTIMATE AIR-SPACES.

The bronchioles are continued as the respiratory bronchioles.

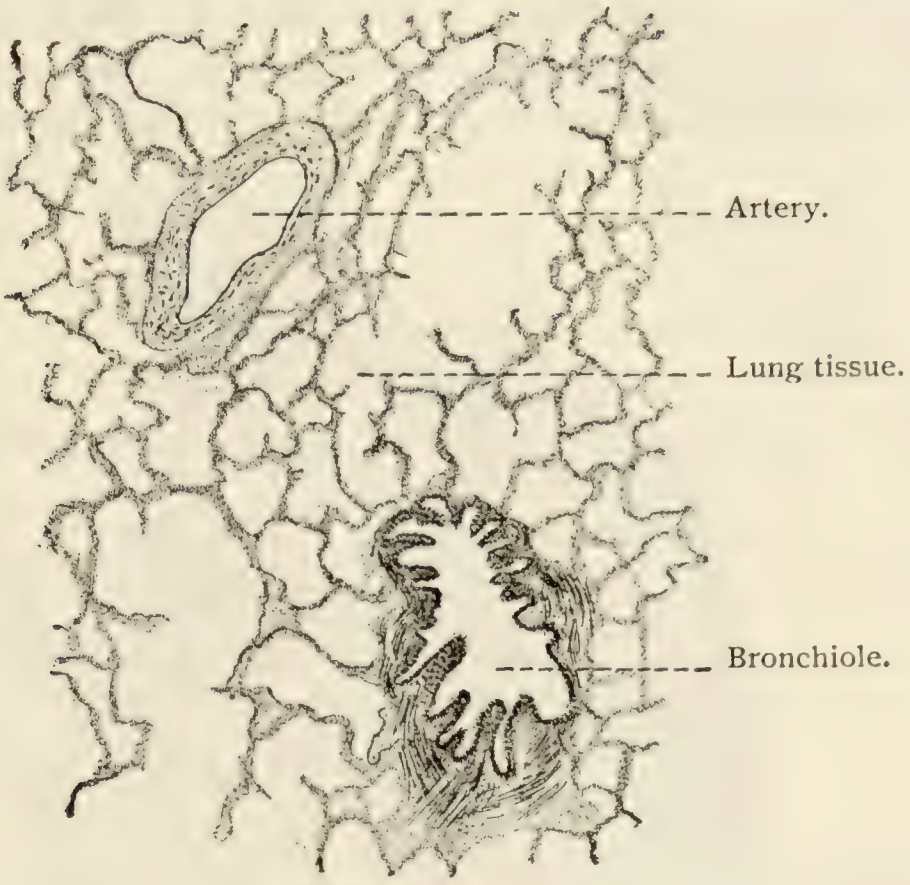

Fig. 248.

Fig. 249.

Figs. 248 and 249.—Two sections of cat's lung: Fig. 248, × 52; Fig. 249, × 35.

The epithelium of the latter is ciliated in patches, but soon becomes nonciliated and assumes the character of respiratory epithelium.

(See below.) The walls of the respiratory bronchioles are relatively thin, consisting of fibro-elastic connective tissue and nonstriated muscle. Our knowledge of the further divisions of the bronchioles and of their relation to the terminal air-spaces has been increased greatly by Miller, who has made use of Born's method of wax-plate reconstruction in the study of these structures. His account is here followed. According to Miller, the respiratory bronchioles divide into or become the terminal bronchioles or alveo-

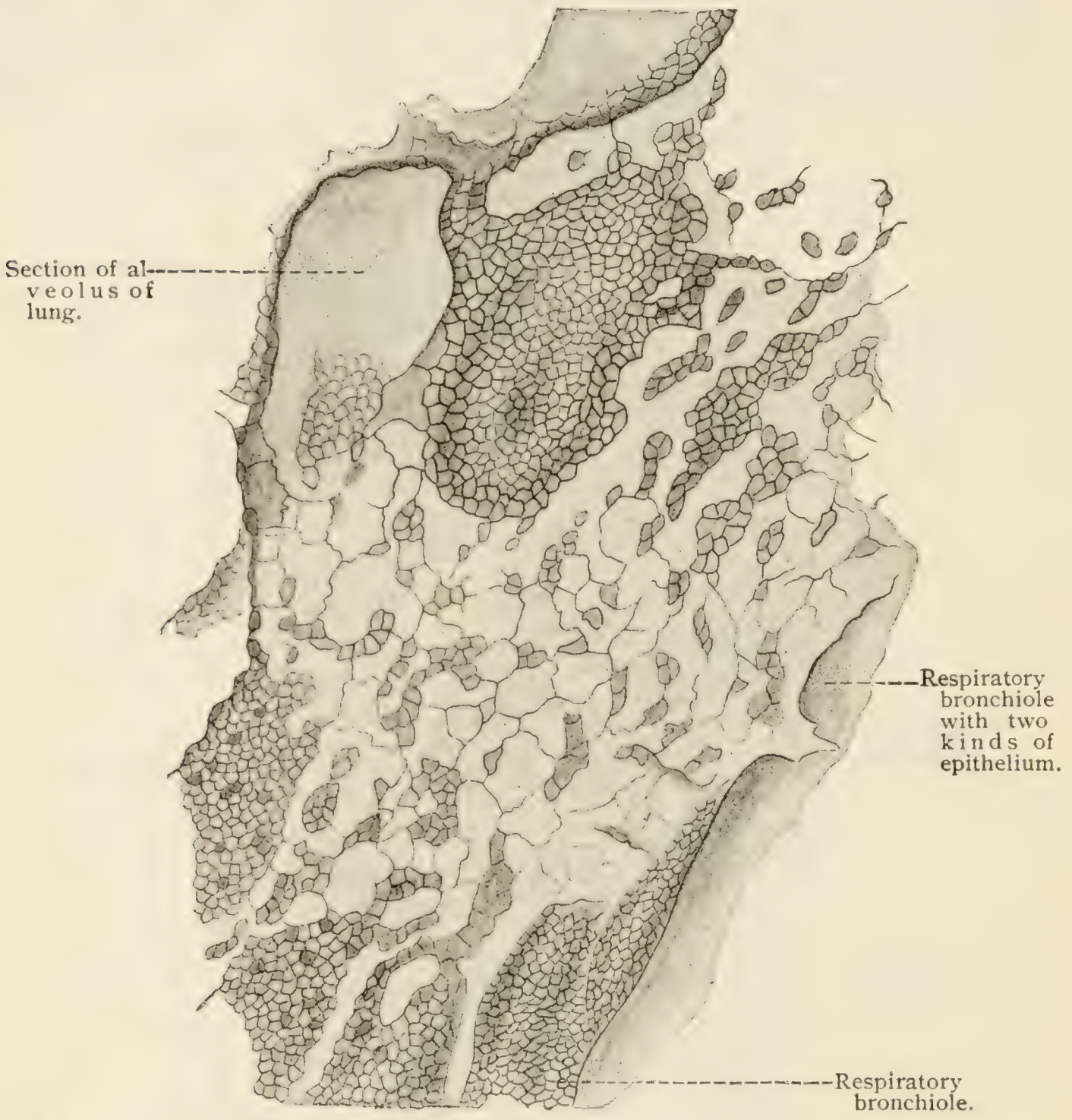

Fig. 250.—Internal surface of a human respiratory bronchiole, treated with silver nitrate ; × 234 (after Kölliker).

lar ducts. These are somewhat dilated at their distal ends and communicate, by means of three to six round openings, with a corresponding number of spherical cavities, known as *atria*. Each atrium communicates with a variable number of somewhat irregular spaces or cavities, the air-sacs, the walls of which are beset with numerous somewhat irregular hemispheric bulgings, the *air-cells* or lung alveoli. The air-cells or alveoli are also numerous in the walls of the atria and the terminal bronchioles or alveolar ducts,

and may even be found in the walls of the respiratory bronchioles. The terminal bronchioles or alveolar ducts have an epithelium which is of the cubic variety in their proximal portions, and which changes to a squamous epithelium in their distal portions.

The epithelium of the distal portions of the terminal bronchioles or alveolar ducts, atria, and air-sacs (11 μ to 15 μ in diameter) and of the alveoli (the so-called respiratory epithelium) consists of two varieties of cells (F. E. Schulze)—smaller nucleated elements and larger nonnucleated platelets (the latter derived very probably from the former). The arrangement of the epithelial cells is generally such that the nonnucleated platelets rest directly upon the blood capillaries, while nucleated cells lie between them. In amphibia the epithelium of the alveoli consists of cells, of which the portion containing the nucleus forms a broad cylindric base; from

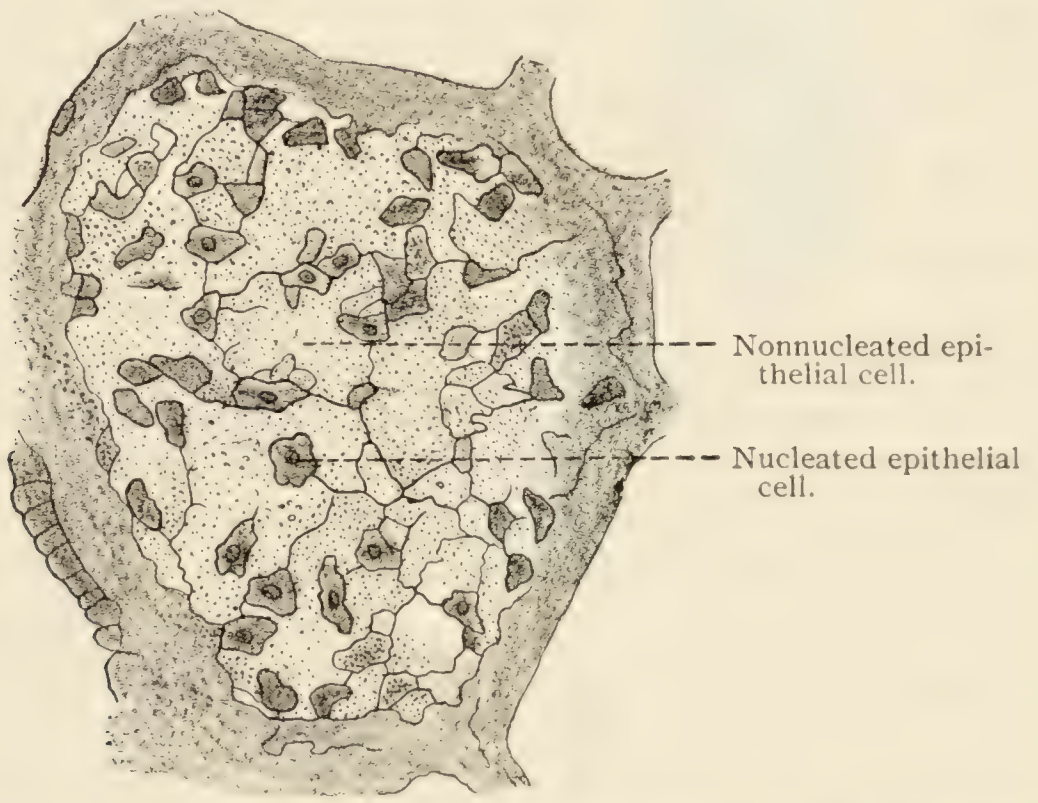

Fig. 251.—Inner surface of human alveolus treated with silver nitrate, showing respiratory epithelium; × 240 (after Kölliker).

the free end of each cell a lateral process extends over the adjoining capillary to meet a similar process from the neighboring cell. When viewed from above, the basal portion of the cell appears dark and granular, while the processes are clear and transparent. These cells, together with their prolongations, are about 50 μ in diameter. The surface view greatly resembles that of the human respiratory epithelium (Duval, Oppel, 89).

The terminal bronchioles or alveolar ducts have a distinct layer of nonstriated muscle having annular thickenings about the openings which lead to the atria. Muscular tissue is not found in the walls of the atria, air-sacs, and air-cells or alveoli (Miller).

Beneath the respiratory epithelium in the atria, air-sacs, and air-cells, there is found a thin basement membrane, which is apparently homogeneous. Here and there are found some fibrils of fibrous

tissue and fixed connective-tissue cells. Elastic fibers are, however, numerous, forming networks beneath the basement membrane.

The work of Miller has given a clearer conception of what may be regarded as the units of lung structure, namely, the lobules. Such a unit or lobule is composed of a terminal bronchiole or alveolar duct, with the air-spaces—atria, air-sacs, and air-cells—connected with it, and their blood- and lymph-vessels and nerves. The general arrangement of these structures may be observed in Fig. 253, which gives a diagram of a lung lobule. The shape of the atria, air-sacs, and air-cells may be seen in Fig. 254, which is from a wax reconstruction of these structures.

The *blood-vessels* of the lung, including their relation to the structures of the lung lobules, have been investigated by Miller; his account is closely followed in the following description: The pulmonary artery follows closely the bronchi through their entire length. An arterial branch enters each lobule of the lung at its apex in close proximity to the terminal bronchiole. After entering the lobule the artery divides quite abruptly, a branch going to each atrium; from these branches the small arterioles arise which supply the alveoli of the lung. "On reaching the air-sac the artery breaks up into small radicals which pass to the central side of the sac in the sulci between the air-cells, and are finally lost in the rich system of capillaries to which they give rise. This network surrounds the whole air-sac and communicates freely with that of the surrounding sacs." This capillary network is exceedingly fine and is sunken into the epithelium of the air-sacs so that between the epithelium and the capillary there is only the extremely delicate basement membrane. Only one capillary network is found between any two contiguous air-cells or air-sacs. The atria, the alveolar ducts and their alveoli, and the alveoli of the respiratory bronchioles are supplied with similar capillary networks. The veins collecting the blood from the lobules lie at the periphery of the lobules in the interlobular connective tissue, and are as far distant from the intralobular arteries as possible. These veins unite to form the larger pulmonary veins.

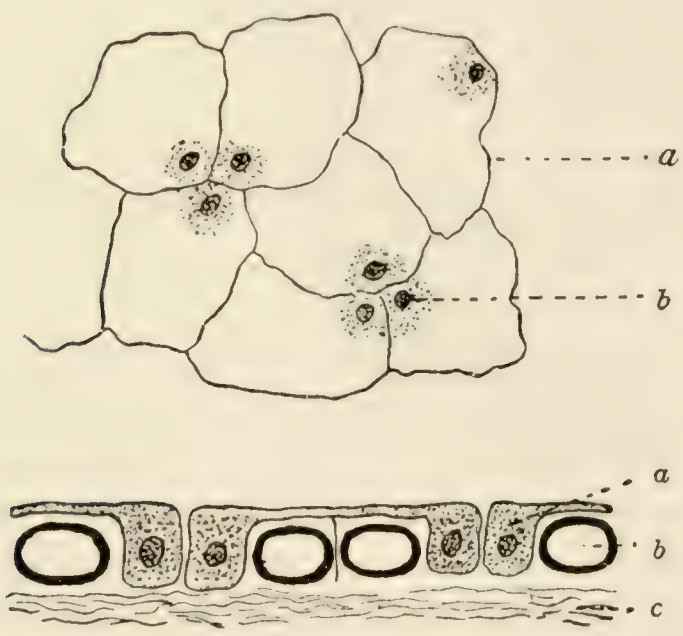

Fig. 252.—Scheme of the respiratory epithelium in amphibia: The upper figure gives a surface view: *b*, Basilar portion; *a*, the thin process. The lower figure is a section: *a*, Respiratory epithelial cell; *b*, blood-vessel; *c*, connective tissue around the alveoli.

The bronchi, both large and small, as well as the bronchioles, derive their blood supply from the bronchial arteries, which also partly supply the lung itself. Capillaries derived from these arteries surround the bronchial system, their caliber varying according

to the structure they supply—finer and more closely arranged in the mucous membrane, and coarser in the connective-tissue walls. In the neighborhood of the terminal bronchial tubes the capillary nets anastomose freely with those of the respiratory capillary system. From the capillaries of the bronchial arteries, veins are formed which empty either into the bronchial veins or into the branches of the pulmonary veins.

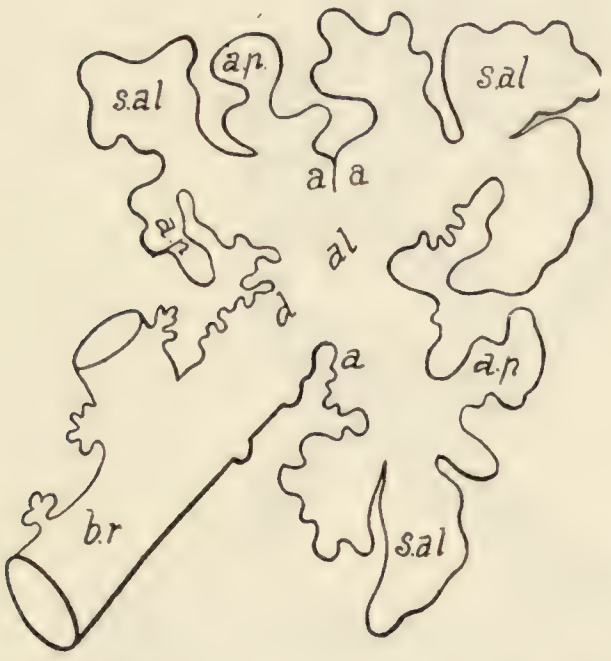

Fig. 253.—Scheme of lung lobule after Miller: *b. r.*, Respiratory bronchiole; *d. al.*, alveolar duct (terminal bronchus); *a*, *a*, *a*, atria; *s. al.*, air-sacs; *a. p.*, air-cells or alveoli.

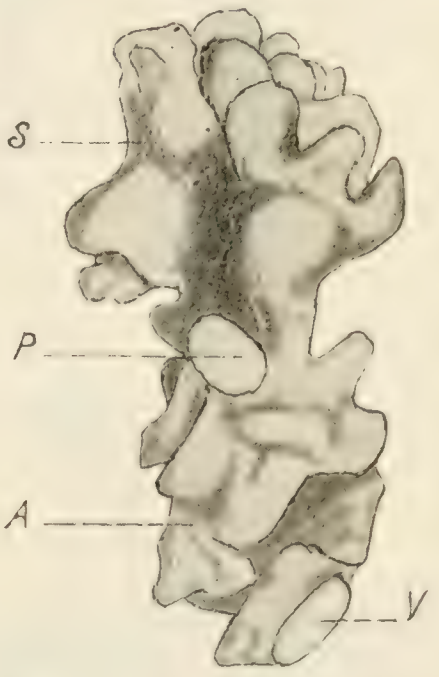

Fig. 254.—Reconstruction in wax of a single atrium and air-sac with the alveoli: *V*, Surface where atrium was cut from alveolar duct; *P*, cut surface, where another air-sac was removed; *A*, atrium; *S*, air-sac with air-cells (alveoli) (after Miller).

The lymphatics of the lung are classified by Miller as follows: (*a*) lymphatics of the bronchi; (*b*) lymphatics of the arteries; (*c*) lymphatics of the veins; (*d*) lymphatics of the pleura. The bronchial lymphatics are arranged in two plexuses as far as cartilage is present in the walls of the bronchi, one internal and one external to the cartilage. Beyond the cartilage only a single plexus is found. In the terminal bronchioles there are found three lymphatic vessels, two of which pass to the vein and one to the artery of the lobules. No lymphatics are found beyond the terminal bronchioles. The larger arteries are accompanied by two lymphatic vessels; the smaller ones, only one. The same is true in general of the lymphatics accompanying the vein. The bronchial lymphatics and those accompanying the arteries and veins anastomose in the regions of the divisions of the bronchi. The pleura possesses a rich network of lymphatics with numerous valves.

Accompanying the bronchi and bronchial arteries are found numerous nerve-fibers, of the nonmedullated and medullated varieties, arranged in bundles of varying size, in the course of which are found sympathetic ganglia. Berkley (94), who has studied the distribution of the nerves of the lung with the chrome-silver method, finds that in the external fibrous layer of the bronchi is found a

plexus of very fine and of coarser fibers, from which branches are given off which end in the muscle tissue of the bronchi, and others which pass through this layer to form, after further division, a sub-

Fig. 255.—From section of human lung stained in orcein, showing the elastic fibers surrounding the alveoli.

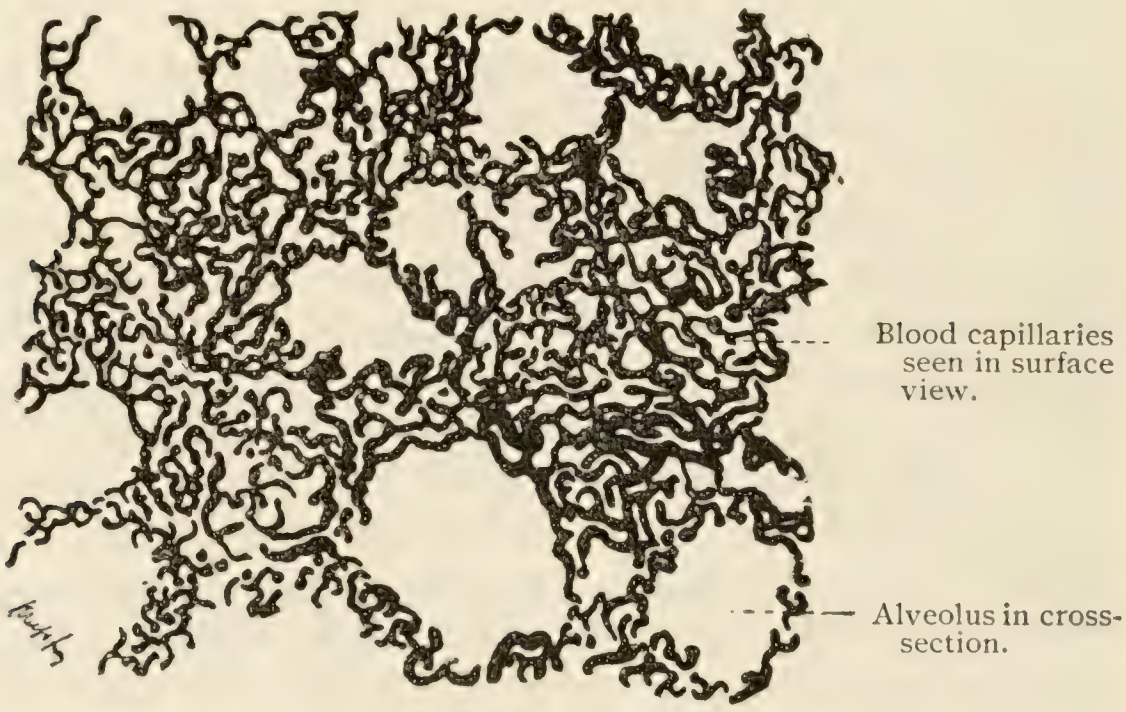

Fig. 256.—Section through injected lung of rabbit.

epithelial plexus from which fibrils may be traced into the connective-tissue folds in the larger bronchi and between the bases of the epithelial cells in the smaller bronchi and bronchioles. Some few fibrils were traced between alveoli situated near bronchi, "terminating, apparently, immediately beneath the pavement epithelium in an elongated or rounded minute bulb;" these may, however, repre-

sent endings on nonstriated muscle tissue. The bronchial arteries have an exceedingly rich nerve supply.

The visceral and parietal layers of the pleura consist of a layer of fibrous tissue containing numerous elastic fibers. Both layers are covered by a layer of mesothelial cells. The presence of stomata in the pleural mesothelium is denied by Miller. The blood-vessels of the visceral layer of the pleura arise, according to Miller, from the pulmonary artery, these forming a wide-meshed network, which empty into veins which pass into the substance of the lung. Sensory nerve-endings, similar to those found in connective tissue, have been observed in the parietal layer of the pleura.

E. THE THYROID GLAND.

The thyroid gland is developed from three sources: Its middle portion, the isthmus of the gland, and a portion of the lateral lobes originate as a diverticulum of the pharyngeal epithelium, from what

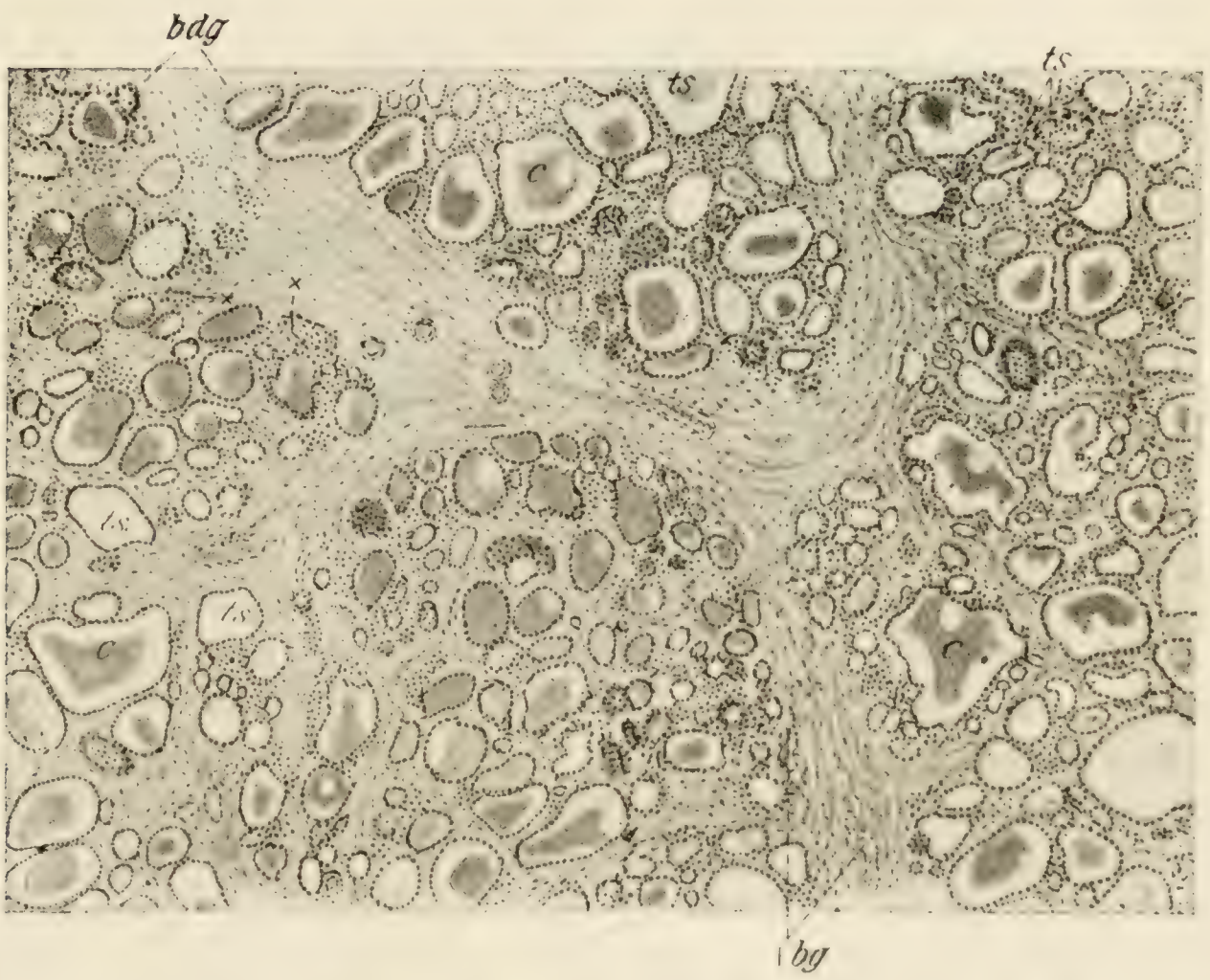

Fig. 257.—Portion of a cross-section of thyroid gland of a man; × 30. *bdg*, Interstitial connective tissue; *bg*, blood-vessel; *c*, colloid substance; *ts*, gland alveoli.

is later the foramen cæcum of the tongue; a part of both lateral portions, the right and left lobes, are formed from a complicated metamorphosis of the epithelium of the fourth visceral pouch. These various parts unite in man into one, so that in the adult the structure of the organ is continuous. The thyroid gland consists of numerous noncommunicating acini or follicles of various sizes lined

by a nearly cubic epithelium; the lobules are separated from each other by a highly vascularized connective tissue, continuous with the firm connective-tissue sheath surrounding the whole gland. The connective-tissue framework of the thyroid has been studied by Flint by means of the destructive digestion method. Relatively greater amounts of connective tissue are found in connection with the blood-vessels, while the follicular membranes are delicate. The follicles are either round, polyhedral, or tubular, and are occasionally branched (Streiff). At an early stage the acini are found to contain a substance known as "colloid" material.

Langendorff has shown that two varieties of cells exist in the acini of the thyroid body—the *chief cells* and *colloid cells*. Those of the first variety apparently change into colloid cells, while the latter secrete the colloid substance. During the formation of this material the colloid cells become lower, and their entire contents, including the nuclei, change into the colloid mass. Hürthle distinguished two processes of colloid secretion; in the one the cells remain intact, in the other they are destroyed. He claims that the colloid cells of Langendorff participate in the former process, while in the latter they are first modified (flattened) and then changed into the colloid substance. The secretion is formed in the cells in the form of secretory granules. The colloid material may enter the lymph-channels, either directly by a rupture of the acini, or indirectly by a percolation of the substance into the intercellular clefts, whence it is carried into the larger lymphatics.

The thyroid gland has a very rich blood supply. The vessels, which enter through the capsule, break up into smaller branches which form a very rich capillary network surrounding the follicles. The veins, which are thin-walled, arise from this capillary network. The gland is provided with a rich network of lymphatic vessels.

Anderson (91) and Berkley (94) have studied the distribution of the nerve-fibers of the thyroid gland with the chrome-silver method; the account given by the latter is the more complete and will be followed here. The nonmedullated nerves entering the gland form plexuses about the larger arteries, which are less dense around the smaller arterial branches. Some of these nerve-fibers are vascular nerves and end on the vessels; others form perifollicular meshes surrounding the follicles of the gland. From the network of nerve-fibers about the follicles, Berkley was able to trace fine nerve filaments which seemed to terminate in end-knobs on or between the epithelial cells lining the follicles. Even in the best stained preparations, however, not nearly all the follicular cells possess such a nerve termination. In methylene-blue preparations of the thyroid gland (Dr. De Witt) some few medullated fibers were found in the nerve plexus surrounding the vessels. In a number of preparations these were traced to telodendria situated in the adventitia of the vessels, showing that at least a portion of these medullated nerves are sensory nerves ending in the walls of the vessels.

PARATHYROID GLANDS.

Small glandular structures found on the posterior surfaces of the lateral lobes of the thyroid were discovered by Sandström in 1880. They are surrounded by a thin connective-tissue capsule and divided into small imperfectly developed lobules by a few thin fibrous-tissue septa or trabeculæ, which support the larger vessels. The epithelial portions of these structures consist of relatively large cells and capillary spaces. According to Schaper (95), who has recently subjected these structures to a careful investigation, the epithelial cells have a diameter which varies from 10 μ to 12 μ, possessing nuclei 4 μ in diameter. These cells are of polygonal shape and have a thin cell-membrane, a slightly granular protoplasm, and a nucleus presenting a delicate chromatic network. The cells are arranged either in larger or smaller clusters or, in some instances, in anastomosing trabeculæ or columns, consisting either of a single row or of several rows of cells. Between the clusters or columns of cells are found rela-

Fig. 258.—From parathyroid of man.

tively large capillaries, the endothelial lining of which rests directly on the epithelial cells. Connective-tissue fibrils do not, as a rule, follow the capillaries between the cell-masses. These vessels may therefore be regarded as sinusoids (Minot). The structure of the parathyroid resembles in many respects that of certain embryonic stages of the thyroid, and it has been suggested that these bodies represent small masses of thyroid gland tissue, retaining their embryonic structure. Schaper has observed parathyroid tissue, the cells of which were here and there arranged in the form of small follicles, some of which contained colloid substance. Such observations lend credence to the view regarding the parathyroid as an embryonic structure. Whether in this stage they form a special secretion has not been fully determined. (See Schaper, 95.)

TECHNIC.

For the demonstration of the *larynx* and *trachea*, young and healthy subjects should be selected. Pieces of the mucous membrane or the whole organ should be immersed in a fresh condition. Sections through the entire organ present only a general structural view; but if a close examination of accurately fixed mucous membrane be desired, the latter should be removed with a razor before sectioning and treated separately.

Chromic-osmic acid mixtures are recommended as fixing agents, and safranin as a stain. Besides the nuclear differentiation, the goblet cells stain brown, and the elastic network of the stratum proprium and the submucosa a reddish-brown.

For examining the epithelium, isolation methods are employed, such as the ⅓ alcohol of Ranvier.

The examination of the respiratory epithelium is attended with peculiar difficulty; it is, perhaps, best accomplished by injecting a 0.5% solution of silver nitrate into the bronchus until the lumen is completely filled, and then placing the whole in a 0.5% solution of the same salt. After a few hours, wash with distilled water and transfer to 70% alcohol. Thick sections are now cut and portions of the respiratory passages examined; the silver lines represent the margins of the epithelial cells. Such sections should not be fastened to the slide with albumen, as the latter soon darkens and blurs the picture. These specimens may also be stained.

For the elastic fibers, especially those of the alveoli, fixation in Müller's fluid or in alcohol and staining with orcein is a good method, as also Weigert's differential elastic tissue stain. Fresh pieces of lung tissue treated with potassium hydrate show numerous isolated elastic fibers.

Pulmonary tissue may be treated by Golgi's method, which brings out a reticular connective-tissue structure in the vessels and alveoli.

The pulmonary vessels may be injected with comparative ease.

The *thyroid gland* is best fixed in Flemming's solution; it is then stained with M. Heidenhain's hematoxylin solution or, better still, with the Ehrlich-Biondi mixture which differentiates the chief from the colloid cells; the former do not stain at all, while the latter appear red with a green nucleus (Langendorff). The colloid substance of the thyroid gland does not cloud in alcohol or chromic acid, nor does it coagulate in acetic acid, but swells in the latter; 33% potassium hydrate hardly causes the colloid material to swell at all, though in weaker solutions it dissolves after a long time.

V. THE GENITO-URINARY ORGANS.

A. THE URINARY ORGANS.

1. THE KIDNEY.

THE kidney is a branched tubular lobular gland, which in man consists of from ten to fifteen nearly equal divisions of pyramidal shape known as the *renal lobes.* The apex of each pyramid (the Malpighian pyramid) projects into the pelvis of the kidney. The kidney is surrounded by a thin but firm capsule consisting of fibrous connective tissue containing a few elastic fibers and, in its deeper portion, a thin layer of nonstriated muscle-cells.

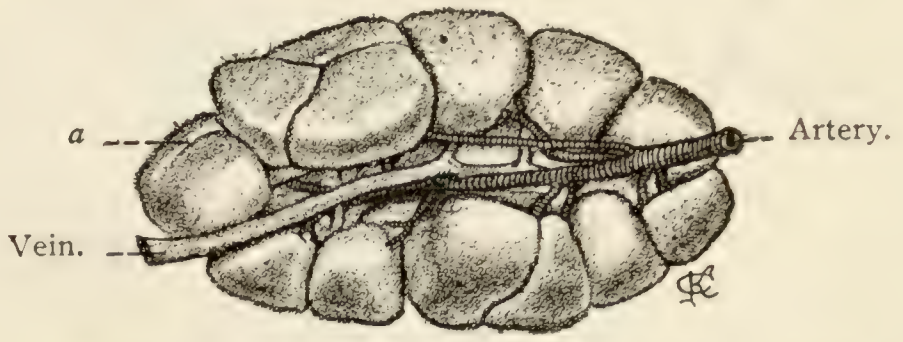

Fig. 259.—Kidney of new-born infant, showing a distinct separation into reniculi; natural size. At *a* is seen the consolidation of two adjacent reniculi.

The secreting portion is composed of a large number of tubules twisted and bent in a definite and typical manner, the *uriniferous tubules.* In each one of these tubules we distinguish the following segments: (1) *Bowman's capsule*, or the ampulla, surrounding a spheric plexus of capillaries, *the glomerulus*, which, with the capsule of Bowman, forms a *Malpighian corpuscle;* (2) a *proximal convoluted portion;* (3) a U-shaped portion, consisting of straight *descending* and *ascending limbs* and the *loop of Henle;* (4) a *distal convoluted portion* or *intercalated portion;* and (5) an *arched collecting portion;* from the confluence of a number of these are formed the larger *straight collecting tubules*, which, in turn, finally unite to form the papillary ducts or tubules of Bellini, which pass through the renal papillæ and empty into the renal pelvis. Besides the uriniferous tubules the kidney contains a complicated vascular system, a small amount of connective tissue, etc.

In a longitudinal median section the kidney is seen to be composed of two substances,—the one, the *medullary substance*, possessing relatively few blood capillaries and containing straight collecting tubules and the loops of Henle; the other, the *cortical substance*, richer in blood-vessels, and containing principally the Malpighian corpuscles and the proximal and distal convoluted tubules. In each renal lobe we find these two substances distributed as follows: The Malpighian pyramid consists entirely of medullary substance, which sends out a large number of processes, the *medul-*

lary rays, or *pyramids of Ferrein*, toward the surface of the kidney. The latter do not, however, quite reach the surface, but terminate at a certain distance below it; they are formed by collecting tubules which extend beyond the medullary substance. The entire remaining portion of the kidney is composed of cortical substance; between the medullary rays it forms the *cortical processes*, and at the periphery of the kidney, where the medullary rays are absent, the *cortical labyrinth*. Those portions of the cortical substance separating the Malpighian pyramids are known as the *columns of Bertini*, or *septa renis*.

Fig. 260.—Isolated uriniferous tubules: *A* and *B*, from mouse; *C*, from turtle. In all three figures *a* represents the Malpighian corpuscle; *b*, the proximal convoluted tubule; *c*, the descending limb of Henle's loop; *d*, Henle's loop; *e*, the straight collecting tubule; *f*, the arched collecting tubule.

The various segments of the uriniferous tubule are characterized by their shape and size and by their epithelial lining.

The Malpighian corpuscle has a diameter of from 120 μ to 220 μ. The capsule surrounding the glomerulus consists of two layers, which are to be distinguished from each other when its relation to the glomerulus is taken into consideration. The capsule forms a double-walled membrane around the glomerulus; a condition which is easily understood by imagining an invagination of the

glomerulus into the hollow capsule. Between the inner wall covering the surface of the glomerulus (glomerular epithelium) and the outer wall (Bowman's capsule) there remains a cleft-like space which communicates with the lumen of the corresponding uriniferous tubule. In the adult the glomerular epithelium is very flat, with nuclei projecting slightly into the open space of the Malpighian corpuscle. The epithelium of the outer wall is somewhat higher, but still of the squamous type. The capsule of Bowman communicates with the proximal convoluted tubule by means of a short and narrow neck. Its epithelium passes over gradually into

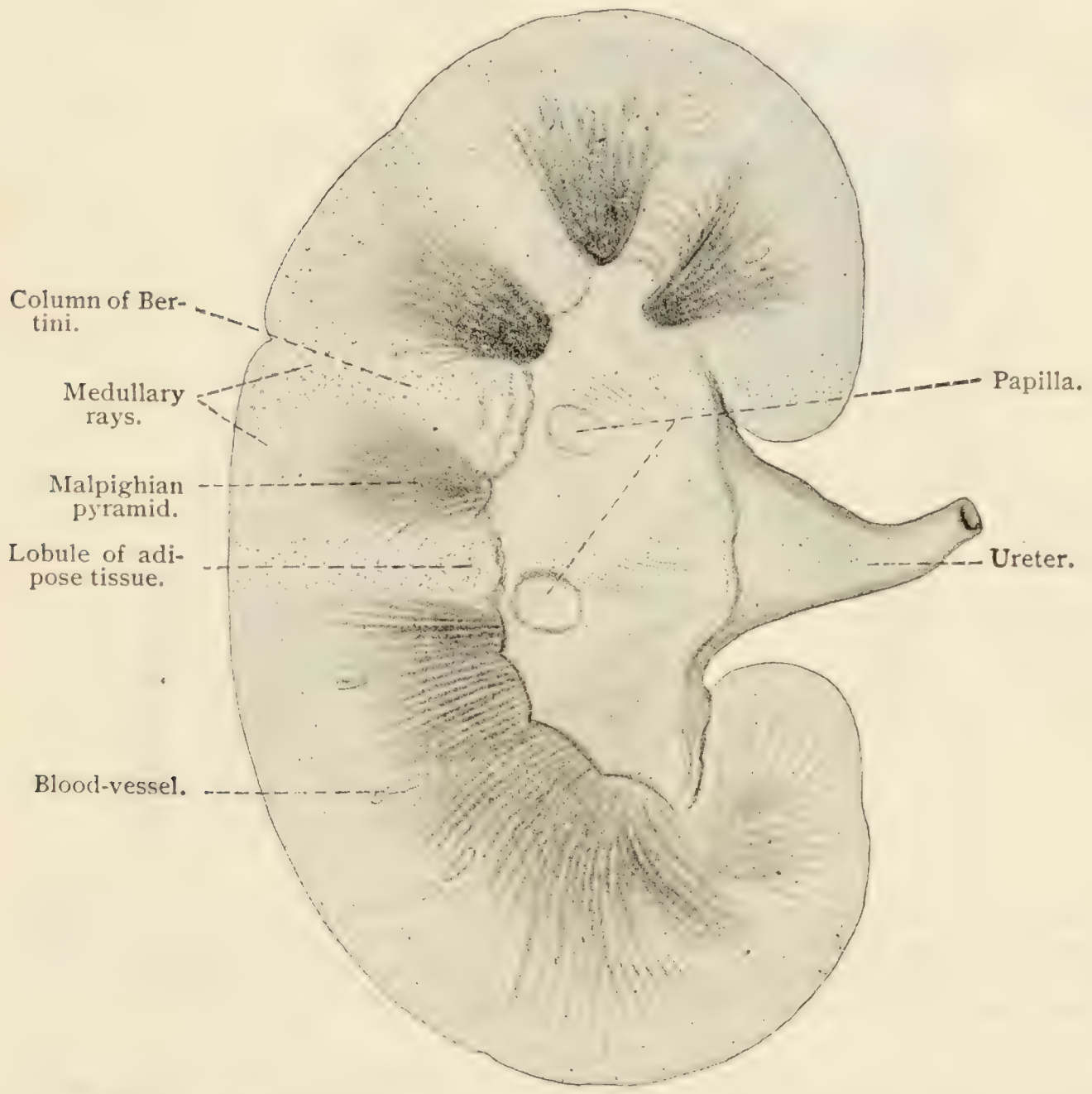

Fig. 261.—Median longitudinal section of adult human kidney; nine-tenths natural size. In the peripheral portion the limits between its renal lobes are no longer recognizable.

the cubical epithelium of the neck, which, in turn, merges into that of the proximal convoluted tubule.

The *proximal convoluted portion* is from 40 μ to 70 μ in diameter and is lined by a single layer of irregular columnar cells, the boundaries of which are made out with difficulty. The structure of these cells has been studied in recent years by a number of investigators, among whom may be mentioned Disse, whose account

is here followed. In the epithelial cells of the proximal convoluted portion there may be recognized an outer or basal portion of the cells, in which there is found a spongioplastic network with rectangular meshes, with cytoreticular fibrils running parallel and at right angles to the basement membrane. In the meshes of this network there is found hyaloplasm. The cytoreticular fibrils which are at right angles to the basement membrane contain numerous granules, giving the basal portions of the cells a striated appearance. The inner portions of the cells contain a cytoreticulum and hyaloplasm; the reticular fibrils do not, however, contain granules,

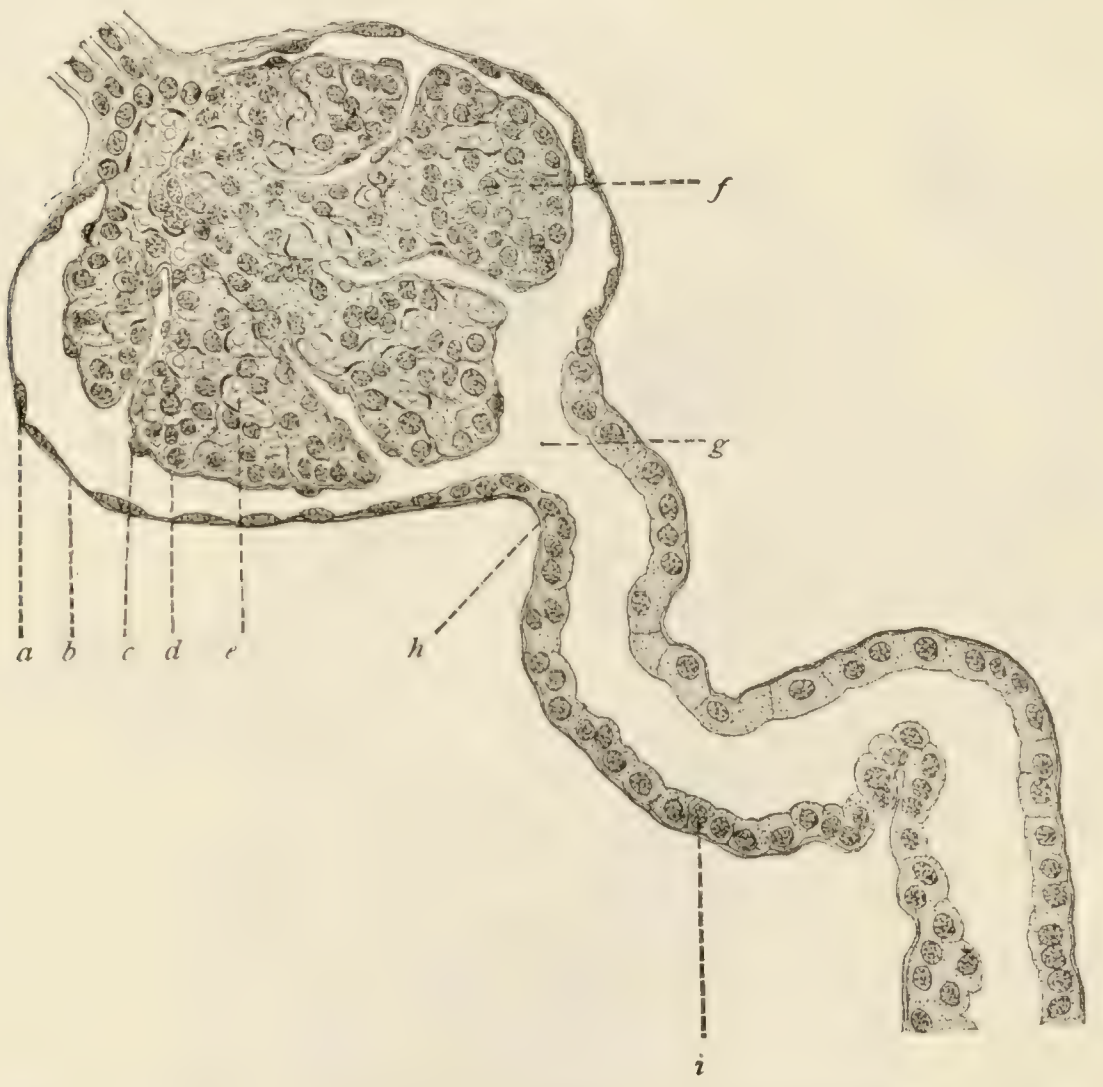

Fig. 262.—From section of cortical substance of human kidney; × 240: *a*, Epithelium of Bowman's capsule; *b* and *d*, membrana propria; *c*, glomerular epithelium; *e*, blood-vessels; *f*, lobe of the glomerulus; *g*, commencement of uriniferous tubule; *h*, epithelium of the neck; *i*, epithelium of proximal convoluted tubule.

the inner portions of the cells presenting, therefore, a much less striated appearance than the outer portions. In tissues not well fixed there is often observed in the cells a free border which presents the appearance of being made of stiff fibrils or coarse and short cilia, which has been interpreted as a distinctive structure. Such a striated border is in all probability a result of partial disintegration or maceration of the cells. The nucleus of these cells is of nearly spheric shape and is situated in the inner part of the basal portions of the cells. The cells, especially in their inner non-striated regions, are so intimately connected that the cell limits are not always distinguishable. In the guinea-pig the basal regions of the lateral

surfaces of the cells constituting the epithelium of the proximal convoluted portion present numerous projections which interlock and give to a surface view an irregular fringe-like outline. In cross-section the cells *appear* to be striated from their bases upward to the middle of the nucleus. Here, however, the striation is without doubt due to the outlines of the irregular ridges. (Fig. 264.) These structural relations have lately been confirmed in the case of the guinea-pig, and also found to hold true for man (Landauer). This striation is much coarser than that found in the basal portions of the cells, but both are, under certain circumstances, seen together.

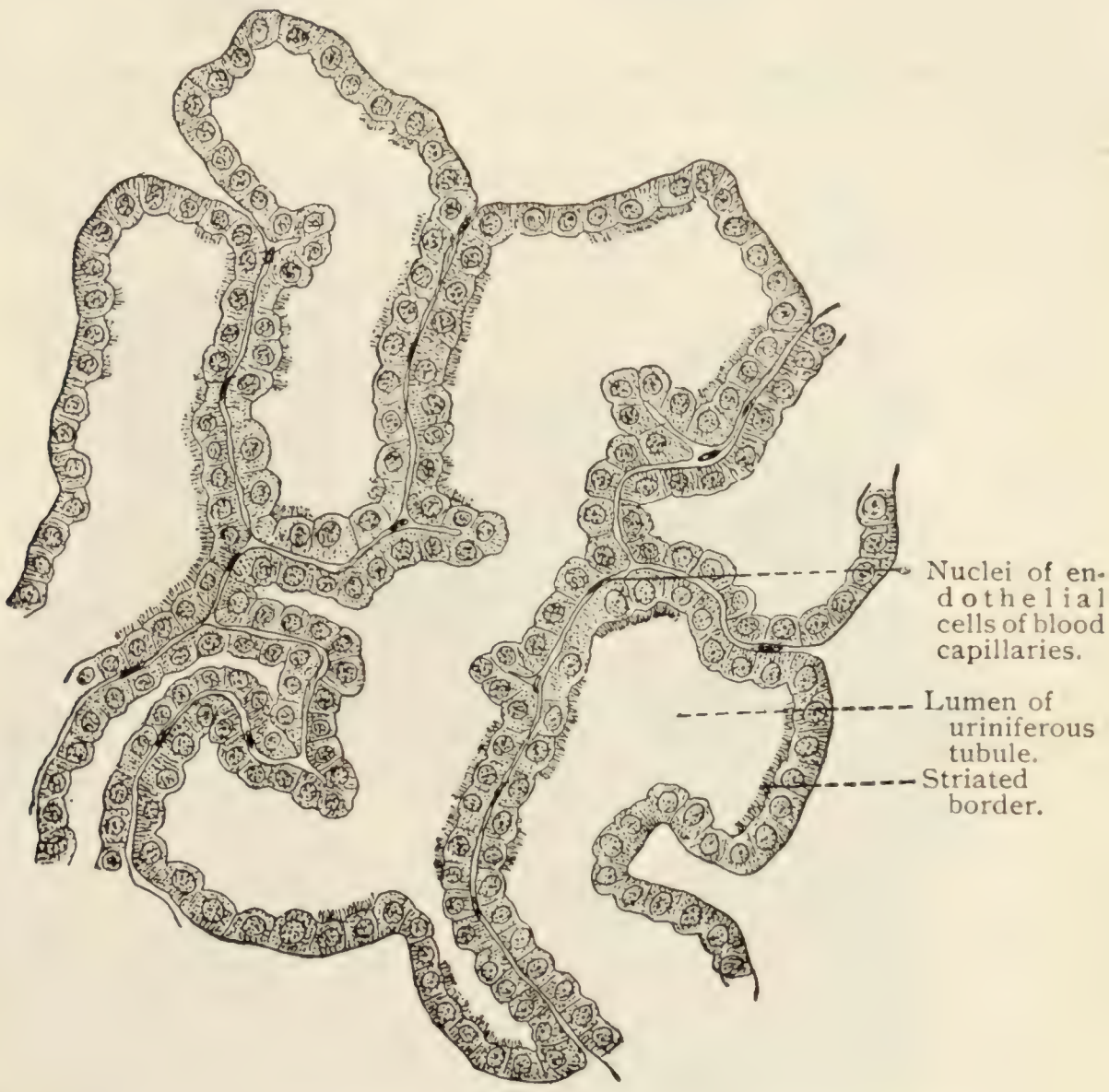

Fig. 263.—Section of proximal convoluted tubules from man; × 580.

The proximal convoluted portion of the uriniferous tubule, before it terminates, passes over into a straighter portion, which gradually becomes smaller in diameter, and is situated in the medullary rays. This portion of the uriniferous tubule, which is sometimes designated as the *spiral segment* of Schachowa, or again as the end segment of Argutinski, is lined by an epithelium which is similar to that of the proximal convoluted portion, as above described. The attenuated end of the spiral segment is continuous with the descending limb of Henle's loop.

The *descending limb of Henle's loop*, from 9 μ to 15 μ in diameter, is narrow and possesses flattened epithelial cells, the centers of

which, containing the nuclei, project into the lumen of the tubule. These central projections of the cells are not directly opposite those of the cells on the opposite wall, but alternate with the latter, thus

Fig. 264.—Epithelium from proximal convoluted tubule of guinea-pig, with surface and lateral views (chrome-silver method); × 590: *a*, *a*, The irregular interlacing projections.

Fig. 265.—From cortical portion of longitudinal section of kidney of young child.

giving to the lumen a zigzag outline corresponding to the length of the cell. The thick portion of the loop, for the most part represented by the ascending limb, but generally embracing the loop itself,

from 23 μ to 28 μ in diameter, possesses a columnar epithelium similar to that of the proximal convoluted portion. Here, however, the basal striation of the cells is not so distinct, the lumen is somewhat larger than that of the descending limb, and by treatment with certain reagents the epithelium may often be separated as a whole from the underlying basement membrane.

The *distal convoluted* or *intercalated portion* (segment of Schweigger-Seidel), from 39 μ to 45 μ in diameter, is only slightly curved (2 to 4 convolutions). Its epithelium is relatively high, though not so high as that lining the proximal convoluted portion and not so distinctly striated, though containing numerous granules. The cells are provided with large nuclei and their basal portions are joined by interlacing projections.

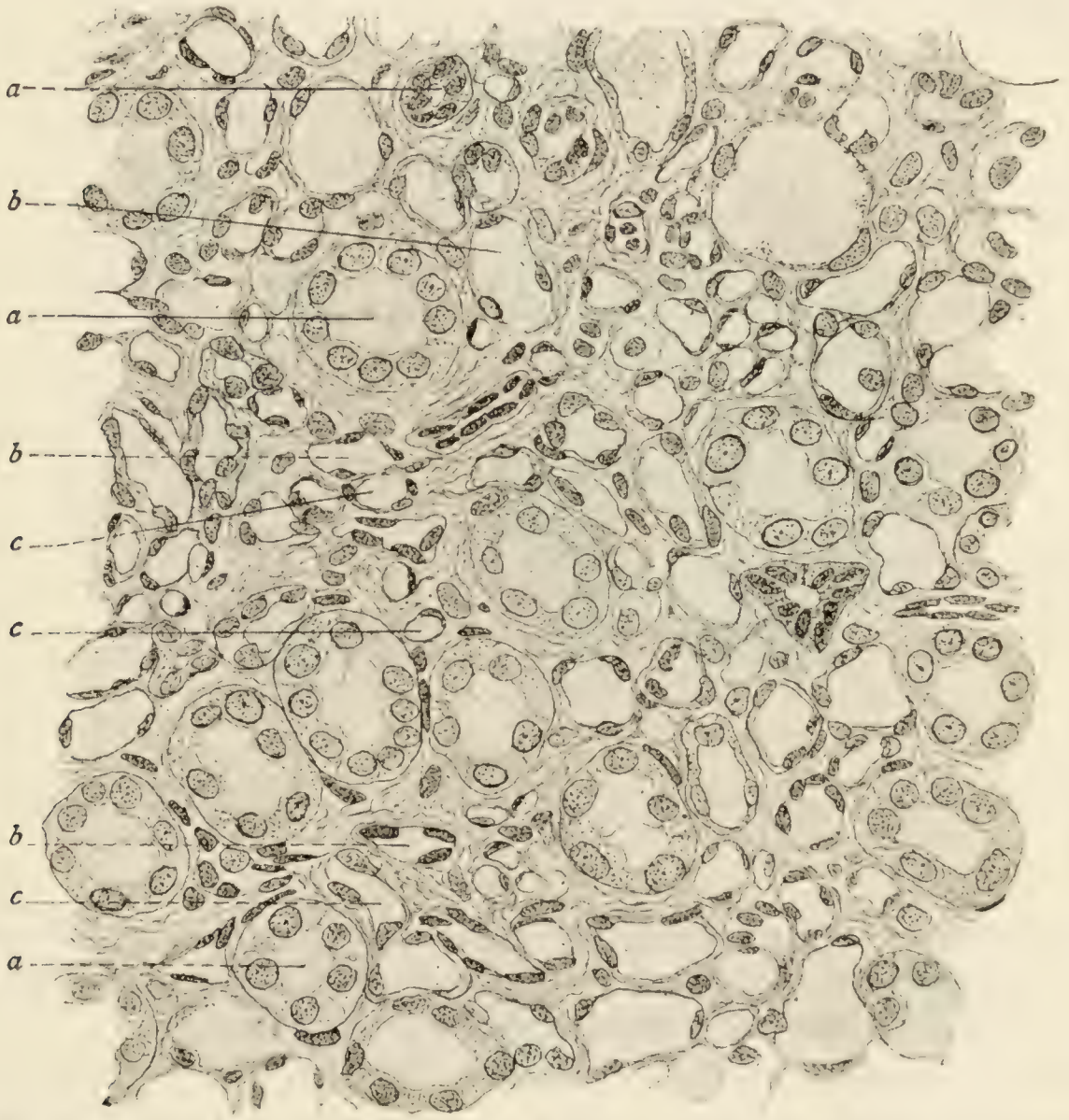

Fig. 266.—Section of medulla of human kidney; × about 300: *a*, *a*, *a*, Ascending limb of Henle's loop; *b*, *b*, *b*, blood vessels; *c*, *c*, *c*, descending limb of Henle's loop.

The next important segment is the short *arched collecting portion*, which has nearly cubical epithelial cells and a lumen somewhat wider than that of the intercalated tubule. The smaller straight collecting tubules have a low columnar epithelium with cells of somewhat irregular shape, the basal portions of which are provided with short, irregular, intertwining processes, which serve to hold the cells in place. The diameter of the collecting tubules measures from 45 μ to 75 μ.

In the larger collecting tubules the epithelium is more regular and becomes higher as the tube widens. These tubules gradually unite within the Malpighian pyramid and the regions adjacent to the columns of Bertini to form 15 to 20 papillary ducts from 200 μ to 300 μ in diameter. The latter have a high columnar epithelium, and empty into the pelvis of the kidney at the apex of the papilla, forming the *foramina papillaria* in an area known as the area cribrosa.

Besides the epithelium, the uriniferous tubules possess an apparently structureless membrana propria, that of the collecting tubules being very thin. This membrane may be isolated, as has been shown by F. P. Mall, by macerating frozen sections in a cold saturated solution of bichromate of soda for several days. This membrane is digested in pancreatin.

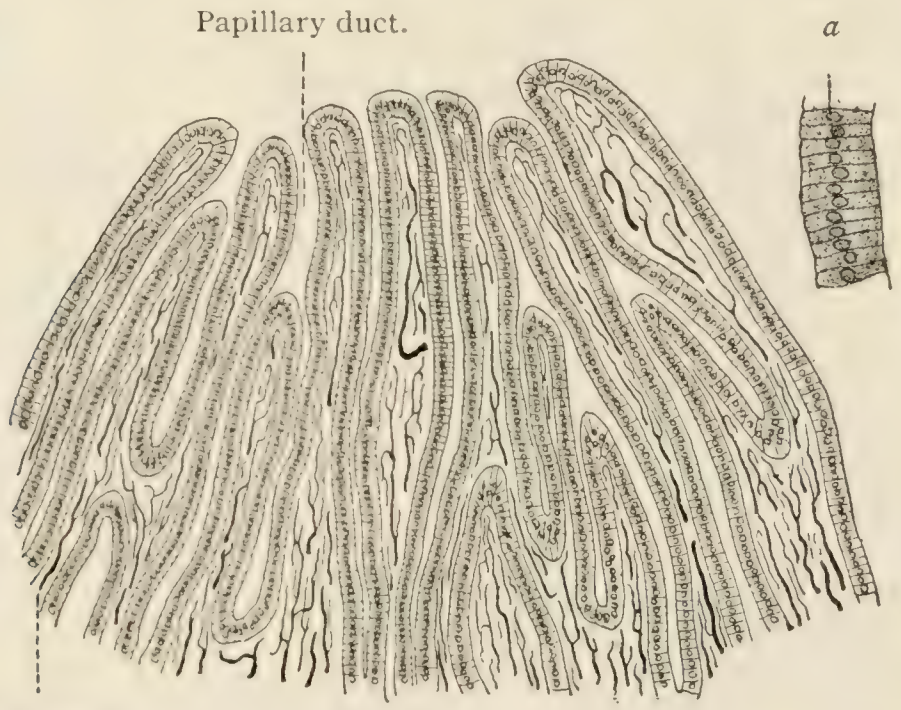

Fig. 267.—From longitudinal section through papilla of injected kidney; $\times$ 40: *a*, Epithelium of collecting tubule under greater magnification.

Between the Malpighian pyramids are found the *columns of Bertini*, presenting a structure similar to that of the cortex of the kidney, and extending to the hilum of the kidney.

Between the uriniferous tubules and surrounding the blood-vessels of the kidney there is found normally a small amount of stroma tissue, consisting of white fibrous and reticular fibers, elastic fibers being found in connection with the blood-vessels (F. P. Mall, Rühle). Between the convoluted portions of the tubules this is present only in small quantity, the fibrils being felted to form sheaths for the tubules; a somewhat greater amount being found in the neighborhood of the Malpighian corpuscles, in the boundary zone between the cortex and medulla and between the larger collecting tubules in the apices of the Malpighian pyramids.

From what has been said concerning the uriniferous tubule it must be evident that its course is a very tortuous one. Beginning

with the Malpighian corpuscles, situated in the cortex between the medullary rays, the tubule winds from the cortex to the medulla and back again into the cortex, where it ends in a collecting tubule, which passes to the medulla to terminate at the apex of a Malpighian pyramid. The different portions of the tubules have the following positions in the kidney : In the cortex between the medullary rays are found the Malpighian corpuscles, the neck, the proximal and distal convoluted portions of the uriniferous tubule, and the arched collecting tubules. The medullary rays are formed by the cortical portions of the straight collecting tubules and a portion of

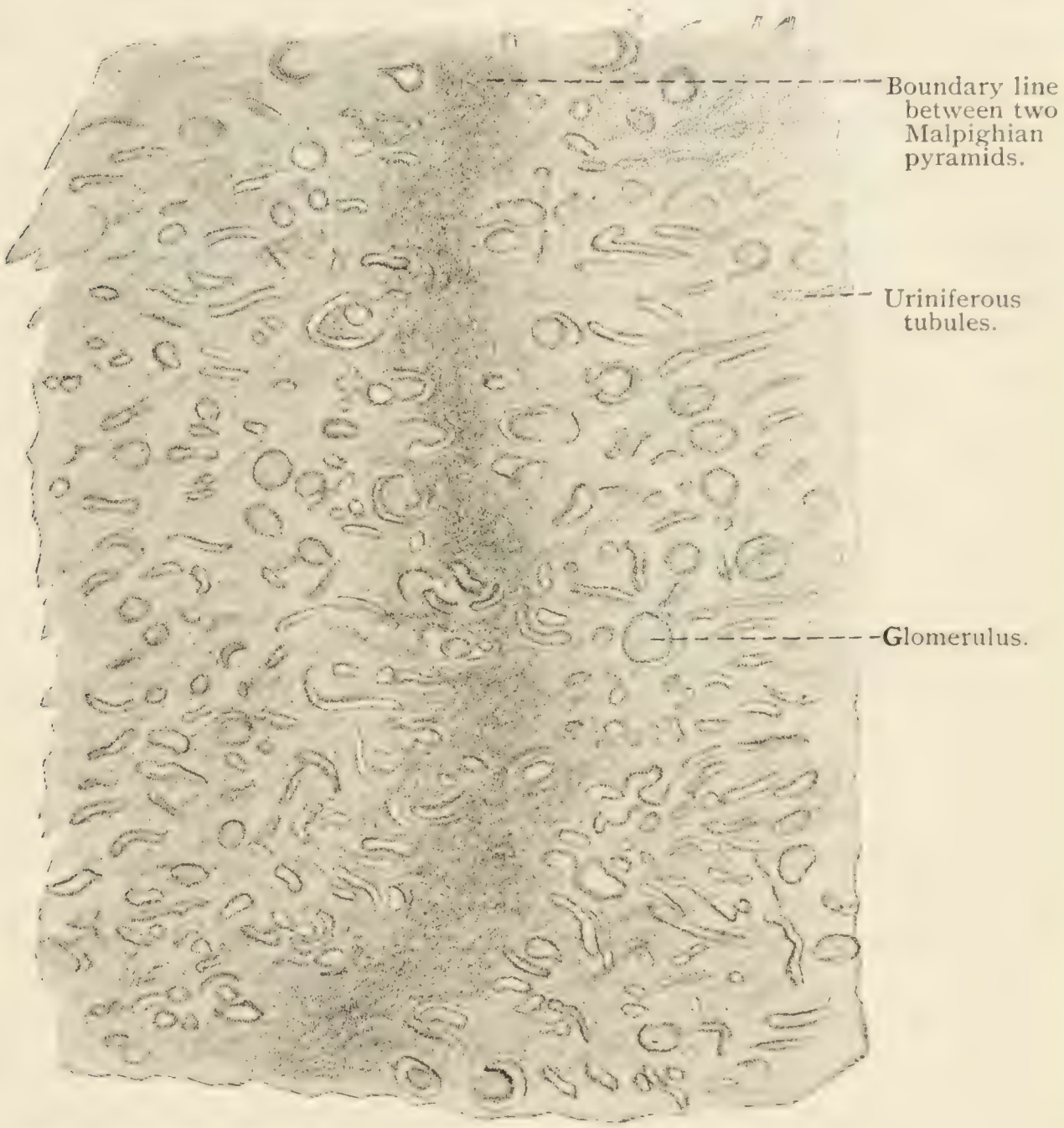

Fig. 268.—Section through junction of two lobules of kidney, showing their coalescence ; from new-born infant.

the descending and ascending limbs of Henle's loops. The medulla is made up mainly of straight collecting tubules of various sizes and of the descending and ascending limbs and loops of Henle's loops, the latter being often found in the boundary zone between the cortex and medulla. (See Fig. 266.) The ascending limb of Henle's loop of each uriniferous tubule, after it enters the cortex, comes into close proximity with the Malpighian corpuscle of the respective uriniferous tubule.

The **blood-vessels** of the kidney have a characteristic distribution, and are in the closest relationship to the uriniferous tubules.

The renal artery, as has been shown by Brödel, divides at the hilum on an average into four or five branches, about three-fourths of the blood-supply passing in front of the pelvis, while one-fourth runs posteriorly. The portion of the kidney supplied by the anterior branches is in its blood-supply quite distinct from that supplied by the posterior branches; the one set of branches do not cross over to the other. The two ends of the kidney are supplied by an anterior and a posterior branch, each of which generally divides into three branches, which pass respectively, one anteriorly, one posteriorly, and one around the end of the uppermost and the lowest calyx.

The main branches of the renal artery give off lateral branches to the renal pelvis, supplying its mucous membrane and then breaking up into capillaries which extend as far as the "area cribrosa." The venous capillaries of this region empty into veins which accompany the arteries. Besides these, other arteries originate from the principal branches, or from their immediate offshoots, and pass backward to supply the walls of the renal pelvis, the renal capsule, and the ureter. The main trunks themselves penetrate at the hilum, and divide in the columns of Bertini to form arterial arches (arteriæ arciformes) which extend between the cortical and medullary substances. Numerous vessels, the *intralobular arteries*, originate from the arteriæ arciformes and penetrate into the cortical pyramids between the medullary rays. Here they give off numerous twigs, each of which ends in the glomerulus of a Malpighian corpuscle. These short lateral twigs are the *vasa afferentia*. Each glomerulus is formed by the breaking down of its afferent vessel, which, on entering the Malpighian corpuscle, divides into a number of branches, five in a glomerulus of a child three months old reconstructed by W. B. Johnston, each in turn subdividing into a capillary net. From each of these nets the blood passes into a somewhat larger vessel constituting one of the branches of the efferent vessel which carries the blood away from the glomerulus. Since the afferent and efferent vessels lie in close proximity, the capillary nets connecting them are necessarily bent in the form of loops. The groups of capillaries in a glomerulus are separated from each other by a larger amount of connective tissue than separates the capillaries themselves, so that the glomerulus may be divided into lobules. In shape the glomerulus is spheric, and is covered by a thin layer of connective tissue over which lies the inner membrane of the capsule, the glomerular epithelium. On its exit from the glomerulus the vas efferens separates into a new system of capillaries, which gradually becomes venous in character. Thus, the capillaries which form the glomerulus, together with the vas efferens, are arterial, and may be included in the category of the so-called arterial retia mirabilia. Those capillaries formed by the vas efferens after its exit from the Malpighian corpuscle lie both in the medullary

rays and in the cortical pyramids. The meshes of the capillary networks distributed throughout the medullary rays are considerably longer than those of the networks supplying the cortical pyramids and labyrinth, the latter being quadrate in shape. The glomeruli nearest the renal papillæ give off longer vasa efferentia which extend into the papillary region of the Malpighian pyramids (arteriolæ rectæ spuriæ) and form there capillaries which ramify throughout the papillæ with oblong meshes.

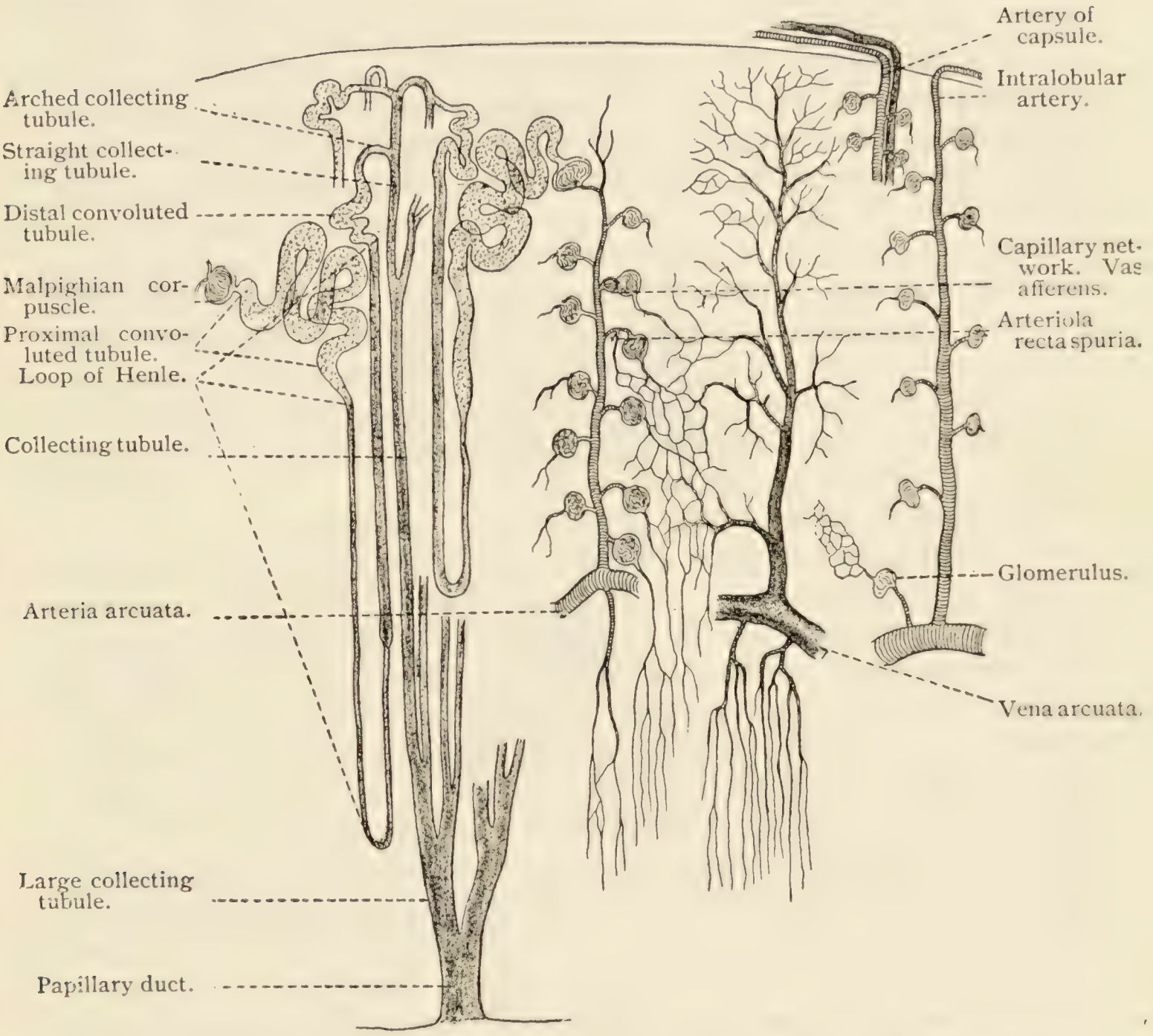

Fig. 269.—Diagrammatic scheme of uriniferous tubules and blood-vessels of kidney. Drawn in part from the descriptions of Golubew.

Arterial retia mirabilia also occur in the course of the vasa afferentia between the intralobular arteries and the glomeruli, but nearer the latter. Each is formed by the breaking down of the small afferent vessels into from two to four smaller branches, which then reunite to pass on as a single vessel. In structure these retia differ greatly from the glomeruli in that here the resulting twigs are not capillaries and have nothing to do with the secretion of urine (Golubew).

From the vasa afferentia arterial twigs are occasionally given

off, which break down into capillaries within the cortical substance. Other arteries originate from the lower portion of the intralobular arteries or from the arciform arteries themselves and enter the medullary substance, where they form capillaries. These vessels constitute the so-called "arteriolæ rectæ veræ." Their capillary system is in direct communication with the capillaries of the vasa afferentia and "vasa recta spuria." The intralobular arteries are not entirely exhausted in supplying the vasa afferentia which pass to the glomeruli. A few extend to the surface of the kidney and penetrate into the renal capsule, where they terminate in capillaries which communicate with those of the recurrent, suprarenal, and phrenic arteries, etc. Smaller branches from these latter vessels may penetrate the cortex and form glomeruli of their own in the renal parenchyma (arteriæ capsulares glomeruliferæ). These relations, first described by Golubew, are of importance not only in the establishment of a collateral circulation, but also as a partial functional substitute in case of injury to the renal arteries. The same author also confirms the statements of Hoyer (77) and Geberg, that between the arteries and veins of the kidney, in the cortical substance, in the columns of Bertini, and at the bases of the Malpighian pyramids, etc., direct anastomoses exist by means of precapillary twigs.

From the capillaries the venous blood is gathered into small veins which pass out from the region of the medullary rays and cortical pyramids and unite to form the "intralobular veins." These have an arrangement similar to that of the corresponding arteries. The venous blood of the labyrinthian capillaries also flows into the intralobular veins, and as a result a peculiar arrangement of these vessels is seen at the surface of the kidney where the capillaries pass radially toward the terminal branches of the intralobular veins and form the stellate figures known as the *venæ stellatæ*. This system is also connected with those venous capillaries of the capsule which do not empty into the veins accompanying the arteries of the capsule. The capillary system of the Malpighian pyramids unites to form veins, the "venulæ rectæ," which empty into the venous arches (venæ arciformes) which lie parallel with and adjacent to the corresponding arteries. The larger veins are found side by side with the arteries and pass out at the hilum of the organ.

Lymphatics of the kidney may be divided into superficial lymphatic vessels, situated in the capsule, and deep ones, found in the substance of the kidney. The deep lymphatic vessels need to be investigated further. They form a network of closed lymphatic vessels throughout the cortex. These empty, according to Rindowsky, into larger lymphatics, which follow the intralobular vessels; and, according to Stahr, into larger vessels situated in the medullary rays. The lymphatic vessels of the kidney proper (deep vessels) leave this organ at the hilum.

The kidneys receive their innervation through nonmedullated

and medullated nerve-fibers. The former accompany the arteries and may be traced along these to the Malpighian corpuscles. From the plexuses surrounding the vessels small branches are given off, which end on the muscle-cells of the media. According to Berkley, small nerve-fibrils may be traced to the uriniferous tubules, which pierce the membrana propria and end on the epithelial cells. Smirnow has also traced nerve-fibers to the epithelial cells of the uriniferous tubules and the Malpighian corpuscles. Dogiel has shown that medullary (sensory) nerve-fibers terminate in the adventitia of the arteries of the capsule.

The secretory processes of the kidney can be considered only briefly in this connection. The theories concerning uriniferous secretion may be grouped under two heads: namely, the theory of C. Ludwig, who believed that all the constituents of the urine

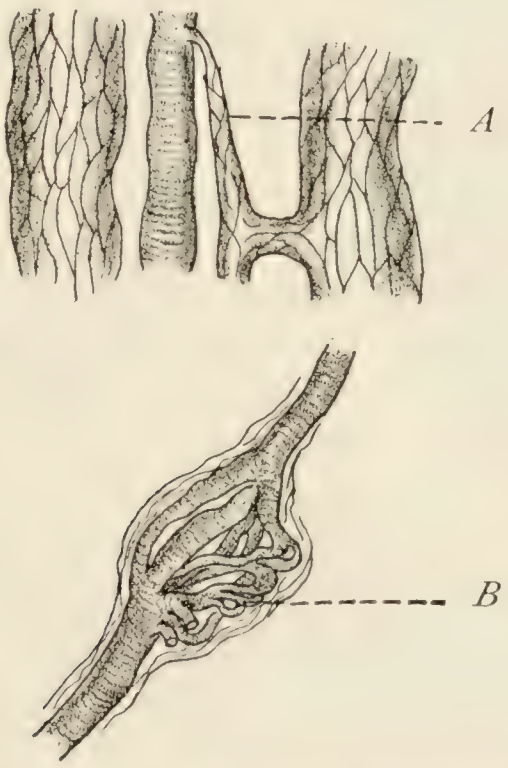

Fig. 270.—*A*, Direct anastomosis between an artery and vein in a column of Bertin of child; *B*, bipolar rete mirabile inserted in the course of an arterial twig. Dog's kidney (after Golubew).

leave the blood through the glomeruli, entering the uriniferous tubules as a urine containing a large percentage of water, which is concentrated in its passage through the uriniferous tubule by the absorption of water; while according to the theory of Bowman, and later Heidenhain, only the water and inorganic salts leave the blood through the glomerulus, and that in the proportion found in the urine, while the urea is secreted by the epithelial cells of the uriniferous tubules, and mainly in those portions of the tubules possessing a striated epithelium. The majority of writers who have considered the question of urinary excretion have directly or indirectly expressed themselves as adherents to one or the other of the above theories. A number of recent observers have departed somewhat from either of the above theories, and of these we may

mention especially the careful researches of Cushny, who brings forth strong proof to show that with the fluid passing through the glomerular epithelium there are carried certain salts and urea, the salts and urea in the proportion in which they occur in the blood-plasma, and that in passage through the uriniferous tubules a certain percentage of the fluids and certain salts are again absorbed, the salts in proportion to their diffusibility or their permeability of the renal cells.

The permanent kidney is developed as early as the fifth week of embryonic life. The renal anlagen, from which the epithelium of the ureter, renal pelvis, and a portion of the uriniferous tubules is formed, originate from the median portion of the posterior wall of the Wolffian duct. These buds grow with their blind ends extending anteriorly, and are soon surrounded by cellular areas, the blastema of the kidneys. After the renal bud has become differentiated into a narrow tube (the ureter) and a wider central cavity (the renal pelvis) hollow epithelial buds are developed from the latter. These extend radially toward the surface of the renal anlagen, where they undergo a T-shaped division. These latter are the first traces of the papillary ducts and collecting tubules. The ends of these T-shaped divisions are surrounded by a cellular tissue, derived from the mesoderm, which is known as the renal blastema or the nephrogenic tissue. In this tissue there are differentiated spheric masses of cells, which in their further growth differentiate into S-shaped structures one end of which unites with the ends of the epithelial buds, developed as above described. The S-shaped structures acquire a lumen and form the anlagen of the uriniferous tubules, from the arched collecting tubules to and including Bowman's capsule. The ducts of the kidneys, from the papillary ducts to the collecting tubules of the medullary rays, have their origin from the epithelial buds which develop from the side of the Wolffian ducts, while the uriniferous tubules proper have their origin in the nephrogenic tissues.

2. THE PELVIS OF THE KIDNEY, URETER, AND BLADDER.

The renal pelvis, ureter, and urinary bladder are lined by stratified transitional epithelium. Its basal cells are nearly cubical; these support from two to five rows of cells of varying shape. They may be spindle-shaped, irregularly polygonal, conical, or sharply angular, and provided with processes. Their variation in form is probably due to mutual pressure. The superficial cells are large and cylindric, a condition characteristic of the ureter and bladder. Their free ends and lateral surfaces are smooth, but their bases present indentations and projections due to the irregular outlines of the underlying cells. The superficial cells often possess two or more nuclei.

The mucosa often contains diffuse lymphoid tissue, which is more highly developed in the region of the renal pelvis. Here also there are found folds or ridges of mucosa which extend into the epithelium and present the appearance of papillæ when seen in cross-section. A few mucous glands are also met with in the pelvis and in the upper portion of the ureter in certain mammals; in man, however, no typical glands are found, although solid

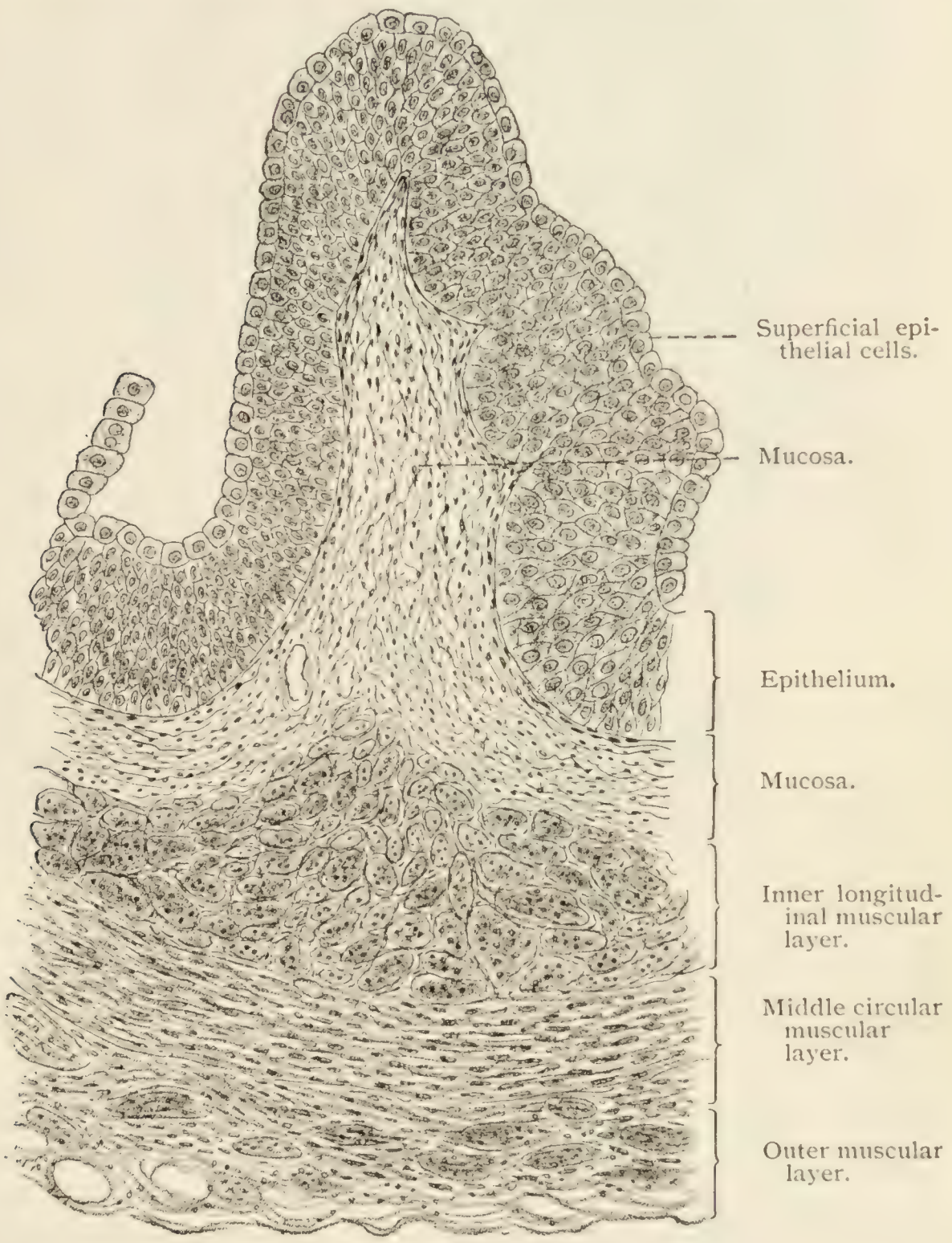

Fig. 271.—Section of lower part of human ureter; × 140.

epithelial buds, which extend into the mucosa for a distance, have been described. The ureter possesses two layers of nonstriated muscle-fibers—the inner longitudinal, the outer circular. From the middle of the ureter downward a third external muscular layer is found with nearly longitudinal fibers.

The urinary bladder has no glands, and its musculature apparently consists of a feltwork of nonstriated muscle bundles, a condi-

tion particularly well seen in sections of the dilated organ. But even here three indistinct muscle layers may be distinguished, the outer and inner layers being longitudinal and the middle circular. A remarkable peculiarity of these structures is the extreme elasticity of their epithelium, the cells flattening or retaining their natural shape according to the amount of fluid in the cavities which they

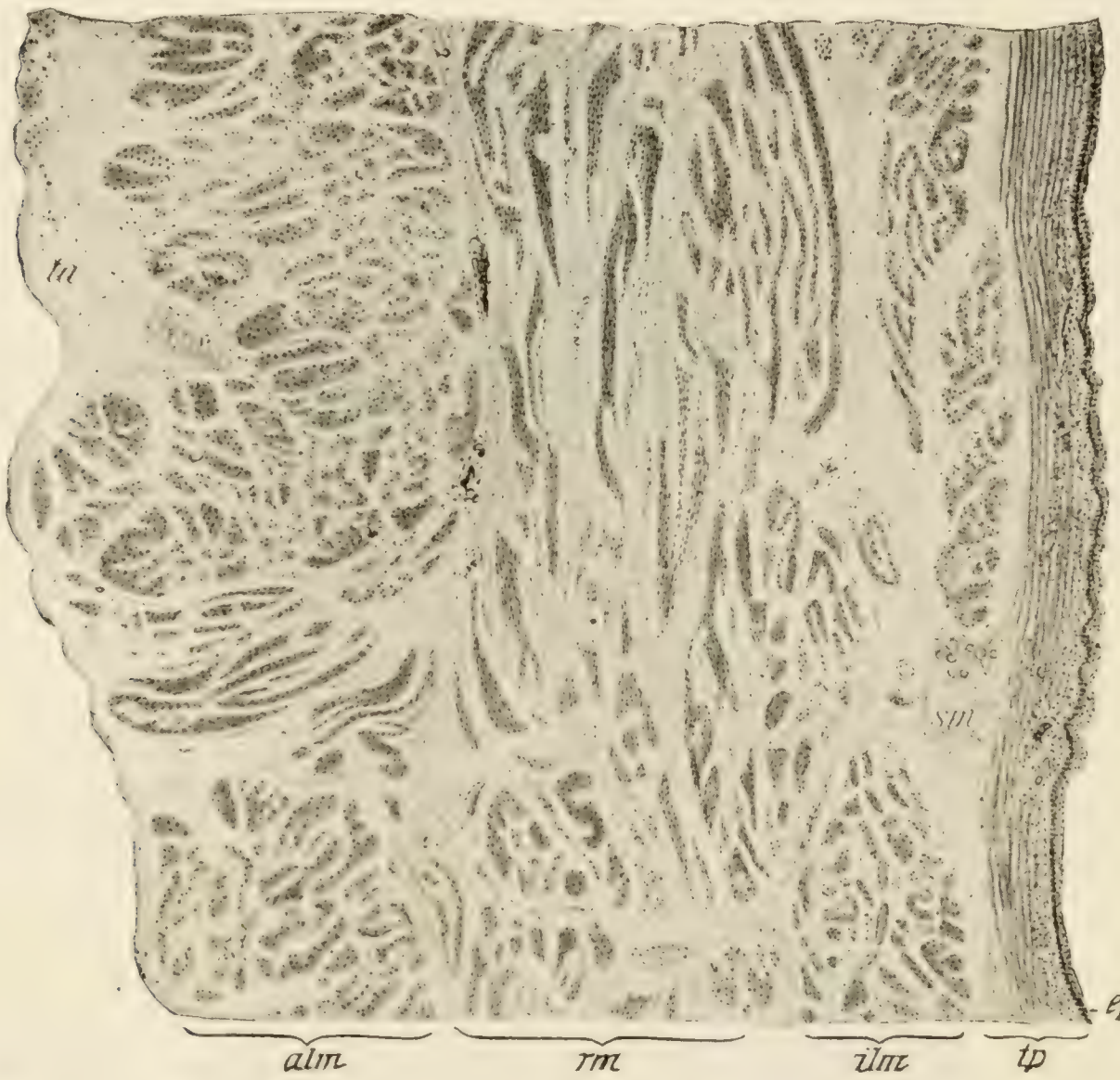

Fig. 272.—Transverse section of the wall of the human bladder, giving a general view of its structure. × 15. *ep*, Epithelium; *tp*, tunica propria or mucosa; *sm*, submucosa; *ilm*, inner longitudinal layer of muscle; *rm*, circular layer of muscle; *alm*, external longitudinal layer of muscle; *ta*, tunica adventitia.

line (compare London, Kann). The terminal blood-vessels of the mucosa of the pelvis of the kidney deserve special mention. The capillaries arise from arterioles which are situated in the ridges of the mucosa above mentioned. The capillaries are peculiar in that they are not completely surrounded by connective tissue, but are in part embedded in the epithelium, the epithelial cells resting on the endothelial wall of the capillaries (Disse). The blood-vessels of the bladder anastomose in the tunica adventitia, smaller branches pass to the muscular tissue. The main stems of the vessels form a plexus in the submucosa, from which arise the capillaries of the mucosa. The veins form submucous, muscular, and subperitoneal plexuses (Fenwick). Lymphatic vessels are found only in the muscular coat and not in the mucosa.

The nerve supply of the bladder has been studied by Retzius, Huber, and Grünstein in the frog and a number of the smaller mammalia. Numerous sympathetic ganglia are observed, situated outside of the muscular coat, at the base and sides of the bladder. The neuraxes of the sympathetic neurones of these ganglia are grouped into smaller or larger bundles which interlace and form plexuses surrounding the bundles of nonstriated muscle-cells. From these plexuses nerve-fibers are given off, which penetrate the muscle bundles and end on the muscle-cells. The cell-bodies of the sympathetic neurones are surrounded by the telodendria of small medullated fibers, which terminate in the ganglia. Passing through the ganglia large medullated fibers (sensory nerves) may be observed which pass through the muscular coat, branch repeatedly in the mucosa, and lose their medullary sheaths on approaching the epithelium in which they end in numerous telodendria, the small branches of which terminate between the epithelial cells.

The ureters are surrounded by a nerve plexus containing nonmedullated and medullated nerve-fibers. The former end on cells of the muscular layers; the latter pass through the muscular layer, and on reaching the mucosa branch a number of times before losing their medullary sheaths. The nonmedullated terminal branches form telodendria, the terminal fibers of which have been traced between the cells of the lining epithelium (Huber).

B. THE SUPRARENAL GLANDS.

The suprarenal gland is surrounded by a fibrous-tissue capsule containing nonstriated muscle-cells, blood- and lymph-vessels, nerves, and sympathetic ganglia. The glandular structure is divided into a cortical and a medullary portion. In the former are distinguished three layers, according to the arrangement, shape, and structure of its cells—an outer glomerular zone, a middle broad fascicular zone, and an inner reticular zone. According to Flint, who worked in F. P. Mall's laboratory, and whose account will here be followed, the framework of the gland is made up of reticulum. In the glomerular zone this reticulum is arranged in the form of septa, derived from the capsule, which divide this zone into more or less regular spaces of oval or oblong shape. In the fascicular zone the reticulum is arranged in processes and fibrils running at right angles to the capsule. In the reticular zone the fibrils form a dense network, while in the medulla the reticular fibrils are arranged in processes and septa which outline numerous spaces.

The gland-cells of the glomerular zone are arranged in coiled columns of cells found in the compartments formed by the septa of reticulum above mentioned. The cells composing these columns are irregularly columnar, with granular protoplasm and deeply staining nuclei. In the fascicular zone the cells are arranged in regular

columns, consisting usually of two rows of cells, and situated between the reticular processes, which run at right angles to the capsule. The cells of this zone are polyhedral in shape, with granular protoplasm often containing fat droplets and with nuclei containing little chromatin. Similar cells are found in the reticular zone, but here they are found in small groups situated in the meshes of the reticulum. The cells of the medullary substance are less granular and smaller in size than those of the cortex, and are grouped in irregular, round, or oval masses bounded by the septa of reticulum. These cells stain a deep brown with chromic acid and its

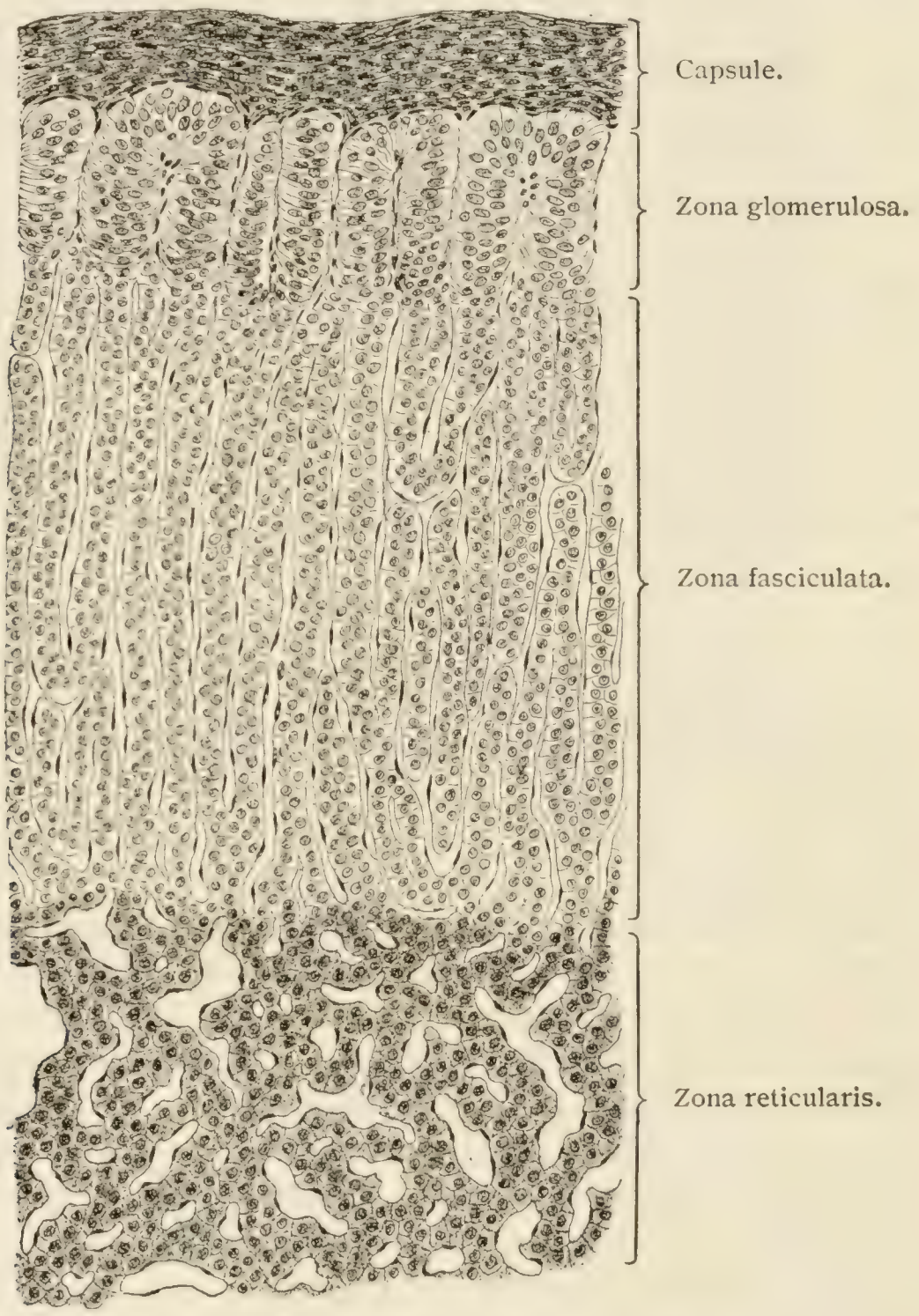

Fig. 273.—Section of suprarenal cortex of dog ; × 120.

salts are therefore known as chromaffin cells ; the color cannot be washed out with water—a peculiarity which shows itself even during the development of these elements, and which is possessed by few other types of cells. Numerous ganglion cells, isolated and in groups, and many nerve-fibers occur in this portion of the organ.

The blood-vessels of the suprarenal glands are of special interest, since it has been shown that the secretion of the glands passes directly or indirectly into the vessels. The following statements we take from Flint: The blood-vessels, derived from various sources, form in the dog a poorly developed plexus, situated in the capsule. From this plexus three sets of vessels are derived, which are distributed respectively in the capsule, the cortex, and the medulla of the gland. The vessels of the capsule divide into

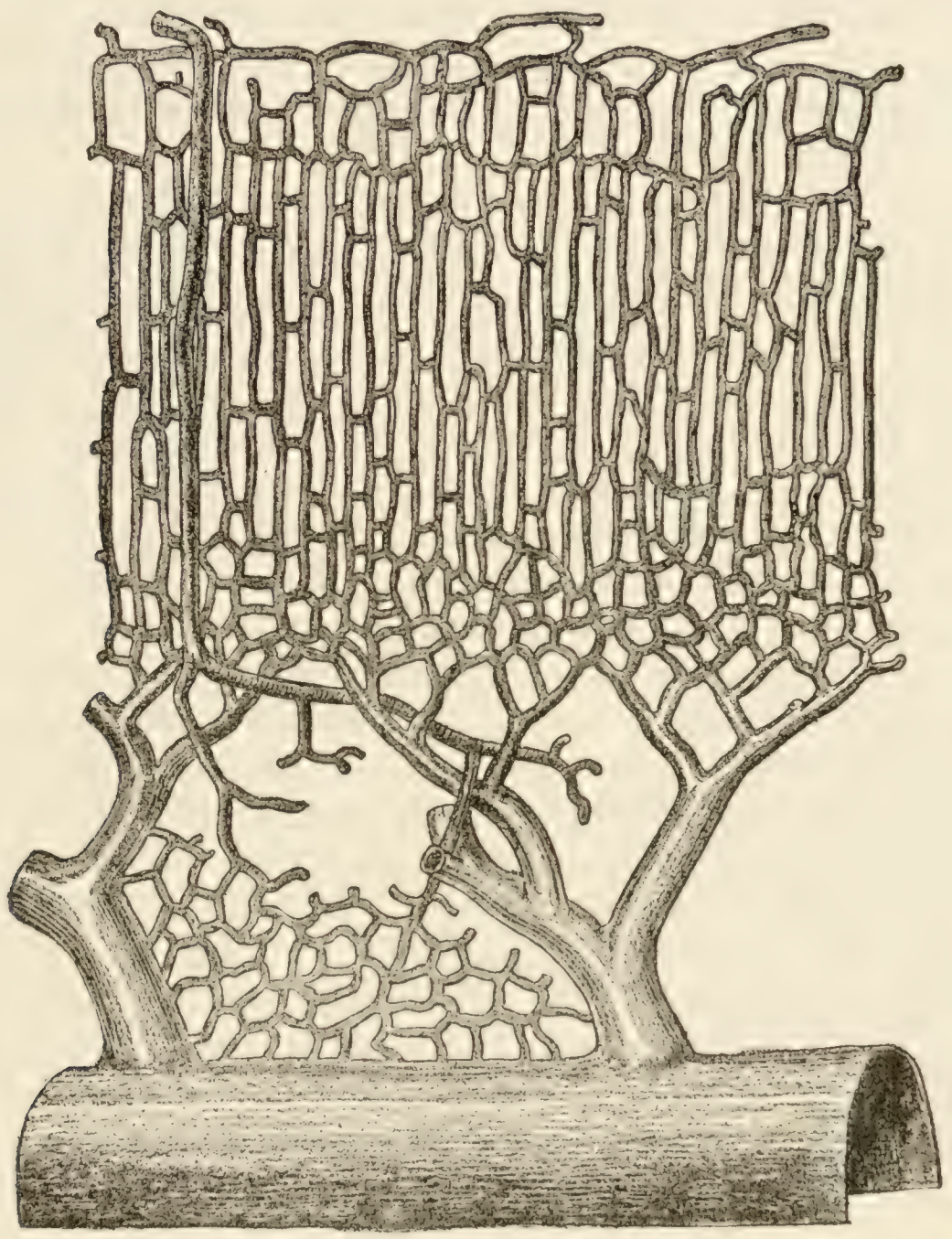

Fig. 274.—Arrangement of the intrinsic blood-vessels in the cortex and medulla of the dog's adrenal (Fig. 17, Plate V, of Flint's article in "Contributions to the Science of Medicine," dedicated to Professor Welch, 1900).

capillaries, which empty into a venous plexus situated in the deeper portion of the capsule. The cortical arteries divide into capillaries which form networks, the meshes of which correspond to the arrangement of the cells in the different parts of the cortex, encircling the coiled columns of cells in the glomerular zone, while in the fascicular zone the capillaries are parallel with occasional anastomoses. These capillaries form a fine-meshed plexus in the reticular zone and unite in the peripheral portion of the

medulla to form small anastomosing veins, from which the larger veins are derived. The latter do not anastomose, and are therefore terminal veins. The arteries of the medulla pass through the cortex without giving off any branches until the medulla is reached, where they break up into a capillary network surrounding the cell masses situated here. The blood from this plexus may be collected into veins of the medulla which empty into the terminal vein or some of its larger branches, or may flow directly into branches of the venous tree. The endothelial walls of the capillaries rest directly on the specific gland cells, with the intervention here and there of a few reticular fibrils. According to Pfaundler, the walls of the blood-vessels of the entire suprarenal body consist solely of the tunica intima.

The **nerves** of the suprarenal glands have been studied recently by Fusari and Dogiel (94); the description given by the latter will here be followed. Numerous nerve-fibers, both nonmedullated and medullated, arranged in the form of a plexus containing sympathetic ganglia, are found in the capsule. From this plexus numerous small bundles and varicose fibers enter the cortex, where they form plexuses surrounding the columns of cells or groups of cells found in the three zones of the cortex and about the vessels and capillaries of the cortex. The nerve-fibers of these plexuses are on the outside of the columns and cell groups and do not give off branches which pass between the cells. The nerve supply of the medullary substance is very rich, and is derived mainly from large nerve bundles which pass from the plexus in the capsule to the medulla, where they divide and form dense plexuses which surround the groups of gland-cells and veins; from these plexuses fine varicose fibers pass between the gland-cells, forming intercellular plexuses. In the medulla there are found in many animals large numbers of sympathetic cells, some isolated, others grouped to form small ganglia. Pericellular networks surround the cell-bodies of certain of these sympathetic cells. (For further information concerning the suprarenal glands consult Gottschau, Weldon, Hans Rabl, C. K. Hoffmann (92), Pfaundler, Flint, and Dogiel.)

TECHNIC.

Kidney.—The arrangement of the cortical and medullary portions of the kidney is best seen in sections of the kidney of small mammalia, cut in the proper direction, and, if possible, embracing the whole organ. If, on the other hand, the finer epithelial structures are to be examined, small pieces are first fixed in osmic acid mixtures or in corrosive sublimate.

Impregnation with silver nitrate (method of Golgi or Cox) reveals some points as to the relation of the cells of the uriniferous tubules to each other.

In order to isolate the tubules, thin strips of kidney tissue are treated for from fifteen to twenty hours with pure hydrochloric acid

having a specific gravity of 1.12 (for this purpose kidney tissue is used taken from an animal killed twenty-four hours previously). It is then washed, teased, and examined in glycerin (Schweiger-Seidel). Fuming nitric acid (40%), applied for a few hours to small pieces of tissue, occasionally isolates the uriniferous tubules very extensively. The further treatment is then the same as after hydrochloric acid. A 35% potassium hydrate solution may also be employed. The isolated pieces are, however, not easily preserved permanently.

The *epithelium* of the uriniferous tubules may be isolated either in ⅓ alcohol or, according to R. Heidenhain (83), in a 5% aqueous solution of neutral ammonium chromate. The latter method shows clearly the striation of the epithelium.

The autophysiologic injection with indigo-carmin, applied as in the case of the liver, fills the uriniferous tubules, which may then be further examined in sections.

The blood-vessels are examined in injected specimens (injection of the kidney is easily accomplished). In larger animals the injection is made into the renal artery, while in smaller ones the whole posterior half of the body is injected through the abdominal aorta.

The **ureter** and **bladder** are cut open, fixed, and then sectioned. In this way the organs are shown in a collapsed condition, in which the arrangement of the epithelium is totally different from that found in the distended organs. In order to observe them in the latter condition the fixing agent is injected into the ureter or bladder, when, after proper ligation, they are placed in the same fixing agent.

The usual fixing fluids are employed in the demonstration of the **suprarenal capsule**; but mixtures containing chromic acid, whether Flemming's fluid, chromic acid, or its salts, are of special importance in the examination of the organ, since the medullary substance of the suprarenal capsule stains a specific brown when treated by these mixtures (a condition only reduplicated in certain cells of the hypophysis). This brown staining also occurs when the cortical and medullary portions are entirely separated, as is the case in certain animals and during the development of the suprarenal capsule. The fat found in the cells of the suprarenal cortex is not identical with that of the rest of the body, as it may be dissolved by chloroform and oil of bergamot out of tissue fixed with osmic acid (Hans Rabl).

C. THE FEMALE GENITAL ORGANS.

1. THE OVUM.

The product of the ovaries is the matured "ovum," or egg, having a diameter of from 0.22 to 0.32 mm. It forms a single cell with a thick membrane, from 7 μ to 11 μ in thickness, known as the zona pellucida. The ovum consists of a cell-body known as the yolk or vitellus, and a nucleus, from 30 μ to 40 μ in diameter, termed the germinal vesicle. The vitellus consists of two substances—a protoplasmic network, with a somewhat denser arrangement at the periphery of the cell and in the neighborhood of the germinal vesicle, and of small, highly refractive, and mostly oval bodies imbedded between the meshes of the protoplasm—the yolk globules. These latter, as a rule, are merely browned on being treated with osmic acid, although occasionally a true fatty reaction may be obtained. The germinal vesicle is surrounded by a distinct membrane having a double contour. In its interior we find a scanty lining framework containing very little chromatin, and one or two relatively large false nucleoli, or germinal spots, from 7 μ to 10 μ in diameter, due to a nodal thickening of the chromatin. In the latter a further very distinct differentiation is sometimes seen in the shape of a small body (vacuole?) of doubtful origin, which has been called Schrön's granule. The germinal vesicle and spot were formerly known as "Purkinje's vesicle" and "Wagner's spot," respectively, from their discoverers.

2. THE OVARY.

The ovaries are almost entirely covered by peritoneum. The mesothelial cells of the latter, however, undergo here a differentiation, to form the germinal epithelium. At the hilum the peritoneal covering is absent, and it is here that the connective-tissue elements of the ovarian ligament penetrate into the organ to form its connective-tissue framework, the so-called *stroma* of the ovary. At an early period in the development of the ovaries, the germinal epithelium begins a process of invagination into the stroma of the ovary, so that at the periphery of the organ a zone is soon formed which consists of both connective tissue and epithelial (mesothelial) elements. This zone is called the *cortex*, or parenchymatous zone. That portion of the organ in the neighborhood of the hilum (aside from the rudimentary structure known as the epoophoron) consists of connective tissue containing numerous elastic fibers and unstriped muscle-cells, and is known as the *medullary substance*, or vascular zone. This connective tissue penetrates here and there into the cortex, separates the epithelial elements of the latter from each other, and is in direct continuation with a stratum immediately beneath the germinal epithelium, called the tunica albuginea. This latter layer of connective tissue is generally distinct in the adult ovary, although

its structure and thickness vary to a considerable extent. In young ovaries it is irregular, but shows in its highest development three layers distinguishable from each other by the different direction of the fibers. In the medullary substance the connective-tissue fibers are long, in the cortex short, and in the zone containing the follicles (see below) are mingled with numerous connective-tissue cells. Nonstriated muscle-fibers occur exclusively in the medulla. Here they are gathered in bundles which accompany the blood-vessels, and may even form sheaths around the latter. They are especially prominent in mammalia.

The *germinal epithelium* is distinguished from that of the remaining peritoneum by the greater height of its cells, which are

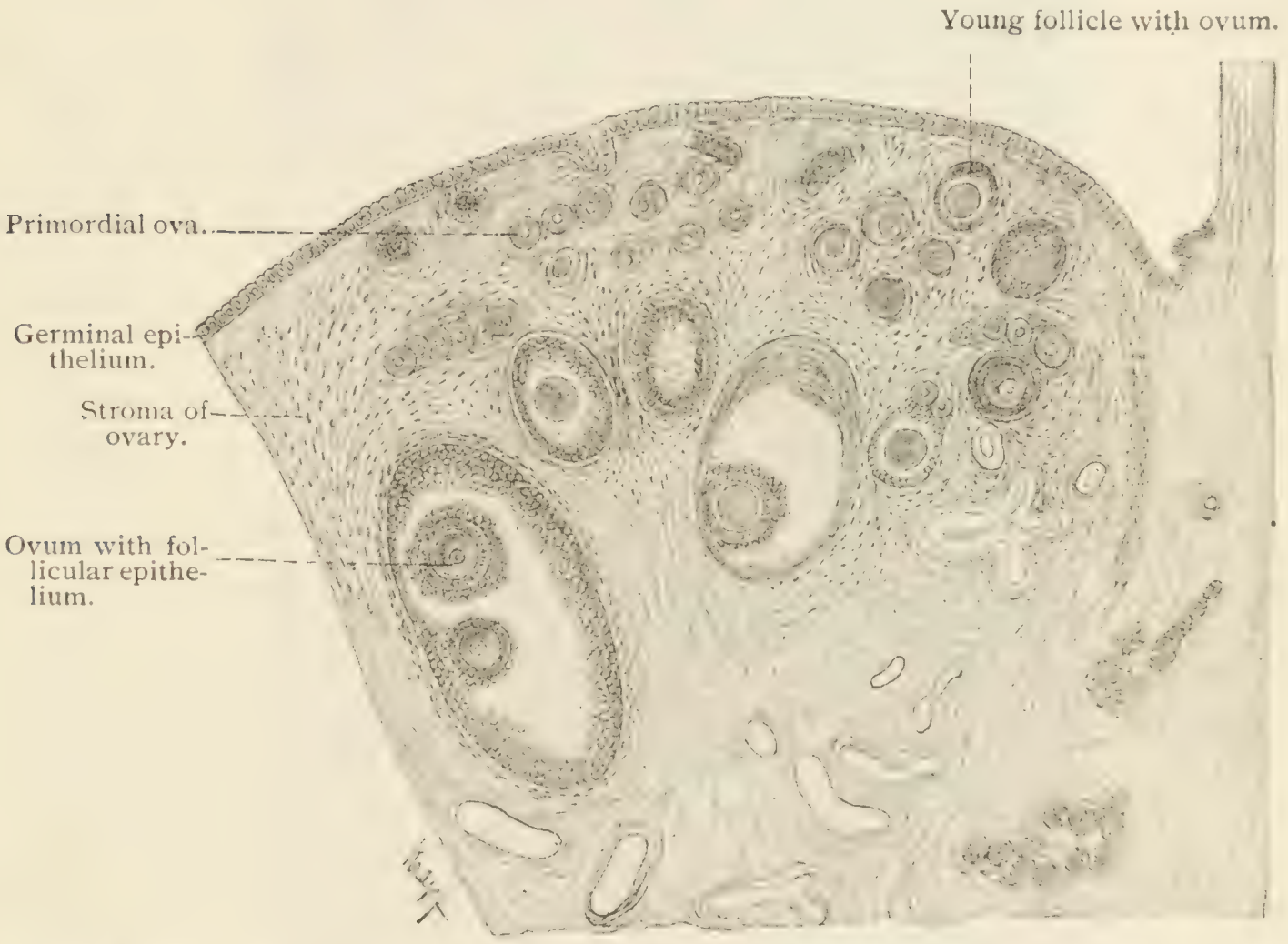

Fig. 275.—Section from ovary of adult dog. At the right the stellate figure represents a collapsed follicle with its contents. Below and at the right are seen the tubules of the parovarium (copied from Waldeyer).

cubic or even cylindric in shape. At an early period in the development of the ovaries this epithelium pushes into the underlying embryonic connective tissue in solid projections, to form the *primary egg tubes of Pflüger*, the cells of which very soon begin to show differentiation. Some retain their original characteristics and shape, while others increase in size, become rounded, and develop into the young ova. Those retaining their indifferent type become the follicular cells surrounding the egg. This differentiation into ova and follicular elements may even occur in the germinal epithelium itself, in which case the larger round cells are known as the *primitive* or *primordial ova*. In the further development of the ovarian cortex

the primitive egg tubes are penetrated throughout by connective tissue, so that each egg tube is separated into a number of irregular divisions. In this way a number of distinct epithelial nests are formed, which lose their continuity with the germinal epithelium and finally lie imbedded in the connective tissue. According to the shape and other characteristics of these epithelial nests, we may distinguish several different groups: (1) The primitive egg tubes

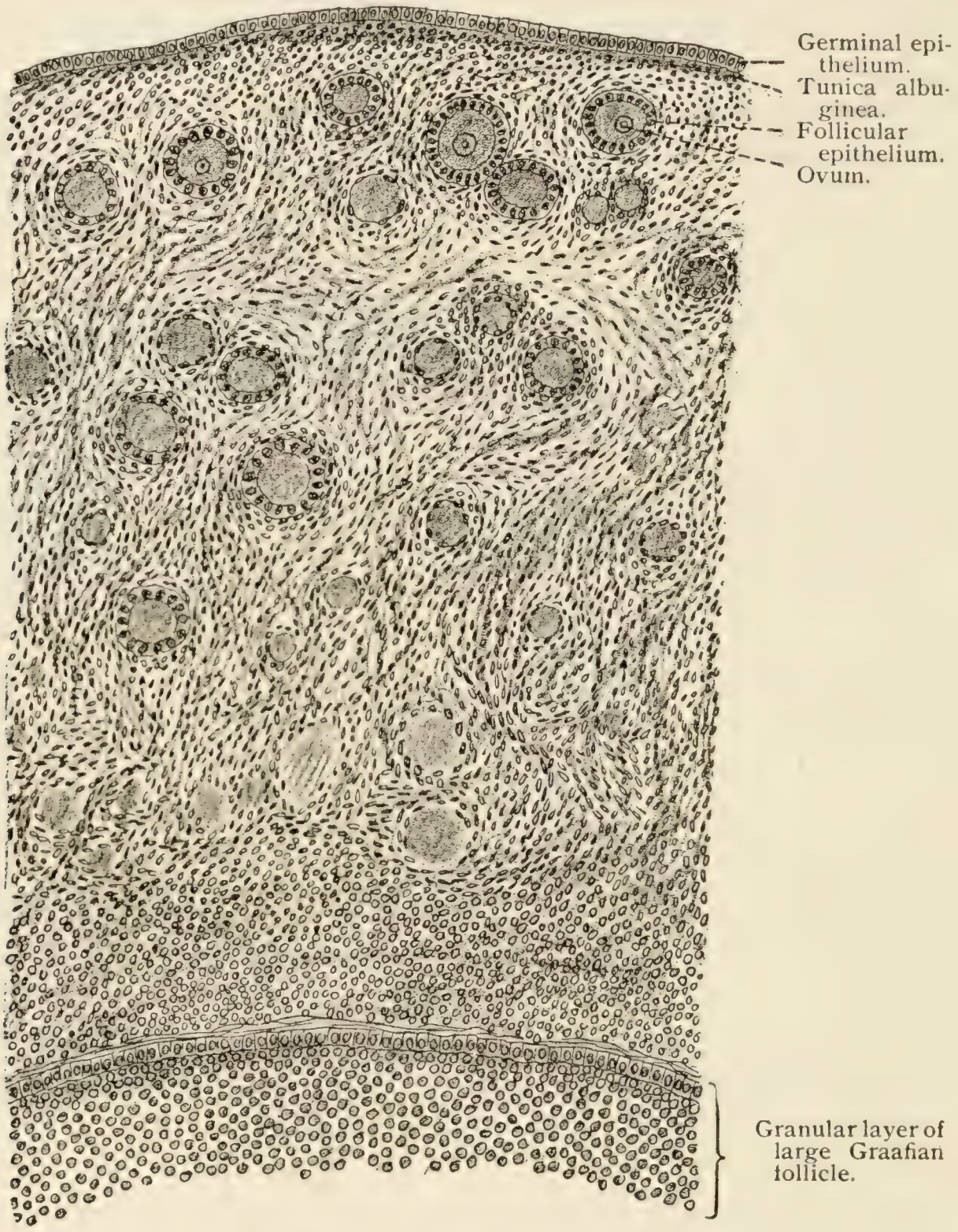

Fig. 276.—From ovary of young girl; × 190.

of Pflüger; (2) the typical primitive follicles—*i. e.*, those which contain only a single egg-cell (present in the twenty-eighth week of fetal life); (3) the atypic follicles—*i. e.*, those containing from two to three egg-cells; (4) the so-called nests of follicles, in which a large number of follicles possess only a single connective-tissue envelope; (5) follicles of the last-named type which may assume the form of an elongated tube, and which are then known as the con-

stricted tubes of Pflüger. The fourth, fifth, and possibly the third types are further divided by connective-tissue septa, until they finally form distinct and typical follicles (Schottländer, 91, 93).

In the adult ovary true egg tubes are no longer developed. Isolated invaginations of the germinal epithelium sometimes occur, but apparently lead merely to the formation of epithelial cysts (Schottländer). The theories as to when the formation of new epithelial nests or follicles ceases are, however, very conflicting, some authors believing that cessation takes place at birth, others that it continues into childhood and even into middle age.

The typical primitive follicle consists of a relatively large egg-cell surrounded by a single layer of smaller cubical or cylindric follicular cells. The growth of the follicle takes place by means of mitotic division in the follicular cells and increase in size of the ovum. The egg-cell is soon surrounded by several layers of cells, and gradually assumes an eccentric position in the cell complex. At a certain distance from the ovum and nearly in the center of the follicle one or more cavities form in the follicular epithelium. These become confluent, and the resulting space is filled by a fluid derived, on the one hand, from a process of secretion and, on the other hand, from the destruction of some of the follicular cells. The cavity is called the antrum of the follicle, and such a follicle has received the name of *Graafian follicle*. Its diameter varies from 0.5 to 6 mm. The follicle increases in size through cell-proliferation, the cavity increasing and gradually inclosing the egg together with the follicular cells immediately surrounding it, although the latter always remain connected with the wall of the vesicle at some point. The egg now lies imbedded in a cell-mass, the *discus proligerus*, which is composed of follicular epithelium, and projects into the follicular cavity. The follicular epithelium forming the wall of the cavity is known as the *stratum granulosum*, the cavity as the *antrum*, and the fluid which it contains as the *liquor folliculi*. Those follicular cells which immediately surround and rest upon the ovum are somewhat higher than the rest and constitute the egg epithelium, or *corona radiata*.

During the growth of the follicle the connective tissue surrounding it becomes differentiated into a special envelope, called the *theca folliculi*. In it two layers may be distinguished—the outer, the tunica externa, consisting of fibrous connective tissue, is continuous with the inner, or tunica interna, rich in blood-vessels and cellular elements. The follicle gradually extends to the surface of the ovary, at which point it finally bursts (see below), allowing the ovum to escape into the body cavity and thus into the oviduct.

During the growth and development of the ovarian follicles the ova undergo certain changes of size and structure which may receive further consideration. These have been described for the human ovary by Nagel (96), whose account will here be followed. The

Fig. 277.

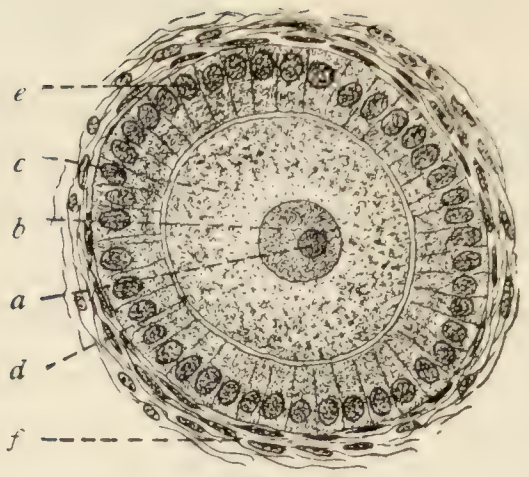

Fig. 278.

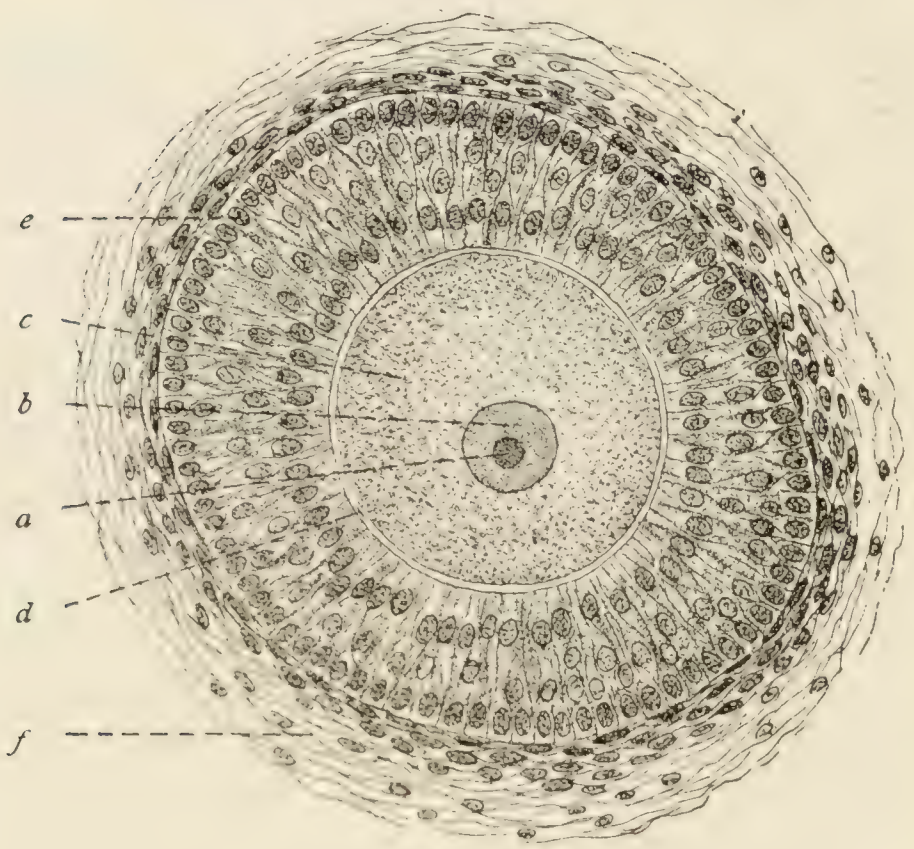

Fig. 279.

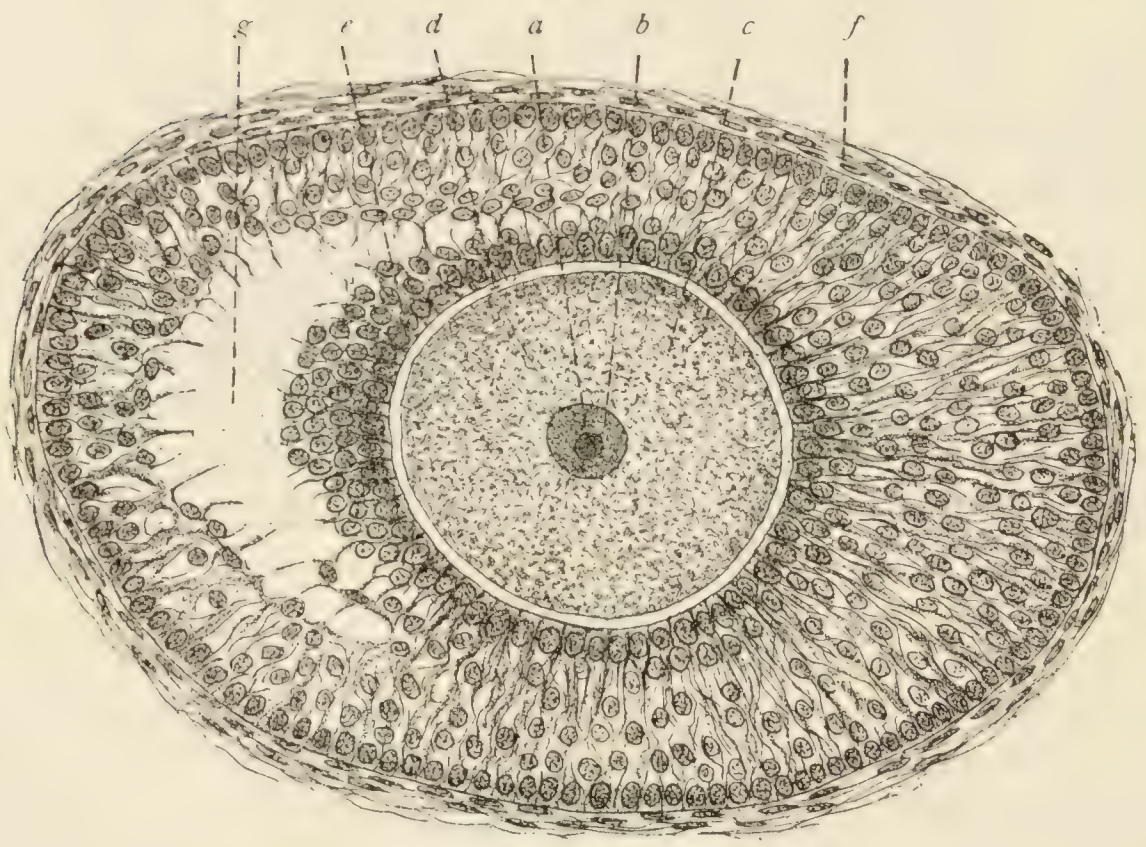

Fig. 280.

Figs. 277, 278, 279, and 280.—From sections of cat's ovary, showing ova and follicles in different stages of development ; × 225 : *a*, *a*, *a*, *a*, Germinal spots ; *b*, *b*, *b*, *b*, germinal vesicles ; *c*, *c*, *c*, *c*, ova ; *d*, *d*, *d*, zonæ pellucidæ ; *e*, *e*, *e*, *e*, corona radiata ; *f*, *f*, *f*, *f*, thecæ folliculorum ; *g*, beginning of formation of the cavity of the follicle.

ova of the primitive or primordial follicles attain a size (in fresh tissue teased in normal salt solution) varying from 48 μ to 69 μ. They possess a nucleus varying in size from 20 μ to 32 μ, presenting a doubly contoured nuclear membrane, and containing a distinct chromatin network with a nucleolus and several accessory nucleoli. The protoplasm shows a distinct spongioplastic network containing a clear hyaloplasm. The primitive ova, until they undergo further development, retain this size and structure, irrespective of the age of the individual. They are numerous in embryonic life and early childhood, always found during the ovulation period, but not

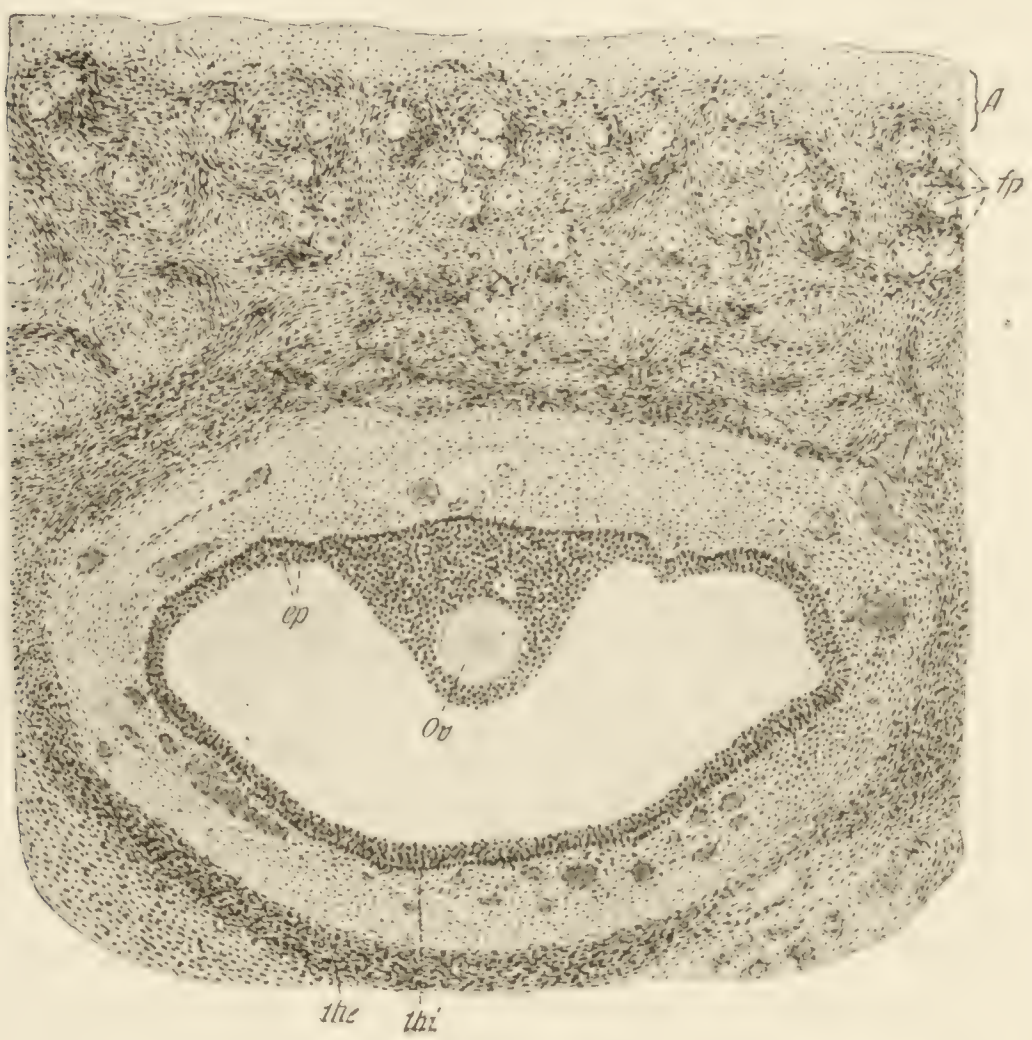

Fig. 281.—Transverse section through the cortex of a human ovary ; × 50 : *A*, Tunica albuginea ; *ep*, follicular epithelium, zona granulosa ; *fp*, primordial follicles ; *ov*, ovum in the discus proligerus ; *the*, theca externa folliculi ; *thi*, theca interna folliculi with blood-vessels (Sobotta, "Atlas and Epitome of Human Histology").

observed in the ovaries of the aged. Changes in the size and structure of the ova accompany the proliferation of the follicular cells in the growing follicles. As soon as the follicular cells of a primitive follicle proliferate, as above described, the ovum of the follicle increases in size until it has attained the size of a fully developed ovum. The zona pellucida now makes its appearance, and after this has reached a certain thickness, yolk granules (deutoplastic granules) develop in the protoplasm of the ovum. In a fully developed Graafian follicle the ovum presents an outer clearer protoplasmic zone and an inner fine granular zone containing yolk

granules; in the former lies the germinal vessel. Between the protoplasm of the ovum and the zona pellucida is found a narrow space known as the perivitelline space. The germinal vesicle (nucleus), which is usually of spheric shape, possesses a doubly contoured membrane and a large germinal spot (nucleolus), which shows ameboid movements.

The origin of the zona pellucida has not as yet been fully determined. It probably represents a product of the egg epithelium, and may be regarded in general as a cuticular formation of these cells. At all events it contains numerous small canals or pores into which the processes of the cells composing the corona radiata extend. These processes are to be regarded as intercellular bridges (Retzius, 90); and, according to Palladino, they occur not only between the ovum and the corona radiata, but also between the follicular cells themselves. In the ripe human ovum the pores are apparently absent (Nagel), and it is very probable that they have to do with the passage of nourishment to the growing egg. Retzius believes that the zona pellucida is derived from the processes of the cells composing the corona radiata, which at first interlace and form a network around the ovum. Later, the matrix of the membrane is deposited in the meshes of the network, very probably by the egg itself.

Further developmental changes are, however, necessary before a fully developed ovum (ripe ovum) may be fertilized. These are grouped under the head of maturation of the ovum. They have in part been described in a former section (p. 71), but may receive further consideration at this time. During maturation the chromosomes are reduced in number, so that the matured ovum presents only half the number found in a somatic cell of the same animal. The manner in which this reduction takes place has been described for many invertebrates and vertebrates, and in all ova studied with reference to this point essentially the same phenomena have been observed. In this account we shall follow the process as it occurs in the Copepoda (Rückert, 94).

During the period of growth the cells composing the last generation of oogonia (primitive ova) increase in size, and are then known as "oocytes" (the ripe ova). These then undergo mitotic division, and in each a spirem is formed which divides into 12 chromosomes, and not into 24 as in the case of the somatic cells. These 12 chromosomes split longitudinally, so that the germinal vesicle is seen to contain 12 pairs of chromosomes, or daughter loops. By this process the oogonia have become egg mother cells (O. Hertwig, 90) or oocytes of the first order. The loops now begin to shorten and each soon divides crosswise into two equal rods, thus giving rise to 12 groups of 4 chromosomes, or 12 tetrads. The mother cell now divides into 2 unequal parts, the process consisting in a distribution of the rods composing the tetrads in such a

way that the pairs of rods derived from one set of daughter loops pass to the one daughter cell, and those derived from the other set to the second daughter cell. In this manner are formed the large egg daughter cells (O. Hertwig) or oocytes of the second order, and a smaller cell, the first polar body. From this it is seen that the daughter cell still retains 12 pairs of rods. A second unequal division immediately follows without a period of rest, but in this case the com-



Fig. 282.— Schematic representation of the behavior of the chromatin during the maturation of the ovum (from Rückert, 94). Instead of 12 chromosomes we have drawn, for the sake of simplicity, only four: *a*, *a*, *a*, First, and (*b*) second polar body.

ponent parts of the pairs of rods are so divided that each separate rod moves away from its fellow, although they both originated from the same daughter loop. In this manner a cell of the third generation is formed, the oocyte of the third order, or *mature* ovum, as well as a second polar body. The second division in the period of maturation is peculiar in that here daughter chromosomes are

formed, not by a longitudinal splitting of the chromosomes, but by a transverse division.

In the process of development of the ova, three periods are therefore distinguishable. The first, or period of proliferation, represents a stage of repeated mitotic division in the oogonia, during which the latter become gradually reduced in size. In the second, or period of growth, the oogonia increase in size and are then ready for the third, or period of maturation. In the latter, by means of a modified double mitotic division, uninterrupted by any resting stage, the matured ovum and the polar bodies are formed. These several periods are represented in figure 283.

The manner in which the fully developed Graafian follicle

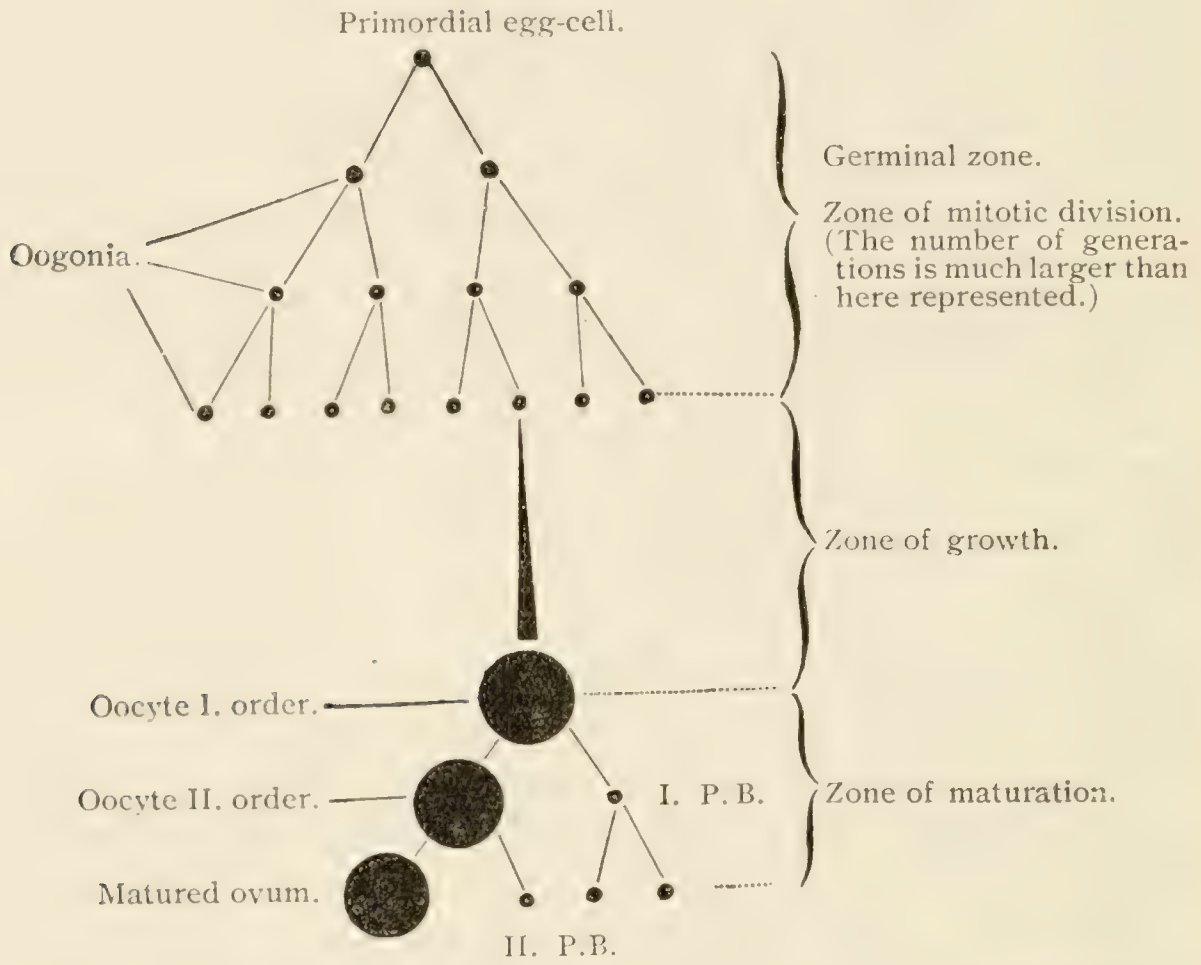

Fig. 283.—Scheme of the development and maturation of an ascaris ovum (after Boveri): P. B., Polar bodies. (From "Ergebn. d. Anat. u. Entw.," Bd. I.)

bursts and its ovum is freed is still a subject of controversy; the following may be said regarding it: By a softening of the cells forming the pedicle of the discus proligerus, the latter, together with the ovum, are separated from the remaining granulosa, and lie free in the liquor folliculi. At the point where the follicle comes in contact with the tunica albuginea of the ovary, the latter, with the theca folliculi, becomes thin, and in this region, known as the stigma, the blood-vessels are obliterated and the entire tissue gradually atrophies; thus a point of least resistance is formed which gives way at the slightest increase in pressure within the follicle, or in its neighborhood.

The part of the Graafian follicle which remains after the ovum has been released forms a structure known as the *corpus luteum*, a structure which passes through certain developmental stages and then undergoes degeneration. The regressive metamorphosis is much slower in a corpus luteum whose ovum has been fertilized and is in process of further development than in those whose ova have not been impregnated; the former is known as the *corpus luteum verum*, the latter as the *corpora lutea spuria*. There is as yet difference of opinion as to the mode of development of the corpora lutea, certain observers maintaining that the cells of the zona granulosa contribute largely to the development of these structures, while others trace their origin to the cells of the theca interna. In this account we shall follow Sobotta, whose careful observations on the development of the corpora lutea of the mouse and rabbit support strongly the former view. According to this observer, the walls of the Graafian follicle collapse after its rupture. The cells of the follicular epithelium, which remains within the collapsed follicle, hypertrophy, the cells attaining many times their original size. As the epithelial cells enlarge, a yellowish pigment known as *lutein* makes its appearance. The cells are now designated as lutein cells. At the same time the vascular connective tissue of the inner thecal layer penetrates between the hypertrophied epithelial cells in the shape of processes accompanied by leucocytes.

The structure which thus develops is known as the corpus luteum. On the rupture of the follicle hemorrhages often take place on account of the laceration of the blood-vessels. The remains of such hemorrhages are found in the form of hematoidin crystals.

After a variable time the corpora lutea degenerate; in this regressive metamorphosis the epithelial cells (lutein cells) undergo fatty degeneration, and the connective tissue trabeculæ become atrophied. Each corpus luteum is thus changed into a *corpus albicans*, which in turn is absorbed, and in its place there remains only a connective tissue containing very few fibers.

Not all of the eggs and follicles reach maturity; very many are destroyed by a regressive process known as *atresia of the follicles*. This process may begin at any stage, even affecting the primitive ova while still imbedded in the germinal epithelium—first attacking the egg itself and later the surrounding follicular epithelium, although in both the degenerative process is identical. The germinal vesicle and the nuclei of the follicular cells usually undergo a chromatolytic degeneration, although they sometimes disappear without apparent chromatolysis (direct atrophy), while the cell-bodies are generally subjected to a fatty degeneration or may even undergo what is known among pathologists as an albuminous degeneration—*i. e.*, one characterized by granulation and showing no fat reaction but numerous reactions such as are observed where albumin is present. These two forms of metamor-

phosis result in a liquefaction of the cell-body, and finally lead to a hyaline swelling, which renders the substance of the cell homogeneous. The zona pellucida softens, increases in volume, becomes wrinkled, and after some time is absorbed. A further stage in the regressive process consists in the formation of scar tissue, as in the case of the corpus luteum. Here leucocytes accompany the proliferation from the tunica interna of the theca folliculi, and assist in absorbing the products of degeneration, the result being a connective-tissue scar (*vid.* G. Ruge, and Schottländer, 91, 93).

The **blood-vessels** of the ovary enter at the hilum and branch in the medullary substance of the ovary. From these medullary vessels branches are given off which penetrate the follicular zone, giving off branches to the follicles and terminating in a capillary network in the tunica albuginea (Clark, 1900). The relations of the branches to the follicles are such that in the outer layer of the theca folliculi the vessels form a network with wide meshes while the inner layer contains a fine capillary network. The veins are of large caliber and form a plexus at the hilum of the ovary.

The lymphatics of the ovary are numerous. They begin in clefts in the follicular zone, which unite to form vessels lined by endothelial cells in the medulla. They leave the ovary at the hilum.

The nerves accompany and surround the blood-vessels, while very few nerve-fibers penetrate into the theca folliculi; those doing so form a network around the follicle and end often in small nodules without penetrating beyond the theca itself. Ganglion cells of the sympathetic type also occur in the medulla of the ovary near the hilum (Retzius, 93; Riese, Gawronsky).

3. THE FALLOPIAN TUBES, UTERUS, AND VAGINA.

The **Fallopian tubes** or ova ducts consist of a mucous membrane, muscular coat, and peritoneal covering.

The mucous membrane presents a large number of longitudinal folds which present numerous secondary folds which frequently communicate with one another. Very early in the development four of these folds are particularly noticeable in the isthmus; these may also be recognized at times in the adult. These are the chief folds, in contradistinction to the rest, which are known as the accessory folds (Frommel). The accessory folds are well developed in the isthmus, and are here so closely arranged that no lumen can be seen with the naked eye. The epithelium lining the tubes is composed of a single layer of ciliated columnar cells which entirely cover the folds as well as the tissue between them. Glands do not occur in the oviducts, unless the crypts between the folds may be considered as such. The mucosa beneath the epithelium contains relatively few connective-tissue

fibers, but numerous cellular elements. In the isthmus it is compact, but in the ampulla and infundibulum its structure is looser. The mucosa contains a few nonstriated muscle-fibers, which have a longitudinal direction and extend into the chief folds, but not into the accessory folds.

External to the mucosa is found the muscular coat, consisting of an inner circular and an outer and thinner longitudinal layer consisting of bundles of nonstriated muscular tissue separated by connective tissue and blood-vessels. The longitudinal layer is imperfectly developed in the ampulla and may be entirely absent in the infundibulum. The peritoneal layer consists of a loose connective tissue covered by mesothelium.

Fig. 284.—Section of oviduct of young woman. To the left and above are two enlarged ciliated epithelial cells from the same tube; × 170.

The ova ducts have a rich blood-supply. The terminal branches of the arteries pass into the primary and secondary folds of the mucosa, where they form capillary plexuses under the epithelium. The blood is returned by means of a well-developed venous plexus. The lymphatic vessels have their origins in the folds of the mucosa. Nerve-fibers have been traced to the musculature and to the lining epithelial cells.

The **uterus** is composed of a mucous, a muscular, and a peritoneal coat.

The mucosa of the body of the uterus and cervix is lined by a single layer of columnar ciliated epithelial cells; these are some-

what higher in the cervix than in the corpus. Barfurth (96) has found intercellular bridges between the cells of the uterine epithelium in the guinea-pig and rabbit. In the cervix of the virgin the ciliated columnar epithelium extends as far as the external os, at which point this usually changes to a stratified squamous epithelium. In multiparæ the squamous epithelium extends into the cervical canal and may be found, with occasional exceptions (islands of ciliated epithelium), throughout its entire lower third. This arrangement is subject to considerable variation, so that even in children the lower portion of the cervical canal may sometimes be lined by stratified epithelium. Recent investigations have established the fact that in both the uterus and oviducts the general direction of the wave-like ciliary motion is toward the vagina (Hofmeier). In the body of the uterus the mucosa is composed of a reticular connective tissue consisting of relatively few connective-tissue fibers and branched connective-tissue cells arranged in the form of a network, in the meshes of which are found lymphocytes and leucocytes. Under low magnification the mucosa presents more the appearance of adenoid tissue than of areolar connective tissue. The mucosa of the cervix is somewhat denser, containing more fibrous tissue. In the cervical canal the mucosa of the anterior and posterior walls is elevated to form numerous folds, extending laterally from larger median folds. These folds are known as the *plicæ palmatæ*.

The mucosa of the body of the uterus and of the cervix contains numerous glands, the uterine and cervical glands. The uterine glands are branched tubular in type, and extend through the mucosa and certain ones may even extend for a short distance into the muscular layer. They are lined by ciliated columnar epithelium, resting on a basement membrane. The cervical glands are larger and more branched than those of the body of the uterus, and belong to the type of tubulo-alveolar glands; they have a mucous secretion. The glands and crypts extend as far as the external os. In the mucous membrane of the cervical region we find peculiar closed sacs of varying size lined by simple cylindric epithelium, the so-called *ovula Nabothi*, which probably represent cystic formations (*vid.* A. Martin).

Three layers of muscular tissue are to be seen both in the corpus and cervix uteri—an inner longitudinal, a middle nearly circular, in which the principal blood-vessels are found, and an outer longitudinal. The inner and outer layers are known respectively from their position as the stratum mucosum and stratum serosum, the middle and more vascular as the stratum vasculosum. As compared with the middle, the inner and outer muscle layers are poorly developed. The complicated conditions found in the uterine musculature can be better understood if some attention be paid to its origin. The circular layer should be regarded as the original musculature of the Müllerian ducts. The outer longitudinal layer develops later, and is derived from the musculature of the broad

ligament. Between these two are the large vessels accompanied by a certain amount of muscular tissue—a condition which persists throughout life in the carnivora. In man the blood-vessels penetrate into the circular musculature and only appear later in the inner muscular layer. A true muscularis mucosæ is not present in the human uterus (Sobotta, 91).

The serous or peritoneal layer consists of a layer of mesothelial cells and submesothelial connective tissue.

The uterus derives its blood supply from the uterine and ovarian arteries, which enter from the broad ligament through its lateral portion. These vessels pass to the stratum vasculosum of the muscular layer, where they branch repeatedly, some of the branches

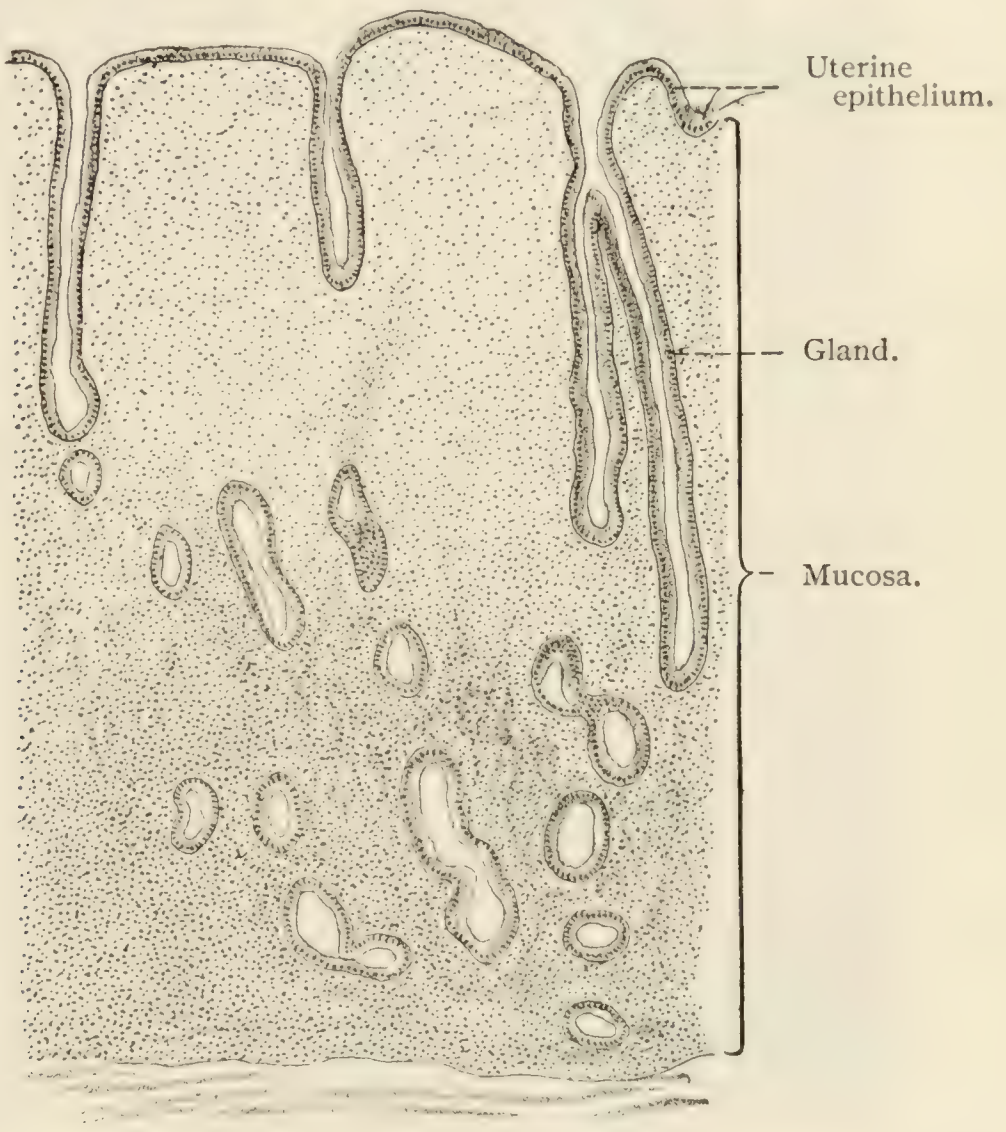

Fig. 285.—From uterus of young woman; × 34. (From a preparation by Dr. J. Amann.)

entering the mucosa, where they form capillary networks surrounding the glands and a dense capillary network situated under the uterine epithelium. The veins form a venous plexus in the deeper portion of the mucosa, especially well developed in the cervix and os uteri. From this plexus the blood passes to a second well-developed venous plexus situated in the stratum vasculosum of the muscular layer, whence the blood passes to the plexus of uterine and ovarian veins.

The lymphatics begin in numerous clefts in the uterine mucosa;

from here the lymph passes by way of lymph-vessels to the muscular coat, between the bundles of which are found numerous lymph-vessels especially in the middle or vascular layer. These lymph-vessels terminate in larger vessels found in the subserous connective tissue.

The uterus receives numerous medullated and nonmedullated nerves. The latter terminate in the muscular layers. Medullated fibers have been traced into the mucosa, where they form plexuses under the epithelium, from which branches have been traced between the epithelial cells and between the gland cells. In the course of the nerves ganglion cells of the sympathetic type have been observed.

Fig. 286.—From section of human vagina.

In the **vagina** we distinguish also three coats—the mucous membrane, the muscular layer, and the outer fibrous covering.

The epithelium of the mucous membrane is of the stratified squamous type, and possesses, as usual, a basal layer of cylindric cells. The mucosa of the vagina consists of numerous connective-tissue fibers mingled with a number of exceptionally coarse elastic fibers. Papillæ containing blood-vessels are present everywhere except in the depressions between the columnæ rugarum. It is generally stated that the vagina has no glands, but according to the observations of von Preuschen and C. Ruge, a few isolated glands occur in

the vagina. They are relatively simple in structure, form irregular tubes, and are lined by ciliated columnar epithelium. The excretory ducts are lined by stratified squamous epithelium. Diffuse adenoid tissue is met with in the mucosa, which sometimes assumes the form of lymphatic nodules.

The muscular coat, which in the lower region is quite prominent, may be separated indistinctly into an outer longitudinal and an inner circular layer ; the latter is, as a rule, poorly developed, and may be entirely absent. The muscular coat is especially well developed anteriorly in the neighborhood of the bladder.

Fig. 287.—From section of human labia minora.

The outer fibrous layer consists of dense connective tissue loosely connected with the adjacent structures.

At its lower end the vagina is partially closed by the hymen which must be regarded as a rudiment of the membrane which in the embryo separates the lower segment of the united Müllerian ducts from the ectoderm of the sinus urogenitalis. Accordingly, the epithelium on the inner surface of the hymen partakes of the character of the vaginal epithelium ; that on the outer surface resembling the skin in structure (G. Klein).

The epithelium of the *vestibulum* gradually assumes the characteristics of the epidermis; its outer cells lose their nuclei and sebaceous glands occur here and there in the neighborhood of the urethral orifice and on the labia minora. Hair begins to appear on the outer surface of the labia majora.

The clitoris is covered by a thin epithelial layer, resembling the epidermis. This rests on a fibrous-tissue mucosa having numerous papillæ, some of which contain capillaries, others special nerve-endings. In the clitoris of the adult no glands are found. The greater portion of the clitoris consists of cavernous tissue, homologous to the corpora cavernosa of the penis; the corpus spongiosum is not present in the clitoris.

The glands of Bartholin, the homologues of the glands of Cowper in the male, are mucous glands situated in the lateral walls of the vestibule of the vagina. The terminal portions of their ducts are lined by stratified squamous epithelium.

Free sensory nerve-endings, with or without terminal enlargements, have been demonstrated in the epithelium of the vagina (Gawronski). The sensory nerve-fibers form plexuses in the mucosa, and lose their medullary sheaths as they approach the epithelium. Sympathetic ganglia are met with along the course of these nerves, and nonmedullated nerves terminate in the involuntary muscular tissue of the vaginal wall.

In the connective-tissue papillæ and in the deeper portions of the mucosa of the glans clitoridis are found, besides the ordinary type of tactile corpuscles and the spherical end-bulbs of Krause, the so-called genital corpuscles (see p. 171). Numerous Pacinian corpuscles have been observed in close proximity to the nerve-fibers of the clitoris and the labia minora.

In varying regions of the medullary substance of the ovary, but more usually in the neighborhood of the hilum, there occur irregular epithelial cords or tubules provided with columnar epithelium, ciliated or nonciliated, which constitute the *paroophoron.* These are the remains of the mesonephros, and are continuations of that rudimentary organ—the *epoophoron*—of similar structure which lies within the broad ligament. The separate tubules of the epoophoron communicate with the *duct of Gärtner* (Wolffian duct), which in the human being is short, ends blindly, and never, as in certain animals, opens into the lower portion of the vagina. These derivatives of the primitive kidney consist of blindly ending tubules of varying length lined by a ciliated epithelium, the cells of which are often found in process of degeneration.

The *hydatids of Morgagni* are duplications of the peritoneum.

D. THE MALE GENITAL ORGANS.

1. THE SPERMATOZOON.

The semen, or sperma, is a fluid that, as a whole, consists of the secretion of several sets of glands in which the sexual cells, the spermatosomes, or spermatozoa, which are formed in the testes, are suspended.

We shall first consider the structure of the typical adult spermatosome, taking up consecutively its component parts. Three principal parts may be distinguished—the *head*, the *middle piece*, and the *tail* or *flagellum*. The round or oval body of the head terminates in a lanceolate extremity. The former consists of chromatin, and is most intimately associated with the phenomenon of fertilization. The middle piece, which is attached to the posterior end of the head, is composed of a protoplasmic envelop which surrounds a portion of the so-called *axial thread*. The latter is enlarged anteriorly just behind the head to form the *terminal nodule*, which fits into a depression in the head. From the middle piece on, the axial thread

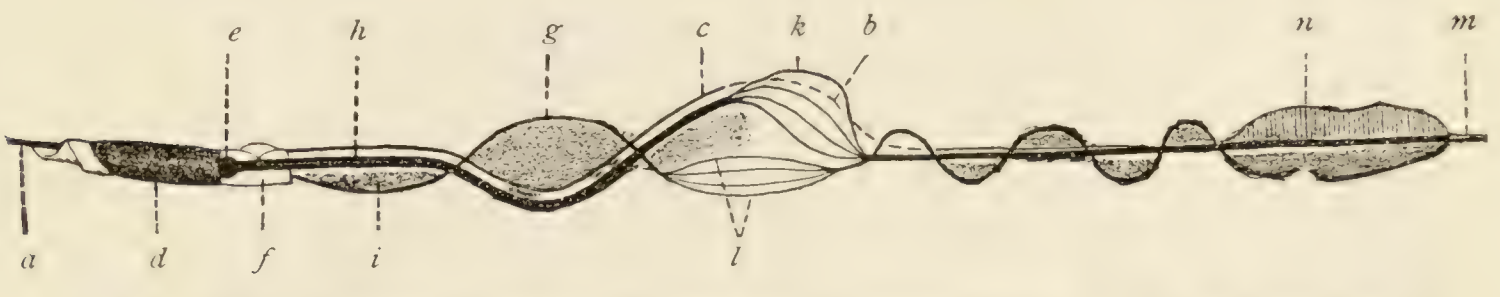

Fig. 288.—Diagram showing the general characteristics of the spermatozoa of various vertebrates: *a*, Lance; *b*, segments of the accessory thread; *c*, accessory thread; *d*, body of the head; *e*, terminal nodule; *f*, middle piece; *g*, marginal thread; *h*, axial thread; *i*, undulating membrane; *k*, fibrils of the axial thread; *l*, fibrils of the marginal thread; *m*, end piece of Retzius; *n*, rudder-membrane.

is continued into the tail of the spermatozoon, and is here surrounded by a transparent substance—the *sheath of the axial thread*. The envelop is lacking at the posterior extremity of the tail, where the axial thread extends for a short distance as a naked filament called the *end-piece of Retzius*. From the middle piece a still finer thread is given off, the *marginal thread*, which extends at a certain distance from the axial thread as far as the end-piece of Retzius. In its course it crosses and recrosses the axial thread at various points, and may even wind around it in a spiral manner. In all instances it is connected with the sheath of the axial thread by a delicate membrane—the *undulating membrane*. Another and still more delicate filament—the *accessory thread*—runs parallel with the axial thread along the surface of its sheath and terminates at a certain distance from the end-piece of Retzius. Near the extremity of the flagellum and immediately in front of the end-piece is another and shorter membrane,—the *rudder membrane*,—which is continuous with the undulating membrane. Maceration reveals a fibrillar

structure of both the axial and marginal threads (Ballowitz), while the accessory thread is separated into a number of short segments.



Fig. 289.—Human spermatozoa. The two at the left after Retzius (81); the one at the extreme left is seen in profile; the other in surface view; the one at the right is drawn as described by Jensen: *a*, Head; *b*, terminal nodule; *c*, middle piece; *d*, tail; *e*, end-piece of Retzius.

In mammalia, and especially in man, the spermatozoa seem to be more simply constructed. Here the head is pyriform, and somewhat flattened, with a slight ridge along the depression at either side of its anterior thinner portion (Fig. 289). In some mammalia (mouse), the head is provided with a so-called cap, which corresponds to the lance previously mentioned. The middle piece is relatively long and shows a distinct cross-striation, which may be attributed to its spiral structure. Here also the middle piece is traversed by the axial thread, which ends at the head in a terminal nodule, and may be separated as in other mammalia into a number of fibrils. Some years ago Gibbes described an undulating membrane in the human spermatozoon, an observation which was confirmed by W. Krause (81). The head of the human spermatosome is from 3 μ to 5 μ long, and from 2 μ to 3 μ in breadth; the middle piece is 6 μ long and 1 μ in breadth; the tail is from 40 μ to 60 μ long, and the end-piece 6 μ long.

The spermatozoa are actively motile, a phenomenon due to the flagella, which give them a spiral, boring motion. They are characterized by great longevity and are very resistant to the action of low temperatures (*vid.* Piersol, 83). In some species of bat the spermatozoa penetrate into the oviduct of the female in the fall, but do not contribute to impregnation until the spring, when the ova mature. (For the structure of the spermatosomes see Jensen, Ballowitz.)

2. THE TESTES.

The testis is inclosed within a dense fibrous capsule,—the *tunica albuginea*,—about one-sixteenth of an inch in thickness, and surrounded by a closed serous sac, derived from the peritoneum during the descent of the testes, and therefore lined by mesothelial cells. This serous sac—the *tunica vaginalis*—consists of a visceral layer attached to the tunica albuginea, and a parietal layer which blends with the scrotum. The cavity contains normally a small amount of serous fluid. On the inner surface of the tunica albuginea is found a thin layer of loose fibrous tissue containing blood-vessels —the *tunica vasculosa*. The tunica albuginea is thickened in its

posterior portion to form the *mediastinum testis*, or the *corpus Highmori*, which projects as a fibrous-tissue ridge for a variable distance into the substance of the testis. The gross structure of the testis is best seen in a sagittal longitudinal section. Even a low magnification will show that the testis is composed of lobules. These are produced by septa which extend into the substance of the organ and are derived from the investing tunics of the testis and diverge in a radiate manner from the mediastinum testis. The lobules are of pyramidal shape, with their bases directed toward the capsule and their apices toward the mediastinum. They consist principally of the seminiferous tubules, whose transverse, oblique, and longitudinal

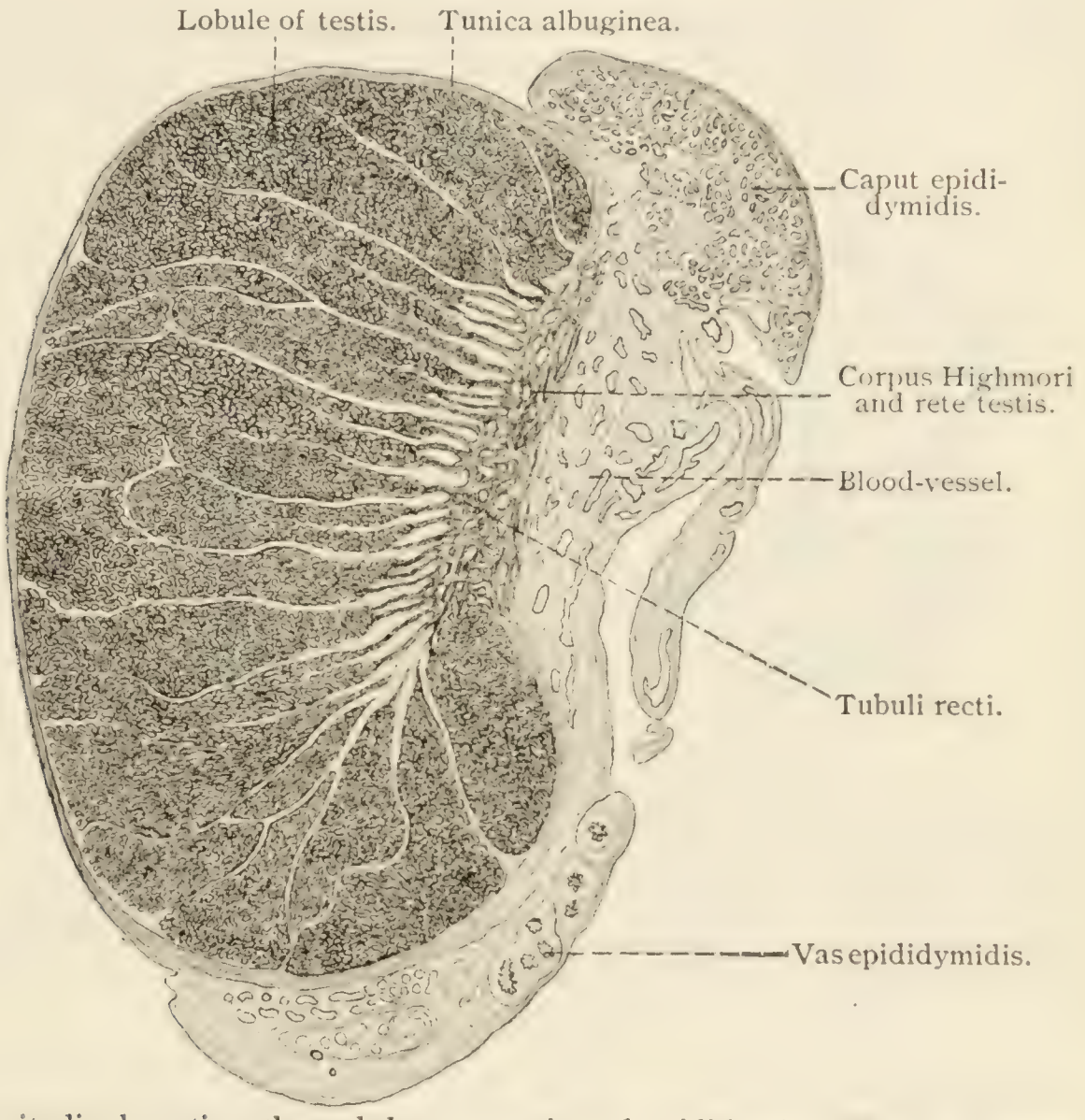

Fig. 290.—Longitudinal section through human testis and epididymis. The light areas between the lobules are the fibrous-tissue septa of the testis; × 2.

sections may be observed in sections of the testis. When isolated, these tubules are seen to begin in the testis as closed canals, which are closely coiled upon each other (convoluted tubules) and describe a tortuous course, until they finally reach the corpus Highmori. Immediately before they reach the latter, the convoluted tubules change into short, straight and narrow segments—the *straight tubules*, or *tubuli recti*. Within the corpus Highmori, all the straight tubules of the testis unite to form a tubular network—the *rete testis* (Haller).

From this network about fifteen tubules—the *vasa efferentia*—

arise. The latter, at first straight, soon begin to wind in such a manner that the various convolutions of each canal form an independent system, invested by a fibrous sheath of its own—*coni vasculosi Halleri*. These lobules constitute the elements of the globus major of the epididymis. In cross-section the vasa efferentia are seen to be stellate in shape. The vasa efferentia gradually unite to form one canal—the *vas epididymidis*. This is markedly convoluted and is situated in the body and tail of the epididymis itself.

The epithelium of the convoluted seminiferous tubules consists of sustentacular cells (cells or columns of Sertoli) and of spermatogenic elements. The former are high, cylindric structures (see below), the basilar surfaces of which are in contact. They do not form a continuous layer, but their basal processes are interwoven to form a superficial network surrounding the epithelium of the

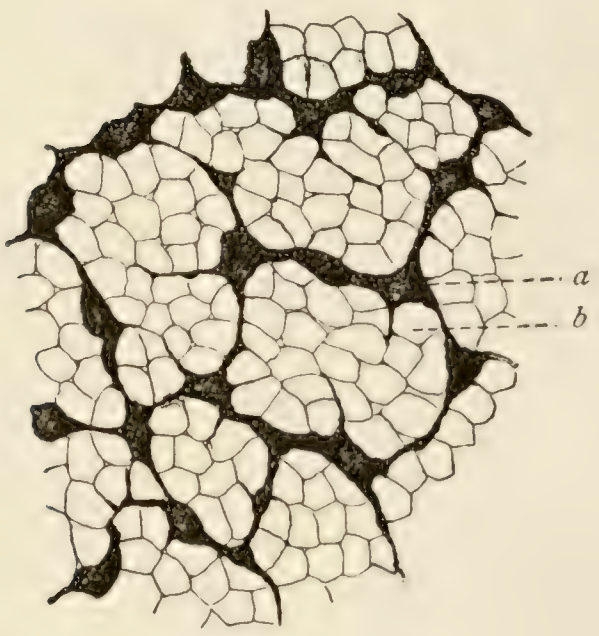

Fig. 291.

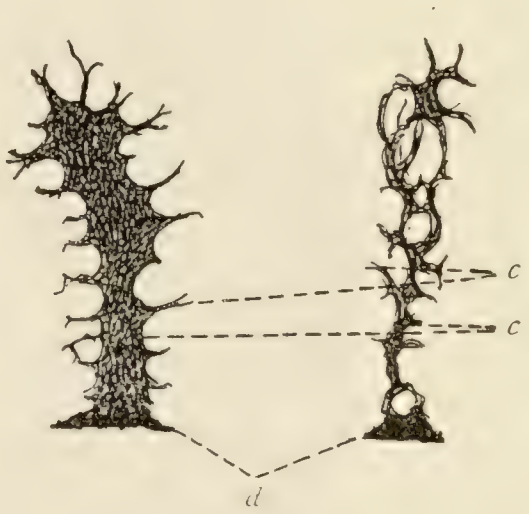

Fig. 292.

Sustentacular cells (cells of Sertoli) of the guinea-pig (chrome-silver method). Figure 291, surface view of the seminiferous tubules; figure 292, profile view; × 220: *a*, Basilar surface of a cylindric sustentacular cell; *b*, flattened sustentacular cell; *c*, *c*, depressions in the sustentacular cells due to pressure from the spermatogenic cells; *d*, basilar portion of sustentacular cells.

seminiferous tubules. (Fig. 292.) In the meshes of the reticulum are deposited numbers of plate-like cells, which lie in contact with the basement membrane and also represent sustentacular elements (*vid.* Merkel, 71).

Between the sustentacular cells are found from four to six rows of cells, possessing relatively large nuclei, rich in chromatin, and derived from cells of the deeper strata by mitotic cell division. The epithelium of the convoluted portion of the seminiferous tubules is, therefore, a stratified epithelium. The cells of this epithelium present various peculiarities according to their stage of development, and will be considered more fully in discussing spermatogenesis. Externally, the walls of the convoluted tubules are limited by a single layer or several layers of spindle-shaped, epithelioid cells. A basement membrane is present, but very thin, and in some cases

hardly capable of demonstration. The convoluted tubules are separated from each other by a small amount of connective tissue, in which, in addition to the vessels, nerves, etc., are found peculiar groups of large cells containing large nuclei, and known as interstitial cells. Nothing definite is known regarding the significance of these cells ; but they are probably remains of the Wolffian body. Reinke (96) found repeatedly crystalloids of problematic significance in the interstitial cells of the normal testis.

The stratified epithelium of the convoluted tubules changes in

Fig. 293.—From section of human testis, showing convoluted seminiferous tubules.

the tubuli recti to an epithelium consisting of a single layer of short columnar or cubical cells resting on a thin basement membrane.

The canals of the rete testis (Haller) are lined by nonciliated epithelium, which varies in type from flat to cubical. Communicating with the rete testis is a blind canal, the vas aberrans of the rete testis, lined with ciliated epithelium.

The vasa efferentia are lined partly by ciliated columnar and partly by nonciliated cubical epithelium. The two varieties form groups which alternate, giving rise to nonciliated depressions, which represent gland-like structures (Schaffer, 92), but do not

cause corresponding evaginations of the mucosa. The mucosa, which consists of fibrous connective tissue, contains flattened endothelioid cells, which resemble nonstriated muscle-cells. The latter are found only at the end of the vasa efferentia, just before reaching the vas epididymidis.

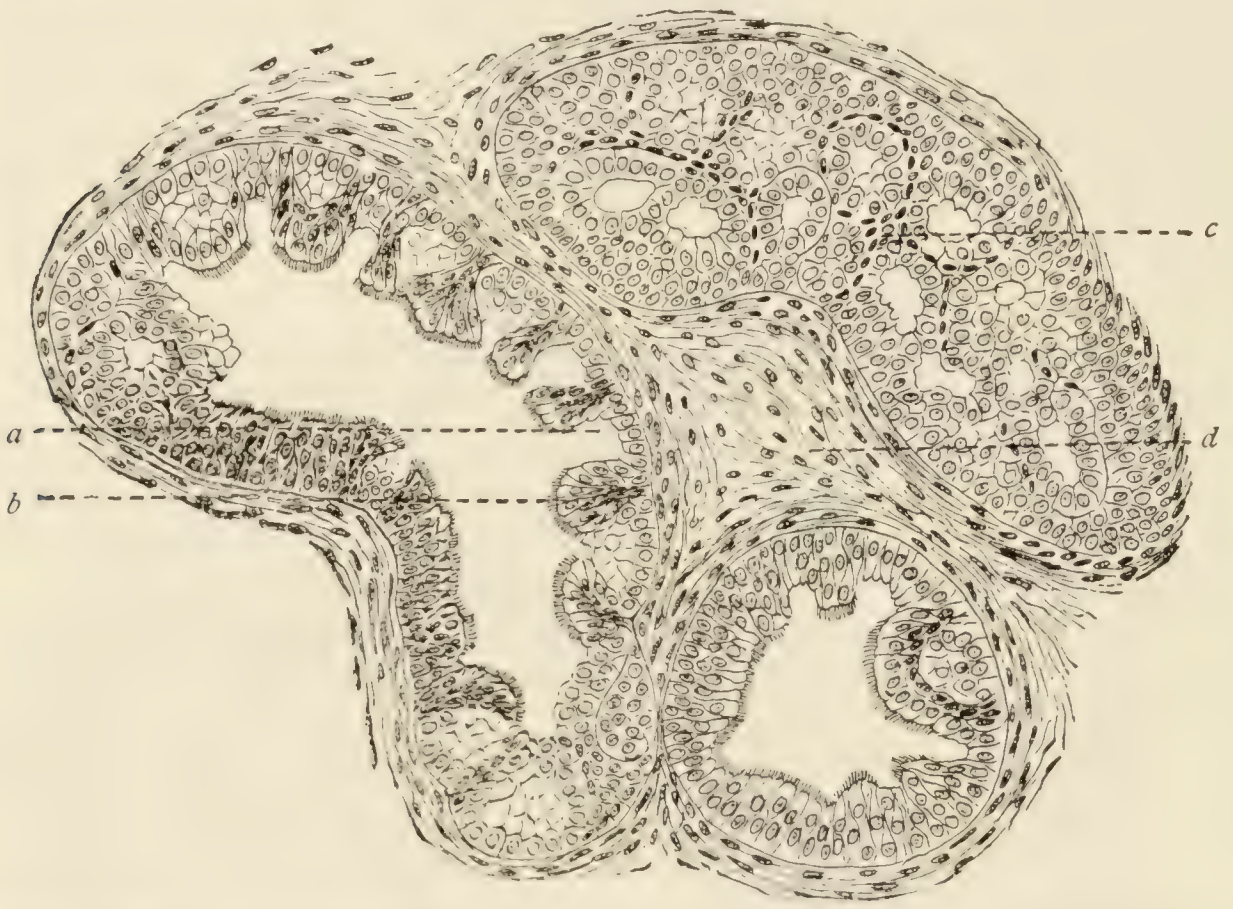

Fig. 294.—Section through human vasa efferentia: *a*, Glands; *b*, ciliated epithelium; *c*, glandular structure; *d*, connective tissue.

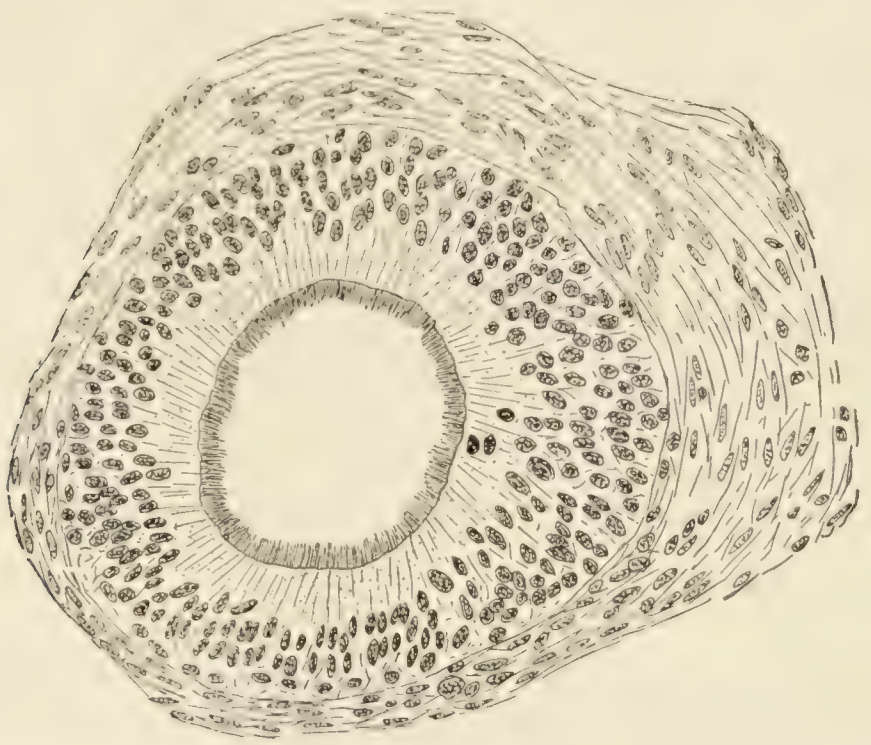

Fig. 295.—Cross-section of vas epididymidis of human testis.

The vas epididymidis is lined by stratified ciliated columnar epithelium, resting on a thin mucosa, outside of which there is found an inner circular and an outer, though thin and not continuous, longitudinal layer of nonstriated muscular tissue.

An aberrant canaliculus also communicates with the vas epididymidis, and is here known as the *vas aberrans Halleri.* Num-

bers of convoluted and blindly ending canaliculi are frequently found imbedded in the connective tissue around the epididymis. These constitute the *paradidymis*, or *organ of Giraldès*.

The blood-vessels of the testis spread out in the corpus Highmori and in the tunica vasculosa of the connective-tissue septa and of the tunica albuginea, their capillaries encircling the seminal tubules in well-marked networks.

The lymphatic vessels begin in clefts in the tunica albuginea and in the connective tissue between the convoluted tubules. They converge toward the corpus Highmori and pass thence to the spermatic cord.

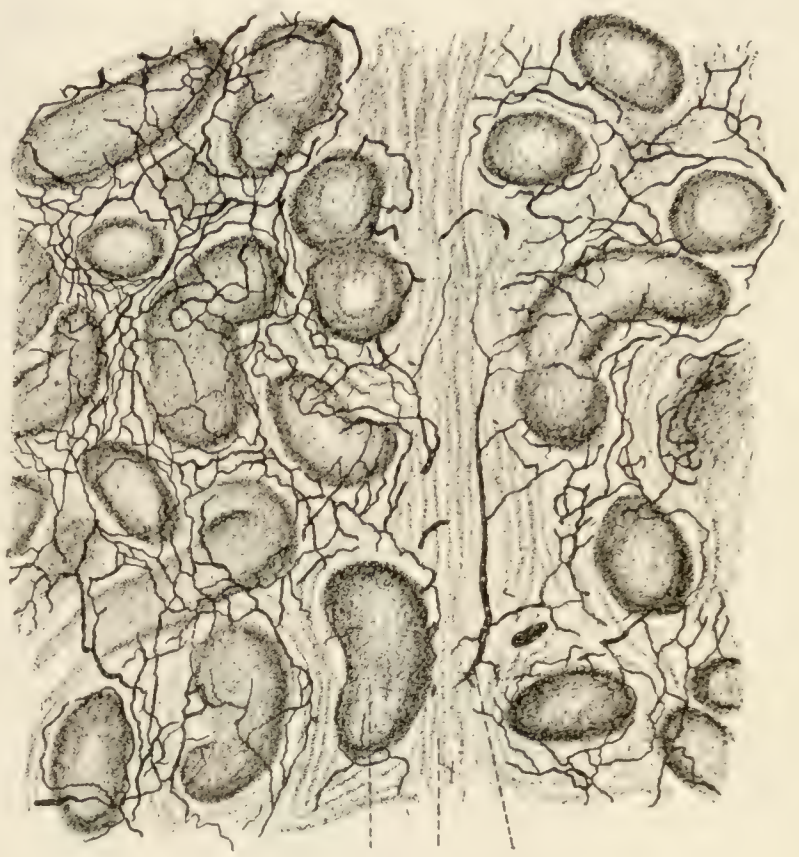

Fig. 296.—Section of dog's testis with injected blood-vessels (low power): *a*, Seminiferous tubule; *b*, connective-tissue septum; *c*, blood-vessel.

Retzius (93) and Timofeew (94) have described plexuses of nonmedullated, varicose nerve-fibers surrounding the blood-vessels of the testis. From such plexuses single fibers, or small bundles of such, could be traced to the seminiferous tubules, about which they also form plexuses. Such fibers have not been traced into the epithelium lining the tubules. In the epididymis Timofeew found numerous sympathetic ganglia, the cell-bodies of the sympathetic neurones of which were surrounded by pericellular plexuses. In the wall of the vas epididymidis and the vasa efferentia were observed numerous varicose nerve-fibers, arranged in the form of a plexus, many of which seemed to terminate on the nonstriated muscle cells found in these tubes. Some of the nerve-fibers were traced into the mucosa, but not into its epithelial lining.

3. THE EXCRETORY DUCTS.

The *vas deferens* possesses a relatively thick muscular wall, consisting of three layers, of which the middle is circular and the other two longitudinal. The subepithelial mucosa is abundantly supplied with elastic fibers and presents longitudinal folds. The lining epithelium is in part simple ciliated columnar and in part stratified ciliated columnar, with two rows of nuclei. The cilia are, however, often absent, beginning with the lower portion of the vas epidi-

dymidis. According to Steiner, the epithelium of the vas deferens varies. It may be provided with cilia in the lower segments, or it may even be similar to that found in the bladder and ureters.

The inner muscular layer is wanting in the ampulla of the vas deferens; here the epithelium is mostly simple columnar and pigmented. Besides the folds, there are also evaginations and tubules which sometimes form anastomoses—structures which may be regarded as glands.

The *seminal vesicles* are also lined, at least when in a distended condition, by simple, nonciliated columnar epithelium containing yellow pigment. In a collapsed condition the epithelium is pseudostratified, with two or even three layers of nuclei. The arrangement of the epithelial cells in a single layer would therefore seem to be the result of distention. The mucous membrane shows

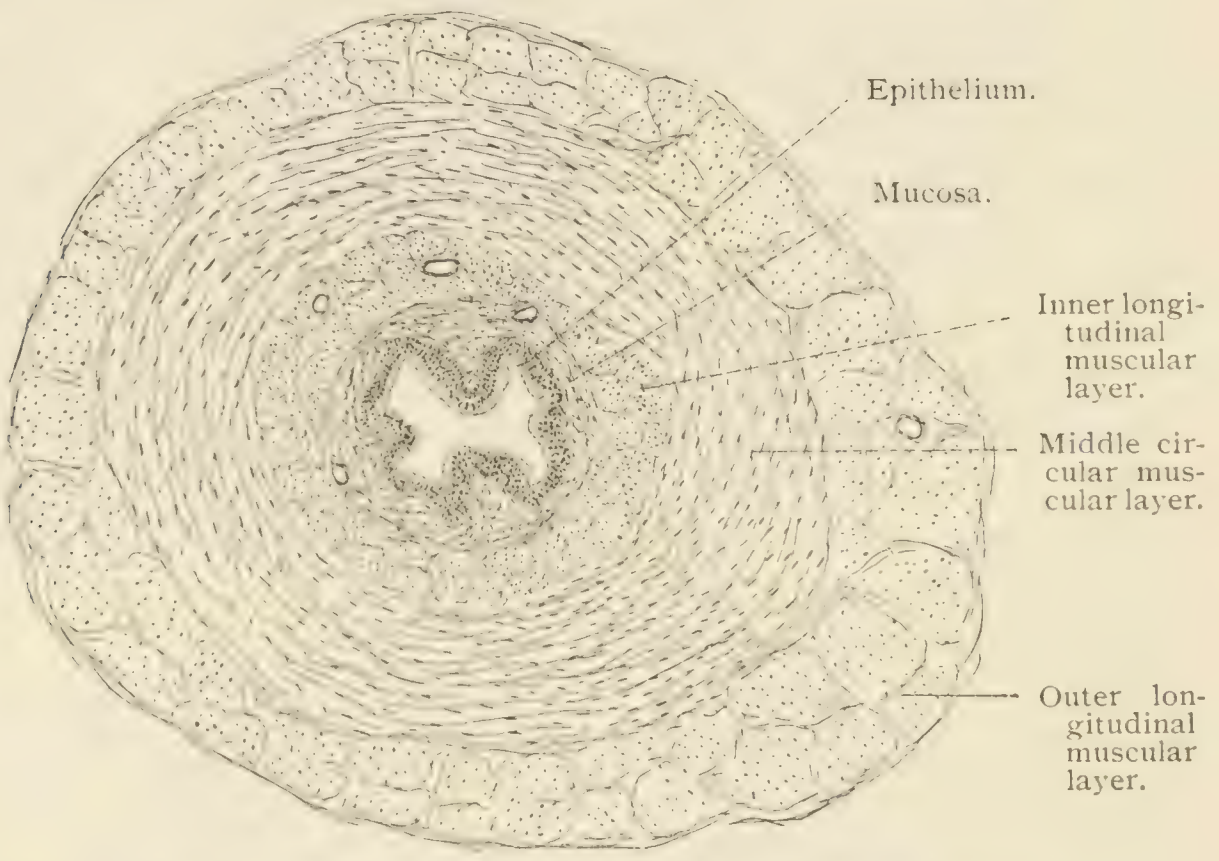

Fig. 297.—Cross-section of vas deferens near the epididymis (human).

numerous folds, which, in the guinea-pig for instance, present a delicate axial connective-tissue stroma. Besides scanty subepithelial connective tissue, the seminal vesicles are provided with an inner circular and an outer longitudinal layer of muscle-fibers. Spermatozoa are, as a rule, not met with in the seminal vesicles.

The epithelium of the *ejaculatory ducts* is composed of a single layer of cells; the inner circular muscle-layer is very poorly developed. In the prostatic portion of the ejaculatory ducts the longitudinal muscle-layer mingles with the musculature of the prostate and loses its individuality. The ejaculatory ducts empty either directly into the urethra at the colliculus seminalis, or indirectly into the prostatic portion of the urethra through the vesicula prostatica.

The *prostate* is a compound branched tubulo-alveolar gland. Its

capsule consists of dense layers of nonstriated muscle-fibers, connective tissue, and yellow elastic fibers. Processes and lamellæ composed of all these elements extend into the interior of the gland, converging toward the base of the colliculus seminalis. Between the larger trabeculæ are situated numerous glands, consisting of large,

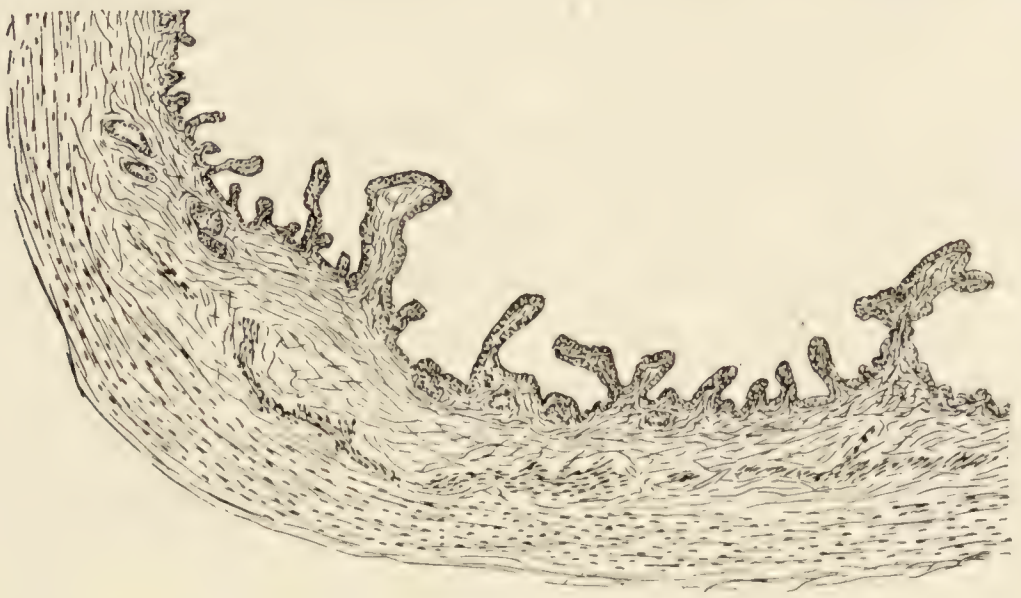

Fig. 298.—Cross-section of wall of seminal vesicle, showing the folds of the mucosa (human).

Fig. 299.—From section of prostate gland of man.

irregular alveoli, separated by fibromuscular septa and trabeculæ. The alveoli are lined by simple columnar epithelium, the inner portion of the cells often showing acidophile granules. Now and then the alveoli present a pseudostratified epithelium, with two rows of nuclei (Rudinger, 83). A basement membrane, although

present, is difficult to demonstrate and consists of a network of delicate connective-tissue threads, as was shown by Walker. The numerous excretory ducts, lined by simple columnar epithelium, become confluent and form from 15 to 30 collecting ducts which empty, as a rule, either at the colliculus seminalis or into the sulcus prostaticus. Near their terminations the larger ducts are lined by transitional epithelium similar to that lining the prostatic portion of the urethra.

In the alveoli of the glands, peculiar concentrically laminated concrements are found, known as *prostatic bodies* or *concretions* (corpora amylacea). They are more numerous in old men, but are found in the prostates of young men and also of young boys. The secretion of the prostate (succus prostaticus) is not mucous in character, but resembles a serous secretion and has an acid reaction. The vesicula prostatica (sinus pocularis) is lined by stratified epithelium, consisting of two layers of cells and provided with a distinct cuticular margin upon which rest cilia. In its urethral region occur short alveolar glands.

The glands of Cowper are branched tubular alveolar glands, the alveoli being lined by mucous cells. The smaller excretory ducts, lined by cubical epithelium, unite to form two ducts, one on each side of the urethra; these are 1½ inches long, and are lined by stratified epithelium consisting of two or three layers of cells.

The blood-vessels of the prostate ramify in the fibromuscular trabeculæ and form capillary networks surrounding the alveoli. The veins collecting the blood pass to the periphery of the gland, where they form a plexus in the capsule. The lymphatics begin in clefts in the trabeculæ and follow the veins. The terminal branches of the vessels supplying Cowper's glands are, in their arrangement, like those of other mucous glands.

Numerous sympathetic ganglia are found in the prostate under the capsule and in the larger trabeculæ near the capsule. The neuraxes of the sympathetic cells of these ganglia may be traced to the vessels and into the trabeculæ; their mode of ending has, however, not been determined. Small medullated nerve-fibers terminate in these ganglia in pericellular baskets. Timofeew has described peculiar encapsulated sensory nerve-endings, found in the prostatic and membranous portions of the urethra of certain mammalia. They consist of the terminal branches of two kinds of nerves, inclosed within nucleated laminated capsules: one large medullated nerve-fiber, after losing its medullary sheath, breaks up into a small number of ribbon-shaped branches with serrated edges, which may pass more or less directly to the end of the nerve-ending or may be bent upon themselves; and very much smaller medullated nerve-fibers which, after losing their medullary sheaths, divide into a large number of varicose fibers which form a dense network encircling the ribbon-shaped fibers previously mentioned.

The penis consists of three cylindric masses of erectile tissue —the two corpora cavernosa, forming the greater part of the penis

and lying side by side, and the corpus spongiosum, surrounding the urethra and lying below and between the corpora cavernosa. The two latter are surrounded by a dense connective-tissue sheath, the tunica albuginea. These erectile bodies are surrounded by a thin layer of skin, containing no adipose tissue and no hair-follicles. The corpus spongiosum is enlarged anteriorly to form the glans penis.

The principal substance of the erectile bodies is the so-called erectile tissue: septa and trabeculæ, consisting of connective tissue, elastic fibers, and smooth muscle-cells inclosing a system of communicating spaces. These latter may be regarded as venous sinuses, the walls of which, lined by endothelial cells, are in apposition to the erectile tissue. Under certain conditions the venous sinuses are distended with blood, but normally they are in a collapsed state and form fissures which simulate the clefts found in ordinary connective tissue. In other words, there is here such an arrangement of the blood-vessels within the erectile tissue that the circulation may be carried on with or without the aid of the cavernous spaces. The arteries of the corpora cavernosa possess an especially well-developed musculature. They ramify throughout the trabeculæ and septa of the erectile tissue and break up within the septa into a coarsely meshed plexus of capillaries. A few of these arteries empty directly into the cavernous spaces. On the other hand, the arteries give off a rich and narrow-meshed capillary network immediately beneath the tunica albuginea. This is in communication with a deeper and denser venous network, which, in turn, gradually empties into the venous sinuses. Aside from these there are anastomoses between the arterial and venous capillaries, which later communicate with the venous network just mentioned. The blood current, regulated as it thus is, may pass either through the capillaries alone, or may divide and flow through both these and the venous sinuses. These conditions explain both the erectile and quiescent state of the penis. The relations are somewhat different in the corpus spongiosum urethræ and in the glans penis. In the corpus spongiosum the arteries do not open directly into the venous spaces, but break up first into capillaries. In the submucosa of the urethra there is found a rich venous plexus. In the glands the arteries end in capillaries which pass over into veins with well-developed muscular walls. The blood is collected by means of the venæ emissariæ which empty into the vena dorsalis penis and into the venæ profundæ.

The epithelium of the urethra varies in the several regions. The prostatic portion possesses an epithelium similar to that of the bladder. In the membranous portion, the epithelium may be similar to that found in the prostatic portion, but more often presents the appearance of a pseudostratified epithelium with two or three layers of nuclei. The cavernous region is lined by pseudostratified epithelium, except in the fossa navicularis, where a stratified squamous epithelium is found. Between the fibro-elastic

mucosa and the epithelium there is a basement membrane. There occur in the urethra, beginning with the membranous portion, irregularly scattered epithelial sacculations of different shapes. Some of these show alveolar branching, and are then known as the glands of Littré.

The submucosa of the cavernous portion of the urethra, which contains nonstriated muscle-tissue arranged circularly, is richly supplied with veins, and contains pronounced plexuses communicating with cavernous sinuses, which correspond in general to those of the corpora cavernosa penis.

The glans is covered by a layer of stratified squamous epithelium, often possessing a thin stratum corneum (see Skin). Near the corona of the glans penis there are now and then found small sebaceous glands (see Hair), known as glands of Tyson. The prepuce is a duplication of the skin, the inner surface presenting the appearance of a mucous membrane.

The nerves terminating in the glans penis have recently been studied by Dogiel, who made use of the methylene-blue method in his investigation. He finds Meissner's corpuscles in the connective-tissue papillæ under the epithelium, Krause's spheric end-bulbs somewhat deeper in the connective tissue, and the genital corpuscles situated still deeper (see Sensory Nerve-endings). In the epithelium are found free sensory nerve-endings. Pacinian corpuscles have also been found in this region.

4. SPERMATOGENESIS.

In order that the student may obtain an understanding of the complicated process of spermatogenesis we shall give a description of it as it occurs in salamandra maculosa, which of all vertebrate animals presents the phenomena in their simplest and best known form. The student should understand, however, that many of the details here described have not been observed in the testes of mammalia; and, since the spermatozoa of many of the mammalia are of simpler structure than those of the salamander, the development of the spermatozoa of the former is consequently simpler. It should also be noticed that the general structure of the testes of the salamander differs in some respects from that of the testes of mammalia, as given in the preceding pages.

At first the seminiferous tubules consist of solid cellular cords, and it is only during active production of spermatozoa that a central lumen is formed, in which the spermatosomes then lie. The cells which compose these solid cords may be early differentiated into two classes—those of the one class being directly concerned in the production of the spermatosomes; those of the other appearing to have a more passive rôle. The cells of the first class—the *spermatogonia*, or *primitive seminal cells*—undergo a process of division accompanied by an increase in size. In this way they soon commence to press upon the cells of the second class—the *follicular* or *sustentacu-*

lar cells. The result is that the nuclei of the latter are forced more or less toward the wall of the seminal tubule, while their protoplasm is so indented by the adjacent spermatogonia that the cells assume a flattened cylindric shape presenting indentations and processes on all sides. In this stage the spermatogonia have a radiate arrangement and entirely surround the elongated sustentacular cells. At present three periods are distinguished in the development of the male sexual cells (spermatosomes) from the spermatogonia. The first period embraces a repeated mitotic division of the spermatogonia—the period of proliferation. In the second, the spermatogonia, which have naturally become smaller from repeated division, begin to increase in size—the period of growth. The third is characterized by a modified double mitotic division without intervening period of rest, and results in the matured spermatozoa—the period of maturation, figure 300. During the third period, a very important and significant process takes place—the

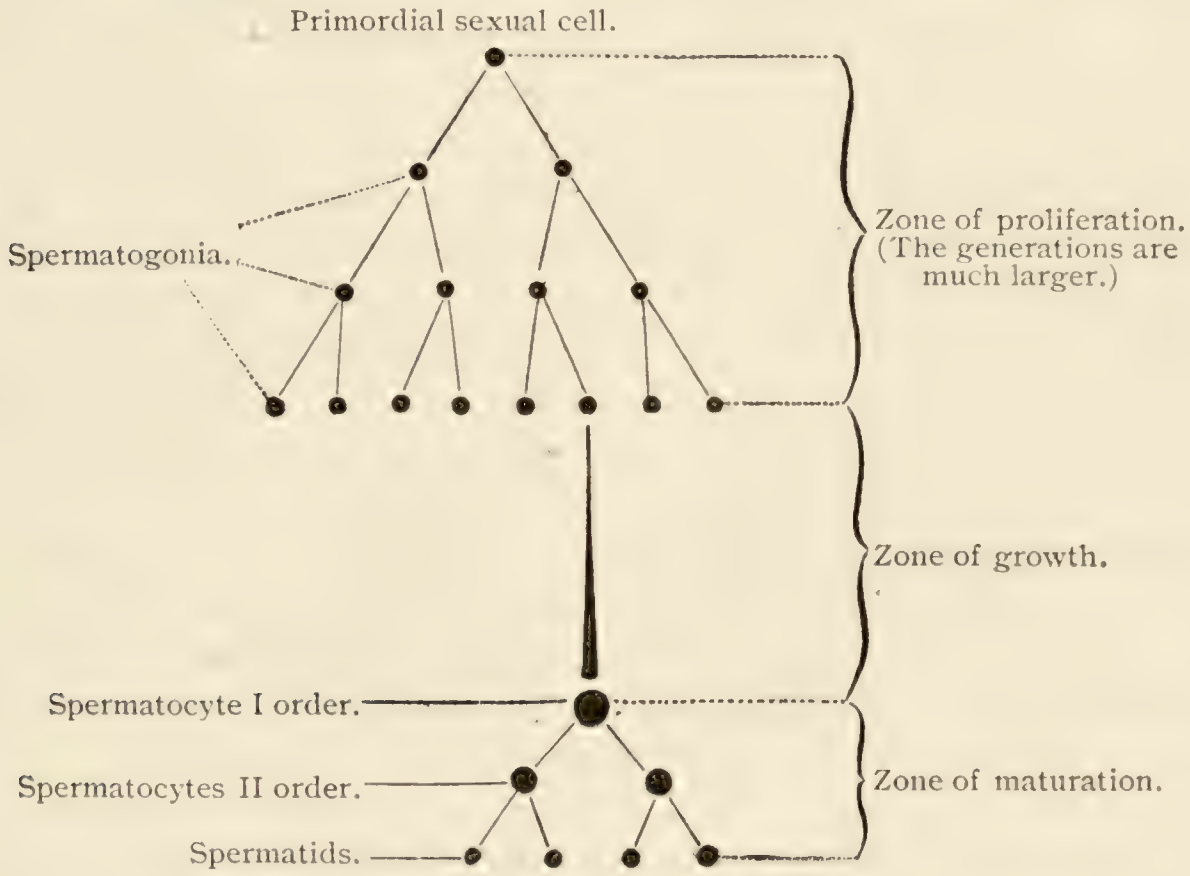

Fig. 300.—Schematic diagram of spermatogenesis as it occurs in ascaris (after Boveri). ("Ergebn. d. Anat. u. Entw.," Bd. 1.)

reduction in the number of chromosomes, so that in the spermatids, the chromosomes are reduced to half the number present in a somatic cell of the same animal. The manner in which this reduction in the number of chromosomes takes place will be described as it occurs in salamandra maculosa.

After the cells composing the last generation of spermatogonia have attained a certain size (period of growth), they undergo karyokinetic division. First, the usual skein or spirem is formed, but instead of dividing into twenty-four chromosomes, as in the somatic cell, the filament of the skein segments into only twelve loops. The cell thus provided with twelve chromosomes now enters upon the period of maturation, and is known as a

spermatocyte of the first order, or a "mother cell" (O. Hertwig, 90). The division of these cells is heterotypic (*vid.* p. 70); the chromosomes split longitudinally and in such a way that the division begins at the crown of the loops, extending gradually toward their free ends. In this case the daughter chromosomes remain for some time in contact, so that the metakinetic figure resembles a barrel in shape. Finally, the daughter chromosomes separate and wander toward the poles. As soon as the daughter stars (diaster) are developed, the number of chromosomes is again doubled by a process of longitudinal division. The spermatocyte of the first order thus divides into two spermatocytes of the second order, or daughter cells (O. Hertwig, 90). The nuclei of the daughter cells now contain twenty-four chromosomes, as is the case in the somatic cell, and, without undergoing longitudinal splitting, the daughter chromosomes are distributed to the two nuclei of the spermatids. In other words, the latter contain only twelve chromosomes. The spermatozoa are formed from the spermatids by a rearrangement of the constituent elements of these cells. It may thus be said that even in the stage of the segmenting skein in the mother cells, the spermatocytes of the first degree contain twice as many chromosomes as a somatic cell, a condition which is first clearly seen in the stage of the diaster (here only an apparent duplication in the diaster stage). As a result, there is, first, a decrease in the double number of chromosomes found in the spermatocytes of the second degree to the normal number; second, a decrease in the number of chromosomes in the spermatocytes of the third degree (spermatids) to one-half the number present in a somatic cell, a condition probably due to the fact that here there is no stage of rest nor longitudinal splitting of the chromosomes. This is the general process in heterotypic division. Besides the heterotypic form, there occurs in the division of the spermatocytes another (homeotypic) form of karyokinetic cell-division. This differs from the heterotypic in the shortness of the chromosomes, the absence of the barrel phase, the late disappearance of the aster, and the absence of duplication in the chromosomes of the diaster. According to Meves (96), the spermatocytes of the first degree undergo heterotypic, those of the second degree, homeotypic division.

The spermatids develop into the spermatozoa, beginning immediately after the close of the second division of maturation. This process has been fully described for salamandra maculosa by Hermann, Flemming, Benda, and others, but need not engage our attention at this point beyond the statement that the chromatin of the nuclei of the spermatids develops into the heads of the spermatozoa, while the remaining structures are developed from the protoplasm. "The mature spermatozoon of the salamander represents a completely metamorphosed cell; in the course of its development no portion of the original cell is cast off" (Meves, 97).

Spermatogenesis in mammalia may be compared to the foregoing

process, with the exception that here the different stages are seen side by side in the seminiferous tubule and without any apparent sequence, making the successive stages more difficult to demonstrate. The various generations of cells form columns, and are arranged in such a manner that the younger are found near the lumen and the older close to the wall of the tubule. (Figs. 301 and

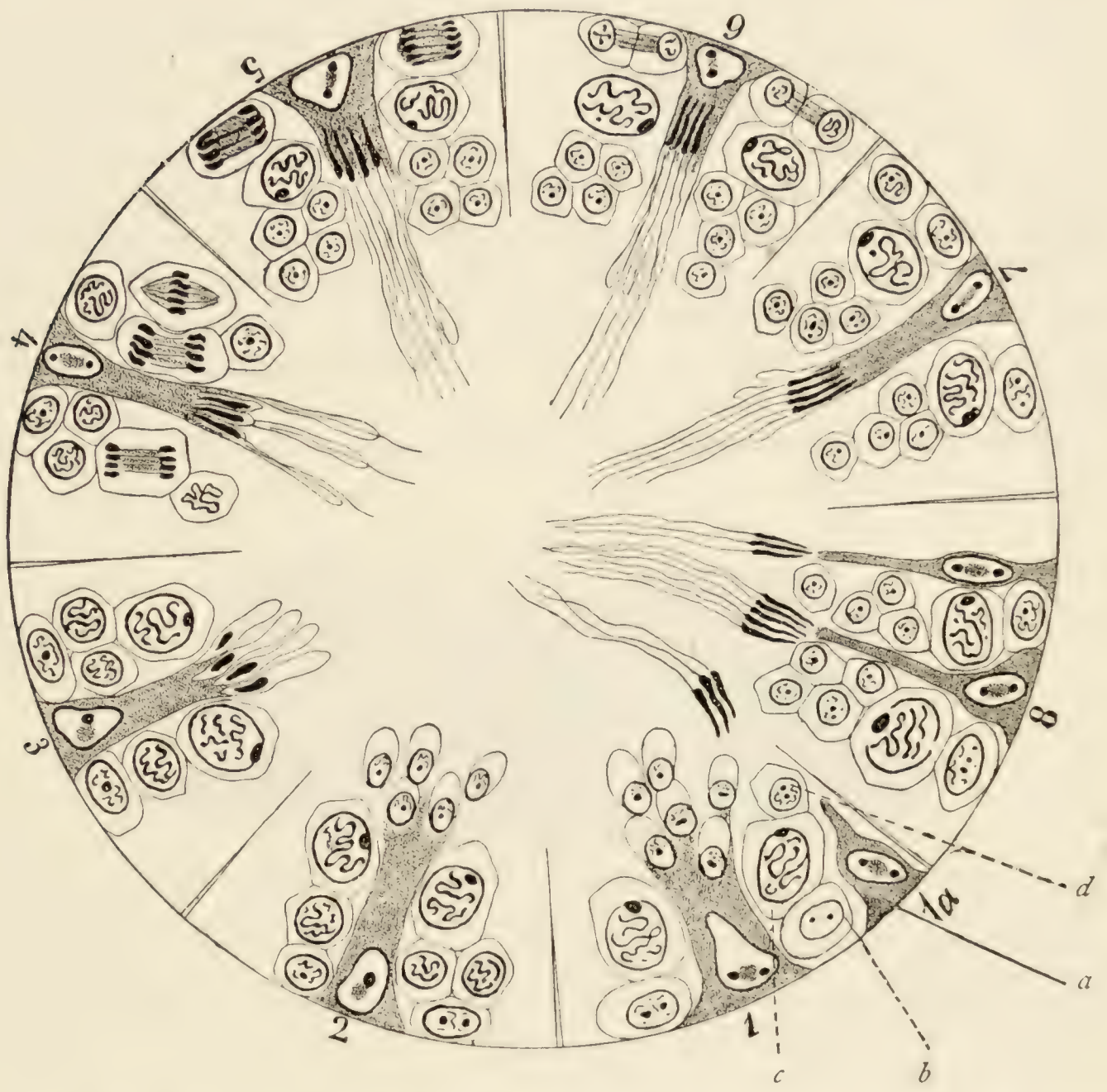

Fig. 301.—Schematic diagram of section through convoluted seminiferous tubule of mammal, showing the development of the spermatosomes. The number of chromosomes is not shown in the various generations of the spermatogenic cells. The progressive development of the spermatogenic elements is illustrated in the eight sectors of the circle: *a*, Young sustentacular cell; *b*, spermatogonium; *c*, spermatocyte; *d*, spermatid. In 1, 2, 3, and 4 the spermatids rest on the enlarged sustentacular cell in the center of the sector; on both sides of the sustentacular cells are the spermatogenic or mother cells in mitosis. In the sectors 5, 6, 7, and 8 spermatozoa are seen in advanced stages resting on the sustentacular cells, with new generations of spermatids on each side. [From Rauber (after Brown) with changes (after Hermann).]

302.) These columns are separated from each other by high sustentacular cells, or Sertoli's cells or columns. The metamorphosis of the cells into spermatids and spermatosomes is accomplished by the changing of the cells bordering upon the lumen and then of those in the deeper layers, etc., into spermatids and then into spermatosomes. During this process the spermatids arrange

themselves around the ends of Sertoli's columns, a phenomenon which was formerly regarded as representing a copulation of the two elements, although it was clearly understood that no real fusion or interchange of chromatin occurred, but that the close relations of the two were for the purpose of furnishing nourishment to the developing spermatosomes. The whole forms a spermatoblast of von Ebner. Since the spermatids lining the lumen are changed into spermatozoa, and the process is repeated in the cells of the deeper layers as they come to the surface, the result is that the entire column is finally used up. The compensatory elements are supplied by the proliferation of the adjacent spermatogonia. The resulting products again divide, and thus build up an entirely new generation of spermatogenic cells. Hand in hand with these progressive phenomena occurs an extensive destruction of the cells taking part in spermatogenesis. This is shown by the presence of so-called karyolytic figures in the cells, which later suffer complete demolition.

These developmental changes are represented in the preceding schematic figure (Fig. 301), and may in part be observed in figure 302.

Fig. 302.—Section of convoluted tubule from rat's testicle (after von Ebner, 88). The pyramidal structures are the sustentacular cells, together with spermatids and spermatosomes. Between these are spermatogenic cells, some of which are in process of mitotic division. Below, on the basement membrane and concealing the spermatogonia, are black points representing fat-globules, a characteristic of the rat's testicle. Fixation with Flemming's fluid.

In mammalia it has been possible to trace the development of the spermatids into the spermatosomes. These phenomena have been studied and described by numerous writers, and although many conflicting views have been expressed, the essential steps of this process seem quite clearly established. The account here given is based in part on the recent observations of v. Lenhossék and the observations of Benda. Before considering the method of development of the spermatosomes from the spermatids, a few words concerning the structure of the latter may be useful. The sharply outlined spermatid possesses a slightly granular protoplasm and a round or slightly oval nucleus with a delicate chromatic network. In the protoplasm there is found a sharply defined globule, known as the sphere or sphere substance, which lies near the nucleus and

presents throughout a nearly homogeneous structure. This substance is first noticed in the spermatocytes, disappears during the cell-divisions resulting in the spermatids, and reappears in the latter. In the protoplasm of the spermatid, lying near the nucleus, there is further found a small globular body, the chromatoid accessory nucleus of Benda, smaller than the sphere and staining very deeply in Heidenhain's hematoxylin. A true centrosome may also be found in the spermatid.

The nucleus of the spermatid develops into the head of the spermatosome, during which change the originally spheric nucleus becomes somewhat flattened and at the same time assumes a denser structure and moves toward that portion of the spermatid pointing away from the lumen of the seminiferous tubule. Accompanying these changes in the nucleus, marked changes are observed in the shape and structure of the sphere, which marks the position of the future anterior end of the head of the spermatosome, and applies itself to the nucleus on the side pointing away from the lumen of the tubule. In this position it differentiates into an outer clear homogeneous zone and a central portion which stains more deeply and to which v. Lenhossék has given the name akrosome. From these structures are developed the head-cap and the lance of the spermatosomes, which differ in shape and relative size in the spermatosomes of the different vertebrates. Recent investigation seems to establish quite clearly that the axial thread of the tail is developed from the centrosome (from the larger, if two are present), which is situated at some distance from the nucleus. Soon after the beginning of the development of the axial thread the centrosome wanders to the posterior part of the future head of the spermatosome (the pole of the nucleus opposite the head-cap) and becomes firmly attached to the nuclear membrane in this position (observations made on the rat by v. Lenhossék, and on the salamander by Meves). The middle piece and the undulating membrane, it would appear, are differentiated from the protoplasm, although the question of the mode of their development is still open to discussion. The chromatoid body assumes a position near the axial thread at its junction with the cell membrane; its fate has not, however, been fully determined.

According to Hermann (97), the end-piece in the selachia is derived from the centrosome, the ring-shaped body from the invaginated half of the intermediate body of the spermatid formed during the last spermatocytic division, and the axial thread from filaments of the proximal half of the central spindle. The lance, according to him, represents a modified portion of the nuclear membrane of the spermatid.

For further particulars regarding spermatogenesis see the investigations of v. la Valette St. George, 67–87; v. Brunn, 84; Biondi, Benda, Meves, and v. Lenhossék.

TECHNIC.

The ovaries of the smaller animals are better adapted to study than those of the human being, since the former are more easily fixed.

The germinal epithelium and its relations to the egg-tubes of Pflüger are best studied in the ovaries of young or newly born animals—cats, for instance, being especially well adapted to this purpose.

Normal human ovaries are usually not easily obtainable. Human ovaries very often show pathologic changes, and in middle life frequently contain but few follicles.

Fresh ova may be easily procured from the ovaries of sheep, pig, or cow in the slaughter-houses. On their surfaces are prominent transparent areas—the larger follicles. If a needle be inserted into one of these follicles and the liquor folliculi be caught upon a slide, the ovum may as a rule be found, together with its corona radiata. That part of the preparation containing the ovum should be covered with a cover-glass under the edges of which strips of cardboard are laid. If no such strips are employed, the zona pellucida of the ovum is likely to burst in the field of vision, giving rise to a funnel-shaped tear. These tears have often been pictured and described as preformed canals (micropyles).

The best fixing fluid for ovarian tissue is Flemming's or Hermann's, either of which may be used for small ovaries or pieces of large ovaries; safranin is then used for staining. Good results are also obtained with corrosive sublimate (staining with hematoxylin according to M. Heidenhain), and also with picric acid (staining with borax-carmin).

The treatment of the Fallopian tubes is the same as that of the intestine; in order to obtain cross-sections of a tube it is advisable to dissect away the peritoneum near its line of attachment and then distend the tube before fixing. It is instructive to dilate the tube by filling it with the fixing agent, thus causing many of the folds to disappear.

No special technic is necessary in fixing the uterus and vagina. The epithelium is, however, best isolated with one-third alcohol.

Seminal fluid to which normal salt solution has been added may be examined in a fresh condition. The effect upon the spermatozoa of a very dilute solution of potassium hydrate (1% or weaker) or of a very dilute acid (acetic acid) is worth noticing. The spermatozoa of salamandra maculosa show the different structural parts very clearly (lance, undulating membrane, marginal thread, etc.). In macerated preparations (very dilute chromic acid), or in those left for some time in a moist chamber, the fibrillar structure of the marginal and axial threads may be seen quite distinctly. The spermatozoa may also be examined in the form of dry preparations (treatment as for blood), stained, for instance, with safranin. Osmic acid, its mixtures, and osmic vapors are useful as fixing agents, certain structures being better brought out so than by employing the dry methods.

In examining the testicle (spermatogenesis) it is advisable to begin with the testis of the salamander, which does not show such complicated structures as do the testes of mammalia. Here also either Flemming's or Hermann's fluid may be used as a fixing agent, the latter being

followed by treatment with crude pyroligneous acid. For the salamander Hermann recommends a mixture composed of 1% platinum chlorid 15 c.c., 2% osmic acid 2 c.c., and glacial acetic acid 1 c.c., and for mammalia the same solution with double the amount of osmic acid. The fluid is allowed to act for some days, the specimen then being washed for twenty-four hours in running water and carried over into alcohols of ascending strengths. Paraffin sections are treated as follows: Place for from twenty-four to forty-eight hours in safranin (safranin 1 gm. is dissolved in 10 c.c. of absolute alcohol and diluted with 90 c.c. of anilin water). After decolorizing with pure or acidulated absolute alcohol the sections are placed for three or four hours in gentian-violet (saturated alcoholic solution of gentian-violet 5 c.c. and anilin water 100 c.c.), and are then placed for a few hours in iodo-iodid of potassium solution until they have become entirely black (iodin 1, iodid of potassium 2, water 300); finally, they are washed in absolute alcohol, until they become violet with a dash of brown. The various structures appear differently stained: for instance, the chromatin of the resting nucleus and of the dispirem, bluish-violet; the true nucleoli, red; while, on the other hand, in the aster and diaster stages the chromatin stains red.

It is of especial importance that small testicles should not be cut into pieces before fixing, as this causes the seminal tubules to swell up and show marked changes, even in regions at some distance from the cut (Hermann, 93, I).

The treatment of the remaining parts of the male reproductive organs requires no special technic.

VI. THE SKIN AND ITS APPENDAGES.

A. THE SKIN (CUTIS).

The skin consists of two intimately connected structures—the one, of mesodermic origin, is the true skin, corium or *dermis;* the other, of ectodermic origin, is the *epidermis* or cuticle. The superficial layer of the corium is raised into ridges and papillæ which penetrate into the epidermis, the spaces between the papillæ being filled with epidermal elements. Thus, the lower surface of the epidermis is alternately indented and raised into a system of furrows and elevations corresponding to the molding of the corium.

In the epidermis two layers of cells may be observed—the *stratum Malpighii*, or stratum germinativum (Flemming), and the horny layer, or stratum corneum. According to the shape and characteristics of its cells, the stratum germinativum may also be divided into three layers—first, the deep or basal layer, consisting of columnar cells resting immediately upon the corium; second, the middle layer, consisting of polygonal cells arranged in several strata, the number of the latter varying according to the region of the body; and third, the upper layer, or *stratum granulosum*, which is composed, at most, of two or three strata of gradually flattening cells characterized by their peculiar granular contents.

All these cell layers consist of prickle cells, and for this reason the stratum Malpighii is sometimes known as the stratum spinosum. When these cells are isolated by certain methods, their surfaces are seen to be provided with short, thread-like processes. In section the cells appear to be joined together by their processes. Since it has been proved that the processes of adjacent cells do not lie side by side, but meet and fuse, they must be regarded as belonging alike to both cells. Between the fused processes, which are known as *intercellular bridges*, there exists a system of channels which is in communication with the lymphatic system of the corium. The prickles just mentioned are variously regarded by different investigators; some considering them to be exclusively protoplasmic

Fig. 303.—Under surface of the epidermis, separated from the cutis by boiling. The sweat-glands may be traced for a considerable part of their length; × 40: *a*, Sweat-gland; *b*, longitudinal ridge; *c*, depression; *d*, cross-ridge.

processes of the cells, others regarding them as derived from the membranes of the cells composing the stratum Malpighii. Ranvier and others ascribe a fibrillar structure to the peripheral portion of the cellular protoplasm, and, according to them, these fibrillæ, surrounded by a small quantity of indifferent protoplasm, form the processes. Ranvier has also shown that such fibrillæ may extend from one cell around several others before reaching their ultimate destination in other cells at some distance. (Fig. 305.) The cells of the stratum granulosum contain peculiar deposits of a substance to which Waldeyer has given the name of *keratohyalin*. This substance occurs in the form of irregular bodies varying in size and imbedded in the protoplasm. The nuclei of such cells always

show degenerative processes, which are possibly due to the formation of the keratohyalin (Mertsching, Tettenhamer). These karyolytic figures and keratohyalin possess in common many apparently identical microchemic peculiarities, and it is very probable that karyolysis and the formation of keratohyalin are processes originally very closely allied—*i. e.*, that the keratohyalin is derived from the fragments of the dying nucleus.

The stratum corneum forms the outer layer of the epidermis and presents, as a rule, a somewhat differentiated lower stratum. This

Fig. 304.—Cross-section of skin of child, with blood-vessels injected; × 30.

latter is more especially noticeable in those regions in which the stratum corneum is highly developed, and is known as the *stratum lucidum*. It is quite transparent, this property being due to the presence in its cells of a homogeneous substance, which is in all probability a derivative of the more solid keratohyalin of the stratum granulosum. The cells of the stratum corneum are more or less flattened and cornified, especially at their periphery. This applies more particularly to the superficial cells. In the interior of each cell a more or less degenerated nucleus may be seen, but otherwise its contents are homogeneous, or, at most, arranged

in concentric lamellæ (Kölliker, 89). Here and there between the cornified cells structures may be seen which probably represent the remains of intercellular bridges. The thickness of the epidermis varies greatly according to the locality, and is directly proportionate to the number of its cell layers. As a rule, the stratum Malpighii is thicker than the stratum corneum, but in the palm of the hand and the sole of the foot the latter is considerably the thicker.

The various layers of the epidermis are in close genetic relationship to one another. The constant loss to which the epidermis is subjected by desquamation is compensated by a continuous upward pushing of its lower elements; cell-proliferation occurs in the basal cells and adjacent cellular strata of the stratum germinativum (Malpighii), where the elements are often seen in process of mitotic division. The young cells are gradually pushed outward, and during their course assume the general characteristics of the elements composing the layers through which they pass. For instance, such a cell changes first into a cell of the stratum germinativum; then, when it commences the formation of keratohyalin, into a cell of the stratum granulosum; later, into a cell of the stratum lucidum, and finally into an element of the stratum corneum, where it loses its nucleus, cornifies, and at last drops off.

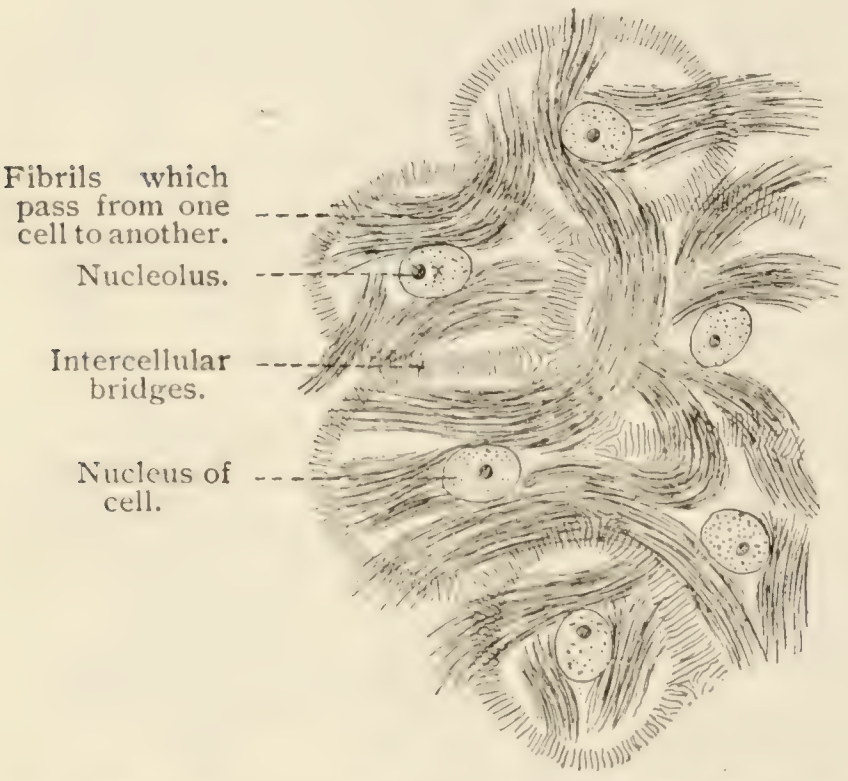

Fig. 305.—Prickle cells from the stratum Malpighii of man; ×480.

The mesodermic portion of the skin, the *corium*, consists of a loose, subcutaneous connective tissue containing fat, the subcutaneous layer, with the panniculus adiposus, and of the true skin, or corium proper. The amount of adipose tissue in the subcutaneous layer is subject to great variation; there are, however, a few regions in which there is normally very little or no fat (external ear, eyelids, scrotum, etc.). To the subcutaneous connective tissue is due the mobility of the skin. The corium may be compared to the mucosa of a mucous membrane, and consists of two layers—of a deeper and looser *pars reticularis*, and of a superficial *pars papillaris* supporting the papillæ. The transition from the one to the other is very gradual. Elastic fibers are present in the connective tissue of both layers.

The pars reticularis is made of bundles of connective-tissue fibers arranged in a network, nearly all of the strands of which have a direc-

tion parallel with the surface of the skin and are surrounded by a reticulum of rather coarse elastic fibers. In that portion of the pars papillaris bordering upon the epidermis, the interlacing strands of connective tissue, as well as the surrounding reticulum of elastic fibers, are finer, so that the whole tissue is denser. This stratum supports the papillæ—knob-like or conical elevations of still denser tissue ending in one or more points. We accordingly speak of simple or compound papillæ. These structures are especially numerous and well developed in the palm of the hand and sole of the foot, where they are from 110 μ to 220 μ long. Here they rest upon ridges of the corium, which are nearly always arranged in double rows. According to whether the papillæ contain blood-vessels alone, or special nerve-endings also, they are known as *vascular* or *tactile* papillæ.

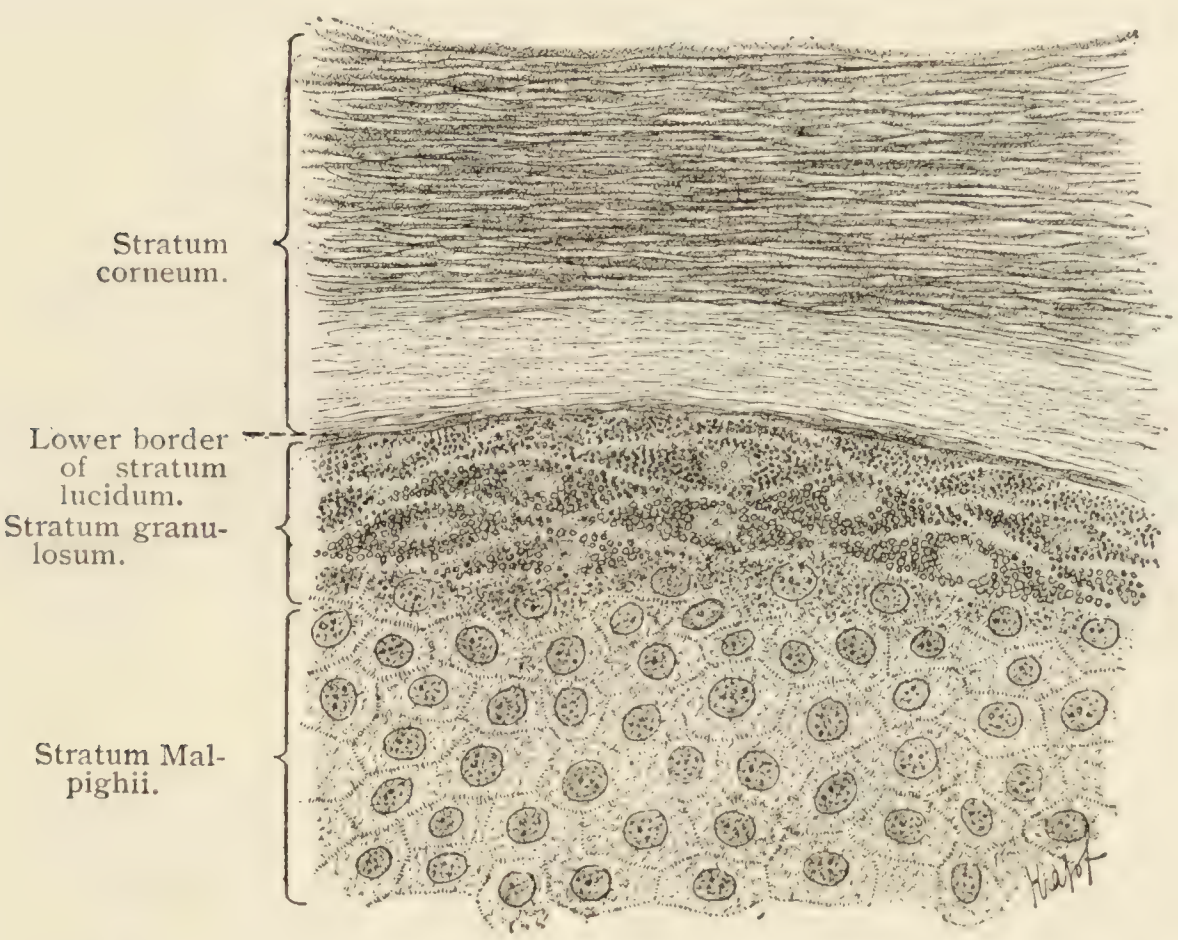

Fig. 306.—Cross-section of human epidermis ; the deeper layers of the stratum Malpighii are not represented ; × 750.

The smallest papillæ are found in the mammæ and scrotum—from 30 μ to 50 μ long. The surface of the pars papillaris is covered by an extremely delicate membrane—the basement membrane. According to most authors, the basal cells of the epidermis are simply cemented to this structure. Others believe that the epithelial cells are provided with short basilar processes which penetrate into the basement membrane and meet here with similar structures from the connective-tissue cells of the corium. This would give the basement membrane a fibrillar structure (Schuberg).

The subcutaneous layer contains numerous more or less vertical strands of connective tissue, containing numerous large elastic-tissue fibers and joining the stratum reticulare of the corium to the

superficial fascia of the body or underlying structure, whatever that may be. These strands are the *retinaculæ cutis*, and inclose in their meshes masses of fatty tissue which form the *panniculus adiposus*. The latter varies greatly in thickness in different parts of the body. The vertically arranged cords of connective tissue are accompanied by blood-vessels, nerves, and the excretory ducts of glands.

Smooth muscle-fibers are also present in the skin, and around the hair follicles are grouped into bundles. Nearly continuous layers of smooth muscle tissue are found in the subcutaneous layer of the scrotum (forming here the *tunica dartos*), in the perineum, in the areolæ of the mammæ, etc. In the face and neck striated muscle-fibers also extend outward into the corium.

Even in the white race certain regions of the epidermis always contain pigment—as, for instance, the areolæ and mammillæ of the

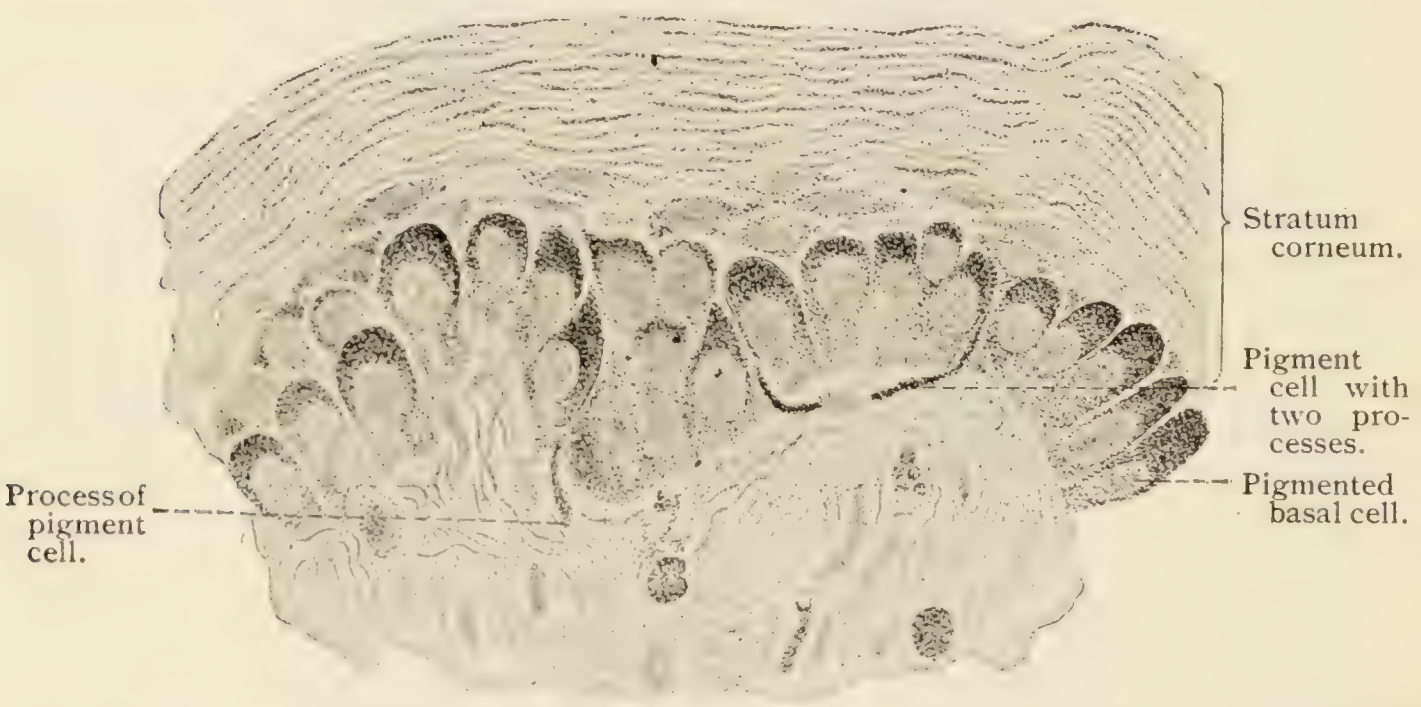

Fig. 307.—Cross-section of negro's skin, showing the intimate relationship of the pigment cells of the corium to the basilar cells of the epidermis. The latter are more deeply pigmented at their outer ends. The pigment granules may be traced into the outermost layers of the stratum corneum; × 525.

mammary glands, the scrotum, labia majora, around the anus, etc. In these regions the epithelial cells and the connective-tissue cells of the pars papillaris corii contain a variable number of small pigment granules. The latter occur chiefly in the basal cells of the epidermis and diminish perceptibly in the cells of the overlying layers, so that in those of the stratum corneum few, if any, are left. In negroes and other colored races the deep pigmentation is due to a similar distribution of the pigment granules in the entire epidermis; but even here the pigmentation decreases toward the surface, although the uppermost cells of the stratum corneum always contain some pigment. The nuclei of the cells are always free from the coloring-matter. The question as to the origin of the pigment is as yet unsolved. This much is known: that in those regions where pigment is present certain branched and deeply pigmented connec-

tive-tissue cells are found immediately beneath the epidermis, sending out processes which may be traced outward between the cells of the stratum Malpighii (Aeby). This fact has led some authors to believe that the connective tissue is in reality the source of the pigment, and that by some unknown process the latter is taken up and conveyed to the cells of the epidermis. This theory would preclude a direct production of pigment granules in the epidermal cells. But although it can not be denied that the pigment may be derived from the connective tissue, it is hardly logical to assume *a priori* that epithelial cells are not capable of pigment production, since, in other regions of the body, pigment formation may be observed in cells of undoubted epithelial origin, as, for instance, in ganglion cells and in

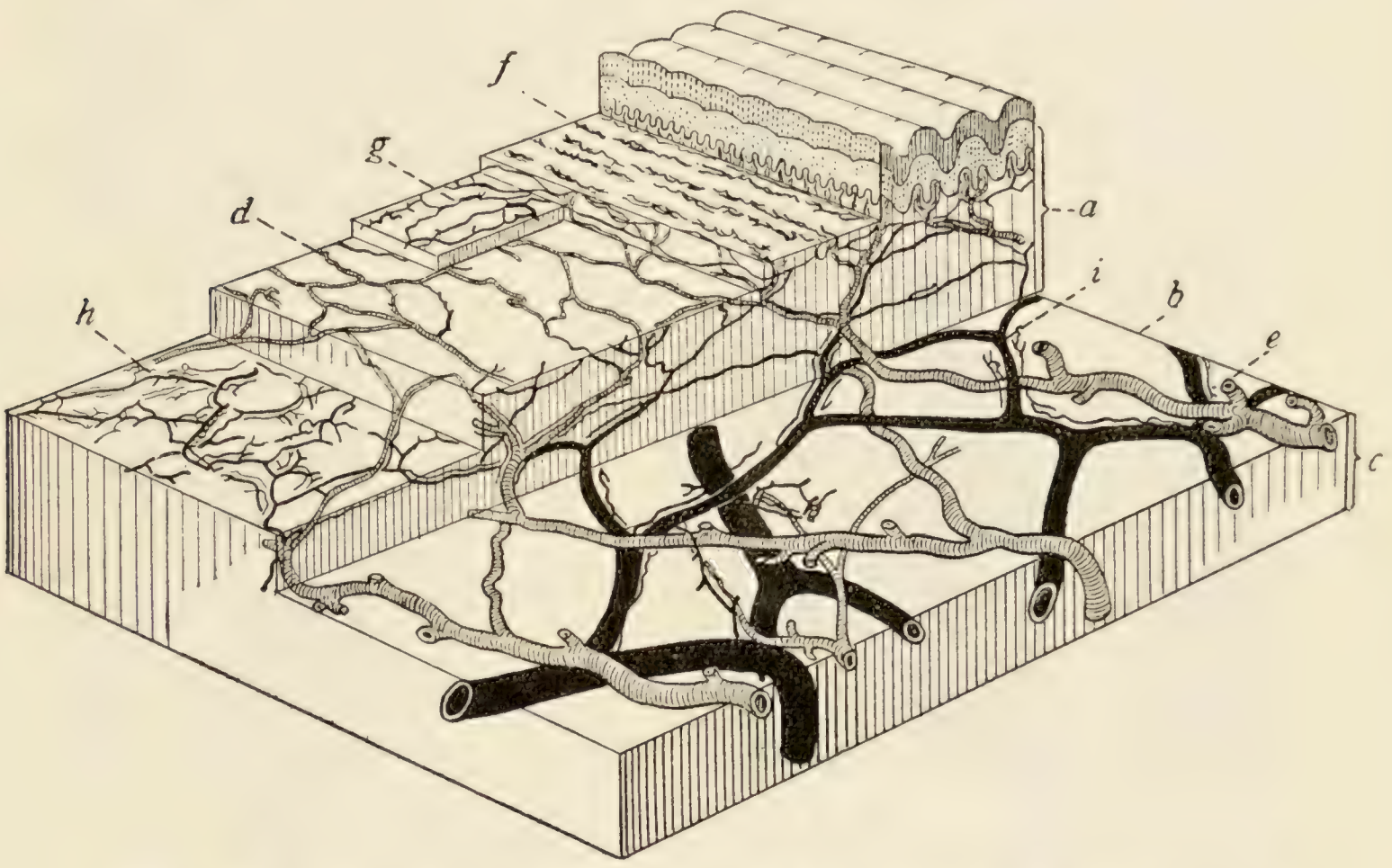

Fig. 308.—A reconstruction showing the arrangement of the blood-vessels in the skin of the sole of the foot (Spalteholz): *a*, Stratum Malpighii and corium; *b*, boundary between cutis and subcutis, in the region of the coiled portions of the sweat-glands; *c*, subcutis; *d*, subpapillary arterial network; *e*, cutaneous arterial network; *f*, *g*, *h*, and *i*, first, second, third, and fourth venous plexuses.

the pigment epithelium of the retina. An interesting proof that the processes of pigmented connective-tissue cells actually penetrate the epidermis is afforded by the case reported by Karg, of transplantation of a piece of skin from a white man to a negro. After some time the piece of white skin became pigmented. Reinke has demonstrated that the pigment in certain cells is in combination with certain definite bodies. The latter have been given the botanical name of *trophoplasts*. If the pigment be removed, colorless trophoplasts are left. They may be tinged with certain stains. In the epidermis of the white race trophoplasts are also constantly present, although they are only slightly or not at all pigmented (Barlow).

The following may be said concerning the *vascular system* of the skin : The arteries which supply the skin with nutriment penetrate the corium and form a characteristic network in its lowest stratum. They also anastomose freely in the fascia and the subcutaneous layer. From this plexus branches pass outward to form a second or subpapillary plexus. From the latter, branches are again given off which, without further anastomoses, pass along beneath the rows of papillæ and supply each separate papilla with capillary twigs. These in turn pass over into venous capillaries which unite and form four venous plexuses, one over the other and in general parallel to the surface of the skin. The uppermost venous plexus lies beneath the papillæ, each venule corresponding to a single row of papillæ and anastomosing with its neighbors. The second plexus is found immediately beneath the first, the third in the lower portion of the corium, and the fourth at the junction of the cutis and subcutis. Near the middle of the subcutis the arteries show a circular musculature, but the veins are already thus provided in the network between the cutis and subcutis, where they also seem to possess valves. As already stated, the subcutaneous fat is divided into lobes by transverse and longitudinal bundles of connective tissue ; a second system of bundles midway between the cutis and fascia separates the panniculus adiposus into an upper and a lower layer. The former is supplied by direct arterial branches ; the latter, by branches passing backward from the cutaneous network. Those regions which are subjected to great external pressure are supplied by a greater number of afferent vessels the caliber of which is increased. In regions where the skin is very mobile the arteries are greatly convoluted. All these vascular peculiarities are present in the newborn (Spalteholz).

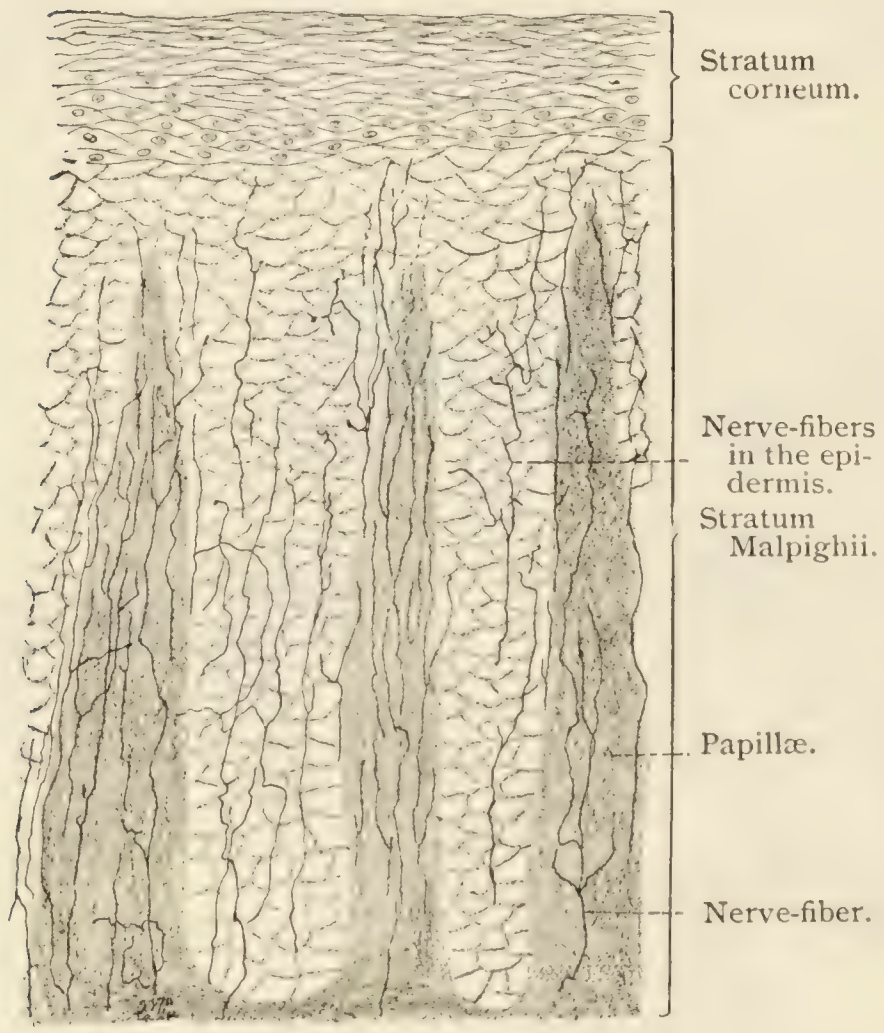

Fig. 309.—Nerves of epidermis and papillæ from ball of cat's foot ; × 750.

The *lymph-vessels* of the true skin are also distributed in two layers—a deep and wide-meshed plexus in the subcutis, and a

superficial narrow-meshed plexus immediately beneath the papillæ. Into the latter empty the lymph-vessels coming from the papillæ. After treating the skin by certain methods, a fine precipitate may be noticed here and there in the papillary region of the corium, a proof that lymph clefts are present. These are regarded as the beginnings of the cutaneous lymphatic system. They may also be traced into the epithelium, where they are in direct communication with the interspinal spaces between the epithelial cells (Unna). Cells are also met with in the interspinal spaces of the epidermis; these are migratory cells, or cells of Langerhans.

The skin owes its great sensitiveness to the numerous *nerves* and special *nerve-endings* present, not only in the epithelium, but also in the corium and subcutis. In certain regions of the skin the nerves have been traced into the epithelium. In the finger-tip, for instance, numerous nerves are seen in the epidermis, where they branch and end in telodendria with or without small terminal swellings. There is no direct communication between the terminal

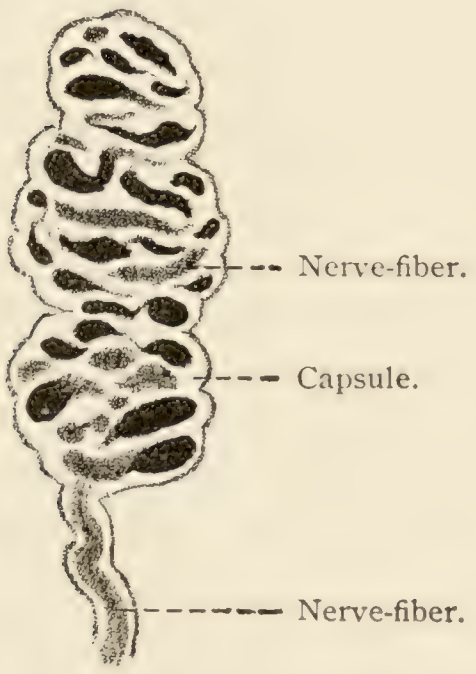

Fig. 310.—Meissner's corpuscle from man; × 750.

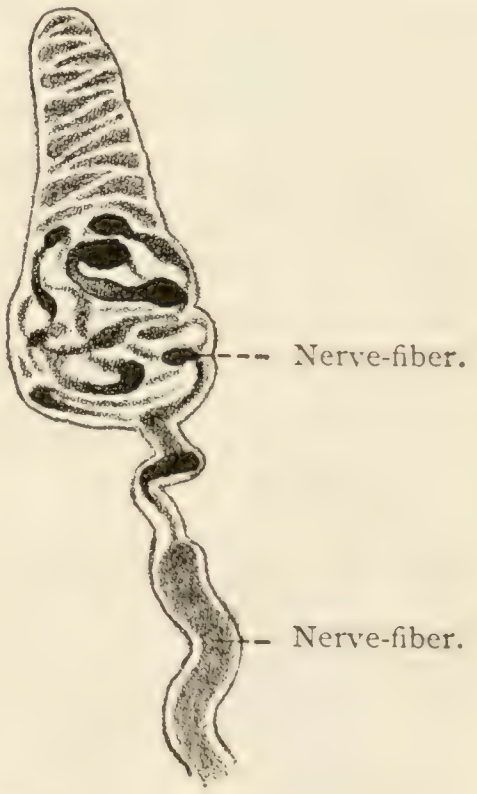

Fig. 311.—Meissner's corpuscle from man; × 750.

nerve filaments and the epithelial cells. (Fig. 309.) In certain peculiarly sensitive regions, as the end of the pig's snout, the nerve-fibers end in distinct saucer-like discs (tactile menisci) which, as a rule, clasp the lower ends of the basal Malpighian cells.

The special sensory nerve-endings are situated in the corium and subcutis. Of these, we may mention the tactile corpuscles of Meissner, the end-bulbs of Krause, the Pacinian corpuscles, Ruffini's nerve-endings, and the Golgi-Mazzoni corpuscles. All these special sensory nerve-endings with the exception of the two last mentioned have been discussed in a former chapter (p. 169). Meissner's tactile corpuscles are situated in the tactile papillæ of the true skin. They are especially numerous in the hand and foot.

In the distal phalanx of the index-finger every fourth papilla is a tactile papilla, containing one or sometimes two corpuscles of Meissner. They are, however, not nearly so numerous in other parts of the hand or in the foot. These corpuscles are further found on the dorsal surface of the hand and volar surface of the forearm, in the nipple and external genitals, in the eyelids (border), and in the lips. In figures 310 and 311 are shown two Meissner's corpuscles, giving the appearance presented by these end-organs when not stained with special reference to nerve terminations. For the latter see figure 137.

The Krause's end-bulbs, both spheric and cylindric, are, as a rule, situated a short distance below the papillary layer, although they are frequently found in the papillæ. They occur in man in the conjunctiva, lips, and external genitals, and in the mucous membranes previously mentioned (p. 170). See page 170 and figure 136 for their structure.

In the palm of the hand and sole of the foot, the subcutaneous connective tissue contains numerous Pacinian corpuscles. They occur also along the nerve-fibers of the joints and in the periosteum of the extremities.

Very recently Ruffini demonstrated in the human corium the existence of peculiar nerve end-organs, which consist of a connective-tissue framework supporting a rich arborization of telodendria. They occur side by side with the Pacinian corpuscles and in apparently equal numbers. These nerve terminations resemble in many respects the neurotendinous spindles (see Fig. 145), although they present certain structural differences. Instead of intrafusal tendon fasciculi, the Ruffini end-organ is composed of white fibrous and elastic tissue. In this end-organ the medullated nerves make long and tortuous turns before becoming nonmedullated, and the terminations of these nerve-fibers occupy the whole of the cross-section.

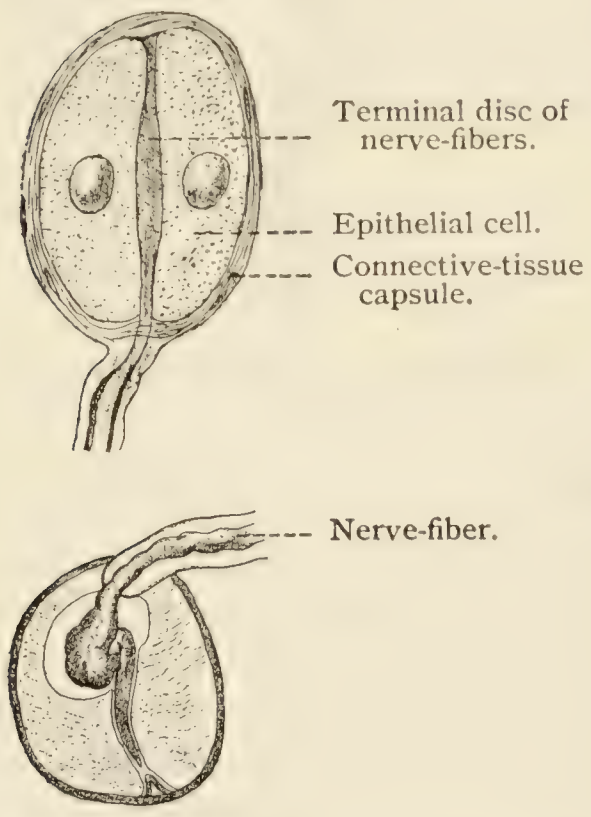

Fig. 312.—Grandry's corpuscles from bill of duck; × 500.

The Golgi-Mazzoni corpuscle resembles in structure the Pacinian corpuscle, although it possesses fewer lamellæ and a relatively larger core, and the nerve-fibers terminating therein are more extensively branched than in the Pacinian corpuscle. Ruffini has found these nerve-endings in the subcutaneous tissue of the finger-tips.

The blood-vessels of the skin are richly supplied with the vasomotor nerves, which terminate in the nonstriated muscle of the

vessel walls. These vasomotor nervé-fibers are neuraxes of sympathetic neurones.

In aquatic birds, and more especially in ducks, the waxy skin of the beak and the cornified portion of the tongue contain the so-called corpuscles of Herbst, which resemble the Pacinian corpuscles in general structure, but have cubical cells in the core. In the same tissues are also found the corpuscles of Grandry, 60 μ long and 40 μ broad. They consist of a thin connective-tissue capsule, containing two or three large cells. The nerve-fiber retains its medullary sheath for some distance within the capsule. The axis-cylinder ends in discs situated between the cells inclosed by the capsule.

B. THE HAIR.

The hair and nails are regarded as special differentiations of the skin. Hair is found distributed over almost the entire extent of the skin, varying, however, in quantity and arrangement in different regions. None whatever is present in the palm of the hand and sole of the foot. In the third fetal month small papillary elevations of the skin are seen to develop in those areas in which the hairy growth later appears. Under each of these elevations there occurs a proliferation of the cells of the Malpighian layer downward into the corium. Although the elevations soon disappear, the epithelial ingrowth continues and finally forms the *hair germ.* This is soon surrounded by a connective-tissue sheath from the corium, in which two layers may be distinguished. At the lower end of the hair germ the corium is pushed upward, forming a papilla which penetrates into the thickened bulb of the germ. This is called the *hair papilla.* In the mean time the hair germ itself is undergoing marked differentiation. An axial portion, forming later the hair and inner root-sheath, and a peripheral, constituting later the outer root-sheath, are developed. From the latter are derived also the first traces of the sebaceous glands, which in the adult state are in close relationship to the hair and empty their secretion into the space between the hair and its sheath. As soon as the various layers of the hair are complete it grows outward, breaking through the overlying layers of the epidermis.

The visible portion of the hair is called the *hair shaft,* and that portion below the skin is the *hair root.* The lower portion of the hair resting upon the papilla is known as the *hair bulb,* and the sheaths encircling the root and bulb are called the *root-sheaths,* the entire structure constituting the *hair follicle.*

The adult hair is covered by a thin *cuticle,* consisting of overlying plate-like cells, 1.1 μ thick, most of which possess no nuclei. Beneath the cuticle is the *cortical layer,* composed of several strata of long, flattened cells from 4.5 μ to 11 μ broad and provided with nuclei. These are also known as the cortical fibers of the hair. Upon treatment with ammonia the fibers separate into delicate

fibrils, the hair fibrils (Waldeyer, 82). Scattered between and within the cells of the cortical layer are varying quantities of pigment granules. The axial region of the hair is occupied by the *medullary substance*, from 16 μ to 20 μ in diameter. This may be lacking; but if present, consists of from 2 to 4 strata of polygonal, nucleated and pigmented cells. The hair shaft often contains air vesicles.

The *inner root-sheath* consists of three concentric layers—first, of an outer single layer of clear nonnucleated cells, the so-called

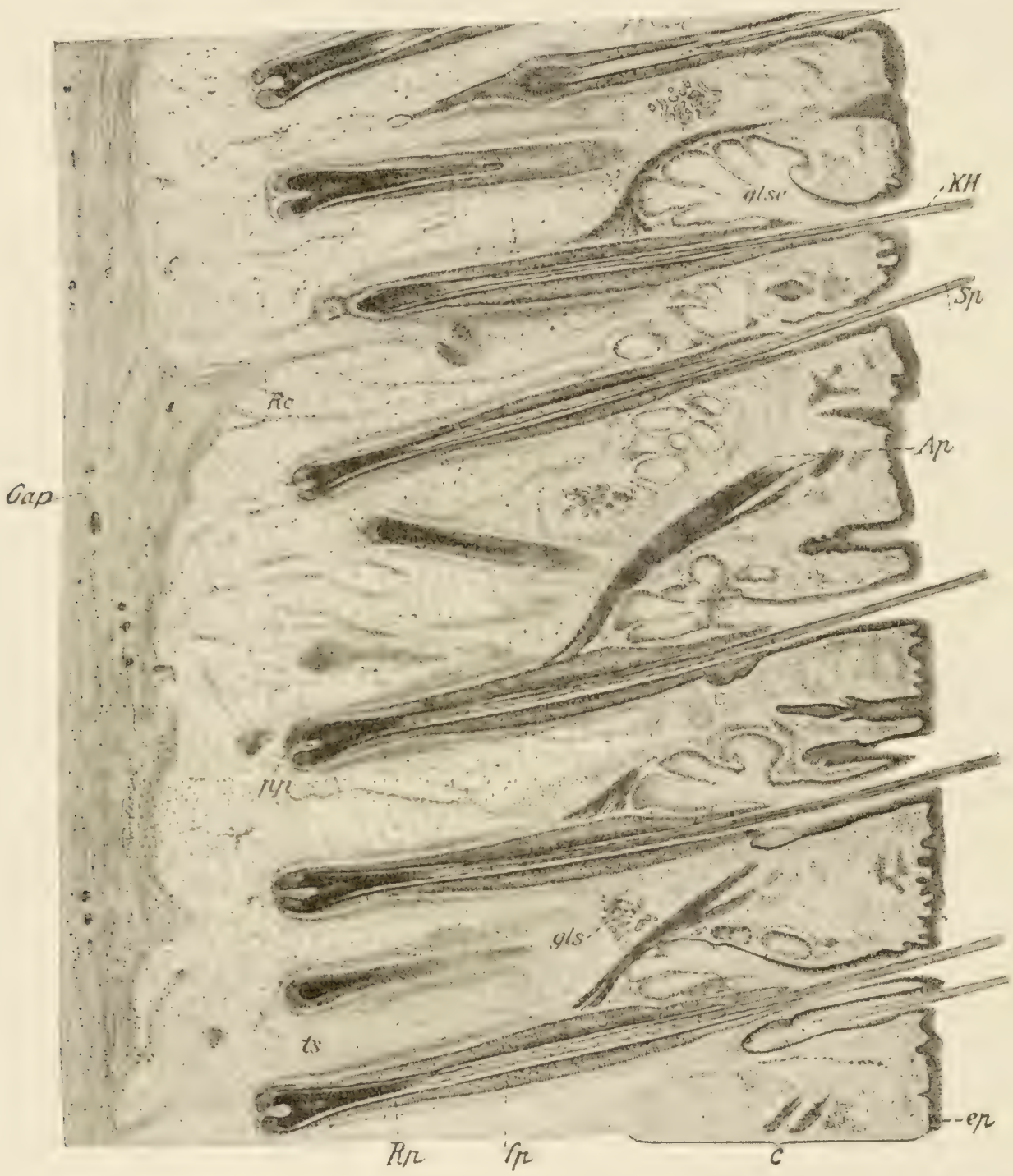

Fig. 313.—Transverse section of human scalp; × 12: *Ap*, Musculus arrector pili; *c*, corium; *ep*, epidermis; *fp*, hair follicle; *Gap*, aponeurosis; *gls*, sweat-gland; *glse*, sebaceous glands; *KH*, club-hair; *pp*, papilla of hair; *Rc*, retinacula cutis; *Rp*, root of hair; *Sp*, shaft of hair; *ts*, subcutaneous layer (Sobotta, "Atlas and Epitome of Histology").

layer of Henle; second, of a thicker middle layer, made up of a stratum of nucleated cells containing keratohyalin, the *layer of Huxley;* and, third, of an *inner cuticle*, bordering upon the hair.

The *outer root-sheath* is made up of elements from the stratum germinativum. Here we have to do with prickle cells, surrounded by an outer layer of columnar elements. The connective-tissue portion of the hair follicle is composed of an outer, looser layer of longitudinal fibrous bundles; of an inner, compacter layer of circu-

lar fibers; and of an innermost well-developed basement membrane—the *glassy membrane*.

At a certain distance above the root bulb all the layers of the

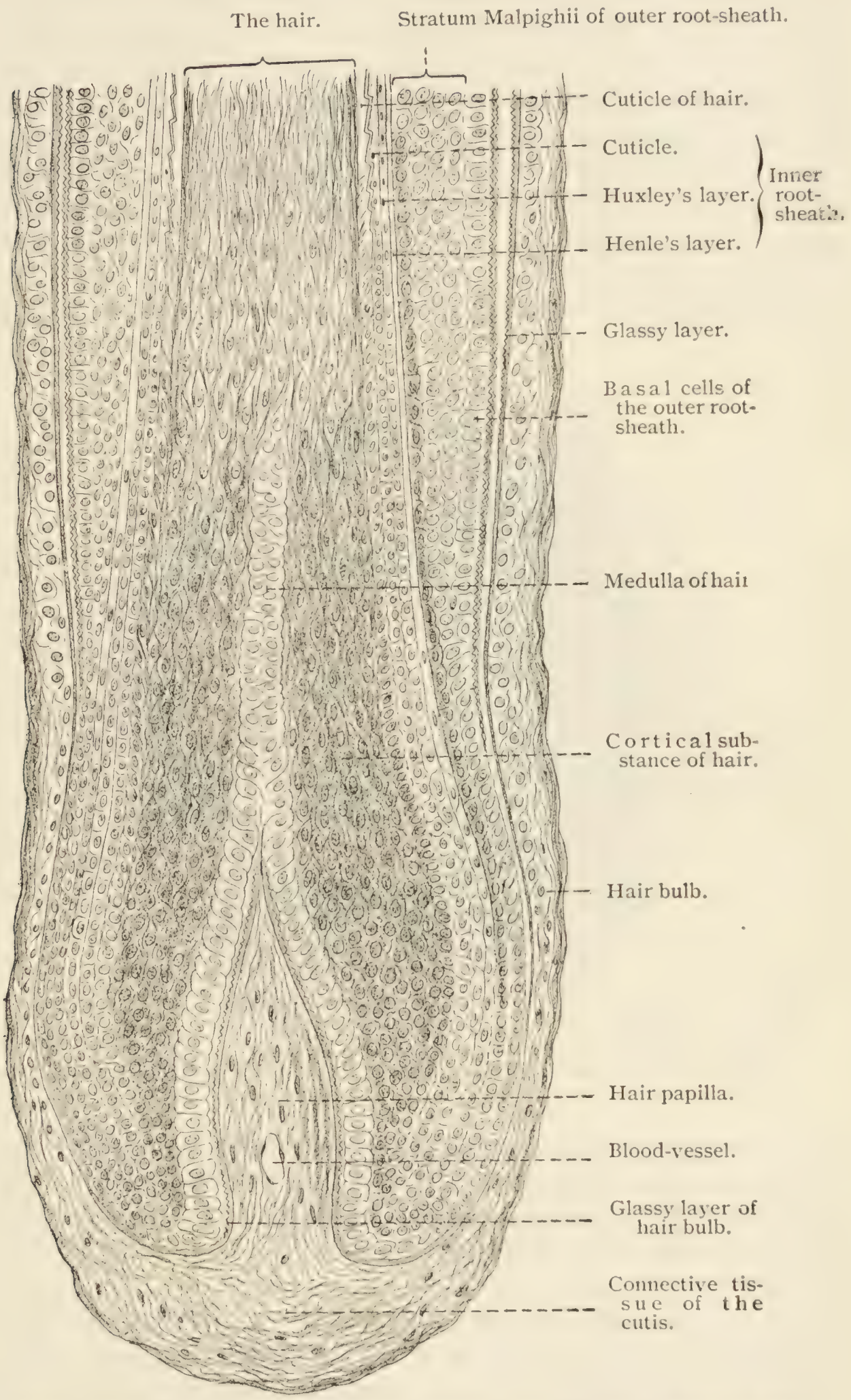

Fig. 314.—Longitudinal section of human hair and its follicle; × about 300.

epithelial portion of the hair follicle are well developed and distinct from each other. This condition changes toward the hair papilla

as well as toward the hair shaft. Below, in the region of the thickened hair bulb, the root-sheaths begin to lessen in thickness, their layers becoming more and more indistinct toward the base of the hair papilla. Finally, all differentiation is lost in the region where they encircle the neck of the papilla. Toward the shaft of the hair, the root-sheath also undergoes changes. In the region into which the sebaceous glands empty, the inner root-sheath disappears, while the outer becomes continuous with the stratum germinativum of the epidermis; the outer layers of the latter—the stratum granulosum, stratum lucidum, and stratum corneum—push downward between the outer root-sheath and the hair to the openings of the sebaceous glands.

Regarding the *growth of the hair*, two theories are prevalent.

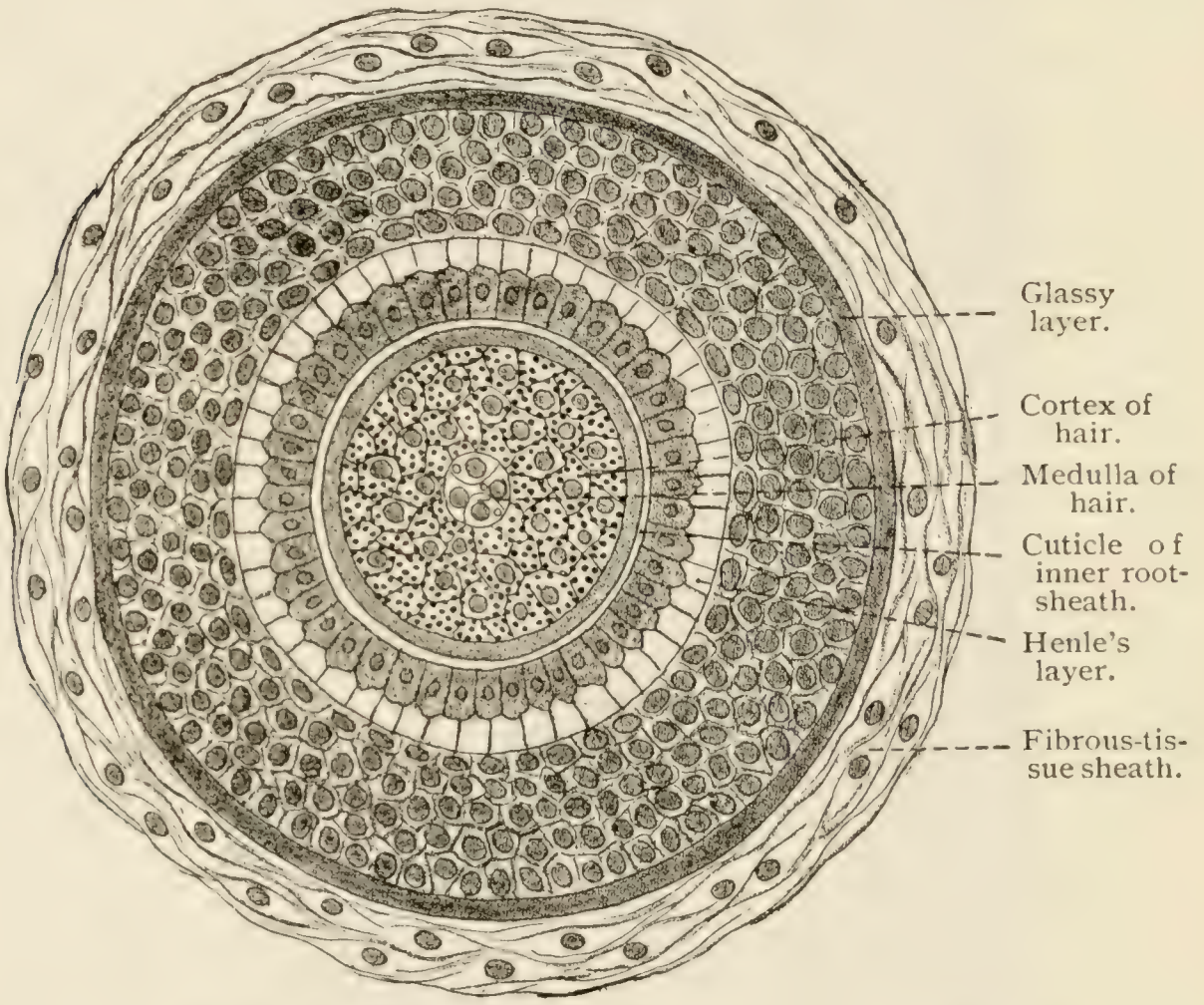

Fig. 315.—Cross-section of human hair with its follicle; × about 300.

The one theory assumes that the elements destined to form the epithelial root-sheaths are derived from the epidermis by a constant process of invagination. The component parts of the hair would thus be continuous with the layers of the root-sheaths, and consequently with those of the epidermis. Thus the basal cells of the external root-sheath would extend over the papilla, and be continuous with the cells of the medulla of the hair (these relations are especially well defined in the rabbit), and the stratum spinosum (middle layer of stratum Malpighii) of the outer root-sheath would be continuous with the cortical substance of the hair. According to this theory also, the layer of Henle would correspond to the stratum lucidum of the epidermis, and at the base of the hair

would become its cuticle, while the layer of Huxley would form the cuticle of the inner root-sheath (Mertsching). The other theory assumes that the hair is derived from a matrix, consisting of proliferating cells situated on the surface of the papilla. From these germinal cells would be derived the medullary and cortical substance of the hair, its cuticle, and the inner root-sheath (Unna).

The *shedding of hair* is common to all mammalia, a phenomenon occurring periodically in the majority of species. In man the process is continuous. Microscopic examination shows that the hair destined to be shed becomes loosened from its papilla by a cornification of the cells of its bulb. At the same time the cortical portion of the hair bulb breaks up into a brush-like mass. Such hairs are called *club hairs* or *bulb hairs,* in contradistinction to papillary hairs. In the region of the former papilla there arises, by a proliferation of the external root-sheath, a bud which grows downward, from which a new hair with its sheaths and connective-tissue papilla is developed. The result is that the developing new hair gradually pushes the old hair outward until the latter finally drops out. The exact details of this process have given rise to considerable discussion (*vid.* Götte and Stieda, 87).

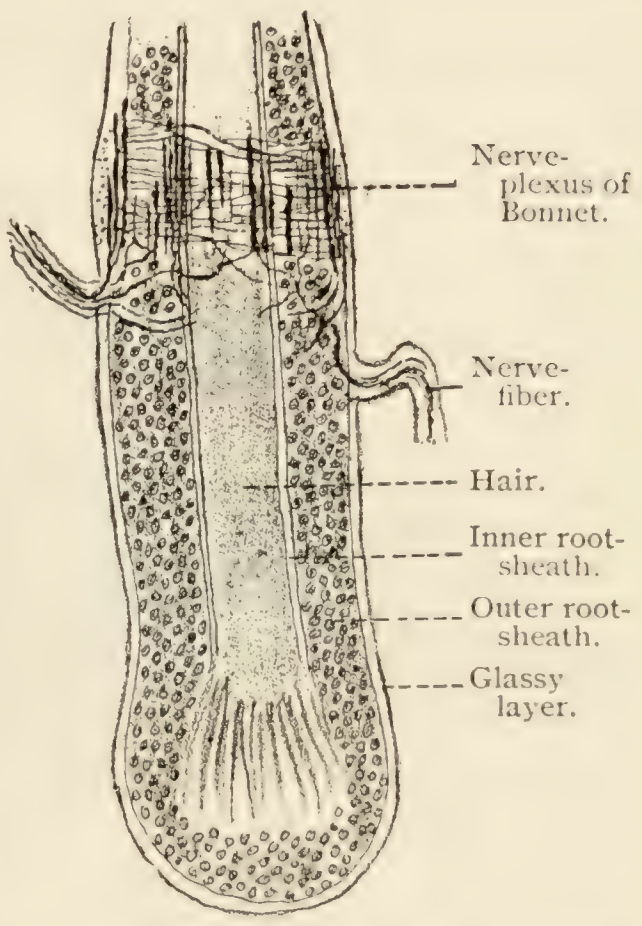

Fig. 316.—Longitudinal section through hair and hair follicle of cat; × 160.

Adjacent to the hair follicles are bundles of smooth muscle-fibers, known as the *arrectores pilorum.* They originate from the papillary layer of the corium and extend to the lower part of the connective-tissue sheath of the hair follicles. In their course they not infrequently encircle the sebaceous glands of the follicle. Since the hair follicles have a direction oblique to the skin surface, forming with it an acute and an obtuse angle, and since the muscle is situated within the obtuse angle, its function may easily be conceived as being that of an erector of the hair. The hair papillæ are very vascular.

The *nerve-fibers* of the hair follicles have recently been studied by a number of investigators, with both the Golgi and the methylene-blue methods. It has been shown that the hair follicles receive their nerve supply from the nerve-fibers which terminate in the immediate skin area. Each follicle receives, as a rule, only one nerve-fiber, which reaches the follicle a short distance below the mouth of the sebaceous gland. The nerve-fiber, on reaching the

follicle, loses its medullary sheath and divides into two branches, which surround it in the form of a ring. From this complete or partial ring of nerve-fibers numerous varicose fibers proceed upward parallel to the axis of the follicle for a distance about equal to the cross-diameter of the follicle, to terminate, it would seem, largely outside of the glassy layer (Retzius). In certain mammalia the nerve-fibers end in tactile discs, found in the external root-sheaths of the so-called tactile hairs. The muscles of the hairs receive their innervation through the neuraxes of sympathetic neurones, which reach the periphery from the chain ganglia through the gray rami communicantes. These nerves are known as *pilomotor nerves*, and when stimulated, excite contraction of the erector muscles of the hairs, causing these to assume an upright position and producing the appearance termed goose skin, or cutis anserina. Langley and Sherrington have made interesting and important observations on the course and distribution of the pilomotor nerves.

C. THE NAILS.

The nails are a peculiar modification of the epidermis. The external arched portion is called the *body of the nail;* that area upon

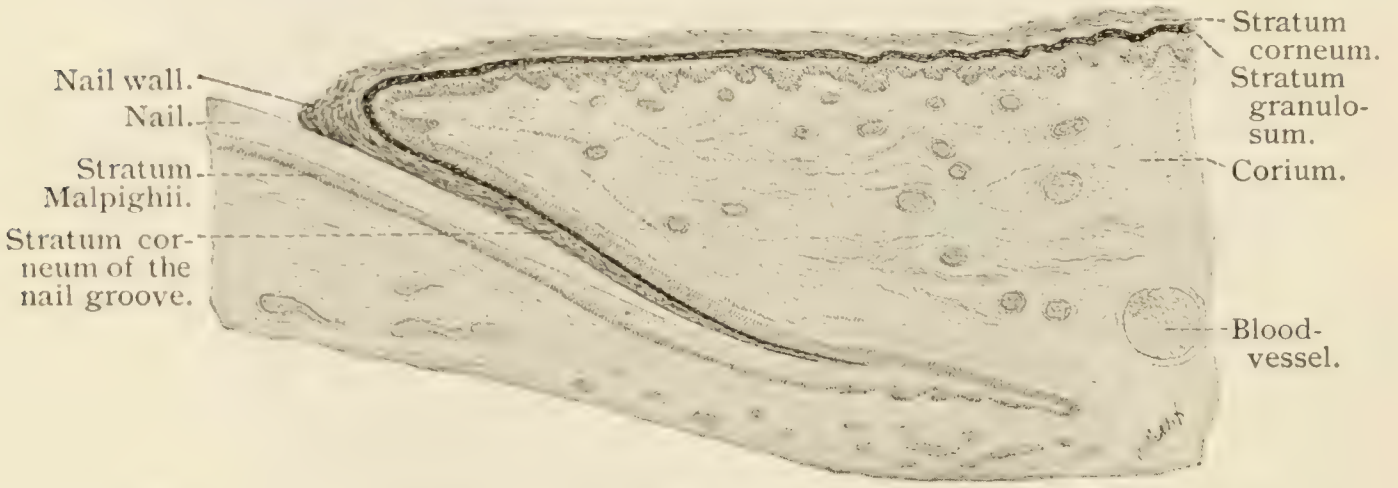

Fig. 317.—Longitudinal section through human nail and its nail groove (sulcus) ; × 34.

which the latter rests, the *nail bed*, or *matrix;* and the two folds of epidermis which overlap the nail, the *nail walls*. The groove which exists between the nail wall and nail bed is known as the *sulcus of the matrix*, and the proximal imbedded portion of the nail as the *nail root*, since all growth of the nail takes place in this region. The nail bed consists of the corium, which is here made up of a dense felt-work of coarse connective-tissue fibers. Immediately beneath the nail the corium is raised into a number of more or less symmetric longitudinal ridges, which again become continuous with the connective-tissue papillæ of the skin at the line where the nail projects beyond its bed.

The depressions between the ridges are occupied by epidermal cells, which also form a thin covering over the ridges themselves.

These cells correspond here to the basilar layer of the stratum Malpighii. The stratum granulosum is not uniformly present, although occurring as isolated areas in the region of the nail root and *lunula*, the white area of demilunar shape at the proximal portion of the nail. Unna has demonstrated that the pale color of the lunula and root of the nail is due to the presence of keratohyalin. Formerly, this peculiarity was attributed to a difference in the distribution of the vessels in the various portions of the nail bed. The body of the nail, with the exception of the lunula, is transparent—a condition which may be explained by the fact that the elements of the nail correspond to those of the stratum lucidum. As a consequence, the vessels of the matrix shine through, except at the lunula, where the keratohyalin granules render the nail opaque.

The nail itself consists of elements homologous to those of the stratum lucidum. They are flat, transparent cells, closely approximated, and all contain nuclei. The cells overlie each other like tiles, and are so arranged that each succeeding lower layer projects

Fig. 318.—Transverse section through human nail and its sulcus; × 34.

a little further distalward than the preceding. At the period when the nails are formed, about the fourth month of fetal life, sulci are already present. The first trace of the nail is seen as a marked thickening of the stratum lucidum in the region which later becomes the body of the nail; in this stage the structure is still covered by the remaining layers of the stratum corneum, constituting the *eponychium*. The embryonal nail then spreads in all directions until it finally reaches the sulcus. Henceforward the growth is uniform. The eleidin normally present in the stratum lucidum of the skin also occurs in the nail, and is derived, as we have already seen, from the keratohyalin. It may readily be conceived that later, when growth is confined to the root of the nail, keratohyalin is also present. As soon as the nail begins to grow forward, in the ninth month, the greater part of the eponychium is thrown off; but during the entire extrauterine life, a portion of the eponychium is retained at the nail wall, and as hyponychium on the anterior and under surface of the nail.

D. THE GLANDS OF THE SKIN.

The glands in the skin are of two kinds—sweat-glands and sebaceous glands. In this connection we may also consider the mammary glands, which may be regarded as a modified skin gland.

1. The Sweat-glands. — The sweat-glands, or sudoriparous

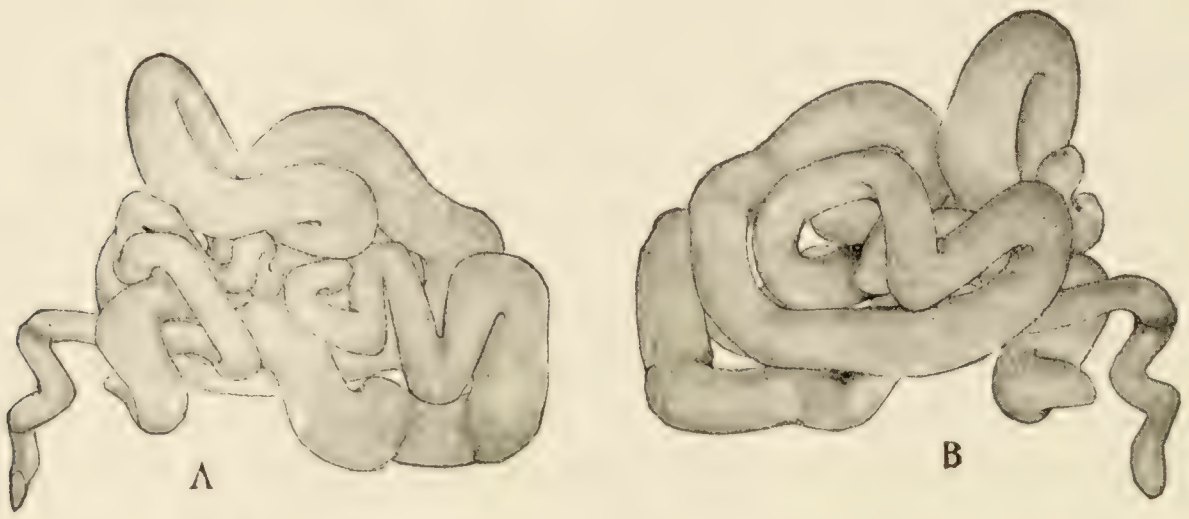

Fig. 319. — A, B, Two views of a model of the coiled portion of a sweat-gland from the plantar region of a man, reconstructed by Born's wax-plate method; × 100 (Huber-Adamson).

glands, are distributed throughout the entire skin, but are especially numerous in certain regions—as, for instance, the axilla, palm of the hand, and sole of the foot. They lie imbedded either in the adipose tissue of the true skin, or still deeper in the subcutaneous connective tissue.

The sweat-glands are simple tubular in type, and their secreting portion is coiled; hence the name *coil-glands*. The coiled portion of these glands measures 0.3 to 0.4 mm. The excretory duct is nearly straight in its course through the corium. From here on its course is spiral, and it should be borne in mind that in its passage through the epidermis it has no other wall than the epidermal cells of the various layers through which it passes, although these cells are arranged concentrically around the lumen of the duct. The duct takes part in the formation of the coiled portion of the gland, forming about one-fourth of the length of the tubule which takes part in the formation

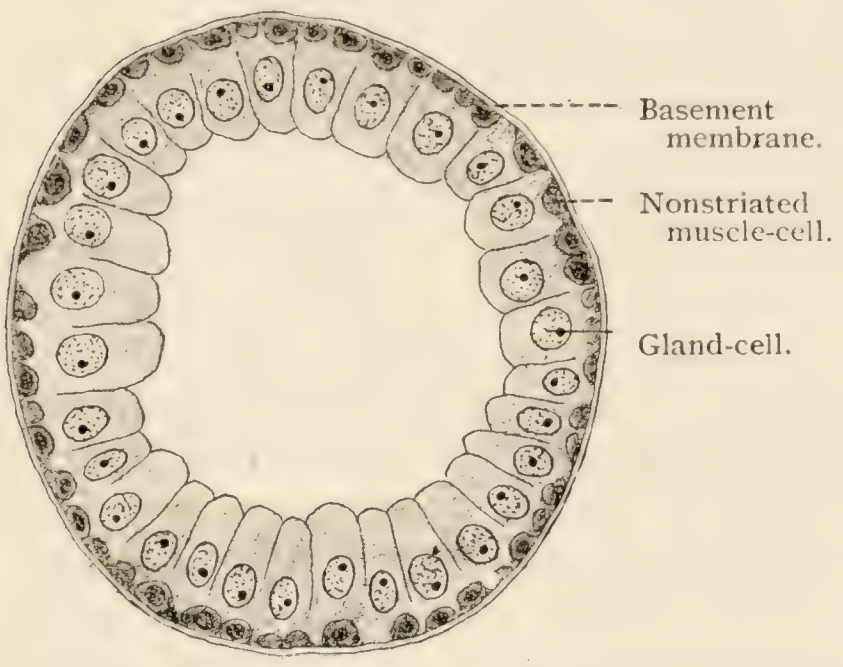

Fig. 320. — Cross-section of tubule of coiled portion of sweat-gland of human axilla. Fixation with sublimate; × 600.

of the coil. In figure 319 are shown two views of a model of the coiled portion of a sweat-gland from the plantar region of the foot of a man. The length of the tubule in the coiled portion of this gland measures 4.25 mm., of which 1.25 mm. fall to the excretory duct and 3.0 mm. to the secretory tubule.

The blind end of the secreting portion of the tubule and the excretory duct as it enters the coil are usually in close proximity. The secretory portion of the tubule of sweat-glands is lined by a single layer of cubic or columnar cells, with finely granular protoplasm and round or oval nuclei possessing one or two nucleoli. Between this layer of cells and the basement membrane there is found a layer of nonstriated muscle-cells, longitudinally disposed. The portion of the excretory duct found within the coil of the glands is lined by a single layer of short cubic cells, with cuticular border, outside of which there is a delicate basement membrane. The muscular layer is lacking in this and the remaining portion of the duct. The excretory portion of the duct passing through the corium is lined by short, somewhat irregularly cubic cells arranged in two layers.

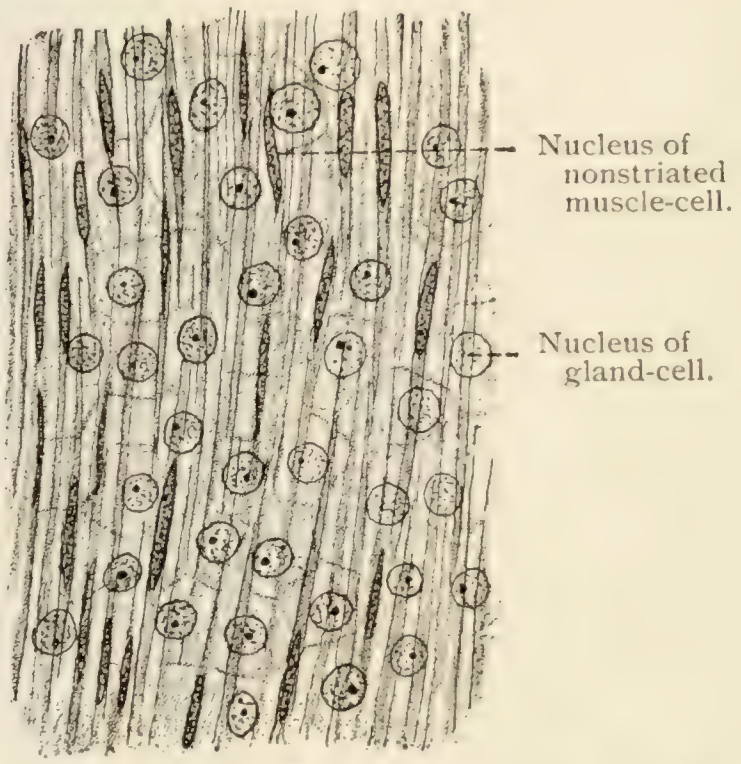

Fig. 321.—Tangential section through coiled portion of sweat-gland from human axilla. Sublimate fixation; × 700.

Capillary networks surround the secreting portions of the sweat-glands.

The nerves of the sweat-glands have been studied with the aid of the methylene-blue method by Ostroumow, working under Arnstein's direction. These glands receive their innervation through the neuraxes of sympathetic neurones, the terminal branches of which form an intricate network just outside of the basement membrane, known as the *epilamellar plexus*. From this plexus fine varicose nerve-fibers pass through the basement membrane, and, after coursing a shorter or longer distance with or without further division, end on the gland-cells, often in clusters of small terminal granules united by delicate threads.

The development of the sweat-glands begins in the fifth month of fetal life. At first solid cords grow from the stratum germinativum of the epidermis into the corium. Later, in the seventh month, these become hollow.

Joseph has shown a structural change in the secretory cells of the sweat-glands when perspiration was induced by electrical stimulation or by drugs.

With the sweat-glands as here described, and which have, as

has been stated, a very wide distribution, we may also class certain skin glands, grouped under the term of "modified sweat-glands," which show certain structural and morphologic peculiarities and are found in special regions of the body. To these belong the axillary glands, the circumanal glands, the ciliary glands or glands of Moll of the eyelid, and the ceruminous glands of the external auditory canal. The axillary glands resemble the sweat-glands in shape and structure, possessing, however, larger and longer tubules. The coiled portions of these glands measure 1.5 to 2 mm., the tubule of the coil attaining a length of 30 mm. In the circumanal region are found several types of sweat-glands, especially in an area having the form of an elliptical ring with a width of about 1.5 cm. and situated about 1.5 cm. from the anus. In this region there

Fig. 322.—Model of a sebaceous gland with a portion of the hair follicle, reconstructed by Born's wax-plate method. A, Hair follicle.

are found large sweat-glands, known as the circumanal glands of Gay; branched sweat-glands of the type of tubulo-alveolar glands; sweat-glands with relatively straight ducts, ending in a relatively large saccule or vesicle, from which arise secondary tubules or alveoli; and, finally, sweat-glands of the type as found in other regions of the body. The ciliary glands or glands of Moll may also be classed as branched glands of the type of tubulo-alveolar glands, with relatively large vesicles. The ceruminous glands are branched tubulo-alveolar glands.

2. The Sebaceous Glands.—The distribution of the sebaceous glands in the skin is closely connected with that of the hair follicles into which they pour their contents. Exceptions to this rule occur

in only a few regions of the body, as, for instance, in the glans penis and foreskin (Tyson's glands), in the labia minora, angle of the mouth, glandulæ tarsales, and the Meibomian glands of the eyelids, etc. As a rule the sebaceous gland empties by a wide excretory duct into the upper third of the hair follicle. The walls of the duct also produce secretion, and can therefore hardly be differentiated from the rest of the gland. At its base the duct widens and is provided with a number of simple or branched alveoli. The sebaceous glands are therefore of the type of simple branched alveolar glands, varying in length from 0.2 mm. to 0.5 mm. They are surrounded by connective-tissue sheaths, which at the same time cover the hair follicles. Inside of the sheath is the membrana propria, which is a continuation of the glassy membrane of the follicle. The two or three basal strata of glandular cells must be regarded as a direct continuation of the elements of the external root-sheath. In the

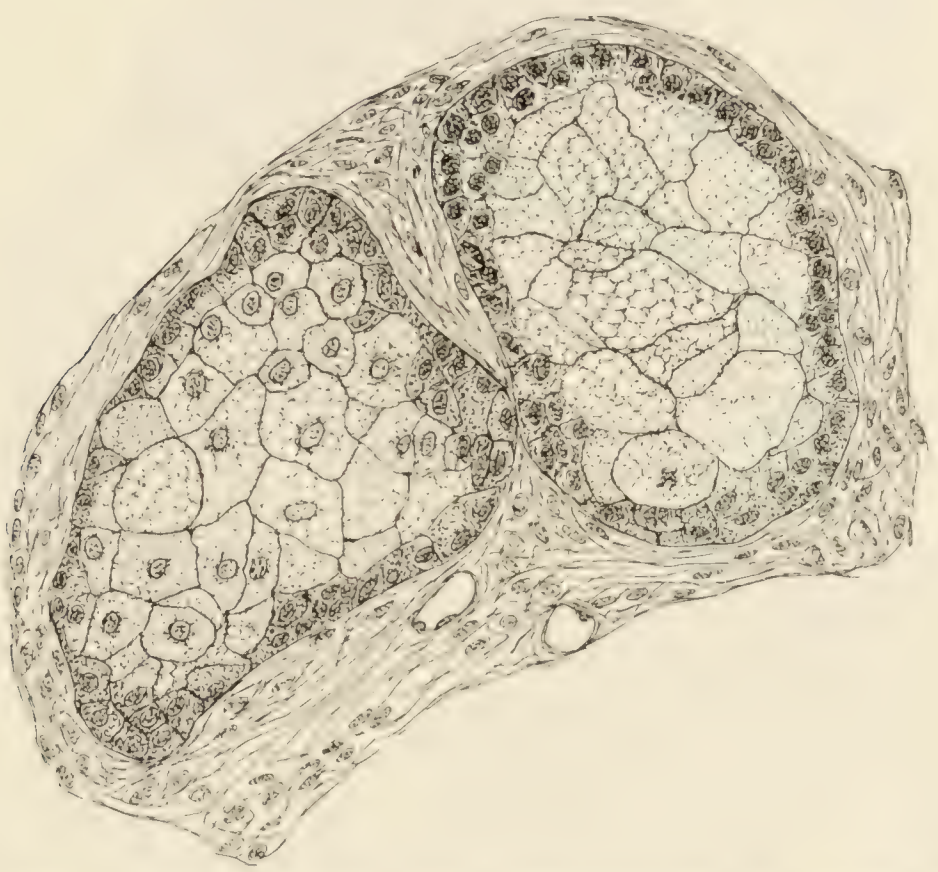

Fig. 323.—Section of alveoli from sebaceous gland of human scalp.

more centrally placed strata the cells are distinctly changed in character; their contents consist of fat globules, varying in size and distributed throughout the protoplasm, giving this a reticular appearance, while the nuclei suffer compression from the accumulation of the fat globules and gradually become smaller and more angular. Finally, the cells change directly into secretion, which is then poured into the hair follicle as sebum. It is thus seen that in the secretion of sebum the cells are consumed and must be replaced. This renewal takes place by the constant proliferation of the basilar cells, which push the remains of the secreting cells upward and finally take their places. The final disintegration of the cells occurs either within the gland itself or between the hair follicle

and the hair. The secretion contains fatty globules of varying size, which occur either free or attached to cellular detritus.

3. The Mammary Glands.—The mammary glands are also included among the cutaneous glandular structures. They are developed early, but not until the fifth month is it possible to distinguish a solid central portion, with radially arranged tubules terminating in dilatations. The structures are all derived from the basal layers of the epidermis. From birth to the age of puberty

Fig. 324. — Model of a small portion of a secreting mammary gland ; × 200.
(Maziarski, *Anatomische Hefte*, vol. XVIII.)

the organs are in a state of constant growth, and are early surrounded by a connective-tissue sheath. The alveoli, which have been developed in the mean time, are still solid and relatively small. Up to the twelfth year the glands remain identical in structure in boys and girls. In the female the mammary glands continue to develop from the age of puberty ; in the male, on the other hand, they undergo a retrograde metamorphosis, ending, finally, in the atrophy of all except the excretory ducts. The mammary glands do not attain their full stage of development in women until the last months of pregnancy, and are functionally active at parturition.

The human mammary gland when fully developed has the following structure : It consists of about twenty lobes, separated from each other by connective-tissue septa. These lobes are again divided into a larger number of lobules, and these in turn are composed of numerous irregularly round or oval or even tubular alveoli. The alveoli are provided with small excretory passages, which unite to form the smaller ducts, these in turn uniting to form the larger ducts. Shortly before terminating at the surface of the mammilla, each mammary duct widens into a vesicle, the *sinus lactiferus*. The number of excretory ducts corresponds to that of the larger lobes. The ducts are lined by simple cubical epithe-

lium, except near their termination in the nipple, where they are lined by stratified pavement epithelium, and surrounded by a fibrous tissue sheath.

The epithelium of the alveoli differs according to the state of functional activity. In a state of rest it consists of a single layer of glandular cells of nearly cubical shape which stain deeply, the internal surfaces now and then projecting slightly into the lumen. At the beginning of secretion fat globules make their appearance in the distal ends of the cells. At the same time a corresponding

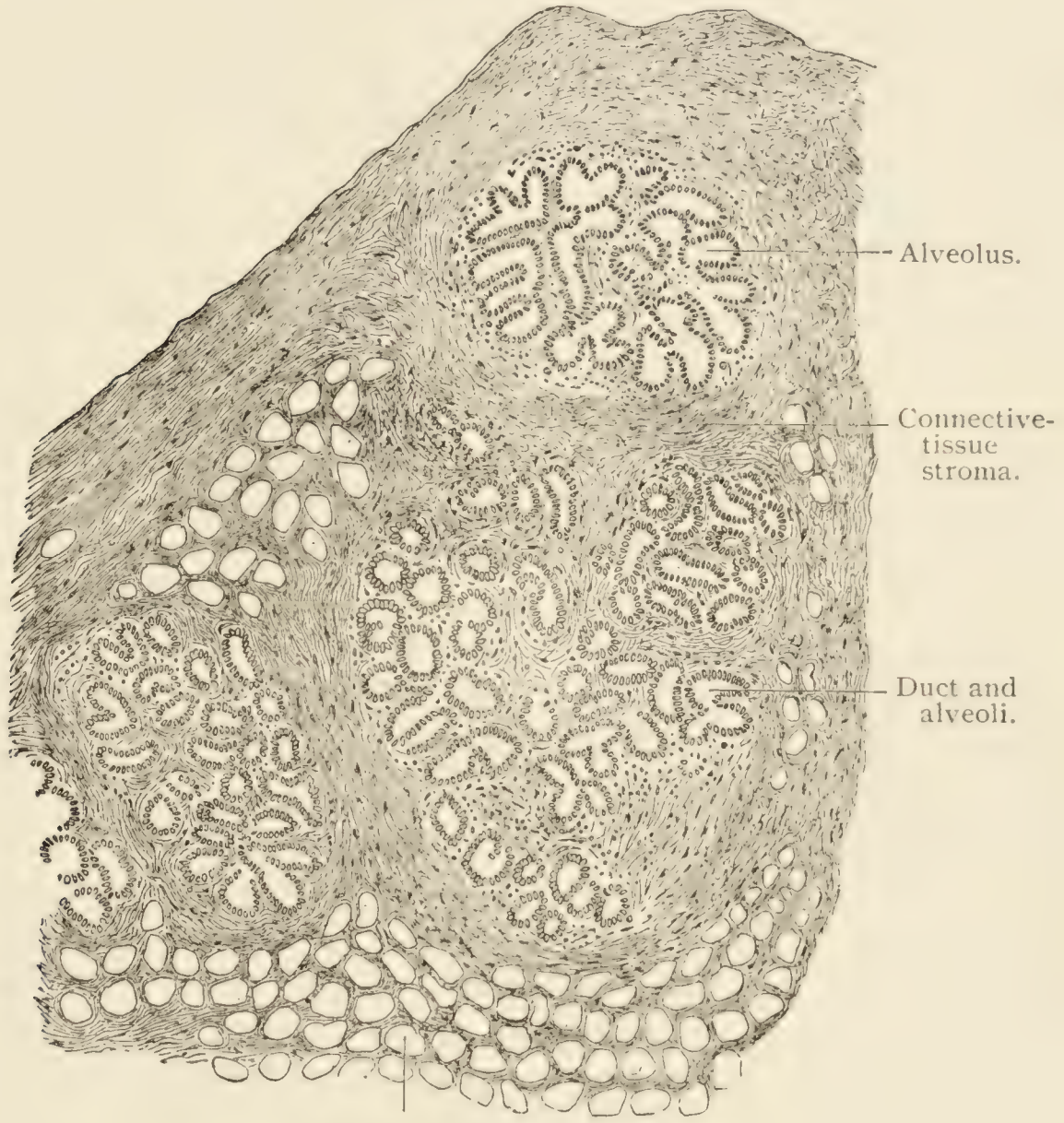

Fig. 325.—From section of mammary gland of nullipara. (From Nagel's "Die weiblichen Geschlechtsorgane," in "Handbuch der Anatomie des Menschen," 1896.)

increase in size occurs throughout the entire alveolus. There are as yet current two quite contradictory views as to the manner in which the milk is secreted. According to certain observers, the free ends of the cells, which contain the most fat globules, are constricted off, after which the fat globules are freed in the lumen. The secretory portion of the alveolus is then composed of low epithelial cells, in which the process begins anew. The process of milk secretion therefore consists in throwing off the inner halves of the cells containing the fat globules, and in regeneration of the cells from the

nucleated remains of the glandular epithelium. Whether a karyokinetic division of the nuclei occurs in this process is not known, and how often the process of regeneration may be repeated in a single cell is not capable of demonstration. It is certain, however, that entire cells are destroyed, to be replaced later by new elements. Other observers regard the secretion of milk as occurring without a partial or total destruction of the secretory cells, but after the manner of the secretion of other glands. This latter view seems more in accord with the more recent observations. The membrana propria of the alveoli appears homogeneous. Between it and the glandular cells are so-called basket cells, similar to those in the salivary glands. Benda regards the basket cells as nonstriated muscle elements having a longitudinal direction, making the structure of the alveoli of the mammary gland similar in this respect to that of the secreting portion of the sweat-glands.

The skin of the mammilla is pigmented, and the papillæ of its corium are very narrow and long. In the corium are also found large numbers of smooth muscle-fibers, which form circular bundles around the excretory ducts. In the areolæ of the mammæ are the so-called *glands of Montgomery*, which very probably represent accessory mammary glands. These are especially noticeable during lactation. The blood-vessels of the mammary gland, the larger branches of which are situated mainly in the subcutaneous tissue, form rich capillary networks about the alveoli.

The mammary glands possess many lymphatics. These are especially numerous in the connective-tissue stroma between the lobules. The lymph-vessels collect to form two or three larger vessels, which empty into the axillary glands. The mammary gland receives its nerve supply from the sympathetic and cerebrospinal nervous systems through the fourth, fifth, and sixth intercostal nerves. The terminations of the nerves in the mammary gland have been studied by means of the methylene-blue method by Dmitrewsky, working in the Arnstein laboratory, who finds that the terminal branches form epilamellar plexuses outside of the basement membrane of the alveoli, from which fine nerve branches pass through the basement membrane and end on the gland cells in clusters of terminal granules united by fine filaments. The nipple has a rich sensory nerve supply. In the connective-tissue papillæ are found tactile corpuscles of Meissner.

The *milk* consists of fat globules of varying size, which, however, do not coalesce—an attribute due to the presence of albuminous haptogenic membranes surrounding the globules. Shortly before, and for some days after, parturition the milk contains true nucleated cells in which are fat globules; these are known as the *colostrum corpuscles*. They probably represent leucocytes which have migrated into the lumen of the gland and have taken up the fat globules of the milk. This milk is known as *colostrum*.

TECHNIC.

287. Good general views of the skin can be obtained only from sections. Any fixation method may be employed, although alcohol is preferable on account of the better subsequent staining. For detail work Flemming's solution, corrosive sublimate, or osmic acid is the best. Sectioning of the skin is attended with many difficulties, and large pieces can be cut only in celloidin. Small and medium-sized pieces may be cut in paraffin; but even in this case the skin must be rapidly imbedded in the paraffin—*i. e.*, it must not remain too long in either alcohol or toluol—and the paraffin must have only the consistency necessary to cut well (about 50° C. melting-point). In order to obtain good paraffin sections of the skin the following procedure is recommended: Pieces fixed in Flemming's solution or osmic acid are kept in 96% alcohol, then placed for not more than twenty-four hours in absolute alcohol and imbedded in paraffin by means of the chloroform method. In the chloroform, chloroform-paraffin, and pure paraffin they remain for one hour each. The paraffin used should consist of two parts paraffin of 42° C., and one part paraffin of 50° C. melting-point. The thermostat must be kept at 50° C. (R. Barlow). The sections should not be mounted by the water-albumen method.

In sections of epidermis which have been freshly fixed with osmic acid, the stratum corneum may be clearly differentiated into three layers (probably because of the defective penetration of the reagent)—into a blackened superficial, a middle transparent, and a still lower black layer (*vid.* Fig. 326).

In tissue fixed in alcohol or corrosive sublimate the stratum lucidum stains yellow with picrocarmin, but is very weakly colored by basic anilin stains. In unstained preparations the stratum lucidum is glass-like and transparent. Eleidin is diffusely scattered throughout both the stratum lucidum and stratum corneum. Like keratohyalin, it stains with osmic acid and also with picrocarmin, but not with hematoxylin. Nigrosin stains eleidin, but not keratohyalin.

Keratohyalin is insoluble in boiling water and is not attacked by weak organic acids. It dissolves, however, in boiling acetic acid, but is not changed by the action of pepsin or trypsin. The keratohyalin granules of the stratum granulosum swell in from 1% to 5% potassium-hydrate solution; under the influence of heat these granules together with the cells containing them are finally dissolved. They are not attacked by ammonia, and remain unaffected for a long time in strong acetic acid. As ammonia and acetic acid render the remaining portions of the tissue transparent, these reagents may be employed for the rapid identification of keratohyalin. The larger flakes of keratohyalin swell in sodium carbonate solution (1%), but not the smaller granules, and it would seem that the larger granules have less power of resistance than the smaller. Keratohyalin remains unchanged in alcohol, chloroform, and ether, but is digested in trypsin and pepsin (not, however, the keratin). Keratohyalin can be stained with hematoxylin and most of the basic anilin dyes.

The prickles of the cells composing the stratum Malpighii may be seen in very thin sections (not over 3 μ in thickness) of skin previously fixed in osmic acid. In this case it is best to employ not Canada balsam, but glycerin, which does not have so strong a clearing action. Isolation of the prickle cells is best accomplished as follows (Schieffer-

decker): A fresh piece of epidermis is macerated for a few hours in filtered, cold-saturated, aqueous solution of dry pancreatin; the whole may then be preserved for any length of time in equal parts of glycerin,

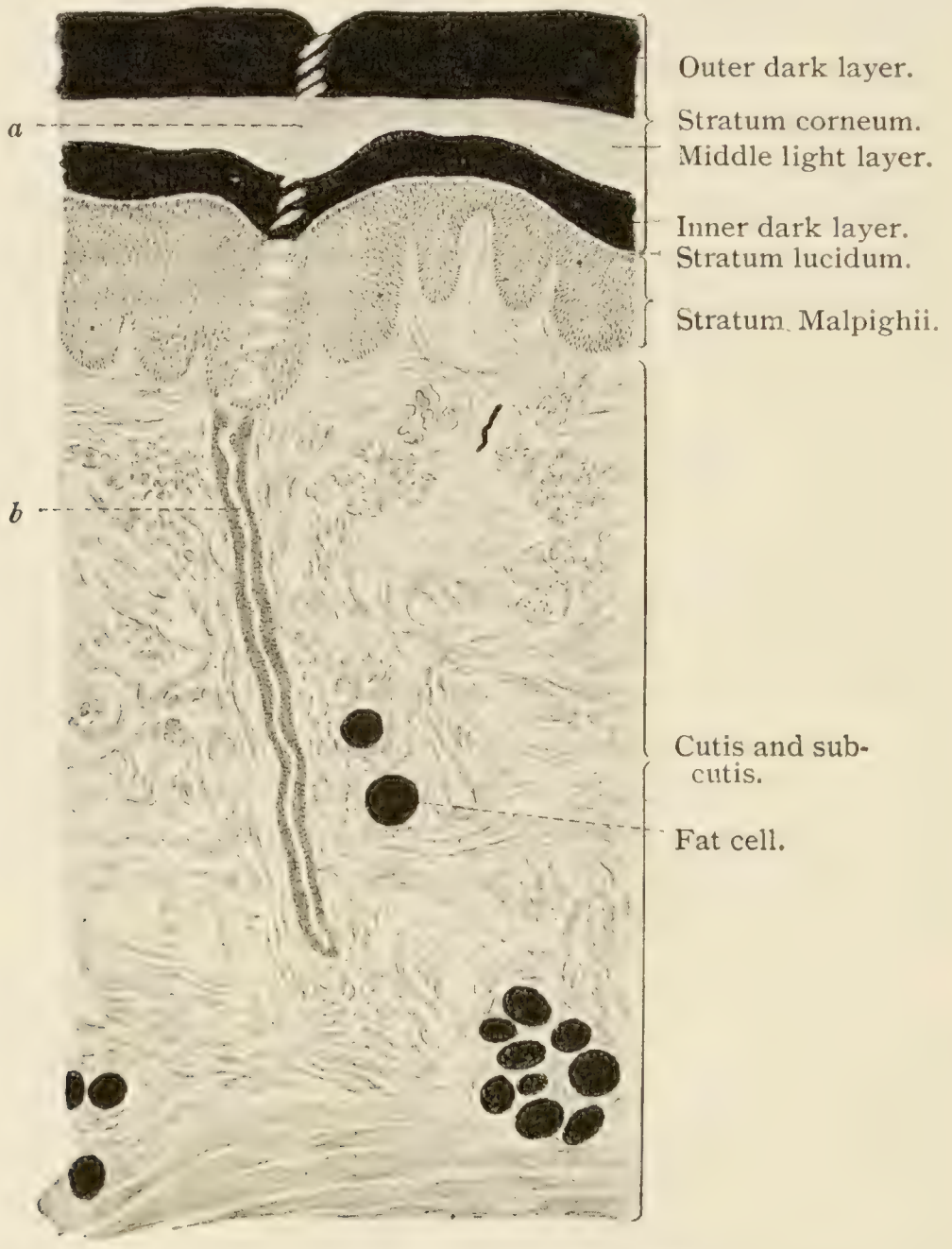

Fig. 326.—Transverse section through the human skin. Treated with osmic acid; × 30: *a*, Part of the tortuous duct of a sweat-gland in the epidermis; *b*, duct of same sweat-gland in the corium.

water, and alcohol. Small pieces taken from such specimens are readily teased and show both isolated and small groups of attached prickle cells.

The distribution of the pigment in the skin is best studied in unstained sections. With a nearly closed diaphragm and under medium magnification the pigment granules appear darker on raising the tube and lighter upon lowering it.

In sections of skin treated with Flemming's fluid, the structure of the cutis also may be studied. The medullary sheaths of the nerve-fibers and the fat appear black. In preparations stained with safranin the elastic fibers are colored red and are very distinct (Stöhr and O. Schultze). For the orcein method according to Unna, see p. 128.

Hair may be examined in water without further manipulation. The cuticle is then seen to consist of polygonal areas, the border-lines of which correspond to the limits of the flattened cells. By slightly lowering the objective the cortical substance comes into view with its indistinct

striation and occasional pigmentation. The medullary substance, if present, may also be seen with its vesicles containing air. Both the cortical and cuticular cells may be isolated, the process consisting in treating the hairs for several days with 33 % potassium hydrate solution at room temperature, or in heating the whole for a few minutes. Concentrated or weak sulphuric acid produces the same result. On warming a hair in sulphuric acid until it begins to curl and then examining it in water, we find that the cortical and medullary layers as well as the cuticle are separated into their elements. Treatment of the skin with Müller's fluid, alcohol, or sublimate is recommended for the examination of hair and hair follicles. The orientation of the specimen should be very precise, in order to obtain exact longitudinal or cross-sections of the hair. There is hardly a structure of the body which is more suitable for staining with the numerous coal-tar colors than the hair and its follicle (Merkel).

The corpuscles of Meissner may be best obtained from the end of the finger. After boiling a piece of fresh skin from the finger-tip for about a quarter of an hour, the epidermis may be easily removed; the papillæ are now seen on the free surface of the cutis. A portion of the latter is cut away with a razor and examined in a 3% solution of acetic acid. The corpuscles are readily distinguished. Their relations to the nerves should be studied in specimens fixed with osmic acid or gold chlorid. The terminations of the nerves in these end-organs are best seen in preparations stained after the *intra vitam* methylene-blue method.

The corpuscles of Herbst and Grandry are found in the waxy skin covering the bill, and in the palate of the duck (especially numerous in the tongue of the woodpecker). For the study of the nervous elements the following method is useful: Pieces of the waxy skin are removed with a razor and placed for twenty minutes in 50% formic acid. After washing the specimens for a short time in distilled water they are transferred to a small quantity of 1% gold chlorid solution (twenty minutes), then again rinsed in distilled water, and placed for from twenty-four to thirty-six hours in the dark in a large quantity (⅓ liter) of Pichard's solution (amyl alcohol 1 part, formic acid 1 part, water 100 parts). After again washing in water the specimens are transferred to alcohols of gradually increasing strengths and finally imbedded in celloidin or celloidin-paraffin.

297. The Pacinian corpuscles occur in the mesentery of the cat and may be examined in physiologic saline solution.

The nerves of the epidermis are demonstrated by the gold-chlorid method (see p. 48). But even here the chrome-silver method and the *intra vitam* methylene-blue method yield extremely good results, and may be used with great advantage in the study of the nerves in the cutis.

The so-called tactile menisci are very numerous in the snout of the pig and the mole. Bonnet recommends for these structures fixation in 0.33% chromic acid solution, overstaining with hematoxylin, and differentiation in an alcoholic solution of potassium ferricyanid.

VII. THE CENTRAL NERVOUS SYSTEM.

In a study of the minute anatomy of the central nervous system consideration should be given to the arrangement of the nerve-cells and nerve-fibers in the various regions, and to the mutual relations which the elements of the nervous system bear to one another. In a text-book of this scope, however, we shall be unable to enter into the consideration of these subjects in detail, but must content ourselves with a very general discussion of the structure of certain regions of the central nervous system and an account of a few typical examples illustrating the mutual relationship of the nerve-elements to one another. We shall, therefore, give a general description of the structure of the spinal cord, cerebellum, cerebrum, olfactory lobes, and ganglia. In this description we have drawn freely from the results of the researches of Golgi (94), Ramôn y Cajal (93, 1), von Lenhossék (95), Kölliker (93), and van Gehuchten (96).

A. THE SPINAL CORD.

The spinal cord extends from the upper border of the atlas to about the lower border of the first lumbar vertebra. It has the form of a cylindric column, which at its lower end becomes quite abruptly smaller, to form the *conus medullaris*, and terminates in an attenuated portion—the *filum terminale*. It presents two fusiform enlargements, known as the cervical and lumbar enlargements respectively. The spinal cord is partly divided into two symmetric halves by an *anterior median fissure* and by a septum of connective tissue, extending into the substance of the cord from the pia mater (one of the fibrous tissue membranes surrounding the cord), and known as the *posterior median septum*. Structurally considered, the spinal cord consists of white matter (mainly medullated nerve-fibers) and gray matter (mainly nerve-cells and medullated nerve-fibers). The white and the gray matter present essentially the same general features at all levels of the spinal cord, although the relative proportion of the two substances varies somewhat at different levels. The different portions of the cord present also certain structural peculiarities.

The distribution of the gray and the white substances of the spinal cord is best seen in transverse sections.

The varying shape of the spinal cord in the several regions and the changing relations of the gray to the white substance are shown in the illustrations of cross-sections of the adult human spinal cord (see p. 407).

The gray substance is arranged in the form of two crescents, one in each half of the cord, united by a median portion extending from one half of the cord to the other, the whole presenting somewhat the form of an H. The horizontal part contains the commis-

A

B

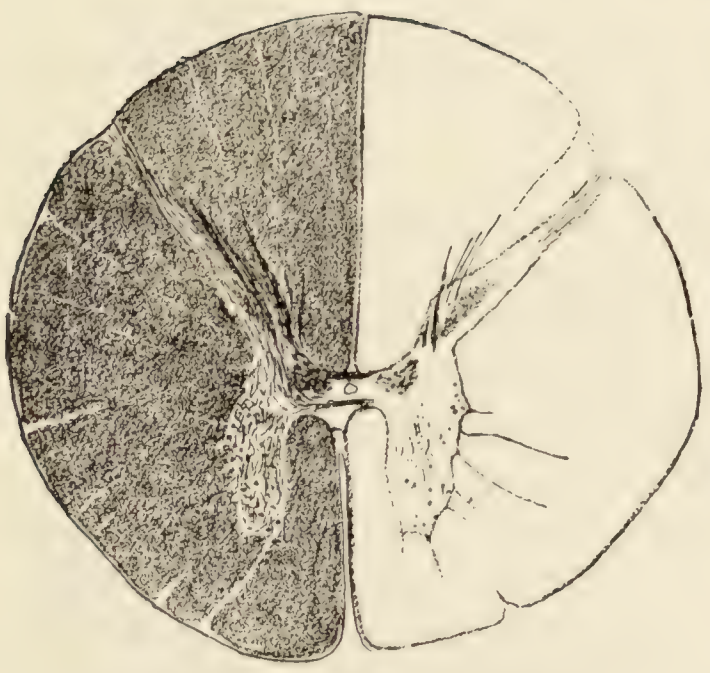

C

D

Fig. 327.—Four cross-sections of the human spinal cord; $\times 7$: *A*, Cervical region in the plane of the sixth spinal nerve-root; *B*, lumbar region; *C*, thoracic region; *D*, sacral region (compare with Fig. 328). (From preparations of H. Schmaus.)

sures and the central canal of the spinal cord, while the vertical limbs or crescents extend to the ventral and dorsal nerve-roots, forming the anterior and posterior horns. The former are, as a rule, the larger, and at their sides (laterally) the so-called lateral horns may be seen, varying in size in different regions. In each anterior horn are three main groups of ganglion cells: the **ventrolateral,** made up of root or motor nerve-cells; the **ventromesial,** composed of commissural cells; and the **lateral** (in the lateral horn), containing column cells. At the median side of the base of each posterior horn we find a group of cells and fibers known as the **column of Clark,** most clearly defined in the dorsal region, while in the posterior horn itself is the **gelatinous substance of Rolando.** Aside from these, numerous cells and fibers are scattered throughout the entire gray substance.

The motor nerve-cells lie in the ventrolateral portion of the anterior horn, their neuraxes extending into the anterior nerve-root. Their dendrites are distributed in a lateral, dorsal, and mesial direction, the two former groups ending in the anterior and lateral columns, the mesial in the region of the anterior commissure. Some of the mesial dendrites extend beyond the median line and form a sort of commissure with the corresponding processes of the other side. The commissural cells lie principally in the mesial group of the anterior horn, but occur here and there in other portions of the gray substance. Their neuraxes form the anterior gray commissure with the corresponding processes from the other side. After entering the white substance of the other side, these neuraxes undergo a T-shaped division, one branch passing upward and the other downward. The column cells are small multipolar elements, represented by the cells of the lateral horns, although they are also found throughout the entire gray mass. Their neuraxes pass directly into the anterior, lateral, and posterior horns.

The cells of the column of Clark, or *nucleus dorsalis*, are of two kinds—those in which the neuraxes pass to the anterior commissure (commissural cells) and those in which the neuraxes pass into the direct cerebellar tract of the same side. The plurifunicular cells are cells the neuraxes of which divide two or three times in the gray substance, the branches then passing to different columns of the white matter on the same or opposite side of the cord. In the latter case the branches must necessarily extend through the commissure. The cells of the *substantia gelatinosa* (Rolando) are cells with short, freely branching neuraxes, which end after a short course in the gray mass (Golgi's cells). The posterior horn contains marginal cells, spindle-shaped cells, and stellate cells. The first are situated superficially near the extremity of the posterior horn, their neuraxes extending for some distance through the gelatinous substance of Rolando and then into the lateral column. The spindle-shaped cells are the smallest in the spinal cord and possess a rich arborization of dendrites extending to the nerve-root of the pos-

terior horn. Their neuraxes, which originate either from the cell-body or from a dendrite, pass over into the posterior column. The stellate cells are supplied with dendrites, which either branch in the substance of Rolando or extend into the column of Burdach.

The gray matter contains, further, numerous medullated nerve-fibers, in part the neuraxes of the nerve-cells previously mentioned, and in part collateral and terminal branches of the nerve-fibers of the white matter with their telodendria; also supporting cells, known as neurogliar cells (to be discussed later), and blood-vessels.

The white matter of the spinal cord consists of medullated fibers, which are devoid of a neurilemma, of neurogliar tissue, and of fibrous connective tissue.

In each half of the cord the white substance, which surrounds the gray, is separated by the gray matter and its nerve-roots into

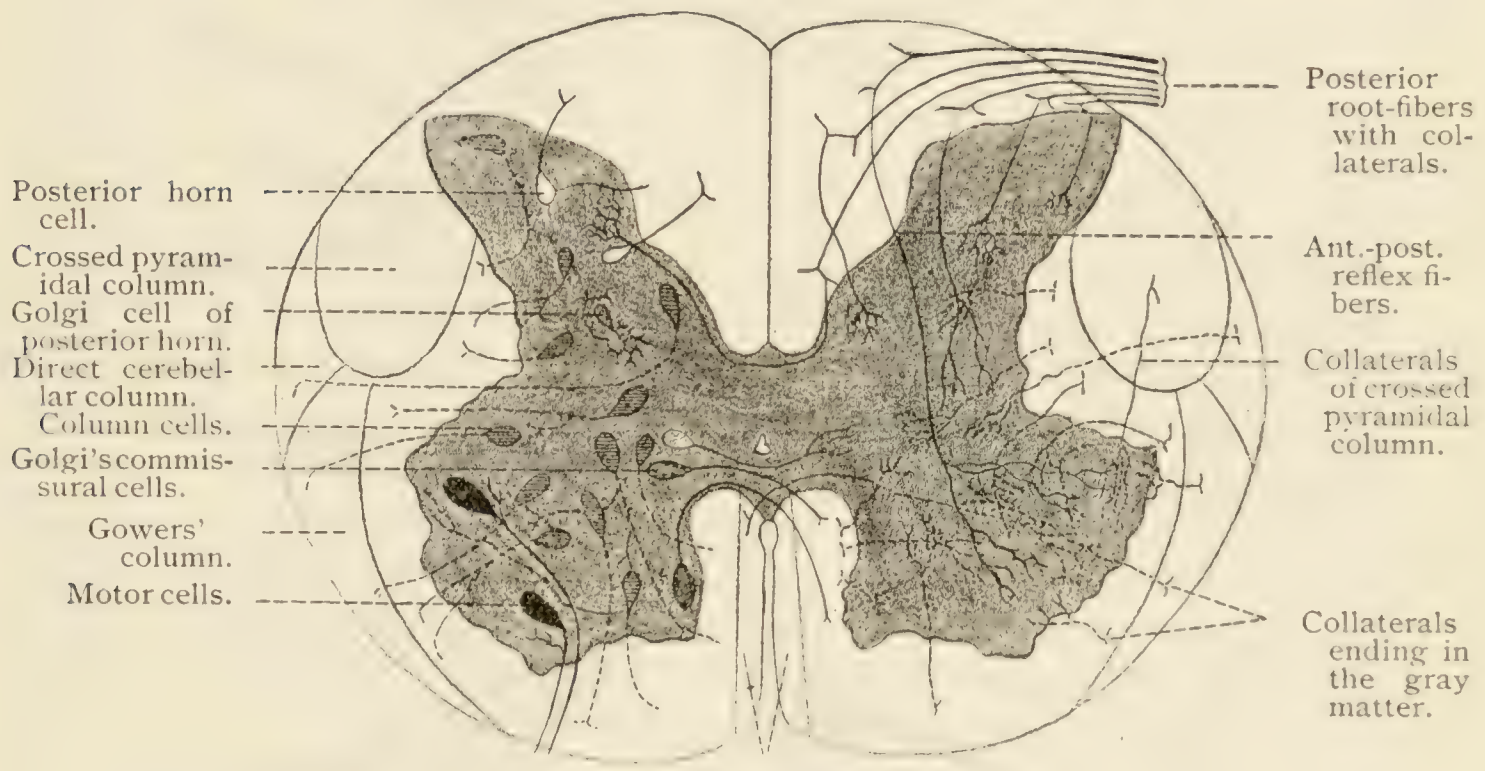

Fig. 328.—Schematic diagram of the spinal cord in cross-section after von Lenhossék, showing in the left half the cells of the gray matter, in the right half the collateral branches ending in the gray matter.

three main divisions or columns: The first division, lying between the anterior median fissure and the anterior horn, is the anterior column; the second, lying between the anterior and posterior horns, is the lateral column (since the anterior and lateral columns belong genetically to each other, the term anterolateral column is often used); and the third, lying between the posterior nerve-root and the posterior median septum, is the posterior column.

By means of certain methods it has been possible to separate the white substance into still smaller divisions, the most important of which may here be described.

In each anterior column is found a narrow median zone extending along the entire length of the anterior median fissure and con-

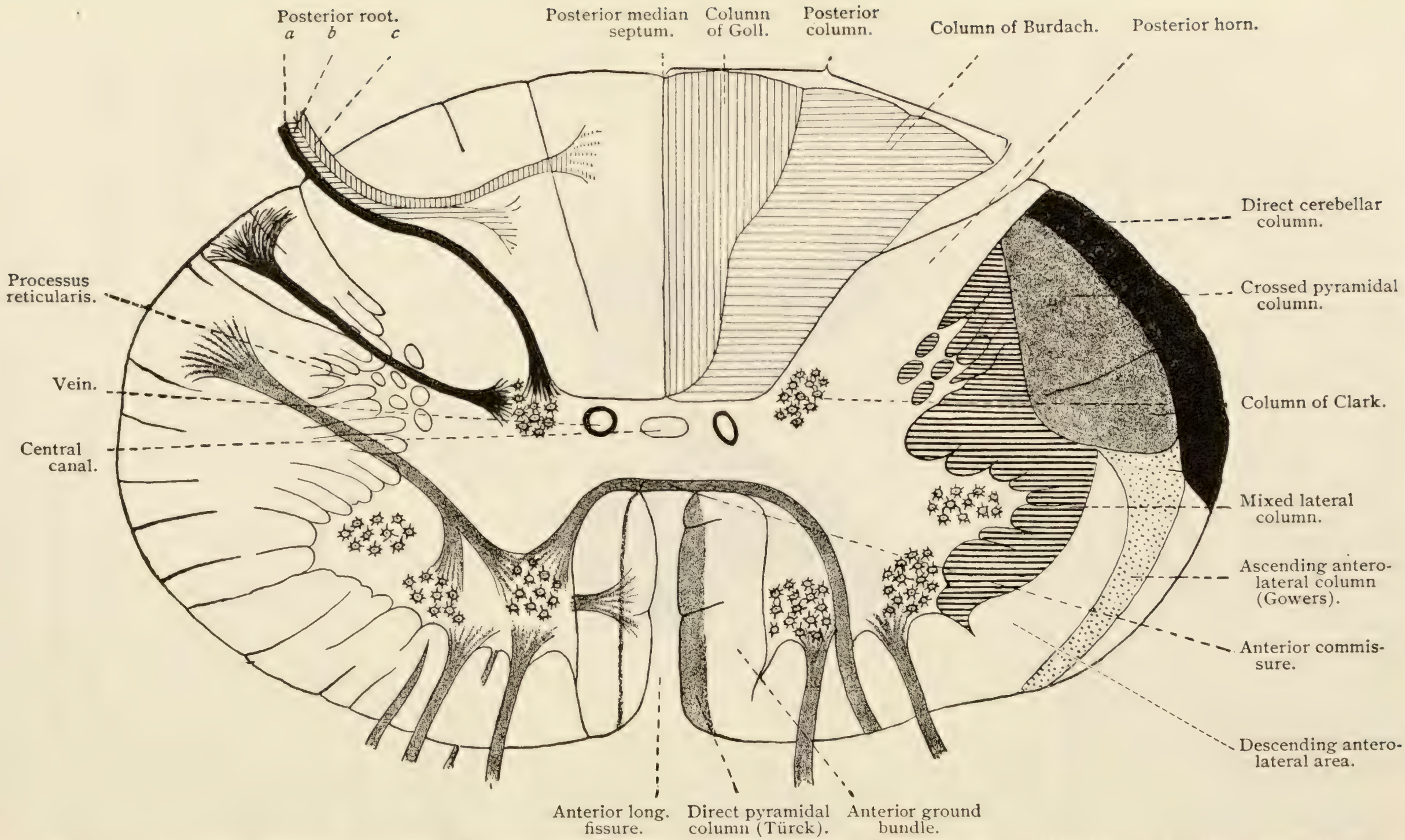

Fig. 329.—Schematic cross-section of the spinal cord, after Professor Ziehen (from von Bardeleben and H. Haeckel): *a*, *b*, and *c*, bundles of the posterior nerve-root.

taining nerve-fibers which come from the pyramids of the medulla. The majority of the pyramidal fibers cross from one side of the cord to the other in the lower portion of the medulla, at the crossing of the pyramids, and form a large bundle of nerve-fibers found in each lateral column, which will receive attention later. Some of the pyramidal fibers descend into the cord on the same side, to cross to the opposite side at different levels in the cord. These latter fibers constitute the narrow median zone, on each side of the anterior median fissure previously mentioned, forming the anterior or **direct pyramidal tract,** or the column of Türck. Between the direct pyramidal tract and the anterior horn lies the **anterior ground bundle.**

In the lateral columns are found a number of secondary columns, which may now be mentioned. In front of and by the side of the posterior horn in each lateral column lies a large group of nerve-fibers, forming a bundle which varies somewhat in size and shape in the several regions of the spinal cord, but which has in general an irregularly oval outline. These nerve-fibers are the pyramidal fibers, previously mentioned, which in the lower part of the medulla cross from one side to the other, and for this reason are known as the crossed pyramidal fibers, forming the **crossed pyramidal columns.** External to these columns and to the posterior horns, and extending from the posterior horns half-way around the periphery of the lateral columns, lie the **direct cerebellar columns,** consisting of the neuraxes of the cells of the columns of Clark, which have an ascending course. Lying just external to and between the anterior and posterior horns is a somewhat irregular zone, the **mixed lateral column,** containing several short bundles of fibers, the anterior of which are probably motor; the posterior, sensory. In the ventrolateral portions of the lateral columns, between the mixed lateral and the direct cerebellar columns and extending as far backward as the crossed pyramidal columns, lie two not well-defined columns, known as the **ascending anterolateral** or **Gowers's columns** and the **descending anterolateral columns;** the former are nearer the outer portion of the cord.

In the posterior column we distinguish a median and a lateral column. The former lies along the posterior median septum, and may even be distinguished externally by an indentation; its upper portion tapers into the *fasciculus gracilis.* This is the **column of Goll,** and it contains ascending or centripetal fibers. The lateral tract lies between the column of Goll and the posterior horn, and is known as the **column of Burdach,** posterior ground-bundle, or posterolateral column. It contains principally the shorter tracts, or bundles of longitudinal fibers connecting the adjacent parts of the spinal cord with one another.

Many of the nerve-fibers of the posterior column are the neuraxes of spinal ganglion cells which enter the spinal cord through the posterior roots. The cell-bodies of the spinal ganglion or sen-

sory neurones are situated in the spinal ganglia found on the posterior roots of the spinal nerves. In the embryo they are distinctly bipolar, but during further development their two processes approach each other, and then fuse for a certain distance, forming finally single processes which branch like the letter T. In reality, then, there are two processes which are fused for a certain distance from the cell-body of each neurone. The peripherally directed process is regarded as the dendrite of the cell, and the proximal as the neuraxis passing to the spinal cord. The neuraxes enter the spinal cord through the posterior roots and pass to the posterior columns, where they divide, Y-shaped, into ascending and much shorter descending branches, from each of which numerous collateral branches are given off.

From the preceding account of the white matter of the spinal cord, it may be seen that it consists of longitudinally directed neuraxes arranged in so-called short and long tracts or columns. The neuraxes constituting the former, after a short course through the gray matter, emerge from it, and after giving off various collaterals, again penetrate into the gray matter, where their telodendria enter into contact with the ganglion cells. The long columns consist of the neuraxes of neurones the cell-bodies of which are situated in the cerebrum or cerebellum, and of neurones the cell-bodies of which are in the spinal cord or spinal ganglia and the neuraxes of which terminate in the medulla or cerebellum. The nerve-fibers of the various columns give off numerous collaterals which enter the gray matter to end in telodendria. The collaterals of the posterior columns end: (1) between the cells of the gelatinous substance of the posterior horns; (2) in the columns of Clark; (3) in the anterior horns, these constituting the principal portion of the so-called reflex bundles; (4) in the posterior horn of the opposite side. The collaterals of the lateral columns pass horizontally toward the central canal, some ending in the anterior horn, others closely arranged near the columns of Clark, and some arching around the central canal, forming with the corresponding fibers of the other side the anterior bundles of the posterior commissure. The collaterals of the anterior columns form well-marked plexuses in the anterior horns of the same and opposite sides.

We have still to describe the two **commissures.** The anterior consists of: first, neuraxes from the commissural cells; second, dendrites from the lateral group of the anterior horn cells; and, third, the collaterals of the anterolateral column, which end in the gray substance of the other side of the cord. The posterior commissure is probably composed of the collaterals from all the remaining columns. The posterior bundle of this commissure comes from the posterior column; the middle, from the posterior portion of the lateral column; and the anterior, or least developed, from the anterior portion of the lateral column, possibly also from the anterior column.

In the gray commissure, nearer its anterior border, is situated the central canal of the spinal cord, continuous above with the ventricular cavity of the medulla and terminating caudally in the filum terminale. This canal is not patent in the majority of adults, being occluded from place to place. The canal is lined by a layer of columnar cells, developed from columnar cells, known as spongioblasts, lining the relatively larger canal of the embryonic spinal cord. In young individuals these cells are ciliated and their basal portions terminate in long, slender processes in which are embedded neuroglia fibers.

B. THE CEREBELLAR CORTEX.

In the cerebellar cortex we distinguish three general layers—the outer molecular, the middle granular (rust-colored layer), and the inner medullary tract.

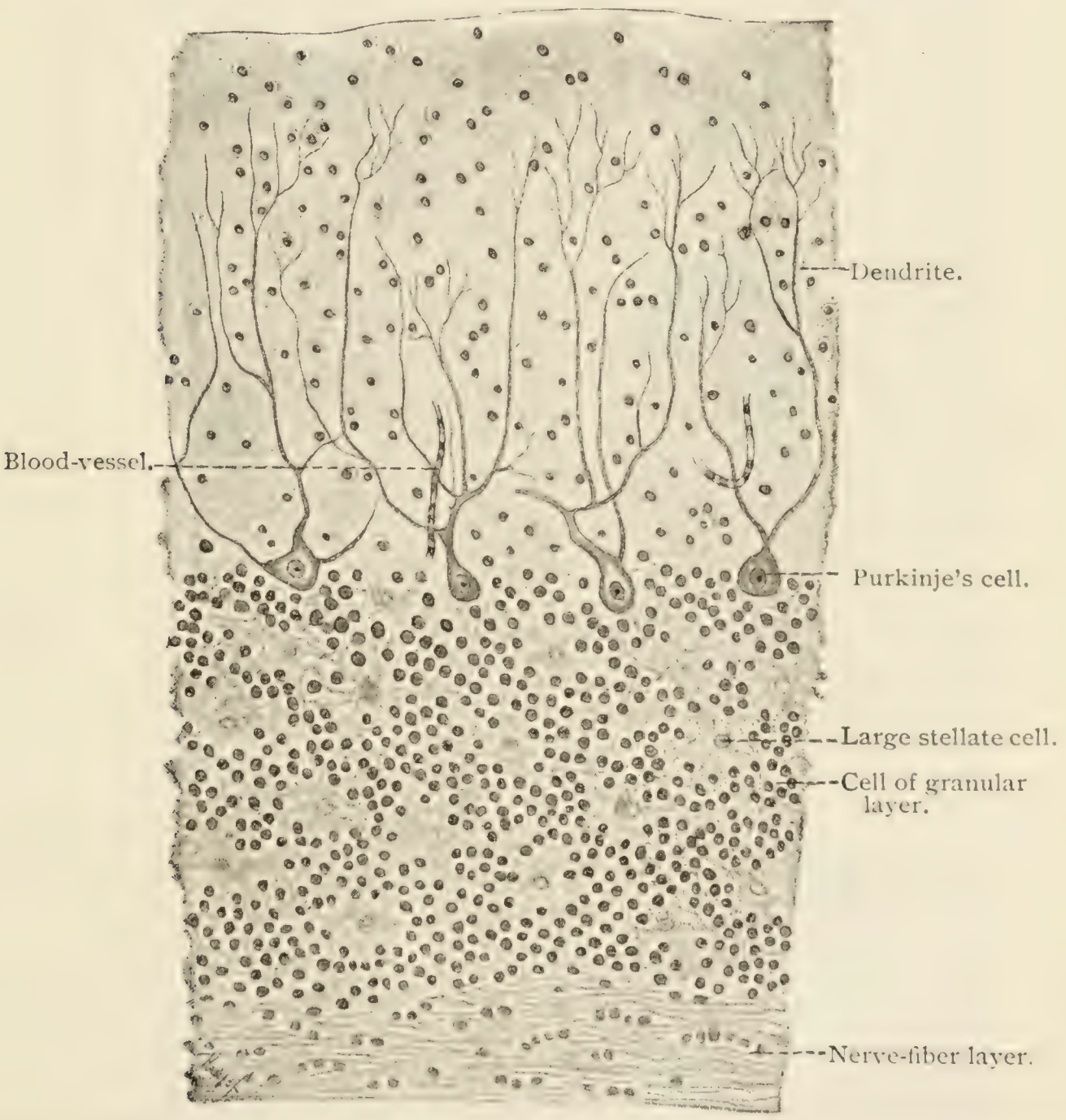

Fig. 330.—Section through the human cerebellar cortex vertical to the surface of the convolution. Treatment with Müller's fluid; × 115.

The **molecular layer** contains three varieties of nerve-cells, those of Purkinje, which border upon the granular layer, the stel-

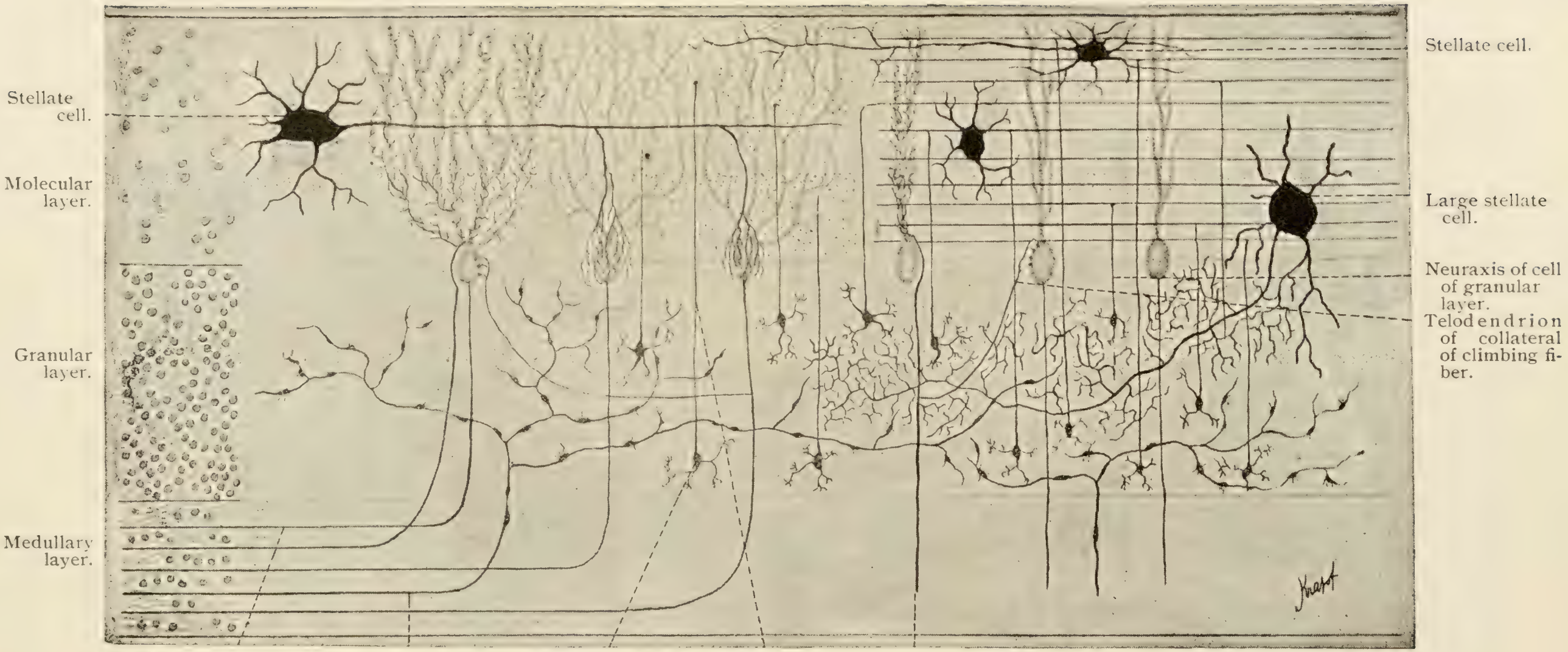

Fig. 331.—Schematic diagram of the cerebellar cortex: *A*, By ordinary nuclear staining (omitting the layer of Purkinje's cells); *B*, vertical to the surface of the convolution; *C*, longitudinal section through the convolution. *B* and *C*, By the chrome-silver method.

late cells, and the small cortical cells. The **cells of Purkinje** possess a large flask-shaped body (about 60 μ in diameter), from which one or more well-developed dendrites pass toward the periphery. The latter branch freely and the main arborization has in each case the general shape of a pair of deer's antlers. These dendrites extend nearly to the periphery of the cerebellar cortex. In a section horizontal to the surface of the organ the dendrites of the Purkinje's cells are seen to lie in a plane very nearly vertical to the surface of the convolutions, so that a longitudinal section through the latter would show a profile view of the cells. In other words, they have an appearance much like that of a vine trained upon a trellis. The neuraxes of the cells of Purkinje arise from their basal

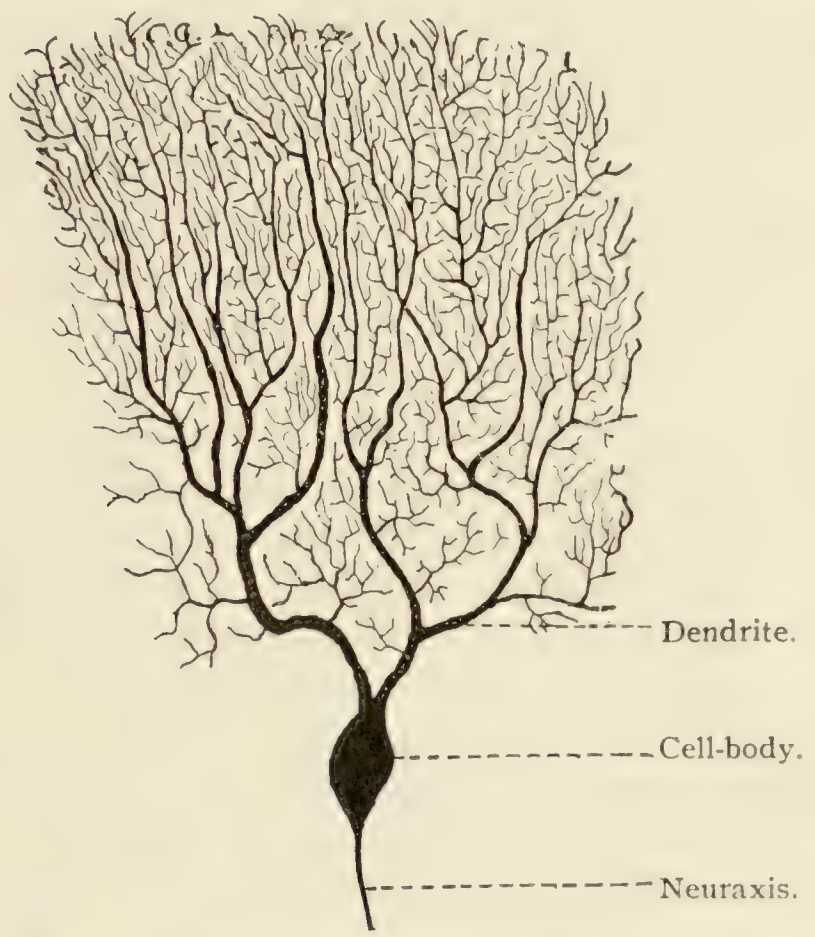

Fig. 332.—Cell of Purkinje from the human cerebellar cortex. Chrome-silver method ; × 120.

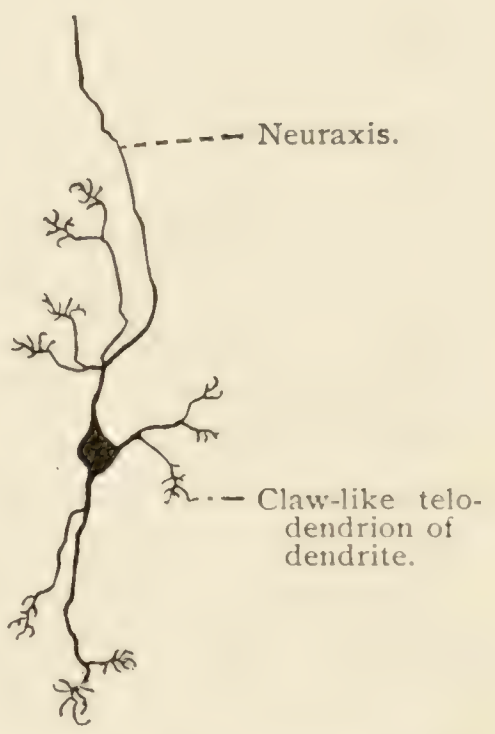

Fig. 333.—Granular cell from the granular layer of the human cerebellar cortex. Chrome-silver method ; × 100.

(inner) ends and extend through the granular layer into the medullary substance. During their course they give off a few collaterals, which pass backward to the molecular layer and end in telodendria near the bodies of the cells of Purkinje. The **stellate cells** lie in various planes of the molecular layer. Their peculiar interest lies in the character of their neuraxes. The latter are situated in the same plane as the dendrites of the cells of Purkinje, run parallel to the surface of the convolution, and possess two types of collaterals. Those of the first are short and branched ; those of the second branch at a level with the cells of Purkinje, and form, together with their telodendria, basket-like nets around the bodies of these cells. The **small cortical cells** of the molecular layer are found

in all parts of this layer, but are more numerous in its peripheral portion. They are multipolar cells with neuraxes which are not readily stained and concerning the fate of which little is known.

The **granular layer** contains two varieties of ganglion elements, the so-called granular cells (small ganglion cells) and the large stellate cells. The dendrites of the **granular cells** are short, few in number (from three to six), branch but slightly, and end in short, claw-like telodendria. Their neuraxes ascend vertically to the surface and reach the molecular layer. At various points some of them are seen to undergo a T-shaped division, the two branches then running parallel to the surface of the cerebellum in a plane vertical to that of the dendrites of the cells of Purkinje. Large numbers of these T-shaped neuraxes produce the striation of the molecular layer of the cerebellum. It is very probable that during their course these parallel fibers come in contact with the dendrites of the cells of Purkinje. The **large stellate cells** are fewer in number and lie close to the molecular layer, some of them even within this layer. Their dendrites branch in all directions, but extend principally into the molecular layer. Their short neuraxes give off numerous collaterals which end in telodendria among the granular cells.

The **medullary substance** is composed of the centrifugal neuraxes of the cells of Purkinje and of two types of centripetal neuraxes, the mossy and the climbing fibers. The position of their corresponding nerve-cells is not definitely known. The **mossy fibers** branch in the granular layer into numerous twigs, and are not uniform in diameter, but are provided at different points with typical nodular swellings. These fibers do not extend beyond the granular layer. The **climbing fibers** pass horizontally through the granular layer, giving off in their course numbers of collaterals, which extend to the cells of Purkinje, up the dendrites of which they seem to climb.

In the medullary portion of the cerebellum are found a number of groups of ganglion cells known as central gray nuclei. The nerve-cells of these nuclei are multipolar, with numerous, oft-branching dendrites and a single neuraxis.

C. THE CEREBRAL CORTEX.

The cell-bodies of the neurones of the cerebrum are grouped in a thin layer of gray matter, varying in thickness from 2 to 4 mm., —which, as a continuous sheet, completely covers the white matter of the hemispheres,—and in larger and smaller masses of gray matter, known as basal nuclei. In our account of the histologic structure of the cerebral hemispheres we shall confine ourselves in the main to a consideration of the cerebral cortex, the thin layer of gray matter investing the white matter.

From without inward the following layers may be differentiated in the cerebral cortex: (1) a molecular layer; (2) a layer of small pyramidal cells; (3) a layer of large pyramidal cells; (4) a layer of polymorphous cells; and (5) medullary substance or underlying nerve-fibers.

Aside from neurogliar tissue, we find in the **molecular layer** a large number of nerve-fibers, which cross one another in all directions, but, as a whole, have a direction parallel with the surface of the brain. Within this layer there are found: (1) the tuft-like telodendria of the chief dendritic processes of the pyramidal cells; (2) the terminations of the ascending neuraxes, arising mostly from the polymorphous cells; and (3) autochthonous fibers—*i. e.*, those which arise from the cells of the molecular layer and terminate in this layer. The cells of the molecular layer may be classed in three general types—polygonal cells, spindle-shaped cells, and triangular or stellate cells. The **polygonal cells** have from four to six dendrites, which branch out into the molecular layer and may even penetrate into the underlying layer of small pyramidal cells. Their neuraxes originate either from the bodies of the cells or from one of their dendrites, and take a horizontal or an oblique direction, giving off in their course a large number of branching collaterals, which terminate in knob-like thickenings. The **spindle-shaped cells** give off from their long pointed ends dendrites which extend for some distance parallel with the surface of the brain. These branch, their offshoots leaving them at nearly right angles, the majority passing upward, assuming as they go the characteristics of neuraxes having collaterals. The arborization is entirely within the molecular layer. The **triangular** or **stellate cells** are similar to those just described, but possess not two, but three, dendrites. The triangular and spindle-shaped cells, with their numerous dendritic processes resembling neuraxes, are characteristic of the cerebral cortex.

The elements which are peculiar to the second and third layers of the cerebral cortex are the **small** (about 10 μ in diameter) and **large pyramidal cells** (from 20 μ to 30 μ in diameter). They are composed of a triangular body, the base of the triangle being downward and parallel to the surface of the brain, of a chief, principal, or primordial dendrite ascending toward the brain-surface, of several basilar dendrites arising from the basal surface of the cell-body, and of a neuraxis which passes toward the medullary substance and which has its origin either from the base of the cell or from one of the basilar dendrites. The ascending or chief dendrite gives off a number of lateral offshoots which branch freely and end in terminal filaments. The main stem of the dendrite extends upward to the molecular layer, in which its final branches spread out in the form of a tuft. The neuraxis, during its course to the white substance, gives off in the gray substance from six to twelve collaterals, which divide two or three times before terminating.

Aside from the fact that the **layer of polymorphous cells** contains a few large pyramidal cells, it consists principally of (1) multipolar cells with short neuraxes (Golgi's cells) and (2) of cells with

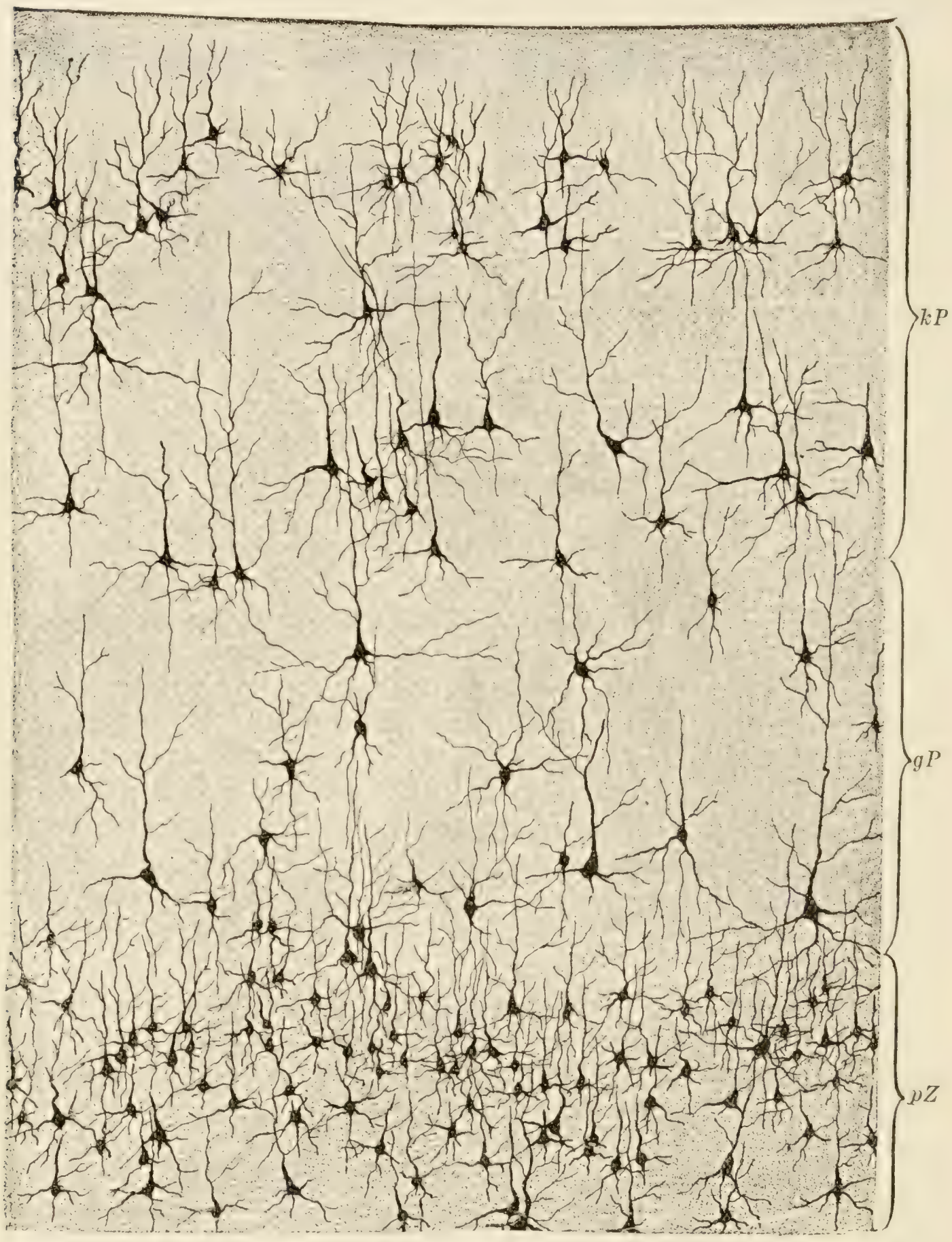

Fig. 334.—Portions of vertical section of human cerebral cortex, treated by the Golgi method; × 70. The figure shows the arrangement of the different cells of the cerebral cortex: *gP*, Layer of large pyramidal cells; *kP*, layer of small pyramidal cells; *pZ*, layer of polymorphous cells (Sobotta, "Atlas and Epitome of Histology").

only slightly branched dendrites and with neuraxes passing toward the surface of the brain (Martinotti's cells). Both these types of cells are, however, not found exclusively in the layer of polymorphous

cells, but may be met with here and there in the layers of the small and large pyramidal cells. The dendrites of the **cells of Golgi** are projected in all directions, those in the neighborhood of the medullary substance even penetrating into this layer. The neuraxes break up into numerous collaterals, the telodendria of which lie adjacent to the neighboring ganglion cells. The **cells of Martinotti,** which, as we have seen, occur also in the second and third layers, are either triangular or spindle-shaped. The neuraxis of each cell originates either from the cell-body or from one of its dendrites, and

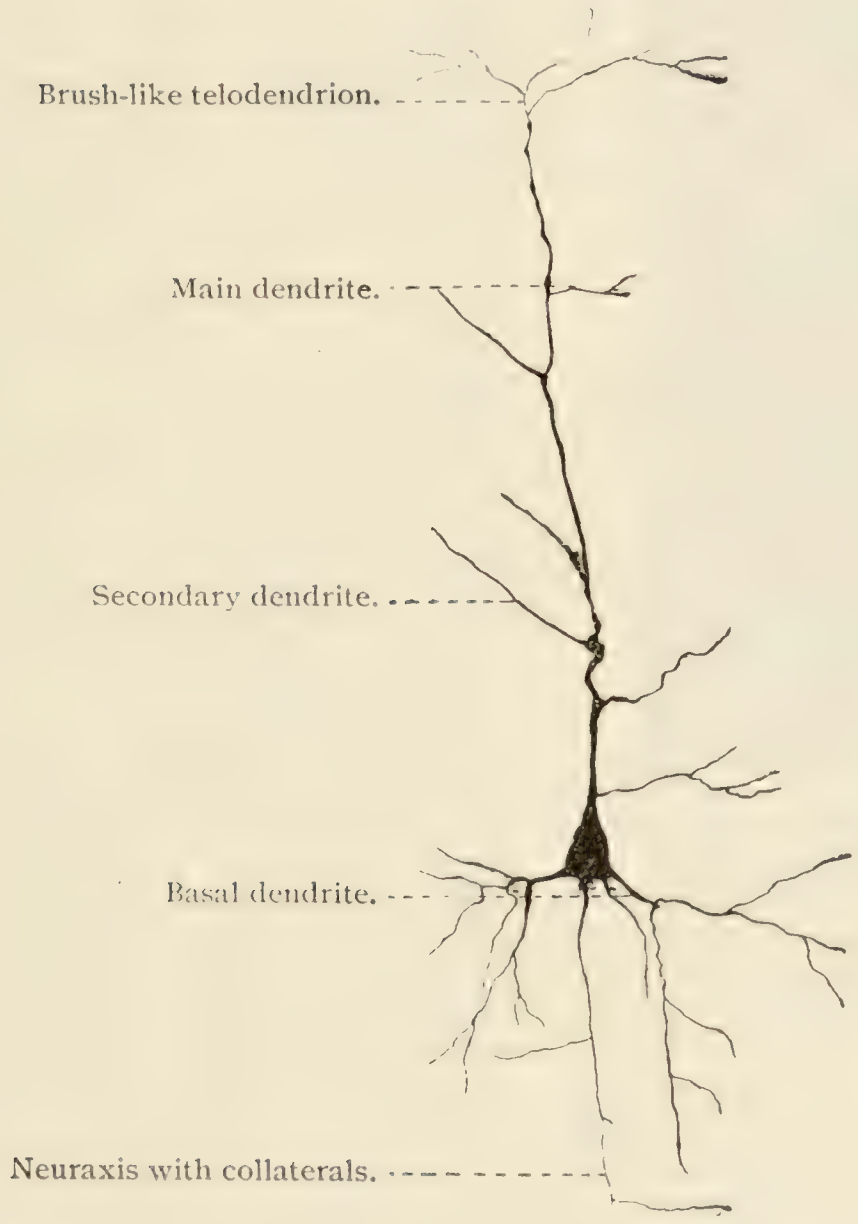

Fig. 335.—Large pyramidal cell from the human cerebral cortex. Chrome-silver method; × 150.

ascends (giving off collaterals) to the molecular layer, in which it finally divides into two or three main branches ending in telodendria. Occasionally it divides in a similar manner in the layer of small pyramidal cells.

In the **medullary substance** the following four classes of fibers are recognized: (1) The **projection fibers** (centrifugal)—*i. e.*, those which indirectly connect the elements of the cerebral cortex with the periphery of the body; their course may or may not be interrupted

during their passage through the basal nuclei ; (2) the **commissural fibers,** which, according to the original definition, pass through the corpus callosum and anterior commissure, thus joining corresponding parts of the two hemispheres ; (3) the **association fibers,** which connect different parts of the gray substance of the same hemispheres ; and (4) the **centripetal** or **terminal fibers** — *i. e.*, the terminal arborizations of those neuraxes, the cells of which lie in some other region of the same or opposite hemisphere, or even in some more distant portion of the nervous system. The projection fibers originate from the pyramidal cells, some of them perhaps from the polymorphous cells. The commissural fibers are also derived from the pyramidal cells, and lie somewhat deeper in the white substance than the association fibers. With the exception of those which join the cunei and those which lie in the anterior commissure, all the commissural fibers are situated in the corpus callosum. They give off during their passage through the hemispheres large numbers of collaterals, which penetrate at various points into the gray substance and end there in terminal filaments. In this respect their arborization is contrary to the old definition of these fibers, and the latter must be completed by the statement that, besides joining symmetric points of the two hemispheres, they also, by means of their collaterals, may connect other areas of the gray substance with the peripheral regions supplied by their end-tufts (Ramôn y Cajal, 93). The association fibers have their origin also in the pyramidal cells. In the medullary substance their neuraxes divide T-shaped, and after a longer or shorter course penetrate into the gray substance of the same hemisphere, where they end as terminal fibers. A few collaterals are, however, previously given off,



Fig. 336.—Schematic diagram of the cerebral cortex : *a*, Molecular layer with superficial (tangential) fibers ; *b*, striation of Bechtereff-Kaes ; *c*, layer of small pyramidal cells ; *d*, stripe of Baillarger ; *e*, radial bundles of the medullary substance ; *f*, layer of polymorphous cells.

which also terminate in the same manner in the gray substance. The association fibers form the bulk of the medullary rays.

On examining a vertical section through one of the cerebral convolutions a number of successive striations may be seen. These are more or less distinct, according to the region, and consist of strands of medullated nerve-fibers between the layers of cells, and parallel with the surface of the convolution. The most superficial form a layer of tangential fibers. Between the molecular layer and the layer of small pyramidal cells is the **striation of Bechtereff and Kaes,** and in the region of the large pyramidal cells the **striation of Baillarger** (Gennari) corresponding to the striation of Vicq d'Azyr in the cuneus. In figure 336 the medullary substance is seen below, with rays, composed of parallel bundles of fibers, passing upward into the gray substance; in reality these fibers penetrate much higher than is shown in the illustration.

D. THE OLFACTORY BULB.

The olfactory bulb is composed of five layers, which are especially well marked on its ventral side: first, the layer of peripheral nerve-fibers; second, the layer of olfactory glomeruli; third, the stratum gelatinosum, or molecular layer; fourth, the layer of pyramidal cells (mitral cells); and, fifth, the granular layer with the deeper nerve-fibers.

The **layer of peripheral fibers** is composed of the nerve-bundles of the olfactory nerve which cross one another in various directions and form a nerve-plexus. The **glomerular layer** contains peculiar, regularly arranged, round or oval, and sharply defined structures, which were first accurately studied by Golgi. They are known as glomeruli (from 100 μ to 300 μ in diameter), and are in reality complexes of intertwining telodendria. As we shall see, the epithelial cells of the olfactory region of the nose must be regarded as peripheral ganglion cells and their centripetal (basal) processes as neuraxes. The telodendria of these neuraxes, together with those of the dendrites from the mitral or other cells, come in contact with each other within the olfactory glomeruli. The **molecular layer** consists of small, spindle-shaped ganglion cells. Their neuraxes enter the fifth layer and their short dendrites end in terminal ramifications in the glomeruli. The **mitral cells** give off neuraxes from their dorsal surfaces which also enter the granular layer, but the majority of their dendrites break up into terminal ramifications in the olfactory glomeruli, as just described. The **granular layer** (absent in the illustration) is made up of nerve-cells and nerve-fibers; but, aside from these, we find also large numbers of peculiar cells with a long peripherally and several short centrally directed dendrites. No neuraxes can be demonstrated in these

cells (granular cells). This layer also contains the stellate ganglion cells. The latter are not numerous, but lie scattered, and each possesses several short dendrites and a peripherally directed neuraxis which ends in the molecular layer in a rich arborization. The deep nerve-fibers are grouped into bundles which inclose between them the granular and stellate cells just mentioned. These nerve-fibers

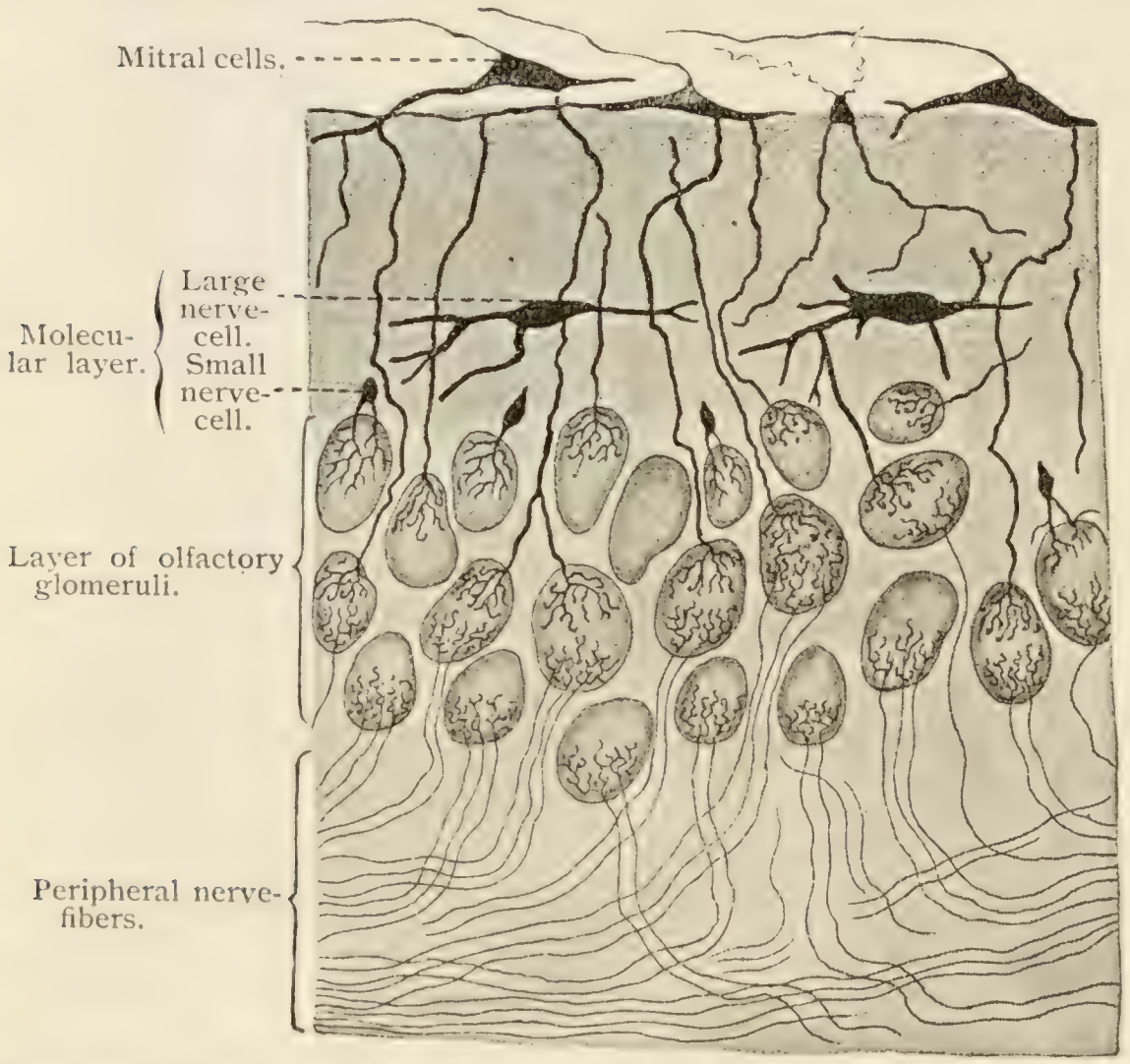

Fig. 337.—The olfactory bulb, after Golgi and Ramón y Cajal. The granular layer is not shown.

are derived partly from the neuraxes of the pyramidal or mitral cells and partly from the cells of the molecular layer, while some of them are centripetal fibers from the periphery, which end between the granules of the fifth layer.

E. EPIPHYSIS AND HYPOPHYSIS.

In mammalia the **epiphysis,** or pineal gland, consists of a fibrous capsule derived from the pia mater, from which numerous fibrous tissue septa and processes pass into the gland, uniting to form quite regular round or oval compartments in which closed follicles or alveoli, whose walls consist of epithelial cells, are found. In the lower portion of the epiphysis there is found a relatively large amount of neuroglia tissue, consisting of coarse fibers, as has been shown by Weigert. The epithelial cells forming the walls of the follicles are of cubic or short columnar shape, and may be arranged in a single layer or may be pseudostratified or stratified. Follicles

completely filled with cellular elements are found. Other follicles contain peculiar concretions, known as brain-sand or **acervulus,** of irregular round or oval or mulberry shape. Medullated nerve-fibers have been traced into the epiphysis, but their mode of termination is not known.

The **hypophysis,** or pituitary body, consists of two lobes. The posterior or infundibular lobe is developed from the floor of the first primary brain-vesicle, and remains attached to the floor of the third ventricle by a stalk, known as the infundibulum ; the anterior or glandular lobe develops from a hollow protrusion derived from the primary oral ectoderm. The distal end of this protrusion or pouch comes in contact with the anterior surface of the lower portion of the infundibulum, and becomes loosely attached to it. As the bones at the base of the skull develop, the attenuated oral end of this pouch atrophies, the distal end becoming finally completely severed from the buccal cavity.

In the infundibular lobe of the hypophysis of the dog, Berkley (94) described three portions presenting different microscopic structure. His account will here be followed : (1) An outer stratum consisting of three or four layers of cells resembling ependymal cells, which are separated into groups by thin strands of fibrous tissue entering from the fibrous covering of this lobe. (2) A zone consisting of glandular epithelial cells which in certain places are arranged in the form of alveoli, often containing a colloid substance. This zone merges into the central portion, (3), containing variously shaped cells and connective-tissue partitions with blood-vessels. In this portion neurogliar cells (see these) and nerve-cells were stained by the chrome-silver method.

The glandular or anterior lobe resembles slightly in structure the parathyroid. This lobe is surrounded by a fibrous tissue capsule and within it are found variously shaped alveoli or follicles, or, again, columns or trabeculæ of cells separated by a very vascular connective tissue. In the alveoli or columns of cells are found two varieties of glandular cells, which may be differentiated more by their staining reaction than by their size and structure, although they present slight structural differences. One variety of cells possesses a protoplasm which shows affinity for acid stains ; these are known as **chromophilic cells.** They are of nearly round or oval shape, with nuclei centrally placed, and have a protoplasm presenting coarse granules. The other variety of cells, known as **chief cells,** are more numerous than the chromophilic. They are of cubic or short columnar shape, with nuclei placed in the basal portions of the cells and with protoplasm showing a fine granulation and with an affinity for basic stains. Now and then alveoli containing a colloid substance, similar to that found in the alveoli of the thyroid gland, may be observed. The blood-vessels of the glandular portion are relatively large, the majority of them having only an endothelial lining which comes in contact with the glandular cells.

The circulation of the hypophysis must be regarded as sinusoidal. In the glandular portion of the hypophysis of the dog, Berkley (94) found small varicose nerve-fibers belonging to the sympathetic system. From the larger bundles, which follow the blood-vessels, are given off single fibers, or small bundles of such, which end on the glandular elements in numerous small nodules.

F. GANGLIA.

In the course of peripheral nerves are found numerous larger and smaller groups of nerve-cells, known as ganglia. The neurones of these ganglia are in intimate relation with the neurones of the cen-

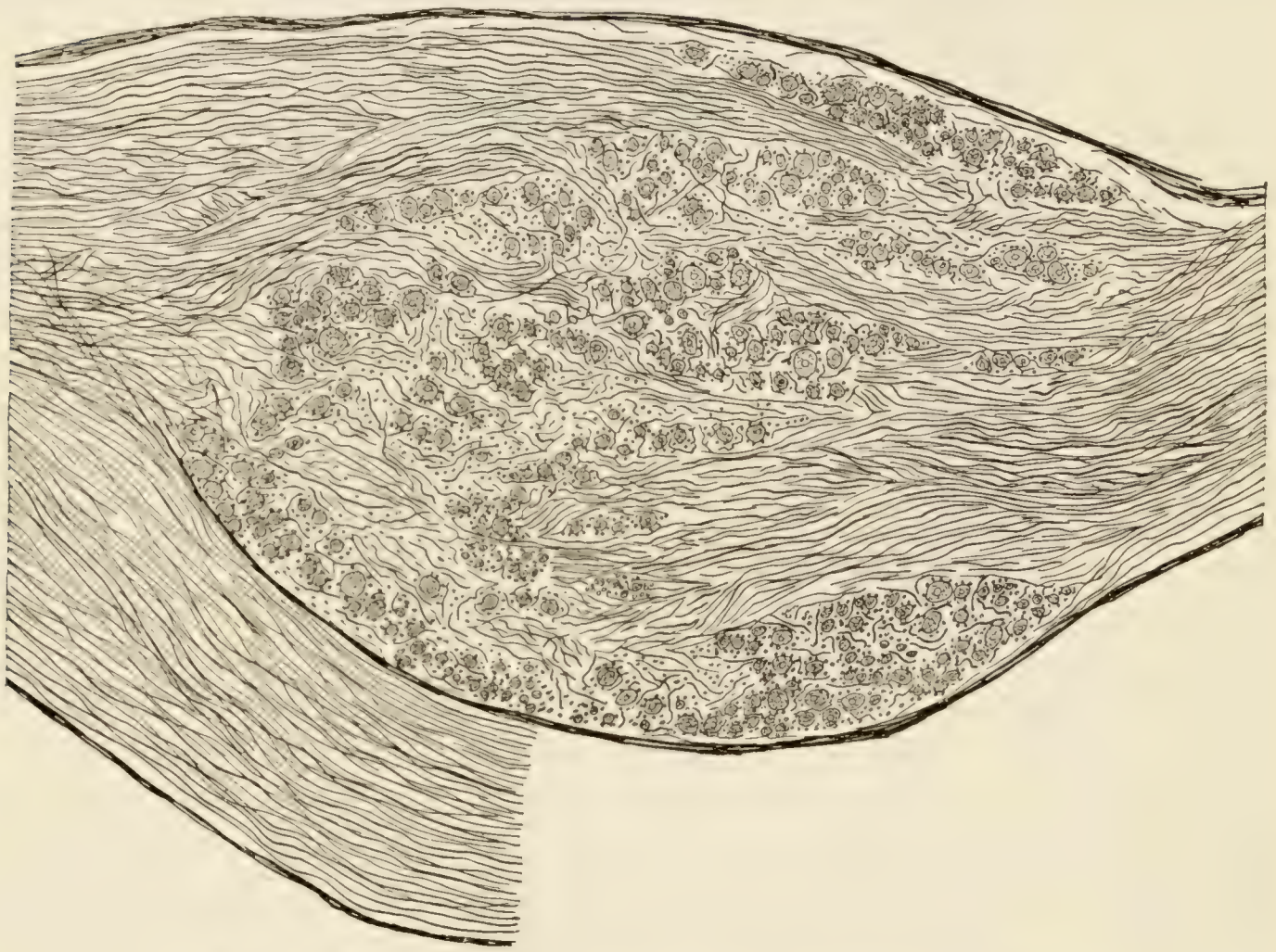

Fig. 338.—Longitudinal section of spinal ganglion of cat.

tral nervous system, and may, therefore, be discussed with the latter. According to the structure and function of their neurones, the ganglia are divided into two groups—(1) spinal or sensory ganglia and (2) sympathetic ganglia.

The **spinal ganglia** are situated on the posterior roots of the spinal nerves. Certain cranial ganglia—namely, the Gasserian, geniculate, and auditory ganglia, the jugular and petrosal ganglia of the glossopharyngeal nerves, and the root and trunk ganglia of the vagi—are classed with the spinal ganglia, since they present the same structure. The spinal and sensory cranial ganglia are surrounded by firm connective-tissue capsules, continuous with the perineural sheaths of the incoming and outgoing nerve-roots. From

these capsules connective-tissue septa and trabeculæ pass into the interior of the ganglia, giving support to the nerve-elements. The cell-bodies (ganglion cells) of the neurones constituting these ganglia are arranged in layers under the capsule and in rows and groups or clusters between the nerve-fibers in the interior of the ganglia. More recent investigations have shown that several types of neurones are to be found in the spinal and cranial sensory ganglia; of these, we may mention the following: (1) Large and small unipolar cells with T- or Y-shaped division of the process. These neurones, which constitute the greater number of all the neurones of the ganglia under discussion, consist of a round or oval cell-body, from which arises by means of an implantation cone

Fig. 339.—Ganglion cell from the Gasserian ganglion of a rabbit; stained in methylene-blue (*intra vitam*).

a single process, which, soon after it leaves the cell, becomes invested with a medullary sheath and usually makes a variable number of spiral turns near the cell-body. According to Dogiel, this process divides into two branches, usually at the second or third node of Ranvier, sometimes not until the seventh node is reached. Of these two branches, the peripheral is the larger, and enters a peripheral nerve-trunk as a medullated sensory nerve-fiber, terminating in one of the peripheral sensory nerve-endings previously described. The central process, the smaller of the two, becomes a medullated nerve-fiber, which enters the spinal cord or medulla in a manner described in a former section. The cell-body of each of these neurones is surrounded by a nucleated capsule, continuous with

the neurilemma of the single process.* (2) Type II spinal ganglion cell of Dogiel. Dogiel has recently described a second type of spinal ganglion cell which differs materially from the type just described. The cell-bodies of these neurones resemble closely those of the typical spinal ganglion neurones. Their single medullated processes divide, however, soon after leaving the cells into branches which divide further and which do not pass beyond the bounds of the ganglia but terminate, after losing their medullary sheaths, in complicated pericapsular and pericellular end-plexuses surrounding the capsules and cell-bodies of the typical spinal ganglion cells. (3) Multipolar ganglion cells; in nearly all spinal and cranial ganglia there are found a few multipolar nerve-cells, which in shape and structure resemble the nerve-cells of the sympathetic system.

Fig. 340.—Diagram showing the relations of the neurones of a spinal ganglion; *p. r.*, posterior root; *a. r.*, anterior root; *p. s.*, posterior branch and *a. s.*, anterior branch of spinal nerve; *w. r.*, white ramus communicans; *a*, large, and *b*, small spinal ganglion cells with T-shaped division of process; *c*, type II spinal ganglion cells (Dogiel); *s*, multipolar cell; *d*, nerve-fiber from sympathetic ganglion terminating in pericellular plexuses (slightly modified from diagram given by Dogiel).

Entering the spinal ganglia from the periphery are found a relatively small number of small, medullated or nonmedullated nerve-fibers, probably derived from sympathetic ganglia. These nerve-fibers, medullated and nonmedullated, the former losing their medullary sheaths within the ganglia, approach a spinal ganglion cell, and after making a few spiral turns about its process, terminate in pericapsular and pericellular end-plexuses. Dogiel believes that the cell-bodies and capsules thus surrounded by the terminal branches of the sympathetic fibers terminating in the spinal ganglia belong to the spinal ganglion cells of the second type first described by him. In figure 340 is represented by way of diagram the structure of a spinal ganglion.

In the medium-sized cells (from 30 μ to 45 μ in diameter) of the

spinal ganglia of the frog, von Lenhossék (95) found centrosomes surrounded by a clear substance (centrospheres). The entire structure lay in a depression of the nucleus and contained more than twelve extremely minute granules (centrosomes), which showed a staining reaction different from that of the numerous concentrically laminated granules present in the protoplasm. This observation is interesting in that it proves that centrosome and sphere occur also in the protoplasm of cells which have not for a long time undergone division and in which there is no prospect of future division.

Sympathetic Ganglia.—The ganglia of the sympathetic nervous system comprise those of the two great ganglionated cords, found on each side of the vertebral column and extending from its cephalic to its caudal end, with which may be grouped certain cranial ganglia having the same structure,—namely, the sphenopalatine, otic, ciliary, sublingual, and submaxillary ganglia; also three un-

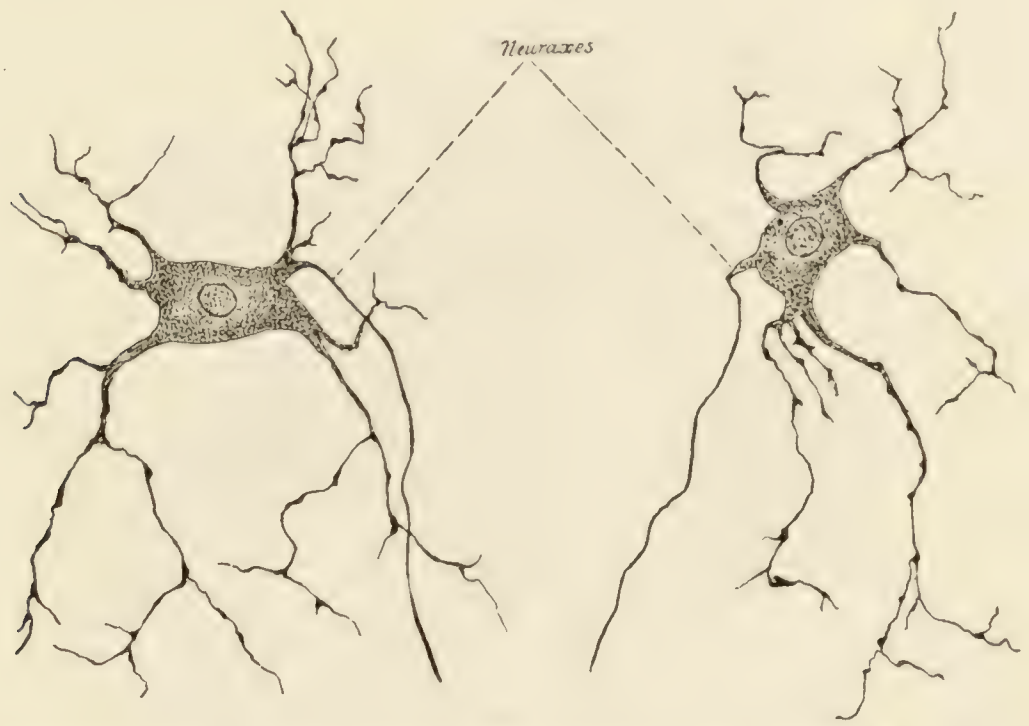

Fig. 341.—Neurone from inferior cervical sympathetic ganglion of a rabbit; methylene-blue stain.

paired aggregations of ganglia, found in front of the spinal column, of which the cardiac is in the thorax, the semilunar in the abdomen, and the hypogastric in the pelvis; and further, large numbers of smaller ganglia, the greater number of which are of microscopic size and are found in the walls of the intestinal canal and bladder, in the respiratory passages, in the heart, and in or near the majority of the glands of the body.

The sympathetic ganglia are inclosed in fibrous tissue capsules continuous with the perineural sheaths of their nerve-roots. The thickness of the capsule bears relation to the size of the ganglion, being thicker in the larger and thinner in the smaller ones. From these capsules thin connective-tissue septa or processes pass into the interior of the ganglia, supporting the nerve elements.

The sympathetic neurones, the cell-bodies and dendritic processes of which are grouped to form the sympathetic ganglia, are variously

shaped unipolar, bipolar, and multipolar cells, the cell-bodies of which are surrounded by nucleated capsules, continuous with the neurilemma of their neuraxes. In the sympathetic ganglia of mammalia and birds the great majority of sympathetic neurones are multipolar, although in nearly all ganglia a small number of bipolar and unipolar cells are to be found, usually near the poles of the ganglia.

The dendrites of the sympathetic neurones in any one ganglion branch repeatedly. Of these branches, some extend to the periphery of the ganglion, where they interlace to form a peripheral subcapsular plexus, while others interlace to form plexuses between the cell-bodies of the neurones in the interior of the ganglion—**pericellular plexuses.** These pericellular plexuses are external to the capsules surrounding the cell-bodies of the sympathetic neurones.

Fig. 342.—From section of semilunar ganglion of cat ; stained in methylene-blue, *intra vitam* (Huber, *Journal of Morphology*, 1899).

The neuraxes of the sympathetic neurones, the majority of which are nonmedullated, the remainder surrounded by delicate medullary sheaths, arise from the cell-bodies either from implantation cones or from dendrites at variable distances from the cell-bodies, leave the ganglion by way of one of its nerve-roots, and terminate in heart muscle tissue, nonstriated muscle, and glandular tissue, and to some extent in other ganglia, both sympathetic and spinal. Terminating in all sympathetic ganglia are found certain small medullated nerve-fibers, varying in size from about 1.5 μ to 3 μ. The researches of Gaskell, Langley, and Sherrington have shown that these small medullated nerve-fibers leave the spinal cord through the anterior roots of the spinal nerves from the first dorsal to the third or fourth lumbar and reach the sympathetic

ganglia through the *white rami communicantes.* Similar small medullated nerve-fibers are found in certain cranial nerves. These small medullated nerve-fibers, which may be spoken of as *white rami fibers,* after a longer or shorter course, in which they may pass through one or several ganglia without making special connection with the neurones contained therein, terminate in some sympathetic ganglion in a very characteristic manner. After entering the sympathetic ganglion in which they terminate, they branch repeatedly while yet medullated. The resulting branches then lose their medullary sheaths and divide into numerous small, varicose nerve-fibers, which interlace to form **intracapsular plexuses,** which surround the cell-bodies of the sympathetic neurones. In the sympathetic ganglia of mammalia such intracapsular pericellular

Fig. 343.—From section of stellate ganglion of dog, stained in methylene-blue and alum carmin: *a*, white ramus fiber (Huber, *Journal of Morphology*, 1899).

plexuses may be very simple, consisting of only a few varicose nerve-fibers, or very complicated, consisting of many such fibers. In the sympathetic ganglia of reptilia, in which are found very large sympathetic neurones, the white rami fibers are wound spirally about the cell-bodies of such neurones before terminating in complicated pericellular plexuses. In the frog and other amphibia the sympathetic neurones are unipolar nerve-cells. The white rami fibers terminating in the sympathetic ganglia of amphibia are wound spirally about the single processes of these unipolar cells while yet medullated fibers, but they lose their medullary sheaths before terminating in the intracapsular pericellular plexuses. From what has been said concerning the white rami fibers and their relation to the sympathetic neurones, it is evident that the sympathetic neu-

rones, the cell-bodies and dendrites of which are grouped to form the sympathetic ganglia, form terminal links in nerve or neurone chains; the second link of these chains is formed by neurones the cell-bodies of which are situated in the spinal cord or medulla, the

Fig. 344.—From section of sympathetic ganglion of turtle, showing white rami fibers wound spirally about a large process of a unipolar cell, and ending in pericellular plexus (Huber, *Journal of Morphology*, 1899).

neuraxes leaving the cerebrospinal axis through the white rami as small medullated nerve-fibers, which terminate in pericellular plexuses inclosing the cell-bodies of the sympathetic neurones.

Large medullated nerve-fibers, the dendrites of spinal ganglion neurones, reach the sympathetic ganglia through the white rami.

Fig. 345.—From section of sympathetic ganglion of frog, showing spiral fiber (white ramus fiber) and pericellular plexus (Huber, *Journal of Morphology*, 1899).

They make, however, no connection with the sympathetic neurones, but pass through the ganglia to reach the viscera, where they terminate in special sensory nerve-endings or in free sensory nerve-endings.

G. GENERAL SURVEY OF THE RELATIONS OF THE NEURONES TO ONE ANOTHER IN THE CENTRAL NERVOUS SYSTEM.

The following figures illustrate the modern theories with regard to the relationship of the neurones in a sensorimotor reflex cycle. The pathway along which the impulse from the stimulated area of the body is transmitted to the motor nerve end-organ traverses two neurones (primary neurones) which are in contact by means of their telodendria situated within the gray matter of the spinal cord. The cell-body of the sensory neurone lies within the spinal ganglion; that of the motor neurone, in the anterior horn of the spinal cord. The dendrite of the sensory neurone commences

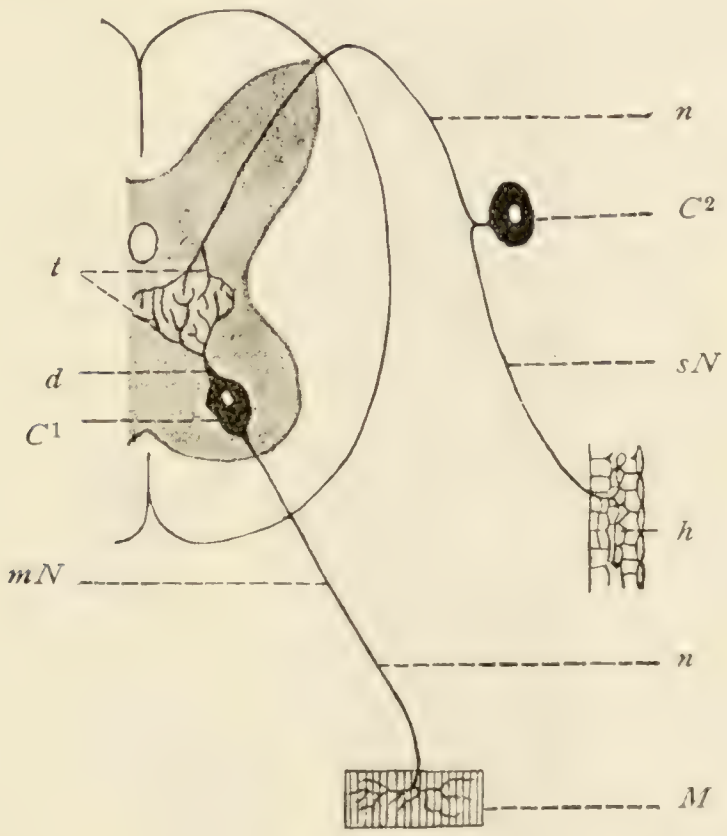

Fig. 346.—Schematic diagram of a sensorimotor reflex arc according to the modern neurone theory; transverse section of spinal cord: *mN*, Motor neurone; *sN*, sensory neurone; C^1, nerve-cell of the motor neurone; C^2, nerve-cell of the sensory neurone; *d*, dendrite; *n*, neuraxis of both neurones; *t*, telodendria; *M*, muscle-fiber; *h*, skin with peripheral telodendrion of sensory neurone.

as a telodendrion in the skin or perhaps also in more deeply seated structures, and transmits a cellulipetal impulse, while its cellulifugal neuraxis and telodendrion (the latter in the gray matter of the cord) transfer the impulse to the cellulipetal telodendrion of the motor neurone. The cellulifugal neuraxis of the latter finally ends as a telodendrion in the muscle. (Figs. 346 and 347.)

In the case of longer tracts the conditions are somewhat more complicated, as, for instance, in tracing the impulse along the sensory fibers to the cortex of the brain, and from there along the motor fibers to the responding muscle. In such cases secondary neurones are called into play by means of their telodendria, which are necessarily in contact with the primary neurones just described.

When we take into consideration the simplest possible case, that of the motor segment of such a neurone-chain, we find, for instance (Fig. 348), that the neuraxis of a pyramidal cell in the brain cortex (psychic cell) enters the white substance and traverses it as a nerve-fiber through the peduncle and the pyramid into the crossed pyramidal tract of the opposite side. Here its telodendria come in contact with those of the motor neurone of the anterior horn.

In the foregoing instance the motor nerve tract is composed of two neurones—of a motor neurone of the first order, extending from the cortex of the brain to the anterior cornua of the spinal cord, and of a motor neurone of the second order, the elements of which extend from the anterior cornua to the telodendria in the muscle.

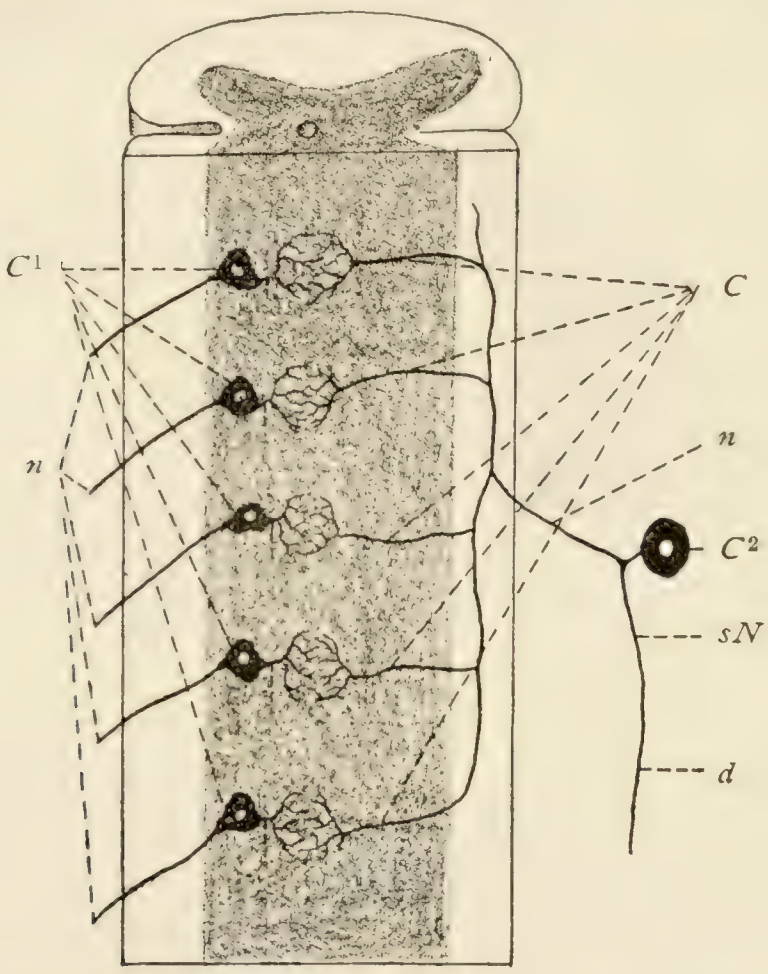

Fig. 347.—Schematic diagram of a sensorimotor reflex cycle; sagittal section of the spinal cord: C^1, Motor cells of the anterior cornua; n, n, neuraxes; sN, sensory neurone; C^2, spinal ganglion cell; C, collaterals of the sensory neuraxes; d, dendrite of sensory neurone; the broken lines at the cells on the left indicate their dendrites.

The sensory tract may likewise be composed of neurones of the first and second orders. The cellulifugal neuraxis arising from a cell of the spinal ganglion passes to the posterior column of the cord, gives off collaterals to the latter, and then passes upward by means of its ascending branch through the posterior column to the medulla. Although here the relationship is not so clearly defined as in the motor tract, it may nevertheless be assumed that the cellulifugal (but centripetally conducting) neuraxis at some point or other terminates in telodendria (sensory neurone of the first order), which enter into contact with the corresponding structures of a cell of the spinal cord or medulla oblongata. These cells would then

constitute the sensory neurones of the second order. Exactly how their cellulifugal neuraxes end has not as yet been fully determined, but it is very probable that in this case the telodendria are represented by the coarse end-fibers which penetrate into the brain cortex, and here seem to come in contact with the dendrites of the pyramidal cells.

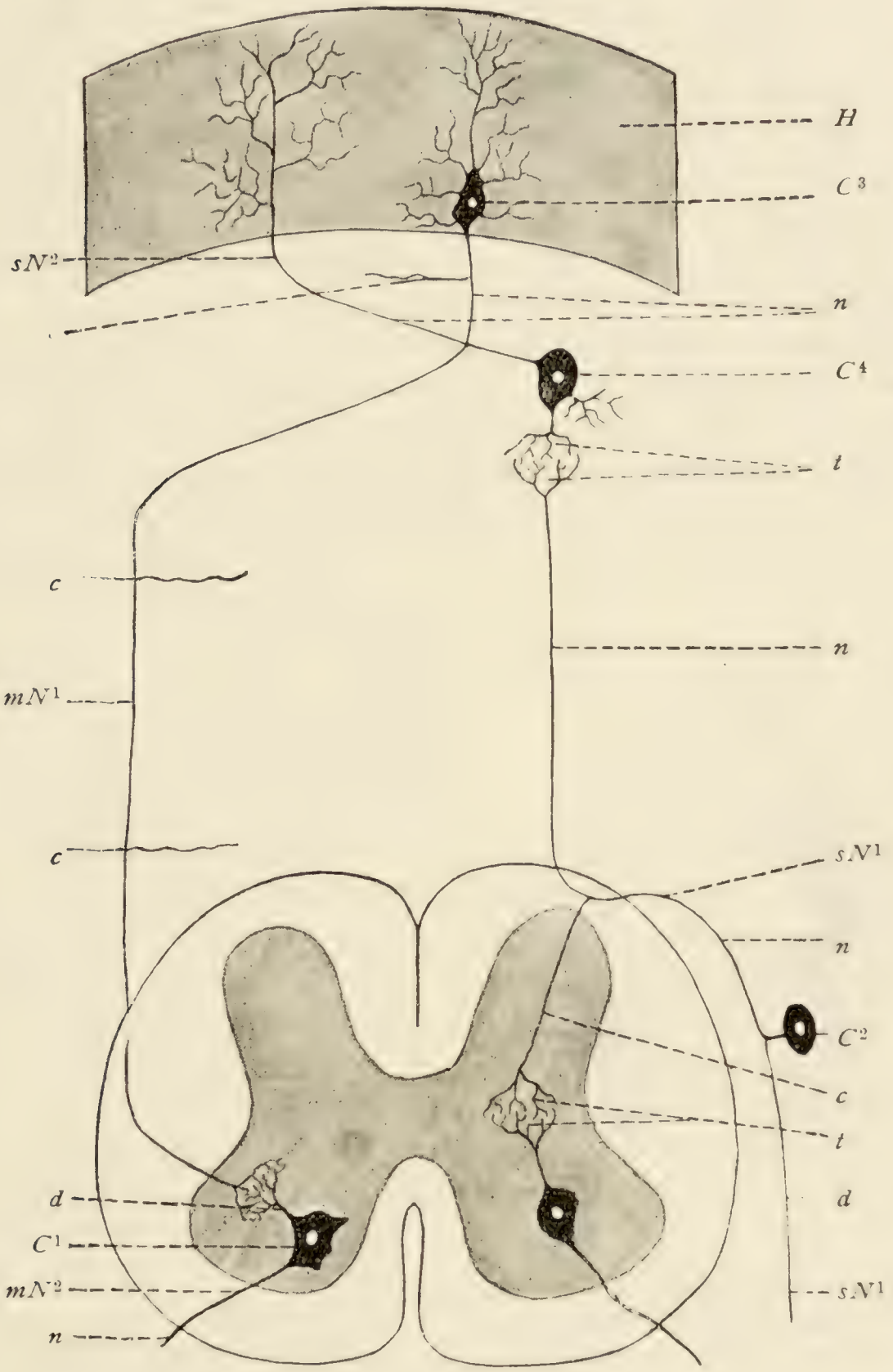

Fig. 348.—Schematic diagram of the reflex tracts between a peripheral organ and the brain cortex: *H*, Cerebral cortex; mN^1, motor neurone of the first, sN^2, sensory neurone of the second, degree; C^1, motor cell of the spinal cord; C^2, sensory cell of a spinal ganglion; C^3, pyramidal cell of the brain cortex (pyschic cell); C^4, nerve-cell of a sensory neurone of the second degree; *n*, *n*, *n*, *n*, neuraxes; *d*, *d*, dendrites; *c*, *c*, *c*, *c*, collaterals; *t*, *t*, telodendria; sN^1, sensory neurone first degree; mN^2, motor neurone second degree.

H. THE NEUROGLIA.

The neuroglia tissue is an especially differentiated supporting tissue found in the central nervous system, the optic chiasm, optic nerve and retina and for some distance, at least, in the olfactory nerve. Its relation to other tissues has long been a matter of controversy, but modern observers have shown quite conclusively that neuroglia tissue is of ectodermal origin. It should not be understood, however, that the neuroglia tissue forms the only supporting tissue of the central nervous system. In all parts of the central nervous system, more especially, however, in the spinal cord, there is found true connective tissue of mesoblastic origin, more especially in connection with the blood-vessels.

At an early stage of embryonic development there are seen in the spinal cord, and also in the brain, elements radially disposed around the neural canal, which upon closer observation appear to be processes emanating from the epithelial cells lining the neural canal. These processes may undergo repeated dichotomous division, ending finally in a swelling near the periphery of the cord. These cells are known as ependymal cells, and are differentiated from ectodermal cells, called **spongioblasts.** In later stages the radial arrangement is still preserved, but the cell-bodies no longer all border upon the central canal, many being found at varying distances from the latter. At this stage in the development of the spinal cord, the elements retaining their original characteristics are situated only in the region of the ventral and dorsal fissures of the spinal cord, and during further development increase in number.

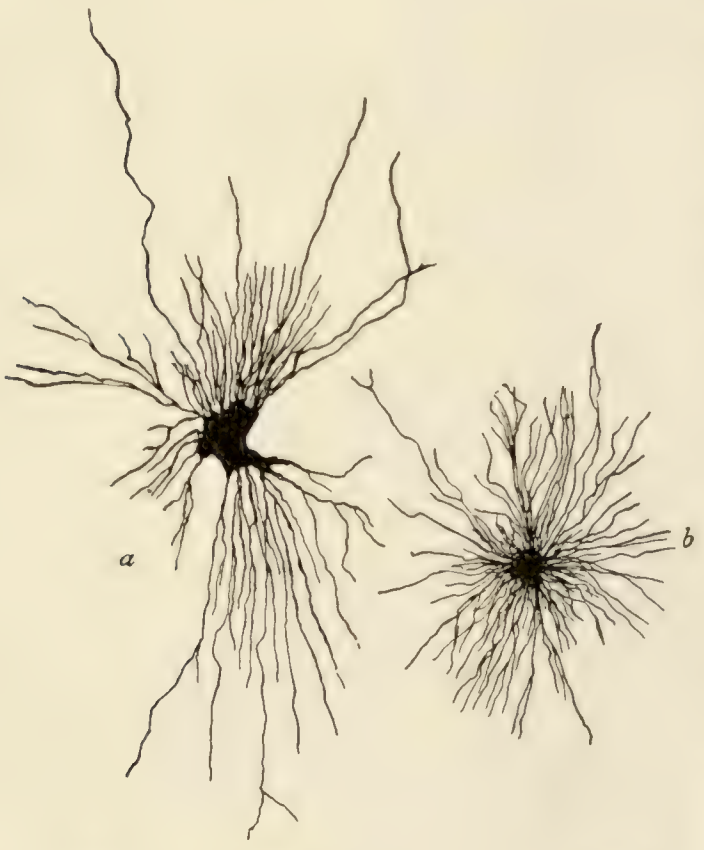

Fig. 349.—Neurogliar cells : *a*, From spinal cord of embryo cat ; *b*, from brain of adult cat ; stained in chrome-silver.

These observations would seem to indicate that at least a portion of the neurogliar cells, which develop from the ependymal cells previously mentioned, originate from the epithelium of the central canal, and that from here they are gradually pushed toward the periphery of the cord. This assumption is still further strengthened by the fact that later the epithelial cells of the central canal still continue to divide. Later observations (Schaper, 97) show, however, that neurogliar cells develop also from certain undifferentiated germinal cells of the neural canal, of ectodermal origin, which

wander from their position near the neural canal toward the periphery of the medullary tube, where they develop into neuroglia cells.

Owing to the fact that of the several methods now at hand for studying neuroglia tissue no two give identical results, the views concerning this tissue are still at variance. The Golgi or chrome-silver method was for many years the only method by means of which the elements of neuroglia tissue were brought to light with any degree of clearness. In preparations of the central nervous system treated with this method all the neuroglia elements appear as cells with processes. The cell bodies of these cells as also the processes being stained black or nearly black (as seen with transmitted light) so that the relations of the processes to the cellular constituents can not be ascertained, investigators who have made use of this method in their study of neuroglia distinguish two essentially different cellular elements of the neuroglia: ependymal cells, previously mentioned, and neuroglia cells, so-called spider cells or astrocytes. The astrocytes are grouped under two main heads: short-rayed astrocytes, possessing a few short processes, found in the gray matter, and long-rayed astrocytes with many fine and long processes, which do not appear to branch, found both in the gray and white matter. The two types of astrocytes are not clearly defined, as intermediate types are also found. In figure 349 are shown two astrocytes (long-rayed) as seen in chrome-silver preparations.

A number of investigators have in recent years perfected methods by means of which neuroglia tissue could be stained differentially—Weigert, Mallory, Benda. In tissues treated after any one of these rather complicated differential staining methods the processes of the neuroglia cells as seen in chrome-silver preparations appear in the form of well-contoured fibrils, which are not interrupted by the cell-bodies of the neuroglia cells, from which they are either entirely separated or are seen to pass through the protoplasm of the cells without losing their identity. In preparations of the central nervous system stained after Benda's differential neuroglia tissue staining method, numerous neuroglia cells may be observed both in the gray and white matter. Certain of these cells possess very little protoplasm, others—and these are in the majority—present it to an appreciable extent. The shape of such cells varies. When situated in the main mass of the white matter of the spinal cord, and seen in cross-sections of the cord, they present an irregular triangular and quadrangular form, with protoplasmic branches which arise from the angles and which extend for a variable distance between the nerve-fibers. In such preparations it may be seen that the neuroglia fibers pass in close proximity to the neuroglia cells, apparently embedded in the outermost part of their protoplasm, and often following the protoplasmic processes. This view of the structure of neurogliar tissue is more in accord with recent investigations on this

subject (Weigert, Mallory, Benda, Krause, Hardesty, Huber). In figure 350 are shown two neuroglia cells from a cross-section of a human spinal cord, in which the relation of neuroglia fibers to neuroglia cells is shown.

Fig. 350.—Typical neuroglia cells, from cross-section of the white matter of the human spinal cord, stained after Benda's selective neuroglia tissue staining method; × 1200 (Huber, "Studies on Neuroglia Tissue," *Vaughan Festschrift*, 1903).

I. THE MEMBRANES OF THE CENTRAL NERVOUS SYSTEM.

The membranes of the central nervous system (meninges) are three in number: the outer, or *dura mater;* the middle, or *arachnoid;* and the inner, or *pia mater.*

Around the brain the **dura mater** is very intimately connected with the periosteum and presents a smooth inner surface. It consists of an inner and an outer layer, the two being separated from each other only in certain regions. At such points either the inner layer is pushed inward to form a duplicature, as in the falx cerebri and falx cerebelli, tentorium, and diaphragma sellæ, or the outer layer is pushed outward to form small, blindly ending sacs. The venous and lymphatic sinuses lie between the two layers. The outer

layer of the dura is continued some distance along the cerebrospinal nerves.

The dura mater of the spinal cord does not form the periosteum for the bones forming the vertebral canal ; these possess their own periosteum. The spinal dura mater is covered on its outer surface by a layer of endothelial cells and is separated from the wall of the vertebral canal by the *epidural space*, containing a venous plexus imbedded in loose areolar connective tissue and adipose tissue.

The dura consists chiefly of connective-tissue bundles having a longitudinal direction along the spinal cord. Within the cranium, however, the bundles of the inner and outer layers cross each other ; those of the outer having a lateral direction anteriorly and a mesial posteriorly ; those of the inner, a mesial direction anteriorly and a lateral posteriorly. In the falx cerebri, tentorium, etc., the fibers are arranged radially, extending from their origin toward their borders. The shape and size of the connective-tissue cells vary greatly, and their processes form a network around the bundles of connective tissue. Few elastic fibers are present, and, according to K. Schultz, these are entirely absent in the new-born ; they are somewhat more numerous in the dura of the spinal cord. The dura is very rich in blood-capillaries, and the presence of lymphatic channels in communication with the subdural space may be demonstrated by means of puncture-injections. The inner surface of the dura mater is covered by a layer of endothelial cells.

The dura mater is quite richly supplied with nerves, especially in certain regions. These are of two varieties : (1) Vasomotor fibers, which form plexuses in the adventitial coat of the arteries, and would seem to terminate in the muscular coat of the arteries ; (2) medullated nerve-fibers, which either accompany the blood-vessels in the form of larger or smaller bundles or have a course independent of the vessels. After repeated division these medullated nerve-fibers lose their medullary sheaths and terminate between the connective-tissue bundles in fine varicose fibrils, which may often be traced for long distances (Huber, 99).

The **arachnoid** is separated from the dura by a space which is regarded as belonging to the lymphatic system—the *subdural space*. The outer boundary of the arachnoid consists, as does the inner lining of the dura, of a layer of flattened endothelial cells. The arachnoid is made up of a feltwork of loosely arranged connective-tissue trabeculæ, which also penetrate into the lymph-space between it and the pia—the *subarachnoid space*. For a short distance from their points of origin the cerebrospinal nerves are accompanied by arachnoid tissue. In the brain the arachnoid covers the convolutions and penetrates with its processes into the sulci. These processes are especially well developed in the so-called cisterns ; in the cisterna cerebellomedullaris, fossæ Sylvii, etc. In the spinal cord the subarachnoid space is separated by the ligamenta denticulata into two large communicating spaces—a dorsal and a ven-

tral. The dorsal space is further divided by the *septum posticum*, best developed in the cervical region.

At certain points, usually along the superior longitudinal sinus, the outer surface of the arachnoid is raised into villi, which are covered by the inner layer of the dura, and form with the latter the **Pacchionian bodies** or granulations. These villi are connected with the arachnoid by pedicles so delicate that they often seem to be suspended free in the venous current of the sinus.

The subarachnoid space contains numerous blood-vessels, some of which are free and others attached to the arachnoid. Their adventitia is covered by endothelium; hence the subarachnoid space would seem to assume here the character of a perivascular space.

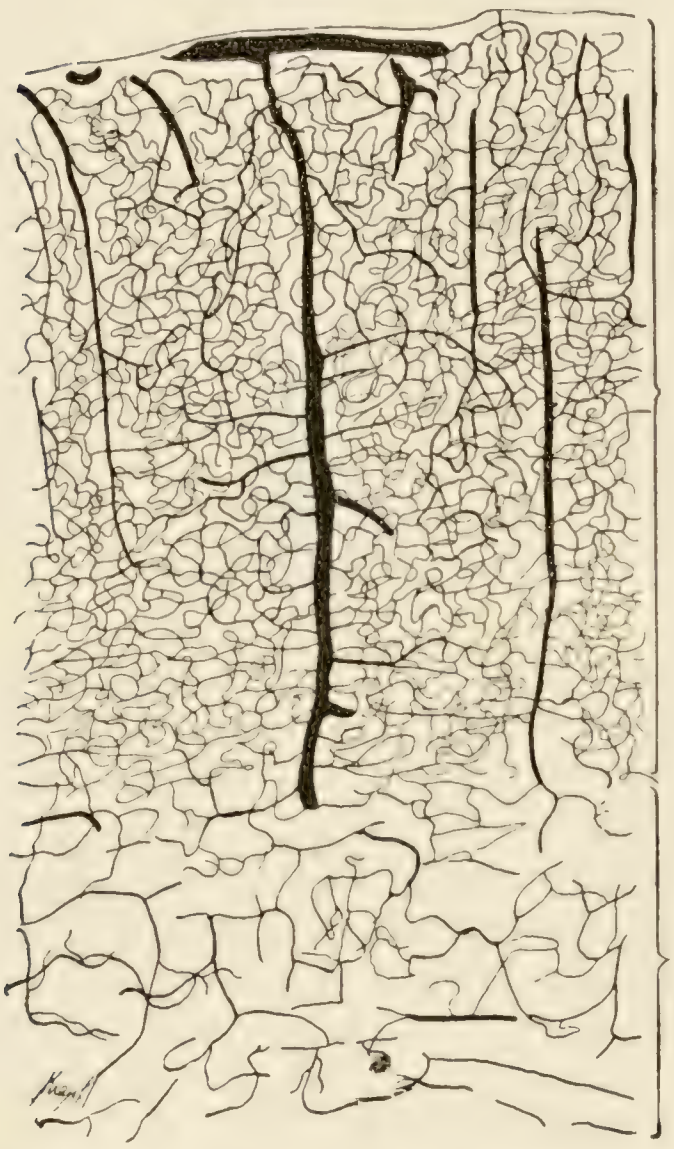

Fig. 351.—Section through the cerebral cortex of a rabbit. The blood-vessels are injected; × 40.

The trabeculæ and membranes composing the arachnoid tissue show a great similarity to those of the mesentery, and especially to those of the omentum. The whole constitutes a typical areolar connective tissue, interrupted at numerous points and covered by a continuous layer of endothelial cells. Large numbers of spiral fibers are found here twining around single or groups of connective-tissue fibers. The arachnoid possesses neither blood-vessels nor nerves.

The **pia mater** covers the entire surface of the brain and spinal cord, dipping down into every fissure and crevice. In the spinal cord it consists of an outer and an inner lamella, the former being composed of bundles of connective tissue containing elastic fibers. As a rule, the course of the fibers is longitudinal. Externally this layer is covered by a layer of endothelium. The blood-vessels lie between the outer and inner layers of the pia. The inner layer (pia intima) is made up of much finer elements, and is covered on both sides by endothelium. It is this layer which accompanies the blood-vessels penetrating into the spinal cord, surrounding their adventitia and forming with the latter the limits of their perivascular spaces. These are in communication with the

interpial spaces, and, by means of the adventitia of the blood-vessels, with the subarachnoid space. Aside from those just described, numerous fine, nonvascular, connective-tissue septa penetrate from the pia mater into the substance of the spinal cord. Wherever the pia mater penetrates the spinal cord, the latter is hollowed out, forming the so-called *pial funnels*. Just beneath the pia there is found in the spinal cord of man a well-developed layer of neuroglia fibers. The posterior longitudinal septum of the spinal cord consists (in the thoracic region) exclusively of neurogliar elements, but in the cervical and lumbar regions the pia also enters into its peripheral formation.

In the brain, however, the conditions are somewhat different. Here the external layer of the pia disappears, leaving only a single layer analogous to the pia intima of the spinal cord.

The pia mater enters into the formation of the **choroid plexus**. This structure consists of numerous freely anastomosing blood-vessels, which form villus-like processes, the surfaces of which are covered by squamous or cubic epithelial cells. This epithelium is regarded as a continuation of the ventricular epithelium, and is ciliated, at least in embryonic life and in the lower classes of vertebrates. From an embryologic point of view the whole structure represents the brain-wall reduced to a single layer of epithelium (internal epithelial investment) pushed forward into the ventricle by the vessels and pia mater.

Since the dura and arachnoid accompany the cerebrospinal nerves for some distance, it is obvious that the lymph-vessels of the nasal mucous membrane (see these) may also be injected from the subarachnoid space (compare also Key and Retzius).

The pia mater, like the dura mater, receives two varieties of nerve-fibers : (1) Vasomotor fibers, which form plexuses in the adventitial coat of the arteries and terminate in the muscular layer of the arteries. These may be traced to the small precapillary branches of the vessels. (2) Larger and smaller bundles of relatively large, medullated nerve-fibers, which accompany the larger pial vessels, forming loose plexuses in or on the adventitial coat of the vessels. After repeated divisions these medullated nerves lose their medullary sheaths and terminate in the adventitia of the vessels, in long, varicose fibrils or in groups of such fibrils (Huber, 99).

J. BLOOD-VESSELS OF THE CENTRAL NERVOUS SYSTEM.

The blood-vessels of the central nervous system present certain peculiarities which deserve special consideration.

The spinal cord receives its arterial blood mainly through vessels which accompany the spinal nerve roots and through numerous anastomoses from a plexus in the pia mater in which there may be

recognized a median ventral unpaired line of anastomosis and along each half of the spinal cord four other lines of anastomosis. From the median unpaired line of anastomosis some 200 to 250 branches pass into the anterior fissure, each of which generally divides into a right and left branch just in front of the commissure, each branch being distributed to the gray matter in its immediate vicinity. The white matter receives its blood-supply from vessels of the plexus in the pia mater, from which numerous fine branches are given off which terminate in capillary networks and extend as far as the gray matter. The veins return the blood to the veins of the pia mater, following in the main the course of the arteries. The central and peripheral arteries do not anastomose except through capillaries and now and then precapillaries (Adamkiewicz and Kadyi).

In the cerebral cortex the capillaries are particularly numerous, and are closely meshed wherever groups of ganglion cells occur. In the medullary substance they are somewhat less closely arranged, their meshes being oblong. In the cerebellum the arrangement is analogous. Of all the layers composing the cerebellum the granular is the most vascular; within it the capillaries are also densely arranged and form a close network.

Lymphatic vessels with definitive walls have thus far not been discovered in the central nervous system. The blood-vessels through the central nervous system are, however, surrounded by perivascular spaces, which may be regarded as performing the function of lymphatic vessels.

TECHNIC.

The organs of the central nervous system are best fixed in Müller's fluid, washed with water, cut in celloidin, and stained with carmin. Such preparations are suitable for general topographic work.

Special structures—as, for instance, the medullary sheaths of the nerve-fibers, the ganglion cells, the relations of the different neurones and dendrites to one another, etc.—require different treatment.

The **medullary sheath** may be demonstrated as follows (Weigert): Pieces of tissue (spinal cord, for instance), fixed as usual in Müller's or Erlicki's fluid, are transferred without washing to alcohol, imbedded in celloidin, and cut. Before staining the sections it is necessary to subject them to the mordant action of a neutral copper acetate solution (a saturated solution of the salt diluted with an equal volume of water). The sections may be subjected to the mordant action of this solution, but the following procedure is more convenient: The specimens, imbedded in celloidin and fastened to a cork or a block of wood, are placed for one or two days in the copper solution just described. At the expiration of this time the pieces of tissue will have become dark, and the surrounding celloidin light green. They are then placed in 80% alcohol, in which they may be preserved for any length of time. The sections are then stained in the following solution: 1 gm. of hematoxylin is dissolved in 10 c.c. absolute alcohol, and 90 c.c. of distilled water are then added (the fluid must remain exposed to the air for a few days); the addition of an alkali—as, for instance, a cold satu-

rated solution of lithium bicarbonate (1. c.c. to 100 c.c. of hematoxylin solution)—brings out the staining power of the solution at once. In this stain the sections are placed (at room-temperature) for a day, and then in a thermostat (40° C.) for a few hours. The sections, now quite dark, are washed in distilled water and then placed in the so-called differentiating fluid. The latter consists of borax 2 gm., ferrocyanid of potassium 2.5 gm., and distilled water 100 gm. In this fluid the color of the sections is differentiated by virtue of the circumstance that the medullary sheath retains the dark stain, while the remaining structures, such as the ganglion cells, etc., are bleached to a pale yellow. The time required for this differentiation varies, but it is usually complete at the end of a few minutes. The sections are then washed in distilled water, dehydrated in alcohol, cleared in carbol-xylol (carbolic acid 1 part, xylol 3 parts) and mounted in balsam.

Weigert's new method is more complicated, but fruitful of correspondingly better results. The preliminary treatment remains the same. After the tissues have been imbedded in celloidin and this hardened in 80% alcohol, they are transferred to a mixture composed of equal parts of a cold saturated aqueous solution of neutral copper acetate and 10% aqueous solution of sodium and potassium tartrate, and the whole is placed in the thermostat. Larger pieces—as, for instance, the pons Varolii of man—may remain in the solution longer than twenty-four hours, after which time, however, the mixture must be changed; but in no case should the specimens be permitted to remain longer than forty-eight hours in this solution. The temperature in the thermostat should not be high, otherwise the specimens will become brittle. The objects are now placed in a simple aqueous solution of neutral copper acetate, either saturated or half diluted with water, and again put in the oven. They are then rinsed in distilled water and placed in 80% alcohol; after remaining in this for one hour, they are in a condition to cut, but may be preserved still longer if desired. Cut and stain in the customary manner. The staining solution is prepared as follows: (*a*) lithium carbonate 7 c.c. and distilled water 93 c.c. (saturated aqueous solution); (*b*) hematoxylin 1 gm., absolute alcohol 10 c.c.; both *a* and *b* keep for some time, and may be kept on hand as stock solutions. Shortly before using, 9 parts of *a* and 1 part of *b* are mixed. After remaining in this solution for from four to five hours at room-temperature the sections are well stained, but do not overstain even if allowed to remain in the solution for twenty-four hours. In the case of loose celloidin sections the use of the differentiating fluid is superfluous. Hence this method is particularly advantageous when the gray and the white matter can not be distinguished macroscopically. Finally, the sections are washed in water, placed in 95% alcohol, cleared with carbol-xylol or anilin-xylol (in the latter case carefully washed with xylol), and mounted in xylol-balsam. The medullated fibers appear dark blue to black, the background pale or light pink, and the celloidin occasionally bluish. In order to remove the latter color, it is only necessary to wash the sections in 0.5% acetic acid instead of ordinary water; a process, however, not to be recommended in the case of very delicate preparations—as, for instance, the cerebral cortex. In applying Weigert's methods a certain thickness of section (not exceeding 25 μ) is essential, since in thicker sections the medullary sheaths are not sharply differentiated from the surrounding tissue.

For thick sections the modified Weigert method, or **Pal's method,** is employed. After the specimens have been treated according to Weigert's method up to the point of staining with hematoxylin, they are placed for from twenty to thirty minutes in a 0.25% solution of potassium permanganate. As differentiating fluid a solution of oxalic acid 1 gm., potassium sulphite 1 gm., and water 200 c.c. is used, care being taken, as in the case of Weigert's differentiating fluid, that the gray matter is thoroughly bleached (here entirely colorless) and the white matter dark. By this method the medullary sheaths are stained blue, while the rest of the structure remains colorless. The staining is very precise, but not so intense as by Weigert's method. Hence its adaptability for thicker sections.

Benda's method is a modification of the Weigert-Pal methods. The tissues are hardened in Müller's or Erlicki's fluid, imbedded in celloidin, and cut. The sections are then subjected to the action of the following mordant for from twelve to twenty-four hours: liquor ferri ter sulphatis 1 part, distilled water 2 parts. They are then thoroughly rinsed in two tap-waters and one distilled water and then stained in the following hematoxylin solution: hematoxylin 1 gm., absolute alcohol 10 c.c., distilled water 90 c.c.; in which they remain for twenty-four hours. They are next washed in tap-water for from ten to fifteen minutes and treated with a 0.25% aqueous solution of permanganate of potassium until the gray and the white matter are differentiated, after which they are rinsed in distilled water and bleached in the following solution until the gray matter has a light yellow color: hydric sulphite 5 to 10 parts, distilled water 100 parts. The sections are then washed in tap-water for from one to two hours, rinsed in distilled water, dehydrated, cleared in carbol-xylol, and mounted in balsam. Medullary sheaths will be stained a bluish-black; other structures, a light yellow. Sections stained after the Weigert, Pal, or Benda method may be counterstained in Van Gieson's picric-acid-fuchsin stain (1% aqueous solution of acid fuchsin, 15 parts; saturated aqueous solution of picric acid, 50 parts; distilled water, 50 parts). The fibrous connective tissue in the sections and degenerated areas stains a light red.

Apáthy (97) demonstrates the **fibrillar elements** of the nervous system in invertebrates and vertebrates by means of his gold method. Fresh tissue may be used, or tissue already fixed. In the first case thin membranes are placed for at least two hours in a 1% solution of yellow chlorid of gold in the dark, then carried over without washing into a 1% solution of formic acid (sp. gr. 1.223), and finally exposed for from six to eight hours to the light (the formic acid may have to be changed). These specimens are best mounted directly in syrup of acacia or in concentrated glycerin. In his second method Apáthy fixes vertebrate tissues for twenty-four hours in sublimate-osmic acid (1 vol. saturated solution of corrosive sublimate in 0.5% sodium chlorid solution combined with 1 vol. 1% osmic acid solution), washes repeatedly in water, and places for twelve hours in an aqueous iodo-iodid of potassium solution (potassium iodid 1% and iodin 0.5%). The further treatment is the same as after ordinary corrosive sublimate fixation. Finally, the specimens are imbedded in paraffin with the aid of chloroform, cut, and mounted by the water method. The whole process, up to the point of imbedding in paraffin, is carried out in the dark. The sections are then passed through chloro-

form and alcohol into water, where they are allowed to remain for at least six hours; or they may be washed in water, placed for one minute in 1% formic acid, again washed in water, immersed for twenty-four hours in a 1% solution of gold chlorid, rinsed in water, and finally placed in a 1% formic acid solution and exposed to the light. For the latter purpose glass tubes are employed in which the slides are placed obliquely, with the sections downward. A uniform illumination of the section with "as intense a light and low a temperature" as possible are conditions indispensable to the attainment of successful results. The sections are then again washed in water and mounted in glycerin or syrup of acacia, or in Canada balsam after being dehydrated. Thin membranes are stretched upon small frames of linden wood especially prepared for this purpose. Their further treatment is then the same as that of sections fixed to the slide. If successful, the nerve-fibrils appear dark violet to black. The large ganglia in the spinal cord of lophius, the calf, etc., are especially recommended as appropriate vertebrate material.

Bethe (1900) has recommended the following method for staining **neurofibrils** and **Golgi-nets** in the central nervous system of vertebrates:

The perfectly fresh tissue is cut in thin lamellæ, varying in thickness from 4 to 10 mm. These are placed on pieces of filter-paper and then in 3 to 7.5% nitric acid, in which they remain twenty-four hours. From the hardening fluid the pieces of tissue are transferred into 96% alcohol, where they remain for from twelve to twenty-four hours. They are then placed in a solution of ammonium-alcohol,—ammonium (sp. gr. 0.95 to 0.96), 1 part; distilled water, 3 parts; 96% alcohol, 8 parts,—in which they remain for from twelve to twenty-four hours. The temperature of this solution should not exceed 20° C. The tissues are then placed for from six to twelve hours in 96% alcohol, and next in a hydrochloric acid-alcohol solution,—concentrated hydrochloric acid (sp. gr. 1.18—37%), 1 part; distilled water, 3 parts; and 96% alcohol, 8 to 12 parts,—in which they remain for several hours. The temperature of this solution should not exceed 20° C. The tissues are then again placed in 96% alcohol for from ten to twenty-four hours, and next in distilled water for from two to six hours. The tissues are now placed for twenty-four hours in a 4% aqueous solution of ammonium molybdate. (This solution should be kept at a temperature varying from 10° to 15° C., if it is desired to stain the neurofibrils; or at a temperature varying from 10° to 30° C., if it is desired to bring out the Golgi-nets.) After the ammonium molybdate treatment, the tissues are rinsed in distilled water, placed in 96% alcohol for from ten to twenty-four hours, then in absolute alcohol for a like period, cleared in xylol or toluol, and imbedded in paraffin. Sections having a thickness of 10 μ are now cut and fixed to slides with Mayer's albumin-glycerin. Since the various solutions used in the fixation and further treatment of the tissues do not act with the same intensity on all parts of the piece of tissue to be studied, and since the differentiation and staining depend on a relative proportion (not yet fully determined) of the mordant (ammonium molybdate) and the stain in a given section, it is advised by Bethe to cut large numbers of sections and fix to each slide about three sections from different parts of the series. After fixation of the sections to the slide the paraffin is removed with xylol; and they are then carried through absolute alcohol into distilled water, in which, however, the sections remain only long enough to re-

move the alcohol. The slides (with the sections fixed to them) are then taken from the water and rinsed with distilled water from a water-bottle. The slide is then wiped dry on its under surface and edges with a clean cloth, and about 1 c.c. to 1.5 c.c. of distilled water placed on the slide over the sections. The slides are now placed in a warm oven with a temperature of 55° C. to 60° C. for a period of time varying from two to ten minutes. No definite time can here be given; sections from each block of tissue need to be tested until the right stay in the warm oven is ascertained. The slides are then taken from the warm oven and rinsed two or three times in distilled water and again dried as previously directed. They are then covered with the following staining solution and again placed in the warm oven for about ten minutes: toluidin-blue, 1 part; distilled water, 3000 parts. The stain is washed off with distilled water and the sections are placed in 96% alcohol until no more stain is given off—usually for from three-fourths to two minutes. They are then dehydrated in absolute alcohol, passed through xylol twice, and mounted in xylol balsam. For a fuller discussion of this method the reader is referred to Bethe's account in "Zeitsch. f. Wissensch. Mikrosk.," vol. XVII, 1900.

For staining **neuroglia** Weigert (95) has recommended a method, from which we give the following: A solution is made consisting of 5% neutral acetate of copper, 5% ordinary acetic acid, and 2.5% chrome-alum in water. The chrome-alum and water are first boiled together, the acetic acid then added, and finally the finely pulverized neutral copper acetate, after which the mixture is thoroughly stirred and allowed to cool. To this solution 10% formalin may be added. Objects not over 0.5 cm. in diameter are placed in this fluid for eight days, the mixture being changed at the end of a few days. By this means the pieces of tissue are at the same time fixed and prepared for subsequent staining by the action of the mordant. If separation of the two processes be desired, the specimens are fixed for about four days in a 10% formalin solution (which is changed in a few days), and then placed in the chrome-alum mixture without the addition of formalin. Specimens thus fixed may be preserved for years without disadvantage, and may then be subjected to further treatment by other methods, Golgi's for instance. Washing with water, dehydration in alcohol, and imbedding in celloidin are the next steps. The sections are then placed for about ten minutes in a 0.33% solution of potassium permanganate, washed by pouring water over them, and placed in the reducing fluid (5% chromogen and 5% formic acid of a specific gravity of 1.20; then filter carefully, and add 10 c.c. of a 10% solution of sodium sulphite to 90 c.c. of the fluid). The sections, rendered brown by the potassium permanganate, readily decolorize in a few minutes, but it is better to leave them for from two to four hours in the solution. If it be desirable to decolorize entirely the connective tissue, no further steps need be taken preliminary to staining; if not, the reducing fluid is poured off and the sections are rinsed twice in water and then placed in an ordinary saturated solution of chromogen (5% chromogen in distilled water, carefully filtered). The sections are left in this solution overnight, and the longer they remain in it, the more marked will be the contrast, as far as stain is concerned, between the connective and nervous tissues; then water is again twice poured upon the sections and they are ready for staining. This process consists in a

modified fibrin stain (*vid.* Technic). The iodo-iodid of potassium solution is the same (saturated solution of iodin in a 5% iodid of potassium solution). Instead of the customary gentian-violet solution, a hot saturated alcoholic (70% to 80% alcohol) solution of methyl-violet is made, and, after cooling, the clear portion decanted off; to every 100 c.c. of this fluid 5 c.c. of a 5% aqueous solution of oxalic acid is added. The staining takes place in a very short time. The sections are then rinsed and normal salt solution and the iodo-iodid of potassium solution poured over them (5% iodid of potassium solution saturated with iodin), and washed off with water and dried with filter-paper and decolorized in the anilin oil-xylol solution in the proportion of 1:1. The reactions are rapid, and the thickness of the section should not exceed 20 μ. This method is best adapted to the central nervous system of the human adult; it has as yet not been sufficiently tested for other vertebrates.

Mallory's Selective Neuroglia Fiber-Staining Methods.—Fix tissues in 10% formalin four days; place in saturated aqueous solution of picric acid four days; place in 5% aqueous solution of ammonium bichromate four to six days in warm oven at 38° C.; dehydrate and imbed in cell-oidin; sections may be stained in Weigert's fibrin stain and differentiated with equal parts of anilin oil and xylol, or they may be treated as follows: Place sections in 0.5% aqueous solution of permanganate of potassium twenty minutes; wash in distilled water one to three minutes; place in 1% aqueous solution of oxalic acid thirty minutes; wash in distilled water; stain in phosphotungstic-acid-hematoxylin solution (hematoxylin 1 g., distilled water 80 c.c., 10% aqueous solution of phosphotungstic acid [Merk], 20 c.c., peroxid of hydrogen [U.S.P.], 2 c.c.) for twelve to twenty-four hours; rinse in distilled water and place for five to twenty minutes in an alcoholic solution of ferric chlorid (ferric chlorid 30 g., 30% alcohol 100 c.c.); rinse in distilled water and dehydrate quickly, clear in oil of bergamot, and mount in xylol-balsam.

Benda's Selective Neuroglia Staining Method.—Benda has for some years concerned himself with perfecting selective staining methods for differentiating certain constituents of the protoplasm of cells, and has recently published a number of staining methods, by all of which neuroglia fibers may be more or less successfully differentiated. According to him, certain hematoxylin solutions, used after proper fixation and mordanting of the tissues, may be used for neuroglia stains; also hematoxylin staining, followed by staining with an acid-anilin water crystal violet solution. These will not be considered here. We wish, however, to call especial attention to the following method for staining neuroglia tissue, suggested by Benda, since it has certain advantages not possessed by other selective neuroglia stains. Fix small pieces of tissue in 10% formalin; place in Weigert's chrome-alum solution (formula given above), four days in warm oven at 38° C.; wash in water twenty-four hours; dehydrate in graded alcohols; imbed in paraffin; cut thin sections and fix these to slides with the albumin-glycerin fixative; remove paraffin and place sections in mordant consisting of a 4% aqueous solution of ferric alum; rinse thoroughly in two tap waters and one distilled water; place in a sodium sulphalizarate solution (add to distilled water a sufficient quantity of a saturated solution of sodium sulphalizarate in 70% alcohol to give it a sulphur-yellow color) twenty-four hours; rinse in distilled water; stain for fifteen minutes in a 0.1% aqueous solution toluidin blue, which should be heated after

the sections are in the stain until the solution steams; allow the stain to cool; rinse in distilled water; wash in a 1% aqueous solution of glacial acetic acid for a few seconds or in acid alcohol (six drops of hydrochloric acid; 70% alcohol 100 c.c.) for a few seconds; dry sections with filter-paper; dip sections a few times in absolute alcohol; differentiate in creosote, ten minutes to an hour—control now and then under the microscope; wash in several xylols and mount in xylol-balsam. Neuroglia fibers blue, chromatin of neuroglia cell nuclei a purplish blue, protoplasm of neuroglia cells brownish red to bluish red.

VIII. THE EYE.

A. GENERAL STRUCTURE.

THE organ of vision consists of the eyeball, or **bulbus oculi,** and the entering **optic nerve.**

In the eyeball we distinguish three tunics: (1) a dense external coat, the **tunica fibrosa** or **externa,** which may be regarded as a continuation of the dura mater, consisting of an anterior transparent structure, called the *cornea*, and the remaining portion, known as the *tunica sclerotica*, or, briefly, the *sclera;* (2) within the tunica fibrosa a vascular tunic, the **tunica vasculosa** or **media,** subdivided into the *choroid*, *ciliary body*, and *iris;* (3) an inner coat, the **tunica interna,** which consists of two layers, the inner being the *retina;* the outer, the *pigment membrane*. The latter lines the internal surface of the tunica vasculosa throughout. Within the eyeball are the *aqueous humor*, the *lens*, and the *vitreous body*. The lens is attached to the ciliary body by a special accessory apparatus—the *zonula ciliaris*. These two structures—the lens and its fixation apparatus—divide the cavity of the eyeball into two principal chambers, the one containing the aqueous humor and the other the vitreous. The former is further subdivided by the iris into an anterior and a posterior chamber. During life the latter is only a narrow capillary cleft.

B. DEVELOPMENT OF THE EYE.

In man the eyes begin to develop during the fourth week of embryonic life, and at first consist of a pair of ventrolateral diverticula, projecting from the anterior brain vesicle. These evaginations gradually push outward toward the ectoderm, and are then known as the *primary optic vesicles*. The slender commissural segments connecting the vesicles with the developing brain are termed the *optic stalks*.

Very soon a process of invagination takes place; that portion of the vesicular wall nearest the ectoderm is pushed inward, thus

forming a double-walled cup—the *secondary optic vesicle*, or *optic cup*. An internal and an external wall may now be differentiated, continuous at the margin of the cup. At the same time a disc-like thickening of the adjacent ectoderm sinks inward toward the mouth of the cup-shaped optic vesicle, forming the first trace of the lens.

During the development of the secondary optic vesicle a groove

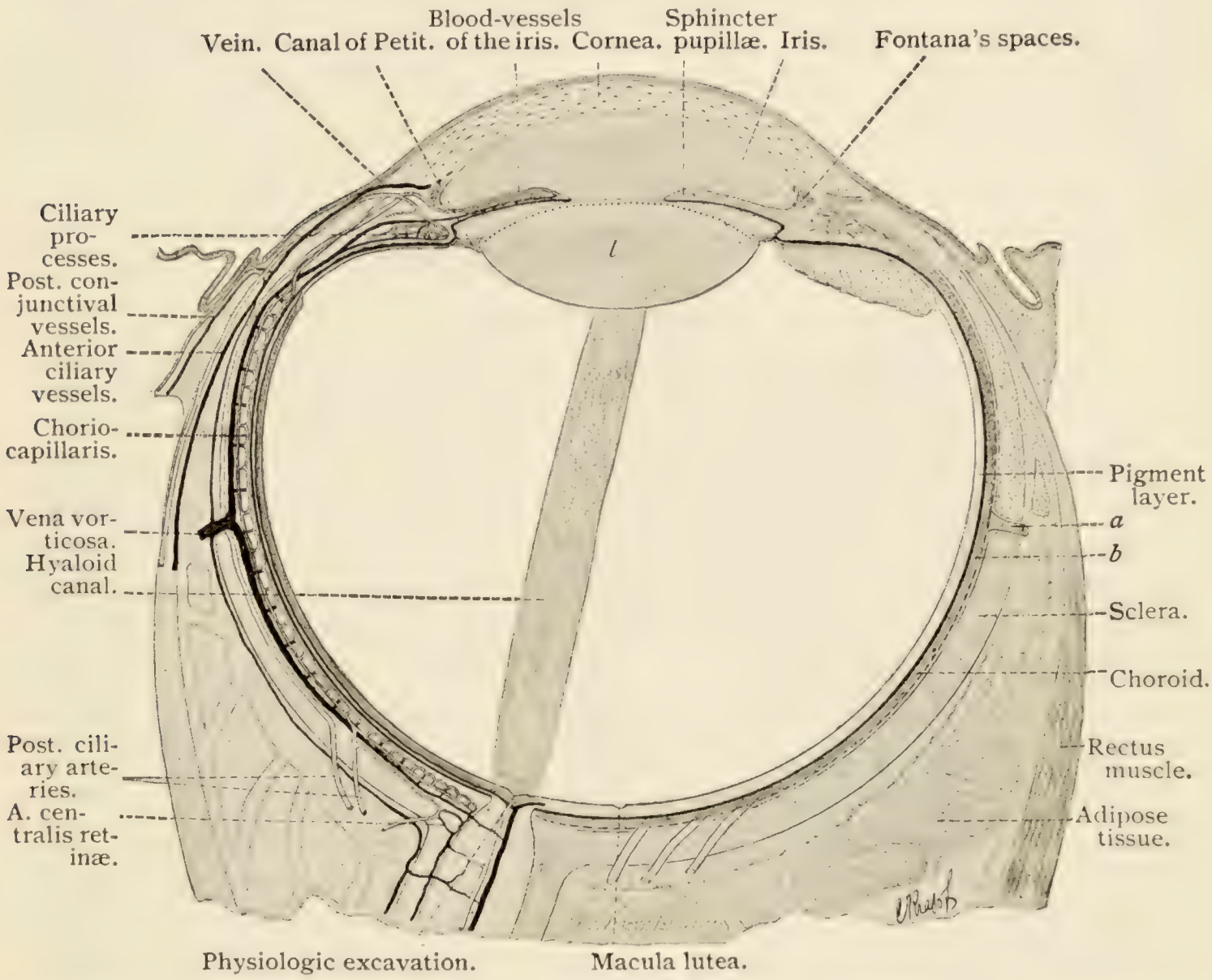

Fig. 352.—Schematic diagram of the eye (after Leber and Flemming) : *a*, Vena vorticosa ; *b*, choroid ; *l*, lens.

is formed on its ventral side, extending from the marginal ring into the optic stalk. This is the embryonic optic fissure, or the *choroidal fissure*. At the edges of the groove the two layers of the optic cup are continuous. This groove serves for the penetration of mesoblastic tissue and blood-vessels into the interior of the optic cup, and in its wall the fibers of the optic nerve develop.

The outer layer of the secondary optic vesicle becomes the *pigment membrane ;* the inner, the *retina*. The optic nerve-fibers consist not only of the centripetal neuraxes of certain ganglion cells in the retina, but also of centrifugal neuraxes, which pass out from the brain (Froriep).

The invaginating ectoderm which later constitutes the lens is constricted off from the remaining ectoderm in the shape of a vesi-

cle, the mesial half of which forms the lens fibers by a longitudinal growth of its cells, while the lateral portion forms the thin anterior epithelial capsule of the lens. The epithelium of the ectoderm external to the lens differentiates later into the external epithelium of the cornea and conjunctiva, neither of which structures is at this stage sharply defined from the remaining ectoderm. It is only during the development of the eyelids that a distinct demarcation is established. All the remaining portions of the eye, as the vitreous body, the vascular tunic with the iris, the sclera with the substantia propria of the cornea and the cells of Descemet's layer, are products of the mesoderm.

C. TUNICA FIBROSA OCULI.

1. THE SCLERA.

The **sclera** is the dense fibrous tissue covering of the eyeball, and is directly continuous with the transparent cornea. At the posterior mesial portion of the eyeball, the sclera is perforated for the entrance of the optic nerve, this region being known as the **lamina cribrosa**. The sclera consists of bundles of connective-tissue fibers arranged in equatorial and meridional layers. At the external scleral sulcus, in the vicinity of the cornea, the arrangement of the fibers is principally equatorial. The tendons of the ocular muscles are continuous with the scleral fibers in such a manner that those of the straight muscles fuse with the meridional fibers, while those of the oblique muscles are continuous with the equatorial fibers. In the sclera are many lymph-channels communicating with those of the cornea. They are much coarser and more irregularly arranged than those of the cornea, and in this respect simulate the lymph-channels found in aponeuroses. Pigmentation is constantly present at the corneal margin, in the vicinity of the optic nerve entrance, and also on the surface next the choroid. The innermost pigment layer of the sclera is lined by a layer of flattened endothelial cells, and is regarded by some as a separate membrane, known as the **lamina fusca ;** generally, however, it is regarded as forming a part of the outermost layer of the choroid (lamina suprachoroidea). The external surface of the sclera also presents a layer of flattened endothelial cells, belonging to the **capsule of Tenon.** Anteriorly, the mobile **scleral conjunctiva** is attached to the sclera by a loose connective tissue containing elastic fibers.

The cornea is inserted into the sclera very much as a watch-crystal is fitted into its frame. At the sclerocorneal junction is found an annular venous sinus, the **canal of Schlemm,** which may appear as a single canal or as several canals separated by incomplete fibrous septa. Anteriorly and externally this canal is bounded by the cornea and sclera ; internally, it is partly bounded by the origin of the ciliary muscle. The sclera comprises, therefore, one-

half of the canal-wall, and presents a corresponding circular sulcus, the so-called **inner scleral sulcus.**

The blood-vessels of the sclera are derived from the anterior and posterior ciliary vessels. The capillaries enter either into the ciliary veins or into the venæ vorticosæ. The numerous remaining vessels traverse the sclera, extending to the choroid, iris, or scleral margin. At the corneal margin the capillaries form loops.

2. THE CORNEA.

The **cornea** is made up of the following layers: (1) the anterior or corneal epithelium; (2) the anterior elastic membrane, or Bowman's membrane; (3) the ground-substance of the cornea, or substantia propria; (4) Descemet's membrane; (5) the endothelium of Descemet's membrane.

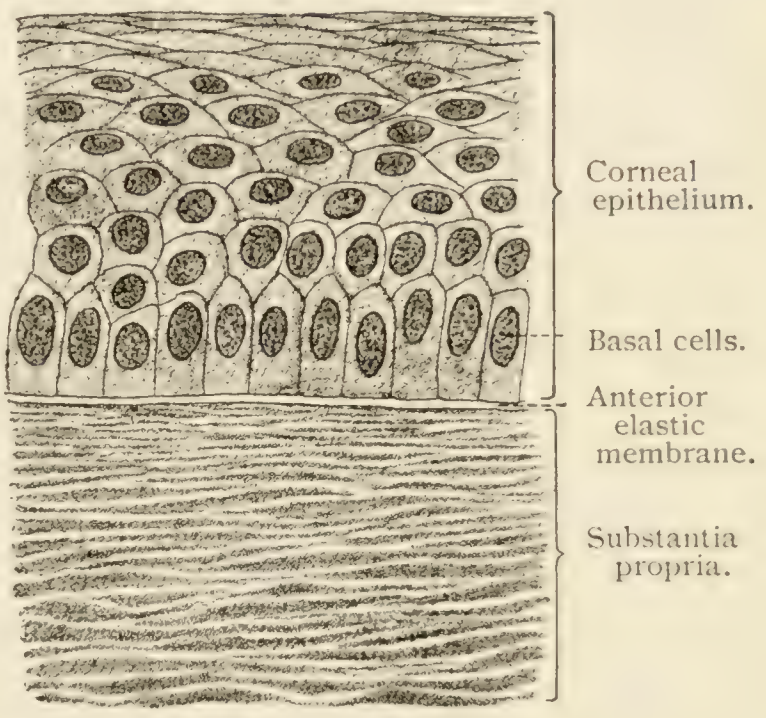

Fig. 353.—Section through the anterior portion of human cornea; × 500.

At the center of the human cornea the epithelium consists of from six to eight layers of cells, being somewhat thicker near the corneal margin. Its basilar surface is smooth and there are no connective-tissue papillæ. The basal epithelial layer is composed of cylindric cells of irregular height; the following layers contain irregular polygonal cells, while the two or three most superficial layers consist of flattened cells. The cells of the corneal epithelium are all provided with short prickles, which are, however, very difficult to demonstrate, and between are found lymph-canaliculi. The lower surfaces of the basal cells also possess short processes which penetrate into the anterior basement membrane.

In man the **anterior elastic** or **Bowman's membrane** is quite thick, measuring from 6 to 8 μ in thickness and is apparently homogeneous, but may be separated into fibrils by means of certain reagents. In structure it belongs neither to the elastic nor to the white fibrous type of connective tissue, and may be regarded as a basement membrane. Numerous nerve-fibers penetrate its pores to enter the epithelium. The thickness of this membrane decreases toward the sclera, and it finally disappears about 1 mm. from the latter.

The **substantia propria** consists of connective-tissue fibrils grouped into bundles and lamellæ. Chemically they do not differ

from true connective-tissue fibers (Morochowetz), but are doubly refracting, although the cornea as a whole yields chondrin and not glutin on boiling. There are about sixty lamellæ in the human cornea. The fibrils composing each lamella are cemented together and run parallel to one another as well as to the surface of the cornea, but they are so arranged that the fibrils of each lamella cross those of the immediately preceding one at an angle of about twelve degrees. The lamellæ themselves are likewise closely cemented to one another. The most superficial lamella, lying immediately beneath the anterior elastic membrane, is composed of finer fibers, the course of which is oblique to the surface of the cornea. Between the anterior and posterior elastic membranes are bundles of fibers, which perforate the various lamellæ of the cornea and are consequently known as the **perforating** or **arcuate fibers.**

Between the lamellæ are peculiar, flattened cells, possessing

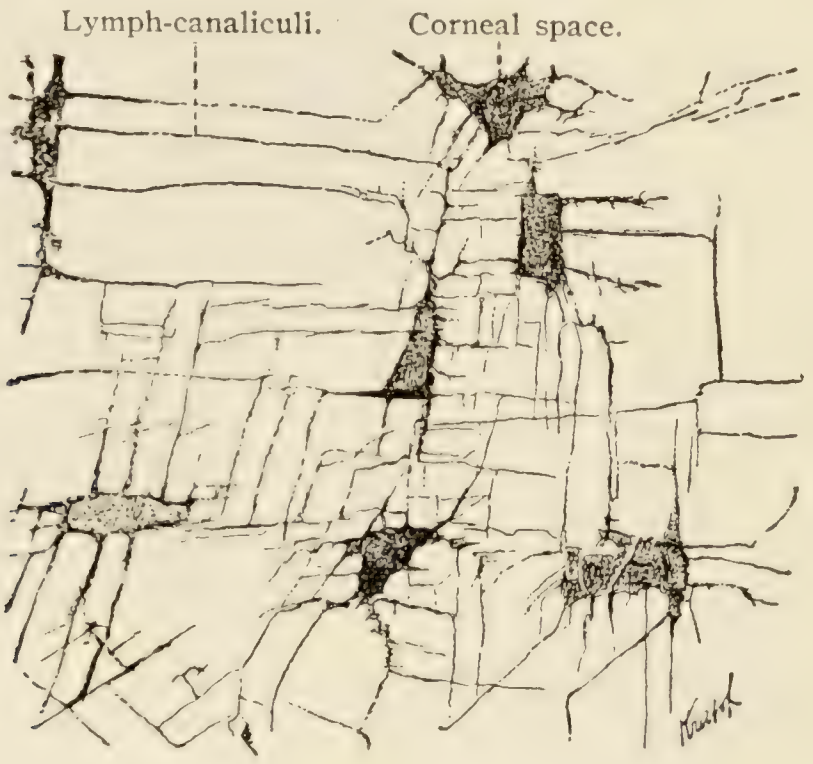

Fig. 354.—Corneal spaces of a dog ; × 640.

irregular or lamella-like processes, the fixed **corneal corpuscles ;** these lie in special cavities in the ground substance of the substantia propria, which are known as **corneal spaces.** In these spaces there are also found a varying number of leucocytes. By means of various methods (silver nitrate and gold chlorid treatment), these corneal spaces may be shown to be part of a complicated lymphatic system, comparable to the lymph-canalicular system of fibrous connective tissue. This system of canals is also in communication with the lymph-channels at the corneal margin.

The **posterior elastic** or **Descemet's membrane** is not so intimately connected with the substantia propria as Bowman's membrane. It is thinnest at the center of the cornea, and becomes thicker toward the margin. It may be separated into finer lamellæ, is very elastic, resists acids and alkalies, but is digested by trypsin.

At the periphery—that is, at the edge of the cornea—Descemet's membrane goes over into the fibers of the ligamentum pectinatum.

The endothelium of Descemet's membrane consists of low, quite regular hexagonal cells, which in certain vertebrates (dove, duck, rabbit) are peculiar in that a fibrillar structure may be seen in that portion of each cell nearest the posterior elastic membrane. By means of these fibers, not only adjacent cells, but also those further apart, are joined together. Thus we have here to a marked degree the formation of fibers which penetrate the cells and connect them with one another, conditions already met with in the prickle-cells of the epidermis.

The cornea is nonvascular. In fetal life, however, the capillaries from the anterior ciliary arteries form a precorneal vascular network immediately beneath the epithelium, a structure which is obliterated shortly before birth and only rarely seen in the newborn. Its remains are found at the corneal limbus either as an episcleral or conjunctival network of marginal capillary loops. Fine branches of the anterior ciliary arteries extend superficially along the sclera to the corneal margin, and form here a network of capillaries also ending in loops, from which numerous veins arise, constituting a corresponding network emptying into the anterior ciliary veins. The conjunctival vessels likewise form a network of marginal loops at the corneal limbus, and are connected with the episcleral vessels (Leber). Under pathologic conditions the cornea may become vascularized from the marginal episcleral network.

The **nerves** of the cornea are derived from the sensory fibers of the ciliary nerves, which form a plexus at the corneal margin ; from this, nonmedullated fibers penetrate the cornea itself and form two plexuses, a *superficial* and a *ground plexus ;* the latter is distributed throughout the whole substantia propria with the exception of its inner third (Ranvier, 81). The two plexuses are connected by numerous anastomoses. At one time it was supposed that direct communication existed between the corneal corpuscles and the nerve-fibers of both plexuses. This view, however, contradicts the generally accepted neurone theory.

Nerve-fibers from the superficial plexus pass through the anterior elastic membrane and form a plexus over the posterior surface of the epithelium, known as the *subepithelial plexus*. From the latter nerve-fibers extend between the epithelial cells, terminating in telodendria with long slender nerve-fibrils, which end in small nodules. Many of the fibrils reach almost to the surface of the epithelium (Rollet, 71 ; Ranvier, 81 ; Dogiel, 90).

Smirnow (1900) has described a rich nerve-supply for the sclera, consisting of both medullated sensory fibers and nonmedullated sympathetic fibers, derived mainly from the ciliary nerves. The sympathetic fibers supply the blood-vessels; the sensory fibers terminate in free endings between the connective-tissue lamellæ.

D. THE VASCULAR TUNIC OF THE EYE.

THE CHOROID, THE CILIARY BODY, AND THE IRIS.

From without inward the following layers may be differentiated in the **choroid :** (1) the *lamina suprachoroidea ;* (2) the *lamina vasculosa Halleri ;* (3) the *lamina choriocapillaris ;* and (4) the *glassy layer,* or *vitreous membrane.*

The **lamina suprachoroidea** consists of a number of loosely arranged, branching and anastomosing bundles and lamellæ of fibrous tissue, joined directly to the sclera. These bundles and lamellæ consist of white fibrous connective tissue containing numerous elastic fibers, among which a few connective-tissue cells are distributed. Pigment cells are also present in varying numbers. The bundles and lamellæ are covered by endothelial cells, and the spaces and clefts between them, and between the lamina suprachoroidea and the lamina fusca, constitute a system of lymph-channels—the *perichoroidal lymph-spaces.*

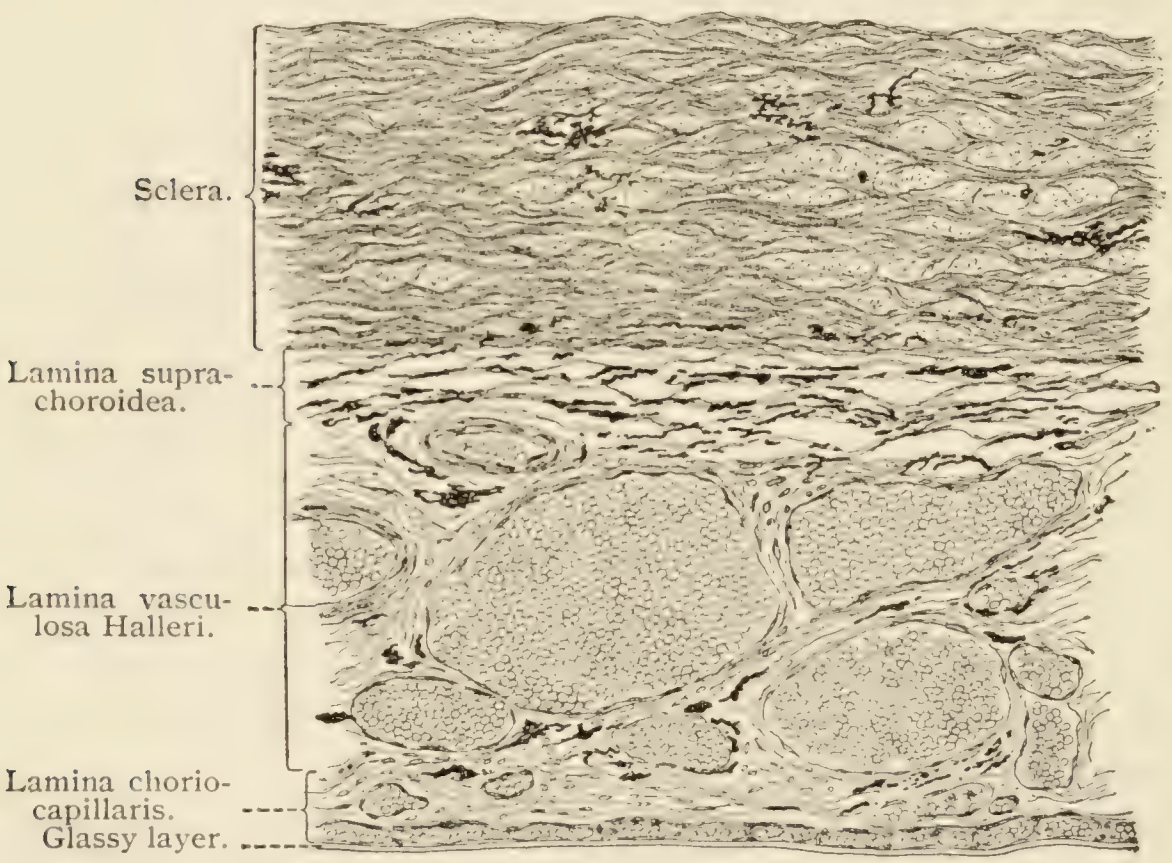

Fig. 355.—Section through the human choroid ; × 130.

The **lamina vasculosa** of the choroid is also composed of similar lamellæ, which, however, are more closely arranged. The blood-vessels constitute the principal portion of this layer, the vessels being of considerable caliber, not capillaries. They are so distributed that the larger vessels, the veins, occupy the outer layer of the lamina vasculosa. The venous vessels converge toward four points of the eyeball, forming at the center of each quadrant one of the four *venæ vorticosæ.* The arteries, on the other hand, describe a more meridional course.

In the inner portion of this layer is found a narrow zone,—in the human eye only about 10 μ in thickness,—consisting largely of elastic fibers and free from pigment cells, known as the *boundary zone.* This zone is somewhat thicker in many mammals, and in some of these presents a characteristic structure. In the eyes of ruminants and horses this zone consists of several layers of connective-tissue bundles, and is known as the *tapetum fibrosum.* It gives the peculiar luster often seen in the eyes of these animals. In the eyes of carnivora this zone consists of several layers of endothelioid cells, containing in their protoplasm numerous small crystals and forming the iridescent layer known as the *tapetum cellulosum.*

The **lamina choriocapillaris** contains no pigment and consists principally of capillary vessels, which form an especially dense network in the neighborhood of the macula lutea. As the venous capillaries become confluent and form smaller veins, the latter arrange themselves in long, radially directed networks, and form in this way the more or less pronounced *stellulæ vasculosæ* (Winslowii).

The **vitreous** or **glassy membrane** is a very thin (2 μ) homogeneous membrane which shows on its outer surface the impressions of the vessels composing the lamina choriocapillaris, and on its inner surface those of the pigment epithelium of the retina.

At the ora serrata the choroid changes in character; from this region forward, the choroidal tissue assumes more the appearance of ordinary connective tissue, and the choriocapillary layer is wanting.

The region of the vascular coat extending from the ora serrata to the base of the iris is known as the **ciliary body.** Its posterior portion, about 4 mm. broad, the *orbiculus ciliaris*, is slightly thicker than the choroid, and presents on its inner surface numerous small folds, meridionally placed, consisting of connective tissue and blood-vessels. Anterior to the orbiculus ciliaris the ciliary body is thickened by a development of nonstriated muscle—the ciliary muscle (see below); and on the inner surface of this annular thickening are placed about seventy triangular folds, meridionally arranged—the **ciliary processes.** The attached border of these processes measures from 2 to 3 mm. The anterior border attains a height of about 1 mm. On and between these folds are found numerous small secondary folds or processes of irregular shape. The ciliary processes consist of fibrous connective tissue and numerous smaller and larger vessels, which have in the main a meridional arrangement. The vitreous membrane extends over the ciliary body, attaining in the region of the ciliary processes a thickness of 3 μ or 4 μ. Internal to the vitreous membrane, the ciliary body is covered by a double layer of epithelial cells, the continuation forward of the retina (*pars ciliaris retinæ*). Of these, the outer layer is composed of cells, which are deeply pigmented, and are of cubic or short columnar shape, and derived from the outer layer of the secondary optic vesicle, while the cells of the inner layer are nonpigmented and of columnar shape, and are developed from the inner layer of the secondary optic vesicle. In the region of the ciliary processes

their epithelial lining presents here and there evaginations of glandular appearance, lined by the unpigmented cells. These evaginations are known as **ciliary glands,** and to them is attributed—in part, at least—the secretion of the fluid found in the anterior chamber of the eye; it is, however, still a question as to whether these structures are to be regarded as true glands or simply as depressions or crypts in the epithelium.

The **ciliary muscle** is bounded anteriorly (toward the anterior chamber) by the ligamentum pectinatum iridis, externally by the cornea and sclera, posteriorly by the orbiculus ciliaris, and internally by the ciliary processes. It consists of nonstriated muscle-fibers in the majority of vertebrates. This muscle is divided into three portions. The outer or *meridional division* extends from the posterior elastic lamina of the cornea and its continuation, forming the inner wall of the sinus venosus scleræ, to the posterior portion of the ciliary ring. The origin of the *middle division* is identical with

Fig. 356.—Meridional section of the human ciliary body; × 20.

that of the outer, but its fibers (assuming that we have before us a meridional section) spread out like a fan, and occupy a large area at their insertion into the ciliary ring and ciliary processes. The radial course of these fibers is interrupted by circular bundles. The *third* or *inner division* (*fibræ circulares, fibers of Müller*) is situated between the ligamentum pectinatum, the ciliary processes, and the middle portion of the muscle just mentioned, and is thus near the base of the iris.

Between the ciliary muscle and the posterior elastic membrane of the cornea is an intermediate, richly cellular tissue, which may be regarded as a continuation of this elastic membrane, and which forms a part of the wall of the sinus venosus. Another structure internal to the foregoing and directed posteriorly is the *ligamentum pectinatum iridis*, which encircles the anterior chamber and is a continuation of Descemet's membrane to the base of the iris. It con-

sists of fibers and lamellæ lined by endothelial cells, and bounds certain intercommunicating spaces lying in the ligament, known as the **spaces of Fontana.** The latter communicate on the one side with the perivascular spaces of the sinus venosus scleræ (canal of Schlemm), and on the other with the anterior chamber.

The **iris** must be looked upon as a continuation of the choroid, and is connected at its anterior peripheral portion with the ligamentum pectinatum. The iris possesses the following layers, beginning anteriorly: (1) the anterior endothelium; (2) the ground layer, or stroma of iris, together with the sphincter muscle of the pupil; and (3) the two-layered, pigmented epithelium—the pars iridica retinæ, of which the anterior is in part replaced by a peculiar muscle tissue, developed from the ectoderm and forming the dilator of the pupil.

The **anterior endothelium** is a single layer of irregularly polygonal, nonpigmented cells, and is directly continuous with the endothelium of the pectinate ligament.

The ground-layer or **stroma of iris** consists anteriorly of a fine reticulate tissue rich in cellular elements (reticulate layer). The remaining strata which form the bulk of the ground-layer constitute its vascular layer. The vessels are here peculiar in that they are covered by coarse, circular, connective-tissue fibers forming vascular sheaths. There is also an entire absence of muscular tissue in the vessel walls. The nerves, too, are enveloped by a dense connective tissue. In all eyes (except the albinotic) pigment is found in the connective tissue.

On the posterior inner surface of the ground-layer is a band of smooth muscle-fibers encircling the pupil—the *sphincter muscle of the pupil.* Posterior to this and in intimate relation with the layer of pigmented epithelium covering the posterior surface of the iris is a layer of spindle-shaped cells having a radial arrangement and containing pigment. Closer microscopic inspection reveals the fact that in all probability these elements represent muscular tissue. Here, therefore, we have to deal with a *dilator muscle* of the pupil. There has been much discussion as to the existence and structure of this muscle. Recent investigations (Szili) indicate that it is developed from the outer layer of the secondary optic vesicle.

The **posterior epithelium** is the direct continuation of the two epithelial layers of the ciliary body, and represents the anterior portion of the secondary optic vesicle, the two layers being continuous at the margin of the pupil. In the iris both layers of cells, so far as they exist, are pigmented.

The **arteries of the choroid** are derived from the short posterior ciliary, the long ciliary, and the anterior ciliary arteries. The short posterior ciliary arteries penetrate the sclera in the vicinity of the optic nerve, where they anastomose with branches from the retinal vessels, and spread through the choroid, where they form the choriocapillary layer. The long posterior ciliary arteries (a mesial and a lateral) penetrate the sclera and course forward between choroid and sclera to the ciliary body, forming there the *circulus arteriosus iridis major;* they

also supply the ciliary muscle, the ciliary processes, and the iris, and anastomose in the ciliary ring with the branches of the short posterior and anterior ciliary arteries. The latter lie beside and partly within the straight ocular muscles, penetrating the latter at the anterior margin of the sclera ; they give off branches to the circulus arteriosus iridis major and to the ciliary muscles, anastomosing at the same time with the posterior ciliary arteries. (Compare Figs. 352 and 357.) Within the iris the blood-vessels generally take a radial direction, but also anastomose with one another, forming capillaries, and subsequently the *circulus arteriosus iridis minor* at the inner pupillary margin. From the region supplied by the posterior ciliary arteries most of the blood is carried toward the vorticose veins. The anterior ciliary veins convey the blood coming from the arteries of the same name. Into these veins is also poured the blood from the veins lying in the canal of Schlemm, the canal itself being in reality an open venous sinus. Besides this, these veins convey also venous blood from the conjunctiva (Leber).

The nonstriated muscle of the ciliary body and iris receives its innervation through sympathetic nerve-fibers, neuraxes of sympathetic neurones, the cell-bodies of which are situated either in the ciliary ganglia or in the superior cervical ganglia. The neuraxes of the sympathetic cells forming the ciliary ganglia form the short ciliary nerves, which pierce the sclera in the neighborhood of the optic nerve and pass forward, to terminate in the muscle of the ciliary body and the sphincter muscle of the pupil. Stimulation of these nerves causes a contraction of the ciliary muscle and a closure of the pupil. The cell-bodies of the sympathetic neurones forming the ciliary ganglia are surrounded by pericellular plexuses, the terminations of small medullated nerve-fibers (white rami fibers) which reach the ciliary ganglia through the oculomotor nerves. Neuraxes of sympathetic neurones, the cell-bodies of which are situated in the superior cervical ganglia, reach the eye through the cavernous plexuses, to terminate, it is thought,—in part, at least,—in the dilator of the iris, since stimulation of these nerves causes a dilatation of the

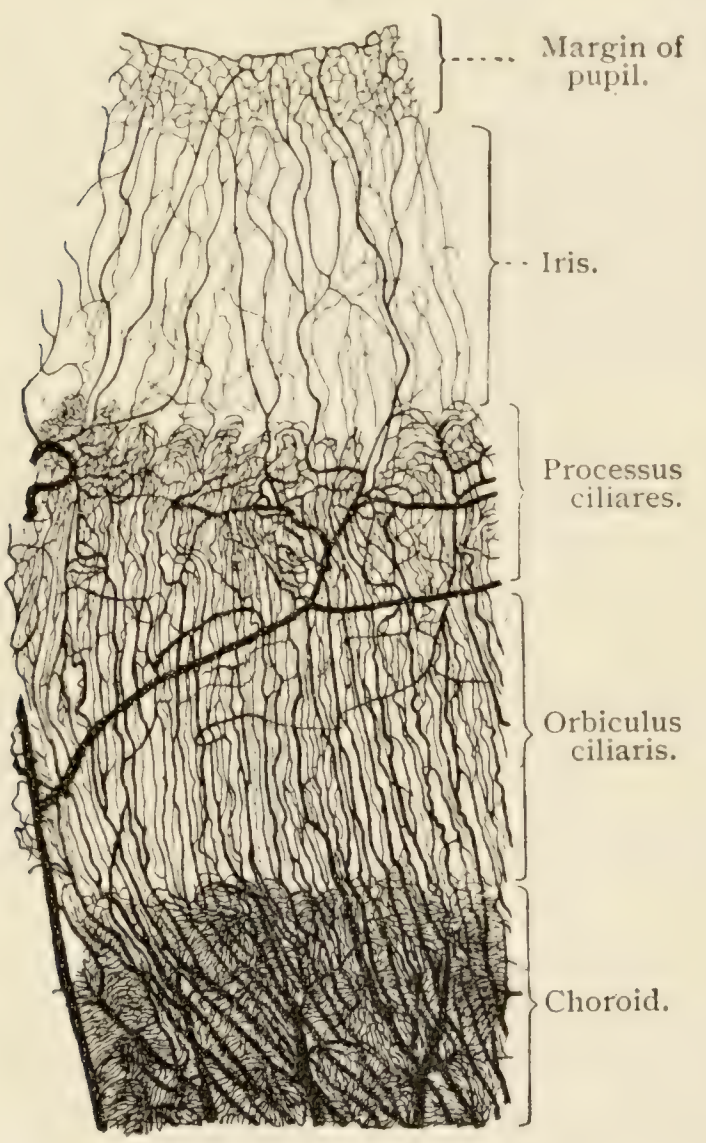

Fig. 357.—Injected blood-vessels of the human choroid and iris; × 7.

pupils. The cell-bodies of these sympathetic neurones are surrounded by pericellular plexuses, the terminations of white rami fibers which leave the spinal cord through the first, second, and third thoracic nerves (Langley), and which reach the superior cervical ganglia through the cervical sympathetic.

Melkirch and Agababow have shown that numerous sensory nerves terminate in free sensory endings in the connective tissue of the ciliary body and iris. The sensory nerve-supply of the iris is especially rich.

E. THE INTERNAL OR NERVOUS TUNIC OF THE EYE.

This tunic is composed of two layers : the outer, or *stratum pigmenti ;* and the inner, or *retina.*

1. THE PIGMENT LAYER.

The pigment layer develops, as we have seen, from the outer layer of the secondary optic vesicle. It consists of regular hexagonal cells, 12 μ to 18 μ in length and 9 μ in breadth, which contain black pigment in the form of granules. The inner surfaces of these cells possess long, thread-like and fringe-like processes, between which project the external segments of the rods and cones of the retina, yet to be described. The nuclei of the pigment cells lie in the outer ends of the cells, the so-called basal plates, and are not pigmented. The distribution of the pigment varies according to the illumination of the retina. If the latter be darkened, the pigment collects at the outer portion of each cell ; if illuminated, the pigment is evenly distributed throughout the whole cell. The pigment granules are therefore mobile (Kühne, 79).

2. THE RETINA.

The retina has not the same structure throughout. In certain areas peculiarities are noticeable which must be described in detail ; such areas are : (1) the macula lutea ; (2) the region of the papilla (papilla nervi optici) ; (3) the ora serrata ; (4) the pars ciliaris retinæ ; and (5) the pars iridica retinæ.

We shall begin with the consideration of that portion of the retina lying between the ora serrata and the optic papilla (exclusive of the macula lutea).

From without inward, we differentiate : (1) the layer of visual cells, including the outer nuclear layer ; (2) the outer molecular (plexiform) layer ; (3) the inner nuclear or granular layer ; (4) the inner molecular (plexiform) layer ; (5) the ganglion-cell layer ; (6) the nerve-fiber layer. Besides these, we must also consider the

supporting tissue of the retina and Müller's fibers, together with the internal and external limiting membranes.

The **visual cells** are either *rod-visual cells* or *cone-visual cells.* The **rod-visual cells** consist of a rod and a rod-fiber with its nucleus. The *rod* (40 μ to 50 μ in length) consists of two segments, an outer and an inner, the former of which is doubly refractive and may be separated into numerous transverse discs by the action of certain reagents. The inner is less transparent than the outer segment, and its inner end shows a fine superficial longitudinal striation due to impressions from the fiber-baskets formed by Müller's fibers. In the lower classes of vertebrates a rod-ellipsoid

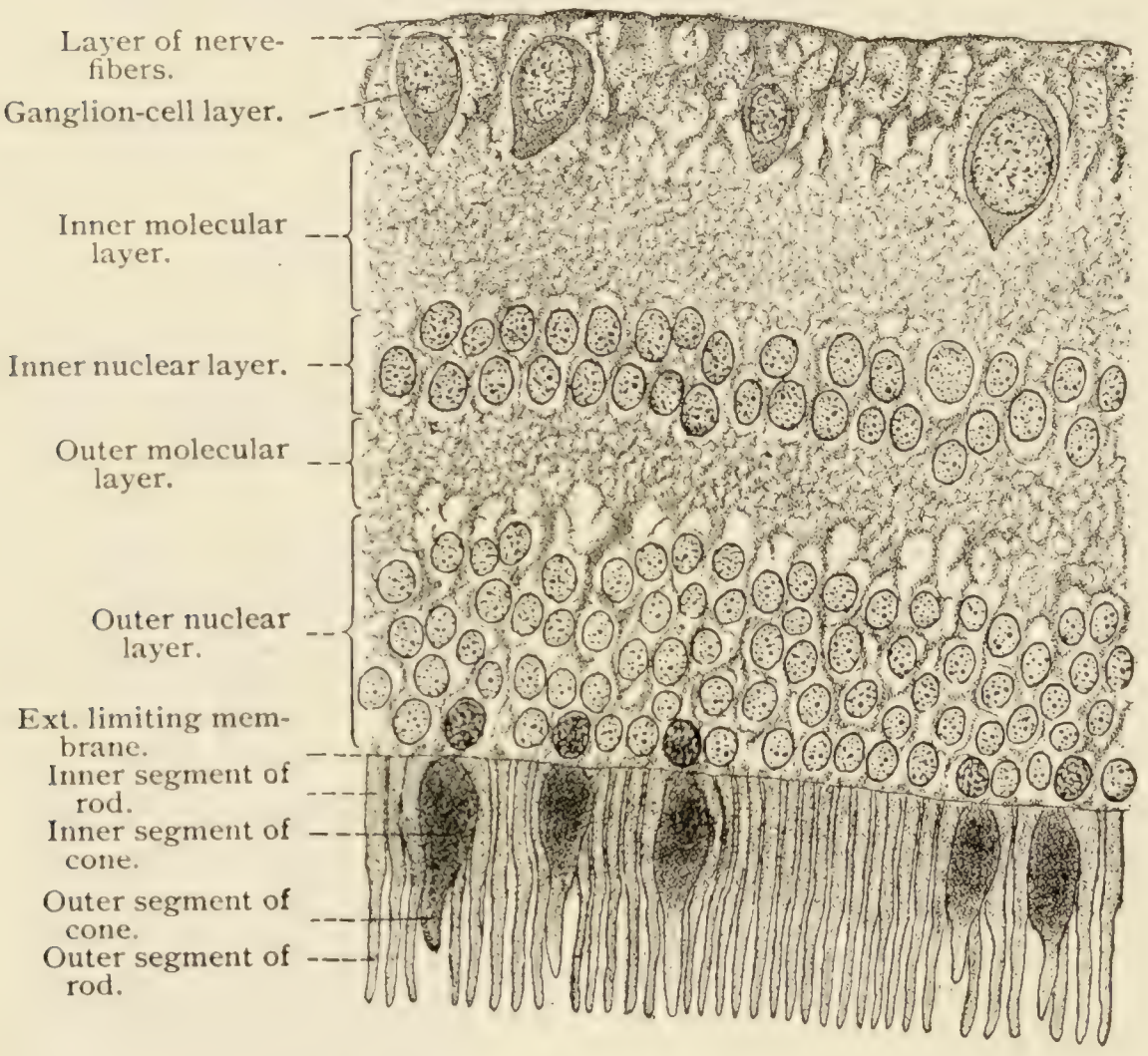

Fig. 358.—Section of the human retina ; × 700.

(a fibrillar structure) may easily be demonstrated in the outer region of each inner portion ; in many mammalia and in man the demonstration of this is more difficult. This structure is a planoconvex, longitudinally striated body, the plane surface of which is coincident with the external surface of the inner segment, its inner convex surface lying at the junction of the outer and middle thirds of the inner segment. The *rod-fibers* extend as far as the outer molecular layer of the retina, where they end in small spheric swellings. The nuclei of the rod-visual cells are found at varying points within the rod-fibers, but rarely close to the inner segment. When treated with certain fixing agents and stains, the rod-nuclei of certain animals (cat and rabbit) are seen to show several zones, which stain alternately

light and dark (striation of the rod-nuclei). This striation is not generally observed in the rod-nuclei of the human retina.

The **cone-visual cells** consist, similarly to the rod-visual cells, of a cone and a cone-fiber with its nucleus. The *cone* (15 μ to 25 μ in length) is, as a whole, shorter than the rod, and its inner segment is considerably broader than that of the rod. The cone ellipsoid comprises the outer two-thirds of the inner segment, and the outer segment has a more conical shape. The *cone-fiber* likewise extends as far as the outer molecular layer, where it ends in a branched basal plate. Its somewhat larger nucleus is always found in the vicinity of the inner segment of the cone. The inner surfaces of the inner segments, not only of the cone-cells, but also of the rod-visual cells, lie in one plane, corresponding to the *external limiting membrane*, a structure composed of the sustentacular fibers of Müller. The rod-fibers and cone-fibers, with the nuclei of the rod- and cone-visual cells, lie between the external limiting membrane and the outer molecular layer. It will be observed, therefore, that the visual cells include the layer of rods and cones and the outer nuclear layer.

The **outer molecular layer** consists: (1) of the ramifications of Müller's fibers; (2) of the knob and tuft-like endings of the visual cells; and (3) of the dendritic processes of the bipolar cells of the inner nuclear layer. These structures will be considered more in detail in discussing the relations of the elements comprising the retina.

The **inner nuclear layer** contains: (1) the nucleated stratum of Müller's sustentacular fibers; (2) ganglion cells situated in the outer region of the layer and extending in a horizontal direction; (3) bipolar ganglion cells with oval nuclei, densely placed at various depths of the layer and vertical to it; (4) amacrine cells (neurones, apparently without neuraxes) lying close to the inner margin of the layer and forming with their larger nuclei a nearly continuous layer of so-called spongioblasts. The numerous processes of these spongioblasts lie in the *inner molecular layer*, the composition of which will be further discussed later.

The **ganglion-cell layer** of the optic nerve consists, aside from centrifugal neuraxes and the fibers of Müller, which are here present, of multipolar ganglion cells, the dendrites of which extend outward and the neuraxes of which are directed toward the optic nerve-fiber layer. These cells vary in size, and their nuclei are typical, being relatively large, deficient in chromatin, and always provided with large, distinct nucleoli. In man the optic nerve-fibers of the retina are nonmedullated.

All these structures are typical of that portion of the retina lying behind the ora serrata. The retina in the vicinity of the optic papilla and macula lutea must be taken up separately.

3. REGION OF THE OPTIC PAPILLA.

The **optic papilla** is the point of entrance of the optic nerve into the retina. At the center of the papilla, in the region where the nerve-fibers spread out radially in order to supply the various areas of the retina, is a small, funnel-shaped depression, the *physiologic excavation*. The fibers of the optic nerve lose their medullary sheaths during their passage through the sclera and choroid, and then continue to the inner surface of the retina, over which they spread in a layer which gradually becomes thinner toward the ora serrata. On account of the deflection of the nerve-fibers, and because, during

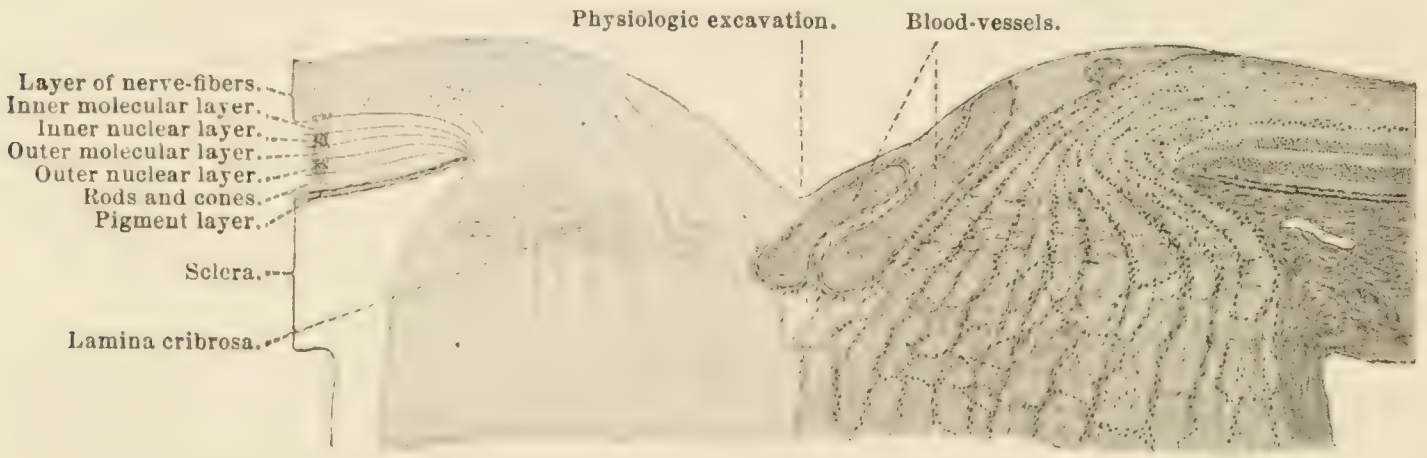

Fig. 359.—Section through point of entrance of human optic nerve ; × 40.

their passage through the sclera, they lose their medullary sheaths at one and the same point, the optic nerve becomes suddenly thinner. The result is a deeply indented circular depression in this region. On this depression border the three ocular tunics. At this point the retina is interrupted, the outer layers extending to the bottom of the depression, while the inner cease at its margin. In many cases the outer layers of the retina are separated from the optic nerve by a thin lamina of supporting tissue (intermediate tissue).

4. REGION OF THE MACULA LUTEA.

At the center of the **macula lutea** is a trough-like depression, the **fovea centralis,** the deepest part of which, the *fundus*, lies very close to the visual axis. Here the layers of the retina are practically reduced to the cone-visual cells. The margin of this depression is somewhat thickened, owing to an increase in the thickness of the nerve-fiber and ganglion-cell layers. Toward the fundus of the fovea each of the four inner retinal layers becomes reduced in thickness, the inner layer first and the three others in their order : the inner molecular layer, however, seems to extend as far as the fundus. As we have seen, only the cone-visual cells are found in the fovea centralis, there being an entire absence of the rod-visual cells. Since the nuclei of the cone-visual cells are in the immediate neighborhood

of the cones, and since the cone-fibers, in order to reach the outer molecular layer, must here describe a curve, there arises a peculiar layer, composed of obliquely directed fibers, known as the *outer fiber-layer* or *Henle's fiber layer.* In other words, the fibers of this region are more distinctly seen because they are not covered by the rod-nuclei and rod-fibers.

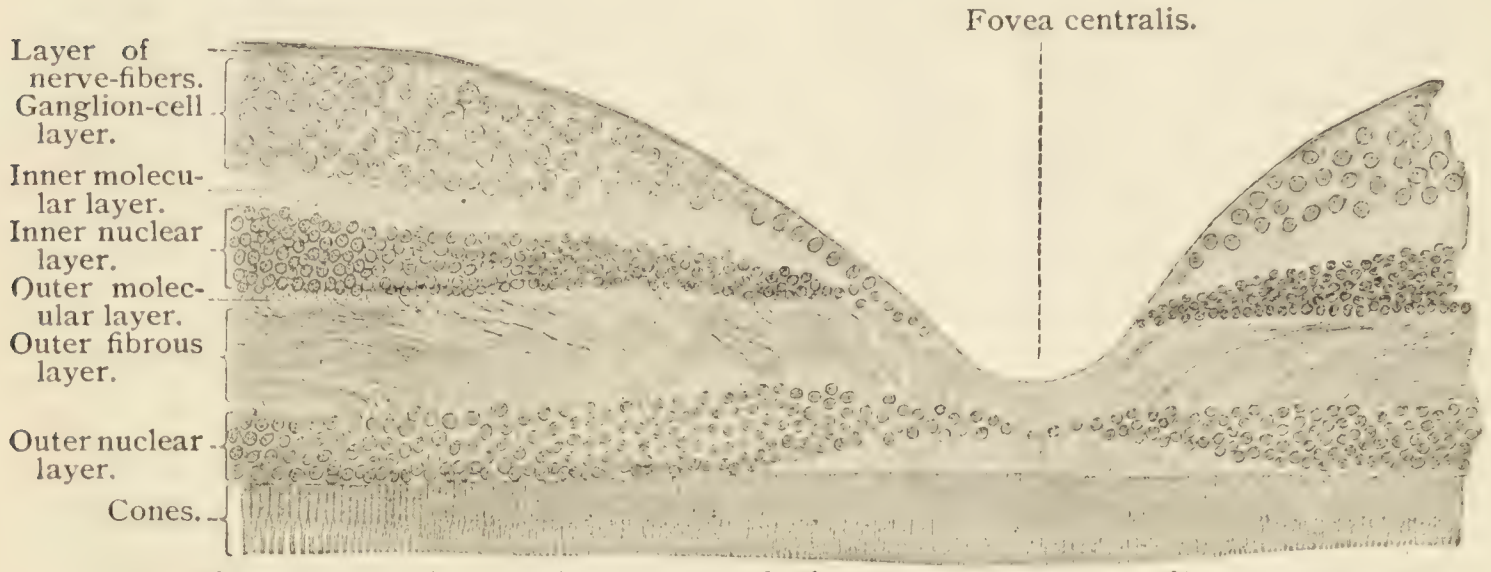

Fig. 360.—Section through human macula lutea and fovea centralis; × 150. As a result of treatment with certain reagents, the fovea centralis is deeper and the margin more precipitous than during life.

The yellowish color of the fovea centralis is due to pigment held in solution within the layers of the retina. The cone-visual cells themselves contain no pigment.

5. ORA SERRATA, PARS CILIARIS RETINAE, AND PARS IRIDICA RETINAE.

In the region of the **ora serrata** the retina suddenly becomes thinner. As seen from the inner surface of the retina, its decrease presents the appearance of an irregular curve rather than of the segment of a sphere. Shortly before the retina terminates, its layers become markedly reduced, certain ones disappearing entirely; first the nerve-fiber layer, then the ganglion-cell layer and cone- and rod-visual cells, their place being taken by an indifferent epithelium. The inner molecular layer of the retina gradually loses the processes which penetrate inward. In the region of the ora serrata the sustentacular fibers are markedly developed. Relatively large hollow spaces are often found in the retina at the ora serrata; they are thought to be due to edema.

The **pars ciliaris retinæ** consists essentially of two simple layers of cells, of which the external represents the pigment layer and the internal the inner epithelium of the secondary optic vesicle. In the **pars iridica retinæ** the arrangement is similar; here both layers are pigmented.

6. MÜLLER'S FIBERS OF THE RETINA.

Genetically, the sustentacular fibers, or **fibers of Müller,** in the retina are, like the whole retina, of ectodermic origin, and represent a highly developed form of neurogliar tissue. They penetrate the retina from within and extend as far as the inner segments of the rods and cones. Each fiber represents a long, greatly modified epithelial cell, terminating in one or more broad basal plates, which come in contact with those of adjacent fibers, thus forming a sort of membrane—the *internal limiting membrane.* Owing to its marked plasticity, each fiber presents certain peculiarities within the various layers of the retina through which it penetrates. Thus, within the molecular layers the fiber is provided with transversely directed processes and platelets. Within the nuclear layers, on the other hand, are numerous lateral indentations, which correspond to the impressions produced by the cells of these layers. At the inner surface of the cones and rods the fibers terminate in end-plates, which represent cuticular formations, and, blending with one another, form a single membrane—the *external limiting membrane.* This membrane is perforated by the rod-fibers and cone-fibers. The end-plates of the fibers give off externally short, inflexible fibrils, which form the *fiber-baskets* containing the basilar portions of the inner segments of the rods and cones. (*Vid.* Fig. 361.) Müller's fibers do not appear as fibers in chrome-silver preparations, but as complicated cellular structures, as above depicted. In preparations of the retina, stained in a differential neuroglia stain (Benda's method), clearly defined fibers, stained after the manner of neuroglia fibers, may be differentiated. These fibers are in contact with or are imbedded in the protoplasm of the Müller's fibers.

7. THE RELATIONS OF THE ELEMENTS OF THE RETINA TO ONE ANOTHER.

We shall now take up the relationships existing between the various elements of the retinal strata, giving the theories now generally accepted and based on observations made with the Golgi and methylene-blue methods, and more particularly on the investigations of Ramôn y Cajal (see diagram, Fig. 361):

1. The inner processes of the rod-visual cells end, as a rule, in small expansions within the *outer molecular layer,* in which also the processes of the cone-visual cells terminate in broader branched pedicles. In this layer also are situated the terminal arborizations of the dendrites and neuraxes of certain cells belonging to the inner nuclear layer.

2. The *inner nuclear layer* consists, as we have seen, (*a*) of bipolar cells, which constitute the principal portion of this layer, (*b*) of horizontally placed cells lying immediately beneath the outer molecular layer, and (*c*) of the layer of spongioblasts situated at the junction

of the inner nuclear with the inner molecular layer. The *bipolar cells* comprise the following : (*α*) *Bipolar cells of the rod-visual cells* the dendrites of which intertwine around the basilar portions of the rod-visual cells, and the neuraxes of which end in telodendria in the neighborhood of the cell-bodies of the nerve-cells of the ganglion-cell layer. (*β*) *Bipolar cells of the cone-visual cells.* The dendrites of these cells,

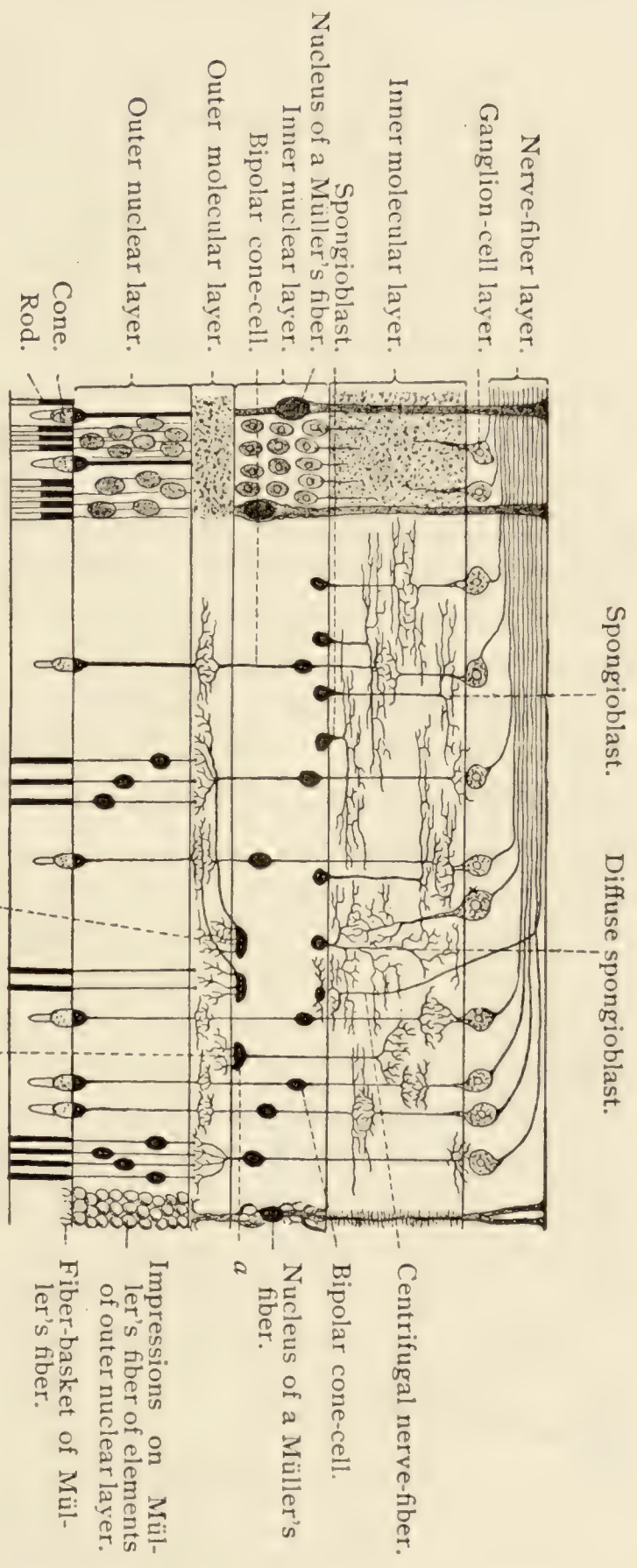

Fig. 361.—Schematic diagram of the retina according to Ramón y Cajal: The line *a*, after passing through a Müller's fiber, crosses a bipolar rod-cell, then two bipolar cone-cells, and finally ends in the body of a bipolar cone-cell.

which also end in the outer molecular layer, are there in relation to the basilar processes of the cone-fibers. Their neuraxes come in contact, by means of terminal arborizations, with the dendrites of the ganglion cells of the ganglion-cell layer at varying depths of the inner molecular layer. (*γ*) Besides these, there are also bipolar cells which, as in the case of *α* and *β*, form contact with the rod- and

cone-visual cells, but end on the cell-bodies of the ganglion cells of the ganglion-cell layer. The *horizontal cells* send their dendrites into the outer molecular layer, while their neuraxes extend horizontally and give off numerous collaterals to the same layer, ending there in telodendria. These cells are of two varieties: the smaller, indirectly connecting the cone-visual cells with one another by means of their dendrites and neuraxes ; and the larger, more deeply situated cells, connecting in a similar manner the basilar ends of the rod-visual cells. A few cells of the second variety give off one or two dendrites each, which penetrate through the inner nuclear layer into the inner molecular layer.

3. The *inner molecular layer.* This is composed of five strata. The majority of the spongioblasts (amacrine or parareticular cells) in the inner nuclear layer send their processes upward into the inner molecular layer, in which some end in fine arborizations in the first, others in the second, and still others in the third interstice, separating the strata of the inner molecular layer from one another. Besides these so-called *stratum spongioblasts*, there are also others in the inner nuclear layer, the *diffuse spongioblasts*, whose ramifications end simultaneously in several or in all of the strata of the inner molecular layer. Besides the ramifications of the spongioblasts just mentioned, autochthonous cells are also present. These lie in one of the interstices of the molecular layers, their ramifications spreading out in a horizontal direction. Besides all these structures the dendrites of the cells in the ganglion-cell layer also ramify throughout the inner molecular layer.

4. The *ganglion-cell layer.* The cell-bodies are irregularly oval ; their dendrites extend into the inner molecular layer, and their neuraxes into the nerve-fiber layer. According to the manner of their dendritic termination, the ganglion cells may be divided into three groups : (1) those the dendrites of which extend into but one stratum of the molecular layer ; (2) those the dendrites of which extend into several strata of the molecular layer ; and (3) those the dendrites of which are distributed throughout the entire thickness of the molecular layer. Thus, these three groups are made up of the so-called *mono-stratified*, *poly-stratified*, and *diffuse* cells ; by means of their dendrites they come in contact with one or several of the neuraxes of the bipolar cells of the inner nuclear layer.

5. The *nerve-fiber layer* of the retina. This layer consists of centripetal neuraxes from the ganglion cells of the ganglion-cell layer, and of centrifugal nerve-fibers ending in various layers of the retina, including the outer molecular layer.

8. THE OPTIC NERVE.

Within the orbit the optic nerve possesses an external sheath, which is an extension of the dura mater and is continuous with the scleral tissue, and an inner sheath, which is a prolongation of the pia

mater. Between these two sheaths is a fissure, divided into two smaller clefts by a continuation of the arachnoid. Both these clefts are traversed by connective-tissue trabeculæ. The inner cleft communicates with the subarachnoid space; and the outer narrower cleft, with the subdural space.

The fibers of the optic nerve are medullated, but they possess no neurilemma. They are grouped into small bundles by septa and bands of fibrous tissue penetrating the optic nerve from the inner or pial sheath. Within these bundles the nerves are separated by neuroglia tissue,—neuroglia cells and fibers,—which further forms a thin sheath about each bundle. In the region of the sclera and choroid the optic nerve-fibers lose their myelin, and the septa of the inner or pial sheath become better developed and relatively more numerous. Connective-tissue fibers from the sclera and choroid also traverse this region of the optic nerve, giving rise to what is known as the *lamina cribrosa.* At from 1 ½ to 2 cm. from the eyeball there enter into the optic nerve laterally and ventrally (according to J. Deyl, mesially) the central artery and vein of the retina, which very soon come to lie within the axis of the nerve. Here they are surrounded by a common connective-tissue sheath which is in direct connection with the pial sheath. The optic nerve-fibers extend through the lamina cribrosa into the retina, where they spread out as the nerve-fiber layer in the manner previously described.

9. BLOOD-VESSELS OF THE OPTIC NERVE AND RETINA.

The blood-vessels of the optic nerve are principally derived from the vessels of the pial sheath. In that portion of the nerve containing the central vessels of the retina the latter anastomose with the pial vessels, so that this portion of the optic nerve is also supplied by the central vessels. At their entrance through the sclera the short posterior ciliary arteries form a plexus around the optic nerve, the *arterial circle of Zinn,* which communicates, on the one hand, with the vessels of the pial sheath, and, on the other, with those of the optic nerve. At the level of the choroid the vessels of the latter communicate by means of capillaries with the central vessels of the optic nerve.

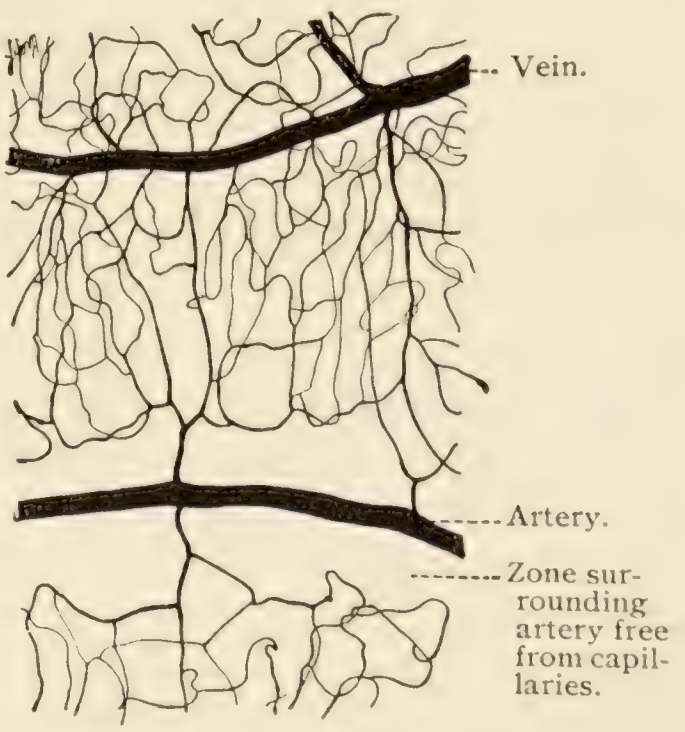

Fig. 362.—Injected blood-vessels of the human retina; surface preparation; × 18.

The *central artery and vein* of the retina enter and leave the retina at the optic papilla, dividing here, or even within

the nerve itself, into the *superior and inferior papillary artery and vein.* Both the latter again divide into two branches, the nasal and temporal arteriole and venule, known, according to their positions, as the *superior and inferior nasal and temporal artery and vein.*

Besides these vessels, two small arteries also arise from the trunk of the central artery itself, and extend to the macula. Two similar vessels extend toward the nasal side as the superior and inferior median branches. Within the retina itself the larger vessels spread out in the nerve-fiber layer, forming there a coarsely meshed capillary network connected by numerous branches with a finer and more closely meshed network lying within the inner

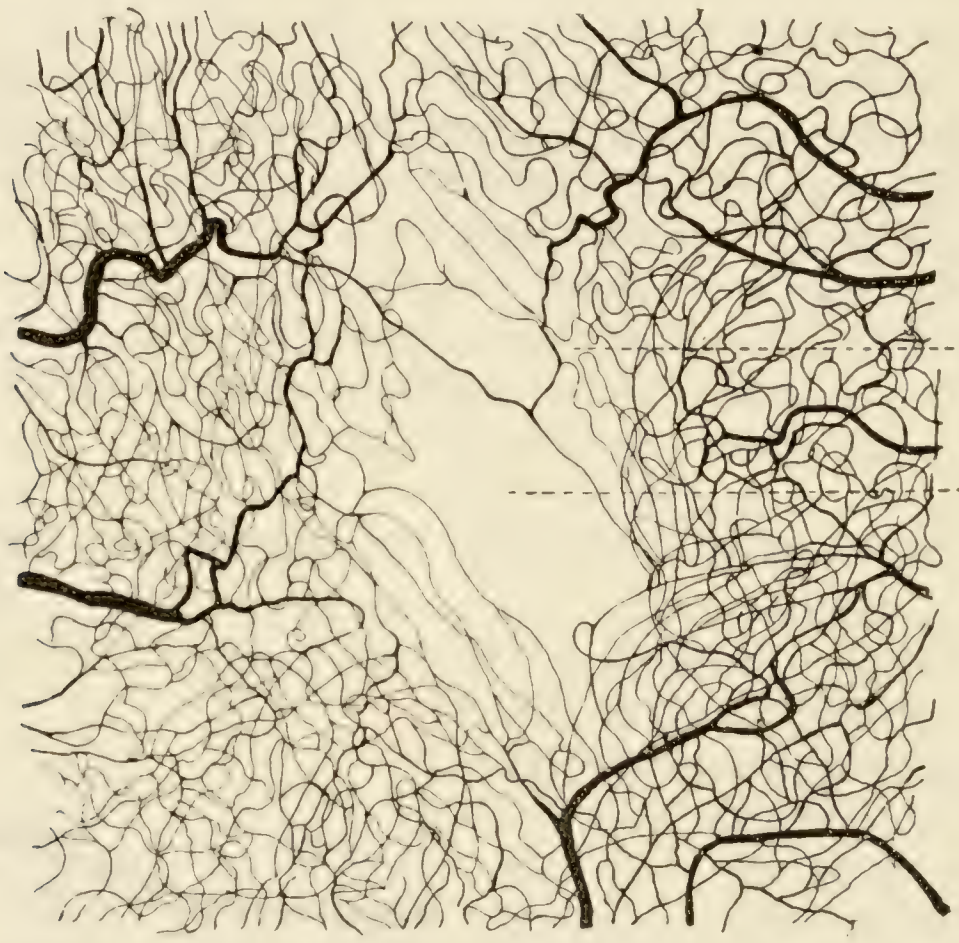

Fig. 363.—Injected blood-vessels of human macula lutea ; surface preparation ; × 28.

nuclear layer. The venous capillaries of this network return as small venous branches to the nerve-fiber layer, in which they form a venous plexus, side by side with the arterial plexus.

The arteries of the retina are of smaller caliber than the veins. The larger arteries possess a muscular layer ; the smaller, only an adventitia. All the vessels possess highly developed perivascular sheaths. The visual-cell layer is nonvascular, as are also the fovea centralis and the rudimentary retinal layers lying anterior to the ora serrata.

The arteries of the retina anastomose with one another solely by means of capillaries (end-arteries), and it is only in the ora serrata that coarser venous anastomoses exist.

F. THE VITREOUS BODY.

The **vitreous body** is a tissue which consists almost entirely of fluid, containing very few fixed cellular elements and only a small number of leucocytes, which are found more particularly in its outermost portion. Thin structureless lamellæ and fibers occur throughout the entire vitreous body, with the exception of the hyaloid canal. These fibrils form an interlacing network with wide meshes. They differ chemically from both the white fibrous tissue and yellow elastic fibers, resembling in some respects cuticular formations (von Ebner). These are particularly numerous at the periphery and especially in the region of the ciliary body. Toward the surface the fibrils are more densely arranged, forming the **hyaloid membrane** of the vitreous body, separating the latter from the retina. This membrane is somewhat thicker in the region of its close attachment around the physiologic excavation of the optic nerve and to the internal limiting membrane of the retina in the ciliary region. In the latter region the hyaloid membrane is in close relation with the epithelium of the pars ciliaris retinæ. It does not, however, penetrate into and between the ciliary processes, but extends like a bridge over the furrows between them. This arrangement gives rise to spaces, the *recessus cameræ posterioris*, which form a division of the posterior chamber, and are inclosed between the hyaloid membrane, the ciliary processes, the suspensory ligament of the lens, and the lens itself; these spaces are filled with aqueous humor. In the region of the ciliary processes the hyaloid membrane is closely associated with numerous fibers, which diverge fan-like toward the lens and become blended with the outer lamella of the lens-capsule. These fibers appear to arise from the epithelium of the pars ciliaris retinæ, and may be regarded as cuticular formations. Those coming from the free ends of the ciliary processes become attached along the equator of the lens and to the adjacent posterior portion of the lens-capsule. On the other hand, the fibers originating between the ciliary processes attach themselves to the anterior surface of the lens-capsule in the immediate vicinity of the equator. Together these fibers constitute the *zonula ciliaris*, *zonule of Zinn*, or the **suspensory ligament of the lens.** Between these fibers of the zonula and the lens itself there is, consequently, a circular canal divided by septa, the **canal of Petit,** which communicates by openings with the anterior chamber.

G. THE CRYSTALLINE LENS.

As we have already seen, the **crystalline lens** originates as an ectodermic invagination, which then frees itself from the remaining ectoderm in the shape of a vesicle and becomes transformed into the finished lens. In this process the cells of the inner wall of the vesicle become the lens-fibers, while those of the outer portion re-

main as the anterior epithelium of the lens. The lens is surrounded on all sides by the lens-capsule.

The **lens capsule** is a homogeneous membrane, nearly twice as thick on the anterior surface of the lens as on the posterior. Its chemic reactions differ from those of connective tissue, and in this respect it may be compared with the membranæ propriæ of glands. In sections the lens capsule appears to possess a tangential striation; under the influence of certain reagents, and under proper preliminary treatment, lamellæ may be detached from its surface which are found to be directly connected with the fibers of the suspensory ligament.

The **anterior epithelium** consists, in the fetus, of columnar cells; in children, of cells approaching the cubic type; and in the adult, of decidedly flattened cells. Toward the equator of the lens, in the so-called transitional zone, the cells increase in height and gradually pass over into the lens fibers.

The **lens fibers** are also derivatives of epithelial cells; they are long, flattened, hexagonal prisms, which extend through the entire thickness of the lens. In the adult the lens may be differentiated into a resistant peripheral and a softer axial substance. The surfaces of the fibers present irregularities, and it is with the help of these serrations and a cement substance that the fibers are bound together. Each fiber possesses one or more nuclei, which, although they have no constant position, are usually found in the middle of the fibers situated near the lens-axis, and in the anterior third of those at some distance from the axis. The course of the fibers in the lens is extremely complicated.

H. THE FETAL BLOOD-VESSELS OF THE EYE.

In the eye of the embryo the vitreous body and the capsule of the lens contain blood-vessels. The vessel which later becomes the central artery of the retina passes through the space subsequently occupied by the vitreous body as far as the posterior surface of the lens (anterior hyaloid artery) and branches in the region of the posterior and anterior lens-capsule. The anterior vascular membrane of the lens capsule of the embryo is known as the *membrana capsulopupillaris*, and that portion corresponding to the pupil, as the *membrana pupillaris*. In the embryo numerous other vessels arise at the papilla and extend over the surface of the vitreous body close to the hyaloid membrane; these are the *posterior hyaloid arteries*. These vessels later disappear. In place of the anterior hyaloid artery there remains in the vitreous humor a transparent cylindric cord containing no fibers nor lamellæ, as is the case in the remaining portion of the vitreous body, and consisting of a more fluid substance; this is the *hyaloid canal*, or the *canal of Cloquet*.

With regard to the posterior hyaloid vessels, the generally accepted theory is that they later enter into the formation of the retinal vessels. Little is known as to the details of this process; but the fact remains that, in the rabbit, for instance, the larger branches of the retinal vessels are internal to the inner limiting membrane, and, therefore, within the vitreous body, and that they send smaller branches into the retina (His, 80).

I. INTERCHANGE OF FLUIDS IN THE EYEBALL.

The **anterior lymph-channels** of the eye comprise (1) the lymph-canaliculi of the cornea, which communicate with similar structures in the sclera; (2) the system of the anterior chamber, which is indirectly connected, on the one hand, with the canal of Schlemm by means of the spaces of Fontana, and with the stroma iridis, into which the ligamentum pectinatum extends; while, on the other hand, it communicates with the posterior chamber and its recesses, and with the canal of Petit.

In the posterior region of the eyeball are the lymph-channels of the retina (the perivascular spaces), those of the optic nerve, the space between the pigment layer and the remaining portion of the retina (interlaminar space, Rauber), and the lymph-spaces of the choroid and sclera. The influx and efflux of intraocular fluid occur principally by means of filtration. The influx takes place through the ciliary processes; that the choroid has to do with this process is very improbable. The efflux takes place through the veins of the canal of Schlemm, into which the fluid filters through the cement lines of the endothelial lining of the canal of Schlemm, finally emptying into the anterior ciliary veins. A posterior efflux from the vitreous body probably does not exist, or at least occurs to a very limited extent. The anterior chamber possesses no efferent lymph-vessels (Leber, 95).

J. THE PROTECTIVE ORGANS OF THE EYE.

1. THE LIDS AND THE CONJUNCTIVA.

At the end of the second month of embryonic life the eyelids begin to develop in the shape of two folds of skin. At the end of the third month these folds come in contact in the region of what is later the palpebral fissure, and grow together at their outer epithelial margins. Shortly before birth the two lids again separate and the definitive palpebral fissure is formed.

The eyelids show three distinct layers: (1) the external cutis, which presents special structures at its free margin and continues about 1 mm. inward from the inner border of the free margin; (2) the mucous membrane, or palpebral conjunctiva, beginning from

this line and covering the entire internal surface; and (3) a middle layer.

1. The **cuticular portion** of the eyelid consists of a thin epidermis and a dermis poorly supplied with papillæ. Fine lanugo-like hairs with small sebaceous glands and a few sweat-glands are distributed over its entire surface. The cutaneous connective tissue is very loose, contains very few elastic fibers, and is supplied with pigment cells in the superficial layers. At the *lid-margin* the papillæ are well developed and the epidermis is somewhat thickened. The anterior margin supports several rows of larger hairs, the *cilia*, the posterior row of which possesses, besides the sebaceous glands, modified sweat-glands, the *ciliary glands of Moll*, which also empty into or near the hair follicles. The ciliary glands are readily distinguished from the sweat glands; their tubules are relatively large, often showing alternating large vesicular segments and short narrow segments. A branching of the tubules has also been observed (Huber). The eyelids are further provided with numerous glands, known as the Meibomian or tarsal glands. About thirty of these glands are found in the upper, a slightly smaller number in the lower, lids. They lie within the tissue of the tarsus vertical to the palpebral margin. Each gland consists of a tubular duct, lined by stratified squamous epithelium, beset with numerous simple or branched alveoli lined by a stratified, cubic epithelium in every respect similar to that lining the alveoli of sebaceous glands. The ducts of these glands terminate at the palpebral margin posterior to the cilia. (See Fig. 364.)

2. The **conjunctival portion** of the eyelids is lined by a simple pseudostratified columnar epithelium, possessing two strata of nuclei. This is continuous with the bulbar conjunctiva at the conjunctival fornix, and is characterized by the occasional presence of folds and sulci. Longitudinal folds in the upper portion of the upper lid running parallel with the lid-margin are frequently present. Goblet cells are usually found in the epithelium. According to W. Pfitzner (97), the epithelium of the conjunctiva consists of two or three strata of cells, of which the more superficial possess a cuticular margin. Certain structures which have always been regarded as goblet cells are in all probability similar to the *cells of Leydig—i. e.*, mucous cells, which do not pour their secretion out over the surface of the epithelium. Some lymphoid tissue is always found in the stratum proprium of the mucous membrane, and occasionally it is seen to form true lymph-nodules. It is of some interest to note that a marked production of these lymph-nodules occurs in certain diseases. Such lymph-nodules are usually associated with epithelial crypts, which fact led Henle to regard them as glandular formations. Small glands with a structure similar to that of the lacrimal glands are also present in the palpebral conjunctiva; they are known as accessory lacrimal glands and are found in the upper eyelid, at the outer angle of the conjunctival fornix. Similar glands occur also at the mesial angle of the fornix.

3. Besides the *tarsus* (fibrocartilage) the **middle layer of the eyelid** contains: (1) The musculus orbicularis oculi, which lies beneath

Fig. 364.—Vertical section of the upper eyelid of man; × 14: *at*, arterial arcus tarseus; *c*, cilia; *dgt*, excretory duct of Meibomian gland; *glc*, ciliary gland (Moll); *McR*, ciliary muscle of Riolani; *Mop*, m. orbicularis palpebrarum; *Mt*, nonstriated muscle-fibers of the tarsal muscle and tendon of the levator palpebræ superioris; *nlc*, lymph-node of the conjunctiva palpebræ; *T*, tarsus (Sobotta, "Atlas and Epitome of Histology.").

the subcutaneous tissue. At the margin of the lid this structure gives off the musculus ciliaris Riolani, which is composed of two

fasciculi separated by the tarsus. (2) The connective tissue between the bundles of the musculus orbicularis oculi. (3) The connective tissue lying behind the latter and the tarsus. In the upper lid the connective tissue mentioned under 2 and 3 is connected with the tendon of the musculus palpebralis superior. The latter is composed of smooth muscle-fibers, and is regarded as a continuation of the middle portion of the striated, voluntary musculus levator palpebræ superioris. The middle layer of the lower lid is struc-

Fig. 365.—Meibomian or tarsal gland, reconstructed after Born's wax-plate method; × 20.

turally analogous, except that here a fibrous expansion from the sheath of the inferior rectus muscle takes the place of the levator palpebræ.

The blood-vessels of the eyelid lie directly in front of the tarsus, and from this region supply adjacent parts; they reach the posterior portion of the lid either by penetrating the tarsus or by encircling it (Waldeyer, 74). The lymph-vessels form a plexus in front and one behind the tarsus.

The "third eyelid," the plica semilunaris, contains, when well developed, a small plate of hyaline cartilage.

At the fornix the epithelium of the palpebral conjunctiva becomes continuous with the two- or three-layered squamous epithelium of the conjunctiva bulbi. Beneath this epithelium is found a loose fibro-elastic connective tissue, presenting subepithelial papillæ, and quite vascular. In it are found medullated nerve-fibers, some of which terminate in free sensory nerve-endings in the conjunctival epithelium; others terminate, especially near the corneal margin, in end-bulbs of Krause; and still others may be traced to the cornea, to terminate in a manner previously described.

2. THE LACRIMAL APPARATUS.

The lacrimal apparatus consists of the lacrimal glands, their excretory ducts, the lacrimal puncta and canaliculi, the lacrimal sac, and the nasal duct.

The **lacrimal gland,** which is a branched tubular gland, is separated into two portions, of which the one lies laterally against the orbit and the other close to the upper lateral portion of the superior conjunctival fornix. The structure of the gland is, on the whole, that of a serous gland (parotid), with the difference that the intralobular ducts are not lined by a striated epithelium such as is found in the salivary tubules, and that those cells which are wedged in between the secretory elements and functionate as sustentacular cells (basket-cells) are here much more highly developed.

The excretory ducts of the orbital division generally pass by the conjunctival half of the gland, taking up a few ducts from the latter as they go, and finally empty on the surface of the conjunctiva. Aside from these, the lateral portion of the gland possesses also independent ducts. All the excretory ducts are lined by columnar epithelium and surrounded by a relatively thick connective-tissue wall having inner longitudinal and outer circular fibers. From the lateral portion of the conjunctival culdesac, into which the secretion is brought by the excretory ducts of the lacrimal gland, the secretion passes into the capillary space of the sac, and is then evenly distributed by means of the sulci and papillæ over the conjunctival surface of the lid. In this manner the secretion reaches the mesial angle of the lid, whence it passes through the lacrimal puncta into the lacrimal canals.

The nerve supply of the lacrimal glands is from the sympathetic nervous system. The neuraxes of sympathetic neurones accompany the gland ducts and form plexuses about the alveoli, the terminal branches of which may be traced to the gland cells.

The lacrimal canals are lined by stratified squamous epithelium, and possess a basement membrane as well as a connective-tissue layer containing circularly disposed elastic elements. Externally we find a layer of transversely striated muscle-fibers.

The **lacrimal sac** is provided with a simple pseudostratified columnar epithelium having two strata of nuclei. In it goblet cells are also found. The **nasal duct** is lined by a similar epithelium. The connective-tissue wall of the latter and that of the lacrimal sac come in contact with the periosteum; between them is a well-developed vascular plexus. Stratified squamous and ciliated epithelium have been described as being present in the nasal duct, as well as mucous glands in both nasal duct and lacrimal sac. (See works of M. Schultze, 72; Schwalbe, 87.)

TECHNIC.

The eyes of the larger animals, after having been previously cleaned by removing the muscles and loose connective tissue, are placed in the fixing fluid and cut into two equal parts by means of an equatorial incision. Smaller eyes with thin walls may be fixed whole.

Müller's fluid, nitric acid, and Flemming's fluid are usually employed as fixing agents. After fixing in one of these fluids, different parts of the eyeball are imbedded in celloidin or celloidin-paraffin and then sectioned.

The corneal epithelium is best macerated in 33% alcohol; the membrane of Descemet may be impregnated with silver. In order to bring the fibers of the latter into view, Nuel recommends an injection of 1% to 2% formic acid into the anterior chamber of the eye of a dove or a rabbit, after having drawn off the aqueous humor. The cornea is then cut out, and fixed for from three to five minutes in osmic acid.

The substantia propria is examined either by means of sections or by means of teased preparations from a cornea macerated in lime-water or potassium permanganate. The sections are stained with picro-carmin (Ranvier). The corneal spaces and canaliculi may be demonstrated in two ways with the aid of silver nitrate; either the fresh cornea of a small animal is stripped of its epithelium, cauterized with a solid stick of silver nitrate, and then examined in water, in which case the corneal spaces and their canaliculi show light upon a dark ground (negative impregnation); or the corneæ of larger animals are treated in the same manner, after which tangential sections are made with a razor, and placed in water for a few days; in this case the corneal spaces and their canaliculi show dark upon a light ground (positive impregnation, Ranvier, 89).

By means of Altmann's oil method casts of the corneal spaces and their canaliculi may be made. Treatment by the gold method often brings out not only the nerves, but also the corneal corpuscles and their processes.

Ranvier (89) especially recommends a 1% solution of the double chlorid of gold and potassium for the corneal nerves. The cornea of the frog is treated for five minutes with lemon-juice, then for a quarter of an hour with 1% potassium-gold chlorid solution, and, finally, for one or two days with water weakly acidulated with acetic acid (2

drops to 30 c.c. of water), the whole process taking place in the light. Golgi's method may also be used, but the gold method is more certain.

The sclera is treated in a similar manner.

The pigmentation of the vascular layer interferes with examination, and albinotic animals should therefore be selected; or the pigment may be removed from the previously fixed eyeball with hydrogen peroxid or nascent chlorin. The latter method is applied exactly as in cases where the removal of osmic acid is desired.

The adult lens is sectioned with difficulty, as it becomes very hard in all fixing fluids. The anterior capsule of the lens may be removed from previously fixed specimens and examined by itself. The lens-fibers are demonstrated by maceration in ⅓ alcohol (twenty-four hours) or in strong nitric acid. Before immersion the lens-capsule is opened by a puncture.

The retina can rarely be kept unwrinkled in eyes that have been fixed whole. The eyeball should therefore be opened in the fixing fluid and the latter permitted to act internally; or the external tunics are removed, thereby enabling the fixing fluid to act externally.

Ranvier recommends subjecting the eyes of smaller animals (mouse, triton) for a quarter or half hour to the action of osmic acid fumes (see p. 24), after which the eyes are opened in ⅓ alcohol with the scissors. At the end of three or four hours the posterior half of the eye is stained for some time in picrocarmin (p. 44), then carried over into 1% osmic acid for twelve hours, washed with water, treated with alcohol, and cut.

In osmic acid preparations the rod-nuclei show dark transverse bands, a condition due to the fact that the end-regions of the nuclei stain more deeply.

The retina is a good object for differential staining, as, for instance, with hematoxylin-eosin, hematoxylin-orange G, etc. The latter combination is particularly successful in staining the rod- and cone-ellipsoids. The examination of tangential sections should not be omitted.

With the retina the best results are obtained by means of Golgi's method. Attention must be called to the fact that the supporting structures of the retina are more easily impregnated than the nervous elements, and that the latter can be demonstrated to any extent only in very young eyes.

Ramón y Cajal (94) recommends the following method, modified after Golgi: After the removal of the vitreous humor the posterior half of the eyeball is placed for one or two days in a mixture containing 3% potassium bichromate 20 c.c. and 1% osmic acid 5 or 6 c.c. The pieces are then dried with tissue paper and placed in a 0.75% silver nitrate solution for an equal length of time. Without washing, the pieces are immersed for from twenty-four to thirty-six hours in a mixture containing 3% potassium bichromate 20 c.c., and 1% osmic acid 2 or 3 c.c., and then again carried over into a 0.75% silver nitrate solution for twenty-four hours. In order to prevent precipitation it is advisable to roll up the retina before treating, and to cover it with a thin layer of a thin celloidin solution, which prevents it from again unrolling.

The methylene-blue method (p. 184) will also bring out the nervous elements of the retina, although the results are not quite so satisfactory as those obtained by Golgi's method.

IX. THE ORGAN OF HEARING.

THE ear, the organ of hearing, consists of three parts: (1) The external ear, including the pinna or auricle and the external auditory canal; (2) the middle ear, tympanum, or tympanic cavity, containing the small ear bones and separated from the external auditory canal by the tympanic membrane, but communicating with the pharynx by means of the Eustachian tube; (3) the inner ear, or labyrinth, consisting of a bony and a membranous portion, the latter lined by epithelial cells, especially differentiated in certain regions to form a neuro-epithelium, in which the auditory nerves terminate. The first two parts serve for the collection and transmission of the sound-waves; the complicated labyrinth, with its differentiated neuro-epithelium, for the perception of the same. Figure 366 presents in a schematic way the relationships of the parts here mentioned.

A. THE EXTERNAL EAR.

The cartilage of the ear, including that of the external auditory passage, is of the elastic variety, but differs from typical elastic cartilage in that it contains areas entirely free from elastic fibers. The elastic reticulum is, however, never absent near the perichondrium. The skin covering the pinna is thin, and in it are found hairs with relatively large sebaceous glands; sweat-glands are found on the outer surface.

The skin lining the cartilaginous portion of the external auditory canal is somewhat mobile and possesses very few pronounced papillæ, and is characterized by the presence of so-called *ceruminous glands*, which represent modified and very highly differentiated sweat-glands. They are branched, tubulo-alveolar glands (Huber). They empty either into the hair follicles near the surface of the skin or on to the surface of the skin in the neighborhood of the hair follicles.

The skin lining the osseous portion of the external auditory canal is supplied with neither hair nor glands, and possesses slender papillæ, especially in the neighborhood of the tympanic membrane. The corium is closely attached to the periosteum.

The tympanic membrane consists of a tense and a flaccid portion. It forms a part of both the external and the middle ear. From without inward, the following layers may be differentiated: (1) the cutaneous layer; (2) the lamina propria; and (3) the mucous layer.

The epidermis of the cutaneous layer is identical in structure with that of the outer skin, except that the superficial layers of the stratum corneum contain nucleated cells. The corium is very thin, except along the course of the manubrium of the malleus, where it

is thickened, forming the so-called *cuticular ridge*, which possesses papillæ and is supplied with vessels and nerves.

The lamina propria ends peripherally in a thickened ring of fibro-elastic tissue, the *annulus fibrosus*, which unites at the sulcus tympanicus with the periosteum of the latter. The lamina propria is composed of connective-tissue fibers, in which two layers may be distinguished—externally, the radiate fibers, the *stratum radiatum*, and internally, the circular fibers, the *stratum circulare*. The external radiate layer extends from the annulus to the umbo and manubrium, and is interrupted in the flaccid portion of the tympanic

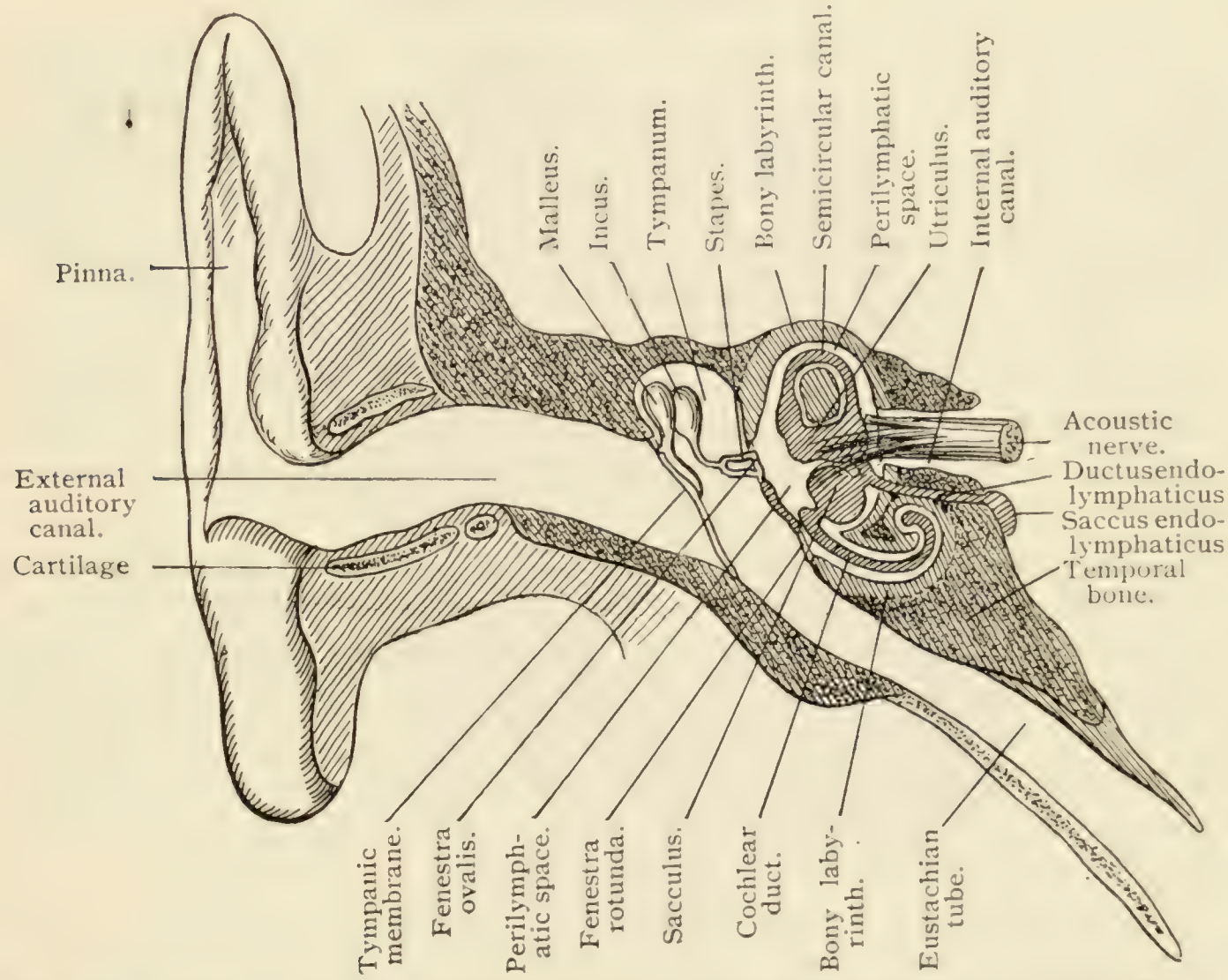

Fig. 366.—Schematic representation of the complete auditory apparatus (Schwalbe).

membrane by the upper fourth of the manubrium and the short process of the malleus; it gradually thins out toward the center until it finally disappears in the vicinity of the umbo. The fibers of the inner (circular) layer are circularly disposed. This layer is thickest at the periphery of the tympanic membrane, becoming gradually thinner toward the lower end of the manubrium, where it disappears. Between the two layers of the lamina propria is a small quantity of loose connective tissue. The manubrium of the malleus is inclosed within the tympanic membrane. This is due to the union of the fibers of the radial layer with the outer strata of the manubrial perichondrium, the handle of the malleus being here covered by a thin layer of cartilage. In the posterior upper quadrant of the tympanic membrane the two layers of the lamina propria

intermingle, forming irregularly disposed bundles and trabeculæ, the *dendritic fibrous structures of Gruber.*

The mucous layer of the tympanic membrane consists of simple squamous epithelium separated from the lamina propria by a thin connective-tissue layer containing but few cells. It likewise extends over the handle of the malleus. In the flaccid portion of the tympanic membrane the lamina propria disappears, so that in this region the cutaneous layer and the mucous membrane are in direct contact.

B. THE MIDDLE EAR.

The middle ear, or tympanum, is a small irregular cavity, filled with air, situated in the petrous portion of the temporal bone between the bony wall of the inner ear and the tympanic membrane, and communicates with the pharynx through the Eustachian tube. It contains the small bones of the ear, their ligamentous attachments, and, in part, the muscular apparatus moving them.

The mucous membrane lining the tympanic cavity is folded over the ossicles and ligaments of the tympanum and is joined to that of the tympanic membrane and the Eustachian tube, the line of junction with the former being marked by the presence of papilla-like elevations.

The epithelium of this mucous membrane is a simple pseudo-stratified ciliated epithelium, having two strata of nuclei. Cilia are, however, lacking on the surface of the auditory ossicles, on their ligaments, and on the promontory of the inner wall, as well as on the tympanic membrane. The mucosa of the mucous membrane is intimately connected with the periosteum, and may now and then contain short isolated alveolar glands, especially in the neighborhood of the opening of the Eustachian tube.

The "auditory ossicles" are true bones with Haversian canals and lamellæ; with the exception of the stapes, they contain no marrow-cavity. Very distinct perivascular spaces are seen surrounding the vessels in the canals (Rauber). The malleus articulates with the incus, both articular surfaces being covered with hyaline cartilage. Within this articulation we find a fibrocartilaginous meniscus, and at the summit of the short limb of the incus another small cartilage plate. Between the lenticular process of the incus and the capitulum of the stapes is another articulation, also provided with cartilaginous articular surfaces. The basal plate of the stapes is covered both below and at its edges with cartilage, as are also the margins of the fenestra ovalis (fenestra vestibuli). The basal plate is held in place within the fenestra by an articulation, provided with tense ligamentous structures on the tympanic and vestibular sides. Between these the connective tissue is quite loose. All the cartilaginous portions of the auditory ossicles, with the ex-

ception of the articular cartilages, rest on the periosteum (Rüdinger, 70).

The *fenestra rotunda* (fenestra cochleæ) is closed by the secondary or inner tympanic membrane, a connective-tissue membrane containing vessels and nerves, the outer wall of which is covered by ciliated epithelium, the inner (the surface toward the scala tympani) by flattened endothelial cells.

In the antrum and mastoid cells, the mucosa of the mucous membrane is immovably fixed to the periosteum. The epithelium is of the simple squamous variety and is nonciliated.

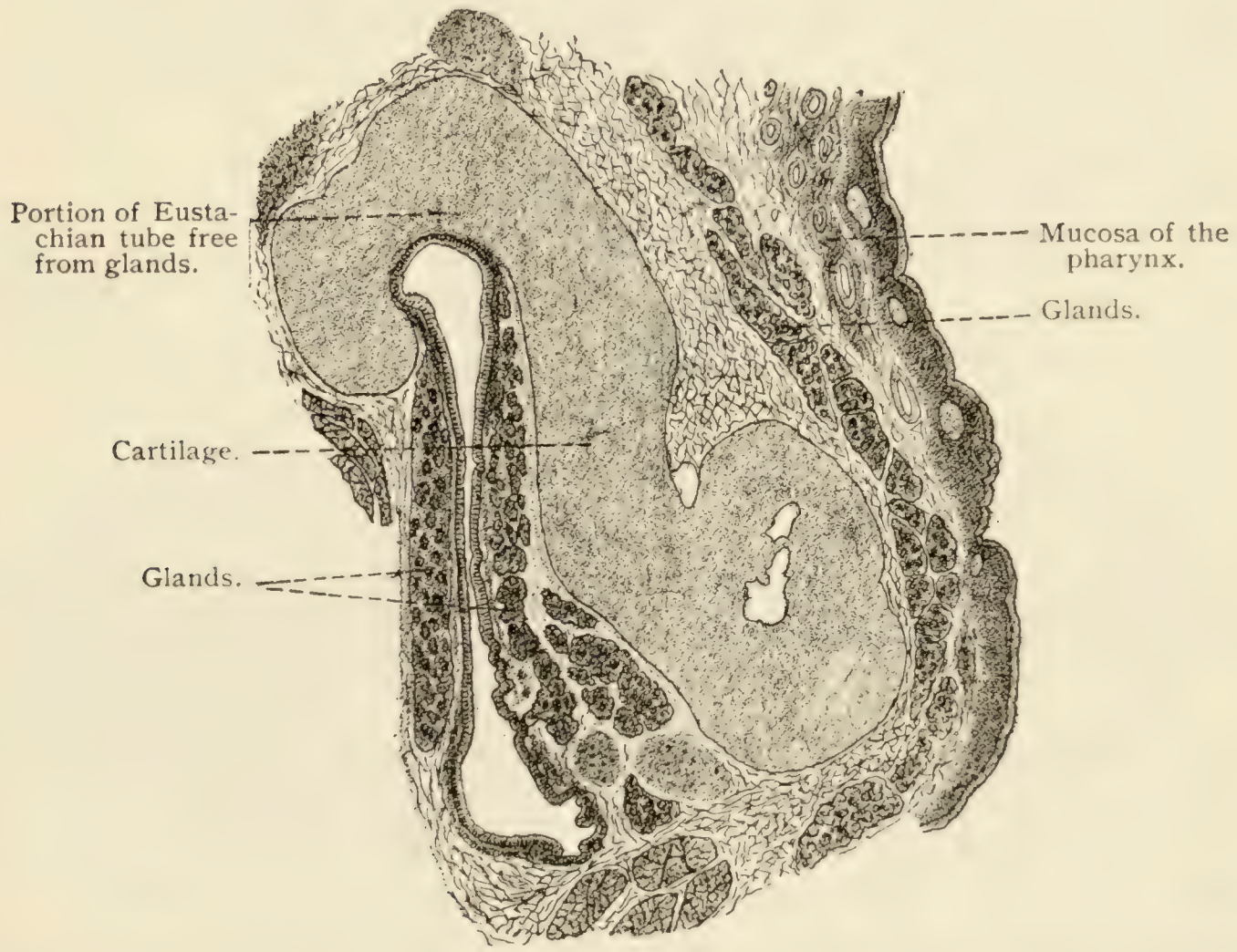

Fig. 367.—Cross-section of the Eustachian tube with its surrounding parts; × 12 (from a preparation by Professor Rüdinger).

The mucous membrane of the osseous portion of the Eustachian tube is very thin, and its mucosa is intimately connected with the periosteum. Its epithelium is of the simple pseudostratified ciliated variety, having two strata of nuclei. There are no glands. The mucous membrane of the cartilaginous portion of the Eustachian tube is thicker, and its epithelium, which is of the stratified ciliated variety, is higher, and often contains goblet-cells. Lymphoid tissue may be demonstrated in the mucosa of this portion, and occasionally structures resembling lymph-nodules are found, especially in the vicinity of the pharyngeal opening of the tube. In the cartilaginous portion of the tube are mucous glands, which are particularly

numerous in the vicinity of the pharyngeal opening (Rüdinger, 72, 2). The cartilage of the Eustachian tube is in part yellow elastic, in part hyaline, and in certain portions presents the appearance of white fibro-cartilage.

C. THE INTERNAL EAR.

The internal ear consists of an osseous and a membranous portion, the *osseous* and the *membranous labyrinths;* the latter is contained within the former, and, although smaller, presents the same

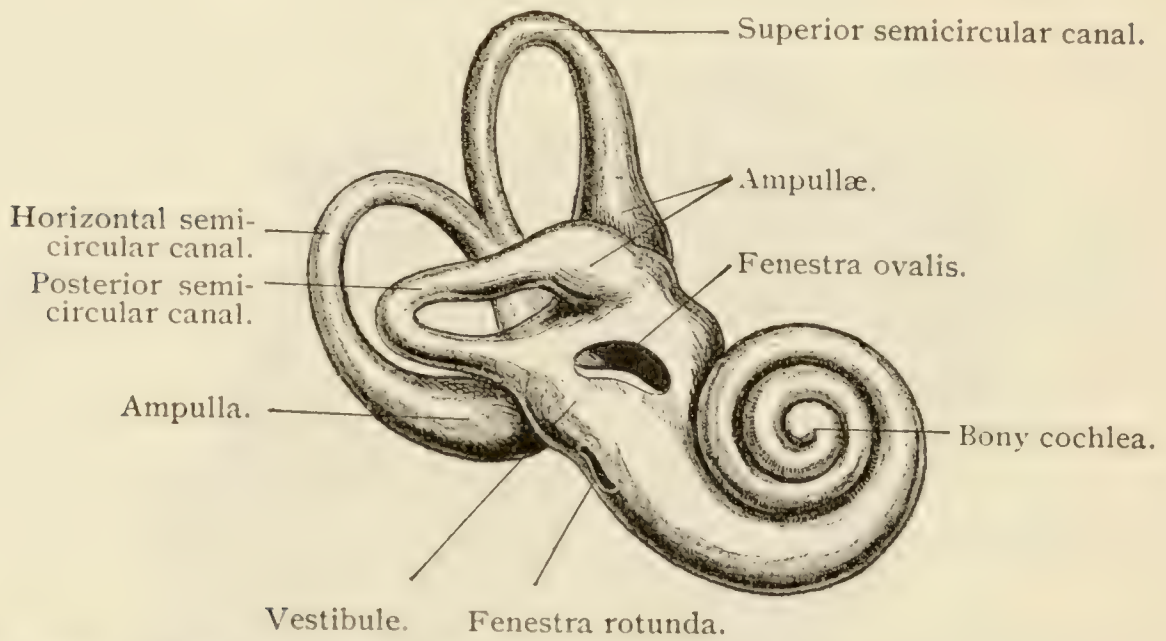

Fig. 368.—Right bony labyrinth, viewed from outer side: The figure represents the appearance produced by removing the petrous portion of the temporal bone down to the denser layer immediately surrounding the labyrinth (from Quain, after Sömmering).

general shape. The two structures are separated by a lymph-space containing the perilymph.

In the *bony labyrinth* we recognize a central portion of ovoid shape, known as the *vestibule*, the outer wall of which forms the inner wall of the tympanum and presents two openings, the fenestra ovalis and the fenestra rotunda, separated by a ridge known as the promontory. This ridge becomes continuous with the lower portion of the bony cochlea, anterior and mesial to the vestibule and having the shape of a blunt cone. From the posterior portion of the vestibule arise three semicircular canals, known respectively as the *external* or *horizontal semicircular canal*, the *anterior superior vertical*, and the *posterior inferior vertical semicircular canals*. The canals communicate with the vestibule by means of five openings, the superior contiguous portions of the anterior and posterior canals uniting to form the *canalis communis* before reaching the vestibule. The three canals present near their origin from the vestibule enlargements known as the osseous ampullæ. The osseous labyrinth is lined throughout by a thin layer of periosteum, covered by a layer of endothelial cells.

The **membranous labyrinth** differs in shape from the osseous labyrinth in that, in place of the single chamber (vestibule) of the latter, the membranous labyrinth presents two sacs, the **utriculus** and the **sacculus**, united by a narrow duct, the **utriculosaccular duct**. The utriculus is the larger, and from it arise the membranous semicircular canals. These present ampullæ, situated within the osseous ampullæ previously mentioned. The sacculus communicates with the cochlear duct by means of the canalis reuniens (Hensen). From the utriculosaccular duct arises the ductus endolymphaticus, which passes through the aqueductus vestibuli and ends in a subdural *saccus endolymphaticus* on the posterior surface of the petrous portion of the temporal bone.

In the membranous labyrinth the nerves are distributed over certain areas known as the *maculæ*, *cristæ*, and *papilla spiralis*.

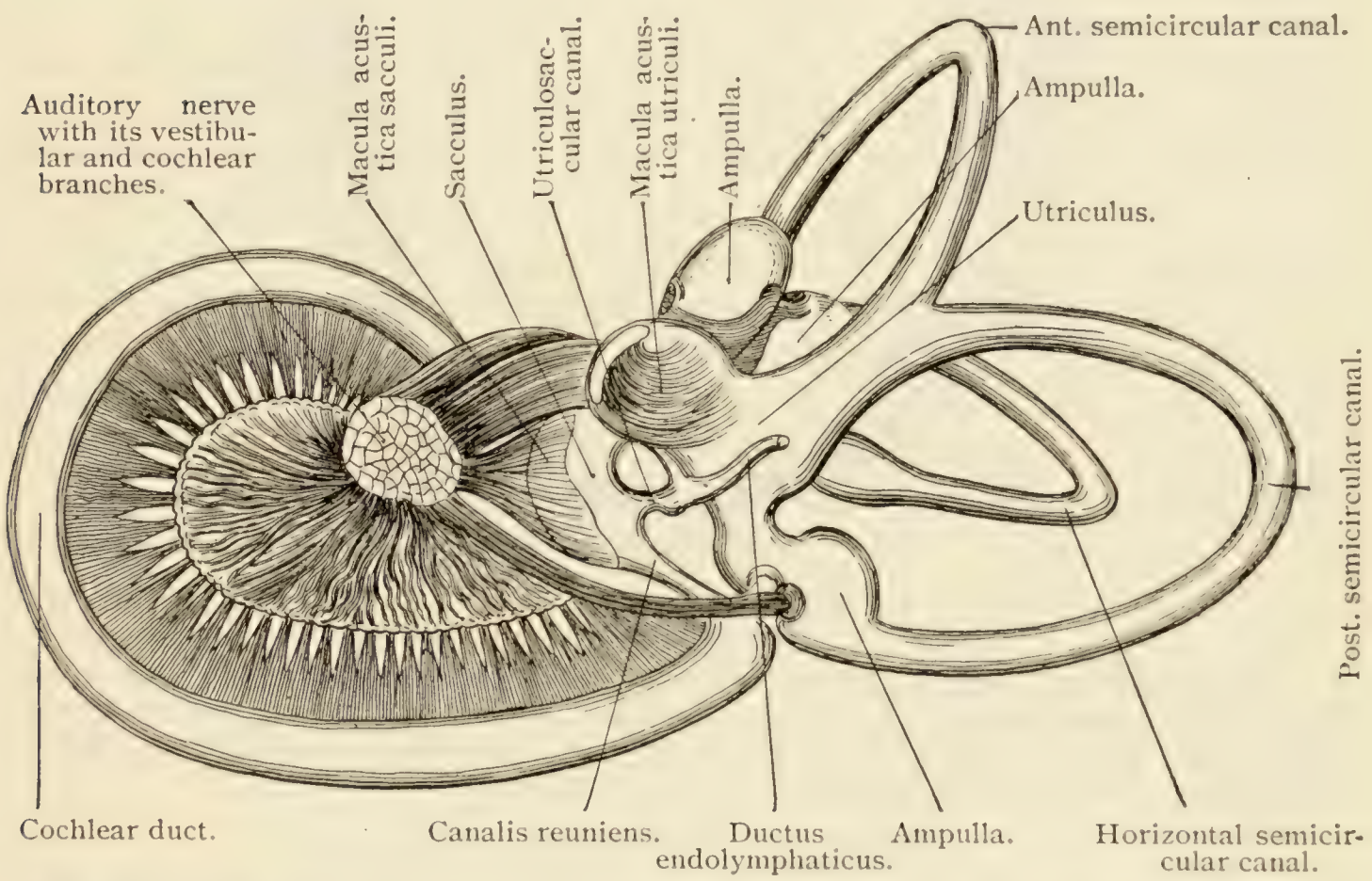

Fig. 369.—Membranous labyrinth of the right ear from five-month human embryo (from Schwalbe, after Retzius).

There is a macula within the recess of the utriculus, the *macula acustica utriculi;* and another within the sacculus, the *macula acustica sacculi;* cristæ are present in the ampullæ of the upper, posterior, and lateral semicircular canals, the *cristæ ampullares sup., post., et lat.* Besides these, we have the terminal arborization of the acoustic nerve in the membranous cochlea, the *papilla spiralis cochleæ*, or the organ of Corti.

1. UTRICULUS AND SACCULUS.

Only the inner wall of the utriculus is connected with the periosteum of the vestibule. In this region lies the corresponding

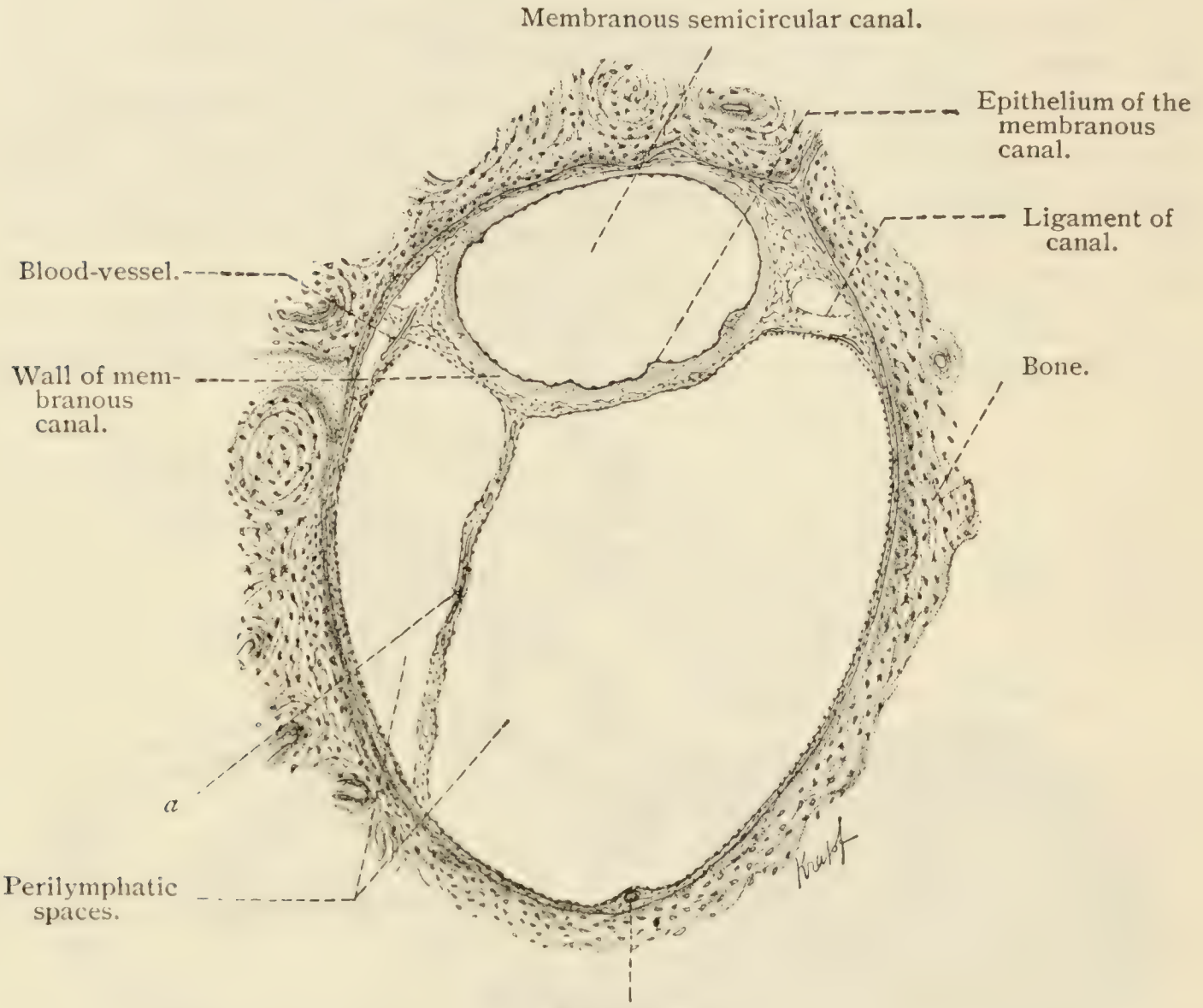

Fig. 370.—Transverse section through an osseous and membranous semicircular canal of an adult human being; × 50 (after a preparation by Dr. Scheibe): *a*, Connective-tissue strand representing a remnant of the embryonic gelatinous connective tissue. Such strands serve to connect the membranous canal with the osseous wall.

macula cribrosa, through which the nerves penetrate to the macula of the utriculus. The utriculus and sacculus fill only a part of the inner cavity of the osseous vestibule. Between the osseous and membranous portions remains a space traversed by anastomosing connective-tissue trabeculæ, and lined by endothelium, which also forms an investing membrane around the trabeculæ. These trabeculæ pass on the one side into the periosteum lining the vestibule, and on the other, into the wall of the utriculus and sacculus. The cavity which they thus traverse represents a perilymphatic space. (Compare Fig. 370, which shows analogous relations in the semicircular canals.)

The wall of the utriculus, especially its inner portion, consists of dense fibrous connective tissue, most highly developed in the region of the macula acustica. In the immediate vicinity of the

macula utriculi the epithelium of the utriculus is high columnar in type ; in the remaining portion it consists of a single layer of low columnar cells, with a distinct basement membrane ; the epithelium of the macula itself is also high, and is composed of two kinds of elements—of sustentacular elements and of the so-called auditory hair-cells. The *sustentacular cells* are tall epithelial cells resting on the basement membrane by means of their single or cleft basal plates. Each possesses an oval nucleus lying at or beneath the center of the cell. The *hair-cells* are peculiar cylindric elements with somewhat thickened and rounded bases. One end extends to the surface of the epithelium, while the other, which contains the nucleus, extends only to the center of the epithelial layer. The free end is provided with a cuticular zone supporting a number of long, stiff hairs, which often coalesce to form single threads. On the surface of the epithelium, which must be regarded as a neuro-epithelium, are crystals of calcium carbonate, known as *otoliths*, each of which incloses a minute central vacuole (Schwalbe). The otoliths are inclosed in a homogeneous substance, the *otolithic membrane*, which coagulates in a network of filaments when subjected to the action of fixing agents.

The *nerve-fibers* going to the macula penetrate the wall, and, under the epithelium, undergo dichotomous division, and, after further division, form, in the region of the basilar ends of the auditory cells, a plexus consisting of fine ramifications, and embracing the lower ends of the auditory cells. A few fibers extend still further upward, where their telodendria enter into intimate relations with the acoustic cells (v. Lenhossék, 94, 1).

The structure of the sacculus is in every respect like that of the utriculus, and a further description of it is therefore unnecessary.

2. THE SEMICIRCULAR CANALS.

The membranous semicircular canals are attached at their convex surfaces to the periosteum of the bony canals, which they only partly fill, the remaining cavity being occupied by an eccentrically situated perilymphatic space traversed by connective-tissue trabeculæ. The walls of the perilymphatic spaces of the semicircular canals, like those surrounding the utriculus and the sacculus, are lined by endothelium, which covers, on the one hand, the periosteal surface of the bony semicircular canals, and, on the other hand, the outer wall of the membranous canals, together with the connective-tissue trabeculæ. The connective-tissue walls of the membranous canals are structurally similar to those of the utriculus and sacculus. Hensen compares their structure to that of the substantia propria of the cornea. In the adult, the inner layer of the wall of the canals supports here and there papillary elevations, which, however,

disappear along its attachment to the bony semicircular canal (Rüdinger, 72, 88).

The epithelium lining the membranous semicircular canals is simple squamous in character and very evenly distributed over the entire inner surface, including the papillæ previously mentioned. On the concave side of each semicircular canal the epithelial cells are somewhat narrower and higher. This inner and higher epithelium (raphé), extending along the concave side into the ampullæ, marks the region at which the semicircular canals were constricted off from the pocket-like anlagen. The epithelium of the ampullæ (Fig. 371), with the exception of that in the region of the raphé, is of the squamous type. At the cristæ of the ampullæ, however, there is found a neuro-epithelium similar to that of the maculæ. The cells adjoining both ends of the cristæ are high columnar, and to these the squamous epithelium is joined. The columnar cells just mentioned form the so-called *semilunar fold*. Otoliths are also present upon the neuro-epithelium of the cristæ. Here the structure corresponding to the otolithic membrane of the utriculus and sacculus is called the *cupula*. In preserved specimens it presents the appearance of a coagulum, showing a faint striation; in the fresh condition, it has never been recognized as a distinct structure, at least in the lower classes of vertebrates.

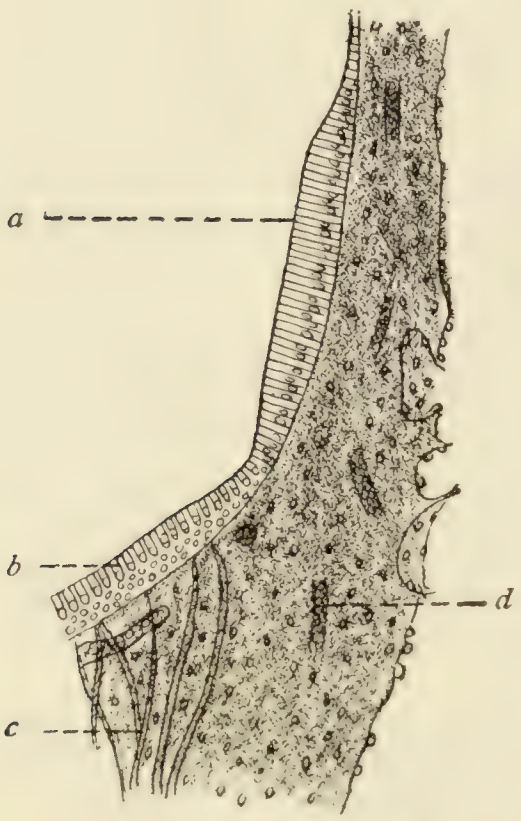

Fig. 371.—Part of a vertical section through the anterior ampulla, showing the membranous wall, a portion of the "crista acustica," and the "planum semilunatum" (after Retzius): *a*, Semilunar fold; *b*, crista acustica; *c*, nerve-fibers; *d*, blood-vessels.

3. THE COCHLEA.

The cochlea consists of an osseous portion, the *bony cochlea*, a membranous portion, the *cochlear duct*, and two perilymphatic canals. The bony cochlea consists of a central bony axis of conical shape, the *modiolus*, around which is wound a spiral bony canal, having in man a little over two and one-half turns, the modiolus forming the inner wall of this canal. The summit of the cochlea, which has the shape of a blunt cone, is formed by the blind end of this bony canal, and is known as the *cupola*. The modiolus further gives support to a spiral plate of bone, the *lamina spiralis ossea*, which extends from the lower part of the modiolus, and, forming two and one-half spiral turns, reaches its top, where it ends in a hook-like process, the *hamulus*. This bony spiral lamina partly

divides the bony cochlear canal into two parts, the division being completed by a fibrous tissue membrane, the *lamina spiralis membranacea*, which extends from the free edge of the osseous spiral lamina to a thickened periosteal ridge, the *ligamentum spirale*, lining the outer wall of the bony cochlear canal. The canal above the lamina spiralis (bony and membranous) is known as the *scala vestibuli*, that below as the *scala tympani*. Both are perilymphatic canals, and communicate in the region of the last half-turn of the cochlea, by means of a narrow canal, the *helicotrema*, partly surrounded by the termination of the bony spiral lamina, the hamulus. The scala vestibuli is in free communication with the perilymphatic space of the vestibule ; while the scala tympani communicates with perivascular spaces surrounding the veins of the cochlear aqueduct, which latter empty into the jugular veins. The scala tympani terminates at the secondary tympanic membrane, closing the fenestra rotunda.

The *cochlear duct*, which, as will be remembered, communicates with the sacculus by means of the canalis reuniens, is a long tube closed at both ends, the one end representing the vestibular sac, or *cæcum vestibulare*, and the other the cupolar extremity, or *cæcum cupolare*, also known as the lagena. The cochlear duct forms about two and three-fourths spiral turns, its length being about 3.5 mm. Its diameter gradually increases from its lower to its upper or distal extremity. The cochlear duct lies above the lamina spiralis, and, in a section of the cochlea parallel to the long axis of the modiolus, it is of nearly triangular shape, with the somewhat rounded apex of the triangle attached to the osseous lamina spiralis. In the cochlear duct we may distinguish the following parts : (1) the outer wall, which is intimately connected with the periosteum of the bony cochlear canal ; (2) the tympanal wall, resting on the membranous basilar membrane, with its highly differentiated neuro-epithelium, the spiral organ of Corti ; and (3) the vestibular wall, bordering on the scala vestibuli, the intervening structures forming a very delicate membrane—the *vestibular* or *Reissner's membrane*.

From the account given thus far, it may be seen that within the bony cochlear canal there are found three membranous canals, running parallel with one another and with the osseous lamina spiralis about which they are grouped. Two of these membranous canals, the scala vestibuli and the scala tympani, are perilymphatic spaces, and are consequently lined by endothelial cells ; between them is found the cochlear duct, from its position known also as the *scala media*, lined by epithelial cells. These three membranous canals retain their relative position in their spiral course about the modiolus, and, in a section through the cochlea parallel to the bony axis of the modiolus, would be met with at each turn, and at each turn present essentially the same relative position and structure. In figure 372, which is from a longitudinal section of the cochlea

of a cat, the general relations of the parts are clearly shown. Figure 373 is sketched from a longitudinal section of the cochlea of a guinea-pig, and shows the appearance presented by a section through one of the turns of the bony cochlear canal and its contents as seen under higher magnification. We may now proceed with a fuller consideration of the structures mentioned.

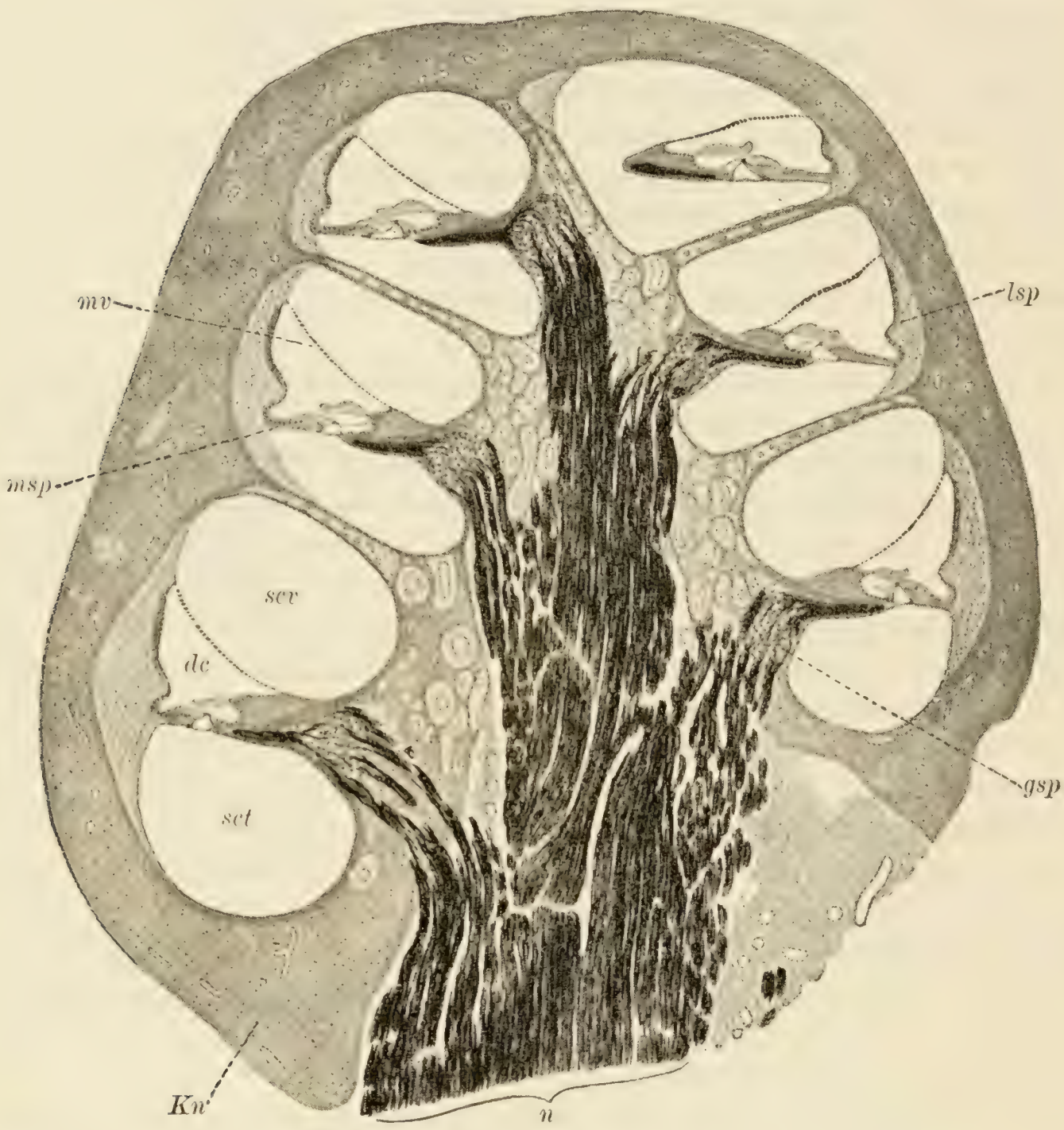

Fig. 372.—Longitudinal section of the cochlea of a cat ; × 25. This figure gives a general view of the cochlea. The cochlear duct is met with six times in the section : *dc*, cochlear duct ; *gsp*, spiral ganglion ; *Kn*, osseous cochlear wall ; *lsp*, ligamentum spirale ; *msp*, membrana spiralis; *mv*, membrana vestibularis or Reissner's membrane ; *n*, nervus cochlearis ; *sct*, scala tympani; *scv*, scala vestibuli (Sobotta, "Atlas and Epitome of Histology").

The **lamina spiralis ossea** consists of two bony plates which inclose between them the ramifications of the cochlear nerve. The vestibular surface of the osseous lamina spiralis is covered by periosteum, which is continuous with a peculiar tissue, known as *limbus spiralis*. The latter begins at the point of attachment of Reissner's

membrane, extends peripherally (externally), and ends in two sharp ridges, of which the shorter, the *labium vestibulare*, projects into the inner space of the cochlear duct and continues into the tectorial membrane; while the other and longer, the *labium tympanicum*, becomes attached to the wall of the scala tympani and continues into the basilar membrane. Between the two ridges is a sulcus, the *sulcus spiralis internus*. (Fig. 373.) The limbus spiralis

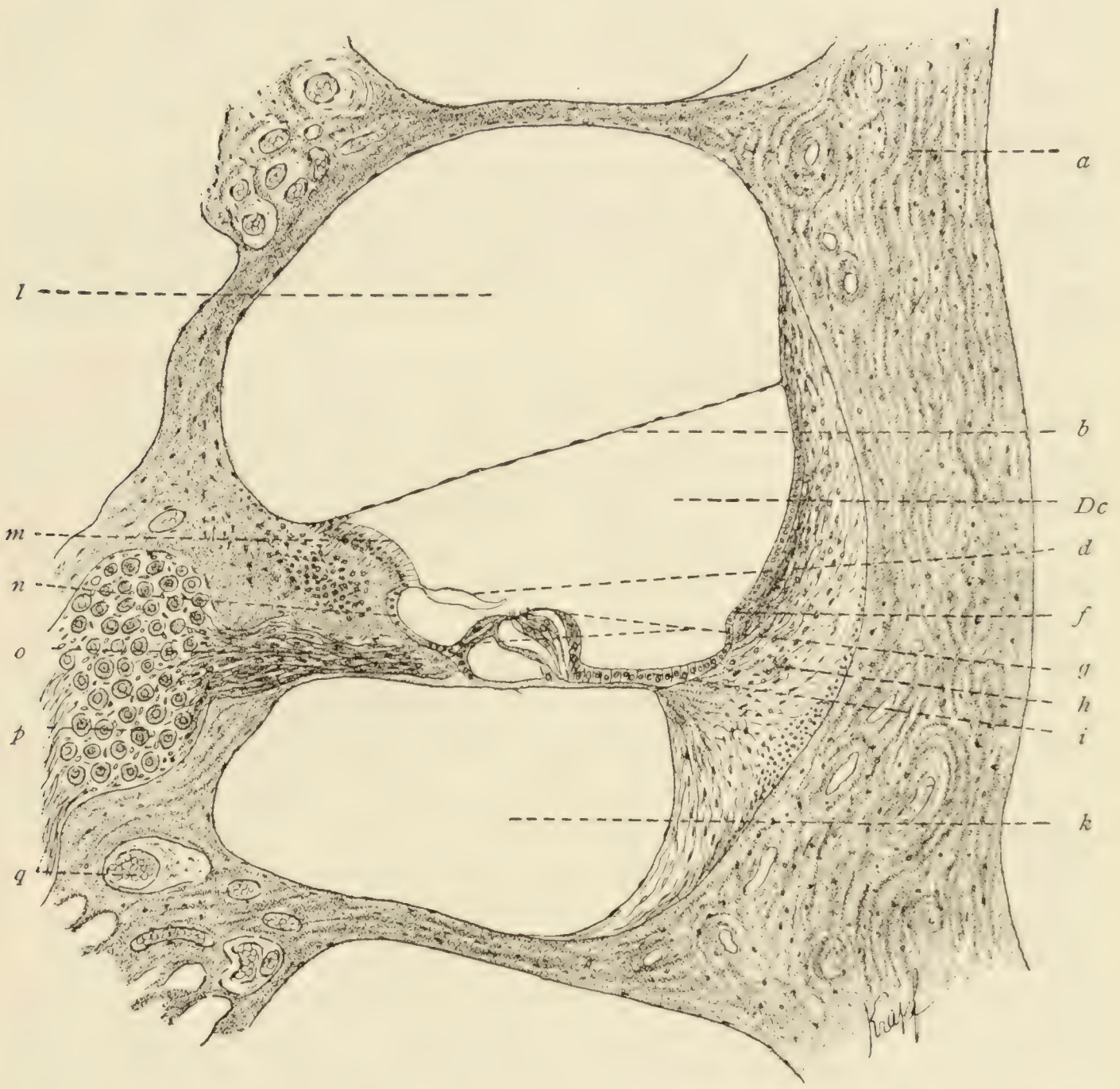

Fig. 373.—Section through one of the turns of the osseous and membranous cochlear ducts of the cochlea of a guinea-pig; × 90: *l*, Scala vestibuli; *m*, labium vestibulare of the limbus; *n*, sulcus spiralis internus; *o*, nerve-fibers lying in the lamina spiralis; *p*, ganglion cells; *q*, blood-vessels; *a*, bone; *b*, Reissner's membrane; *Dc*, ductus cochlearis; *d*, Corti's membrane; *f*, prominentia spiralis; *g*, organ of Corti; *h*, ligamentum spirale; *i*, crista basilaris; *k*, scala tympani.

is a connective-tissue formation in the region of the cochlear duct connected with the periosteum of the osseous spiral lamina and extending from the point of attachment of Reissner's membrane to the labium tympanicum. The tissue of the limbus spiralis is dense and richly cellular, and simulates in its structure the substantia propria of the cornea. A casual view would seem to disclose

a high columnar epithelium, but upon closer observation, it is seen that the cellular elements are interspersed with fibers which extend to the surface. Some investigators regard this tissue as fibrocartilage; others, again, as a tissue *sui generis*, consisting of epithelial cells mingled with connective-tissue fibers. If the labium vestibulare of the limbus spiralis be examined from the vestibular surface, a number of irregular tubercles are seen at its inner portion (near Reissner's membrane), while at its outer portion long, radially disposed ridges may be observed, the so-called *auditory teeth* of Huschke. The connective-tissue wall of the sulcus spiralis internus consists of a nonnucleated fibrillar tissue which is continued into the labium tympanicum. The latter is perforated by nerves, thus giving rise at this point to the *foramina nervosa.*

Between the point of attachment of Reissner's membrane and the labium vestibulare, the superficial epithelium of the limbus spiralis is flat, and lines the auditory teeth and the depressions between them in a continuous layer. The epithelium of the sulcus spiralis internus is somewhat higher.

The **ligamentum spirale** forms the thickened periosteum of the outer wall of the osseous cochlear canal. It presents two inwardly projecting ridges, the *crista basilaris*, to which the membranous lamina spiralis is attached, and the *prominentia spiralis*, which contains one or several blood-vessels; between the two ridges lies the sulcus spiralis externus. The portion of the ligamentum spirale forming the periosteum of the bony cochlear canal consists of a fibrous tissue containing many nuclei, but changes internally into a looser connective tissue. The connective tissue lying external to the outer wall of the cochlear duct is very dense and rich in cellular elements and blood-vessels, but in the crista basilaris it changes to a hyaline, noncellular tissue, continuous with the lamina basilaris. That portion of the spiral ligament lying between the prominentia spiralis and the attachment of Reissner's membrane is known as the *stria vascularis.* The epithelium covering this area (a portion of the epithelium lining the cochlear duct) consists of columnar, darkly granulated cells, which now and then are arranged so as to present the appearance of a stratified epithelium, but which is more correctly interpreted as an epithelium of the pseudostratified variety. This epithelium shows no distinct demarcation from the underlying connective tissue. Beneath this epithelium there is found a rich capillary network, certain loops of which extend into the epithelium (Retzius). It is thought that the stria vascularis is concerned in the formation of the endolymph of the cochlear duct.

The membranous lamina spiralis, or the **basilar membrane,** extends from the tympanic lip of the osseous spiral lamina to the crista basilaris of the ligamentum spirale.

As already stated, the tissue composing the labium tympanicum of the limbus extends into the basilar membrane. In this

membrane the surface toward the cochlear duct is known as the cochlear surface, that toward the scala tympani as the tympanic surface. Two layers are differentiated in the basilar membrane, the *lamina basilaris propria* and the *tympanic investing layer*. The lamina propria consists, in turn, of (1) radially arranged basilar fibers, or acoustic strings ; (2) two thin strata of a homogeneous substance, one above and the other below the layer of basilar fibers, the upper of which is the thicker and nucleated ; and (3) a fine cuticula, of epithelial origin, lying on the cochlear side. The *tympanic investing layer* is highly developed in youth, but later becomes thinner, and may then be differentiated into a connective-tissue layer, regarded as a periosteal continuation of the tympanic portion of the osseous lamina spiralis, and an endothelial cell layer belonging to the lining of the perilymphatic space or the scala tympani. In the vicinity of the labium tympanicum is a blood-vessel situated within the tympanic investing layer of the basilar membrane—the *vas spirale*.

Reissner's membrane consists of an exceedingly thin connective-tissue lamella, lined on the side of the cochlear duct by a layer of flattened epithelial cells and on the vestibular side by a layer of endothelial cells. The epithelium lining the cochlear duct is occasionally raised into small villus-like projections.

The Organ of Corti.—In the region of the labium tympanicum of the limbus spiralis and in the greater portion of the adjoining basilar membrane, the epithelium of the cochlear duct is peculiarly modified, forming here a neuro-epithelium, which receives the terminal ramifications of the cochlear nerve and is known as the **spiral organ of Corti.**

Passing from the labium tympanicum to the ligamentum spirale, the following three regions may be recognized in the organ of Corti : An inner region, composed of the inner sustentacular cells and the inner auditory cells ; a middle region, consisting of the arches of Corti ; and an outer region, in which are found the outer auditory cells and the outer sustentacular cells or Deiters's cells. Two cuticular membranes are in close relationship to the organ of Corti : namely, the *lamina reticularis* and the *membrana tectoria*, or membrane of Corti.

In figure 374, a sketch of the organ of Corti and adjacent structures, it may be observed that the epithelium lining the sulcus spiralis internus (at the right of the figure) is of the pavement variety, and that the epithelium becomes gradually thicker until the organ of Corti is reached, where it becomes suddenly elevated in the form of a wall. In this, two varieties of cells are distinguished —sustentacular cells and inner auditory cells. The sustentacular cells, which follow the flattened cells, become gradually higher from within outward and occupy three or four rows. Next come the inner auditory cells, cylindric elements, somewhat rounded and

thickened at their nucleated basilar ends. The latter do not extend to the basilar membrane but end at about the level of the center of the inner pillars. At the free end of each cell is an elliptic cuticular zone, somewhat broader than the end-surface of the corresponding cell. In man about twenty rigid filaments, known as **auditory hairs,** are found resting on each elliptic cuticular zone. These are either arranged in a straight row or they describe a slight curve.

The middle division of the organ of Corti, the **arches of Corti,** consists of long slender structures, known as **pillar cells,** or, briefly, pillars, resting firmly upon the basilar membrane and forming an arch at the vestibular side of the latter. They surround, by the

Fig. 374.—Organ of Corti: At *x* the tectorial membrane is raised; *c*, outer sustentacular cells; *d*, outer auditory cells; *f*, outer pillar cells; *g*, tectorial membrane; *h*, inner sustentacular cells; *i*, *p*, epithelium of the sulcus spiralis internus; *k*, labium vestibulare; *e*, tympanic investing layer; *m*, outer auditory cells; *n*, *n*, nerve-fibers which extend through the tunnel of Corti; *o*, inner pillar cell; *q*, nerve-fibers; *b*, *b*, basilar membrane; *a*, epithelium of the sulcus spiralis externus; *r*, cells of Hensen; *s*, inner auditory cell; *l*, ligamentum spirale (after Retzius).

union of their free ends, a space which, as seen in figure 374, appears triangular in section. This is the tunnel of Corti.

According to their position, we distinguish *inner* and *outer pillars*, the inner being more numerous than the outer. Including the entire extent of the lamina spiralis membranacea, we find that there are about 6000 of the inner and 4500 of the outer pillar cells.

Each pillar cell originates from an epithelial cell, and is found to be composed of a protoplasmic portion containing the nucleus, which may be regarded as a remnant of the primitive cell, and of a cuticular formation derived from the primitive cell, forming the elongated body of the pillar cell—the pillar. The free adjoining ends are called the *heads of the pillars.* The head of the inner pillar is provided with a flattened process, the head-plate, which extends outward and forms an obtuse angle with the axis of the pillar. Under this plate, and at the outer side of the head of the

inner pillar, is a depression into which fits the head of the outer pillar. The latter also extends outward in the shape of a *phalangeal plate*, with a thinner process, the *phalangeal process*, at its end. The phalangeal plate and process lie under the head-plate of the inner pillar, the process extending a little beyond this, forming an acute angle with the head of the outer pillar. At the inner side of the head of the outer pillar is a convex articular surface, with which, as a rule, two, and occasionally even three, articular surfaces of the inner pillars come in contact. The outer and inner pillars appear to possess an indistinct longitudinal striation, and their basilar plates are continuous with the extremely fine cuticula covering the basilar membrane. The inner margins of the basilar plates belonging to the inner pillars border on the foramina nervosa ; while the outer margins of the basilar plates belonging to the outer pillars come in contact with the basal end of the innermost row of the cells of Deiters in the outer region of Corti's organ. The protoplasmic portions of the pillar cells, constituting what are known as basal cells, lie against the basilar plates of the corresponding pillars,—*i. e.*, on the basilar membrane,—and partly cover the bodies of the pillars, especially the surfaces toward the tunnel.

In order to comprehend the relative position of the inner auditory cells to the inner pillars, it may be stated that one auditory cell rests upon every two inner pillars.

The outer region of Corti's organ is joined directly to the outer pillar cells, and consists of four rows of auditory cells alternating with an equal number of sustentacular cells or **Deiters's cells.** Following these structures and in contact with them are the outermost sustentacular cells, known as **Hensen's cells.**

The **outer auditory cells** have a structure similar to that of the inner auditory cells, but possess a more slender body. They do not extend as far as the basilar membrane, but end at a distance from the latter equal to about double their own length. The cuticular zone of each outer auditory cell likewise assumes the form of an ellipse, with its long axis pointing radially. The surface of this zone also is provided with about twenty stiff auditory hairs, arranged in the form of a decidedly convex arch, the convexity of which points outward. At a short distance from the cuticular zone of each outer auditory cell is a peculiar round body, found only in these cells, the significance of which is unknown.

Deiters's cells rest on the basilar membrane, and in shape resemble a flask with a narrow neck, known as the *phalangeal process*, the latter lying between the auditory cells. The nuclei of Deiters's cells lie in the upper parts of the thickened basal portions of these cells.

With each Deiters's cell there is associated a cuticular structure, which extends along the surface of each cell in the form of a thin

fiber, the *sustentacular fiber*, and which is found partly within and partly without the cell. The sustentacular fiber begins near the center of the thicker basal portion of the cell-body and extends first into the cell itself, then passes to the surface, and, entering the phalangeal process, passes to the top of the cell and expands as a plate, to which the name *phalangeal plate* has been given. The latter is broader than the phalangeal process, and since, as we shall see, the phalangeal plates are joined to one another, as well as to the elliptically shaped cuticular zones of the outer auditory cells, there remains a space between the cells of Deiters and the auditory cells, as also between the outer pillars and the innermost of the outer auditory cells, known as *Nuel's space*. To the basal regions of the inner row of the cells of Deiters is joined the basal plate of the outer pillars of the arches of Corti.

Next to the outer row of Deiters's cells are the **cells of Hensen,** arranged in about eight radially disposed rows. They form an eminence which is high internally, but gradually decreases in height externally. The somewhat narrowed bases of Hensen's cells probably extend, without exception, to the basilar membrane. The free surfaces of these cells are likewise covered by a thin cuticular membrane. In man the cells of Hensen usually contain yellow pigment; in the guinea-pig, as a rule, fat; and in the rabbit, generally rudiments of sustentacular fibers. Externally the cells of Hensen gradually change into elements of a more cuboid type—the **cells of Claudius,** of which there are about ten rows, radially disposed. The surfaces of the latter also possess a cuticular margin; the nucleus is at the center of each cell and pigment is also present. Darker elements with more basally situated nuclei sometimes occur between these cells, giving rise to the appearance of a double-layered epithelium (Böttcher's cells).

Thus far we have considered in detail the cells comprising the organ of Corti, and described their relative positions and sequence from within outward. In order to give a clearer understanding of the mutual relations of these cells, from within outward and in the direction of the spiral turning of the cochlea, we shall now consider the appearance presented in a surface view of the organ of Corti.

From within outward a surface view of the organ of Corti presents the following characteristics: The somewhat broadened hexagonal outlines of the inner sustentacular cells adjoin the epithelial elements of the sulcus spiralis internus and terminate externally in a spiral undulating line (if seen for only a short distance, this line appears straight). On this line border the contours of the cuticular zones belonging to the inner auditory cells. The outer margins of the cuticular zones come in contact with the head-plates of the inner pillars, the cuticular zone of one inner auditory cell coming in contact with at least two head-plates. The externally directed processes of the head-plates belonging to the inner pillars come in contact with one another and end in a spiral line which for a short

distance is apparently straight. The head-plates of the inner pillars cover the head-plates of the outer pillars (which also come in contact with each other), also their phalangeal plates, but not their phalangeal processes, which thus project beyond the line formed by the outer borders of the head-plates of the inner pillars. It should be mentioned that about three head-plates belonging to the inner pillar cells are in apposition to every two head-plates and their phalangeal processes of the outer pillar cells. The succeeding four rows, from within outward, are made up of alternately placed cuticular zones of the outer hair cells and the phalangeal plates of the Deiters's cells, alternating like the squares of a chess-board. This regular arrangement is lost in the outer row of Deiters's cells. The cells of Hensen adjoin this row, and when viewed from the surface, present the appearance of irregular polygons.

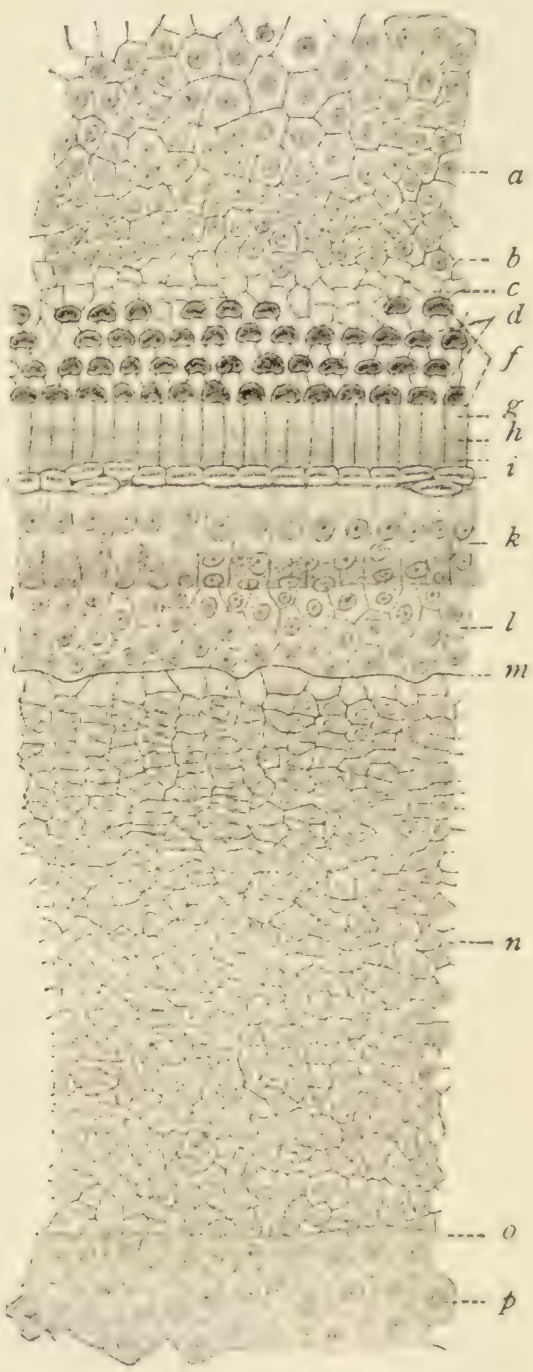

Fig. 375.—Surface of the organ of Corti, with the surrounding structures, from the basal turn of the cochlea of a new-born child; the original drawing reduced one-half (after Retzius, 84): *a*, Epithelium of the sulcus spiralis externus; *b*, Hensen's cells; *c*, terminal frame; *d*, phalanges; *f*, outer auditory cells; *g*, flattened processes of the outer pillar cells; *h*, flattened processes of the inner pillar cells; *i*, inner auditory cells; *k*, inner sustentacular cells; *l*, epithelium of the sulcus spiralis internus; *m*, margin of the labium vestibulare; *n*, epithelium of the limbus laminæ spiralis; *o*, line of attachment of the membrana Reissneri; *p*, epithelium of the membrana Reissneri, the latter inverted.

This arrangement is, however, seldom found to be as typical as that just described; although the relations of the cells to one another always correspond in general to the foregoing scheme.

In the cupolar and vestibular sacs the neuro-epithelium changes into an epithelium of an indifferent type.

The **lamina reticularis** is formed by the cementing together of the phalangeal processes of the outer pillars and the phalangeal plates of Deiters's cells, and is continued externally by a cuticular membrane which covers the cells of Hensen and, as a much thinner cuticular membrane, extends over the cells of Claudius. In this membrane there are found three or four rows of small apertures, into which the outer hair cells project.

The **membrana tectoria Cortii** is attached to the limbus spiralis, but becomes free at the margin of the labium vestibulare and thickens considerably, again becoming thinner toward its free end.

Hence an inner attached and an outer free zone may be differentiated. This membrane has no nuclei, and shows a fine radial striation. Its free portion bridges over the sulcus spiralis internus and rests upon the organ of Corti. Its outer margin extends as far as the cells of Hensen. The development of this membrane is not thoroughly understood, although it very probably represents a displaced cuticular formation belonging to the cells of the limbus spiralis. This acceptation has recently been confirmed (Exner).

The **auditory nerve** gives off, soon after entering the internal auditory meatus, vestibular branches to the maculæ in the utriculus and sacculus and to the cristæ in the semicircular canals, and a cochlear branch, which passes up through the modiolus in anastomosing bony canals. From this centrally placed column of nerve-fibers, a continuous sheet of nerve-fibers, arranged in the form of anastomosing bundles, passes radially into the osseous spiral lamina and thence to the organ of Corti. Near the base of the osseous spiral lamina, along the entire length of this sheet of nerve-fibers, there is situated in a special bony canal a ganglion, known as the *spiral ganglion* of the cochlea. The ganglion cells of this ganglion are bipolar, one of the processes of each cell, the dendrite, extending outward through the osseous spiral lamina to the organ of Corti, the other process, the neuraxis, passing through the bony canal in the modiolus, through the internal auditory meatus, and thence to the medulla. The dendritic processes of the nerve-cells of the spiral ganglion form bundles of medullated nerve-fibers, which pass outward within the osseous spiral lamina, forming, in the outer portion of the latter, a closely meshed plexus, from which small bundles of nerve-fibers proceed through the foramina nervosa of the labium tympanicum to the organ of Corti; immediately before passing through these foramina, the medullated nerve-fibers lose their medullary sheaths and neurilemma.

These nonmedullated fibers, with or without further dividing, are then arranged in small bundles, which, for a certain distance, have a spiral course: that is to say, parallel to the tunnel of Corti. One such spiral bundle is situated on the inner side of the inner pillars, under the inner row of hair cells; another, on the outer side of the inner pillars, in the tunnel of Corti. Other fibers pass through the tunnel of Corti, so-called *tunnel-fibers*, to reach the outer side of the arches of Corti, where they are arranged in three or four spiral bundles, at the outer side of the outer pillars and between the rows of the cells of Deiters. From the nerve-fibers of these spirally arranged bundles, terminal branches are given off, which terminate, after further division, *on* the inner and outer hair cells (Retzius, Geberg).

Regarding the blood-vessels of the membranous labyrinth, it should be mentioned that the *internal auditory artery* is a branch of the basilar artery, and divides into the *rami vestibulares* and *rami cochleares*. The branches of the former accompany those of the auditory nerve as far as the utriculus and sacculus. At the maculæ

and cristæ the capillary networks are numerous and finely meshed, but in the remaining portions of the utriculus, sacculus, and semicircular canals, they form coarser networks. The cochlear branch accompanies the divisions of the auditory nerve as far as the first spiral turn of the cochlea ; the arteries supplying the remaining turns enter the axis of the modiolus, where they divide into numerous branches. The latter are coiled in a peculiar manner, forming the so-called *glomeruli arteriosi cochleæ*. From these, branches are given off which penetrate the vestibular wall of the lamina spiralis ossea, where they supply the limbus spiralis and the small quantity of connective tissue in the membrana vestibularis. Other branches surround the scala vestibuli, supply the walls of the latter, and then continue to the ligamentum spirale, the stria vascularis, and the lamina basilaris.

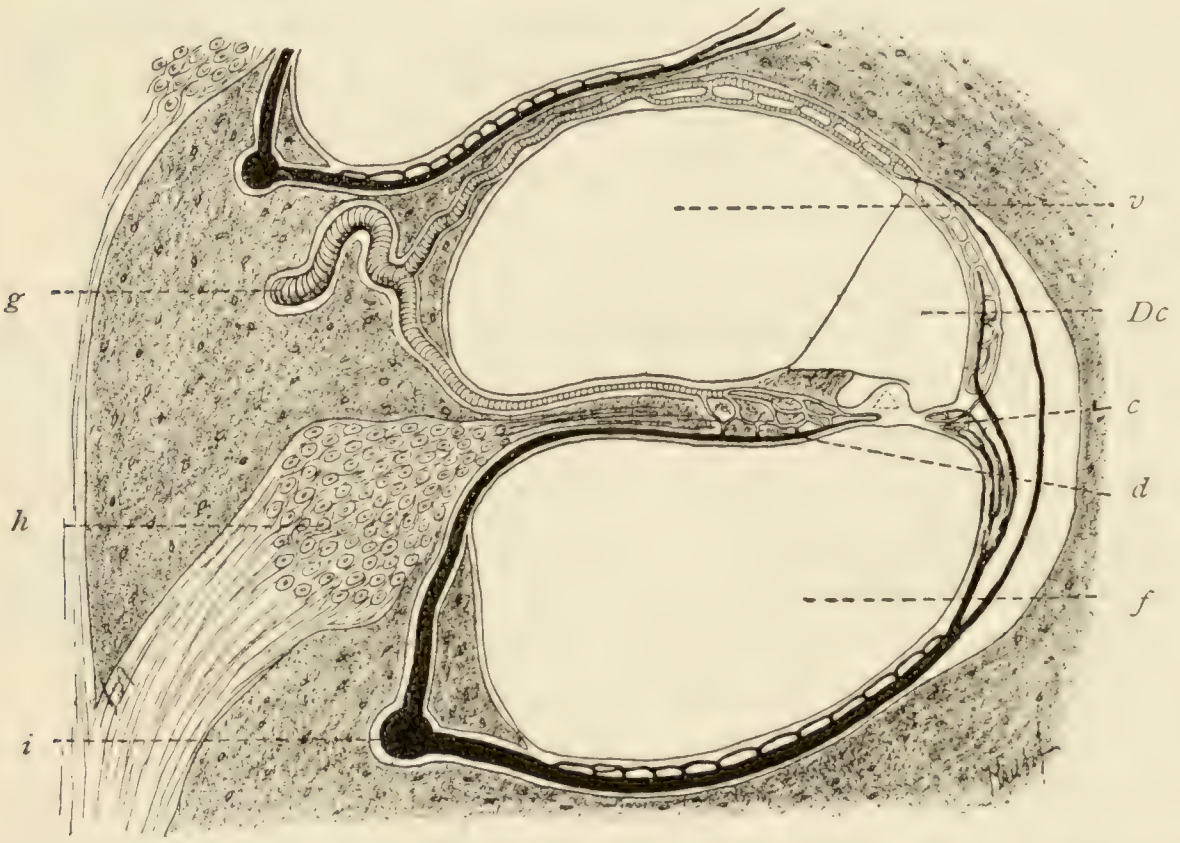

Fig. 376.—Scheme of distribution of blood-vessels in labyrinth (after Eichler): *g*, Artery ; *h*, spiral ganglion ; *i*, vein ; *v*, scala vestibuli ; *Dc*, ductus cochlearis ; *c*, capillaries in the ligamentum spirale ; *d*, capillaries in the limbus spiralis ; *f*, scala tympani.

The venous trunks lie close to the arteries and receive their blood from the veins which lie at the tympanal surface of the lamina spiralis and from those which encircle the outer wall of the scala tympani. The former, in turn, receive their blood from the capillaries of the limbus spiralis ; the latter, principally from the region of the ligamentum spirale and the basilar membrane.

From this description it is seen that the arterial channels are connected with the scala vestibuli, the venous with the scala tympani, and that the inner blood stream circulating through the lamina spiralis and limbus spiralis is separated from the blood current of the two scalæ, the ligamentum spirale, and the crista basilaris (Eichler).

The entire membranous labyrinth is filled with *endolymph*. The ductus endolymphaticus is, as will be remembered, a canal ending

under the dura in a *saccus endolymphaticus*. In connection with the latter are epithelial tubules bordering upon lymph-channels, with which they probably communicate by means of interepithelial (intercellular) spaces (Rüdinger, 88). The efferent channels for the *perilymph* of the vestibule extend along the nerve sheaths of those nerves supplying the maculæ and cristæ; these passageways finally communicate with the subdural or subarachnoid spaces. The *perilymph* of the cochlea is carried off by the adventitious tissue of the vena aqueductus cochleæ, the lymph-vessels of which empty into certain subperiosteal lymph-channels near the inner margin of the jugular fossa.

4. ON THE DEVELOPMENT OF THE LABYRINTH.

In man the epithelium lining the membranous labyrinth originates from the ectoderm as a single-layered epithelial vesicle, the auditory vesicle or the otocyst, during the fourth week of embryonic life. After being constricted off from the ectoderm, this vesicle lies in the vicinity of the epencephalon and is surrounded by mesenchyme. The auditory vesicle then develops a dorsomesial evagination, which gradually grows larger and finally becomes the *ductus endolymphaticus*. An evagination also occurs in the ventral wall of the vesicle, the *recessus cochleæ*. At the same time the mesial wall is pushed inward, thus incompletely dividing the vesicle into two smaller sacs—the dorsal *utriculus* and the ventral *sacculus*. From the utricular portion there arises a horizontal evagination, flat and quite broad—the first trace of the lateral or horizontal semicircular canal; soon after, another evagination, vertical and still broader than the first, is seen—the anlage of the other two canals. The outer portion of these pouches gradually expands, while in the middle, the two layers of each evagination come in contact with each other and coalesce, finally becoming absorbed. In the vertical evagination two such areas of adherence are found, thus forming a superior and a posterior canal, both having a common crus at one end.

The recessus cochleæ grows both in a longitudinal and in a spiral direction, forming the cochlear duct.

In the immediate vicinity of the membranous labyrinth, the mesenchyme is differentiated into a connective-tissue wall for the former. The successive layers of mesenchyme, except in those areas where the membranous labyrinth later becomes adherent to the osseous, are transformed into a mucous connective tissue. The latter is surrounded by a more compact tissue, from which are derived, first, cartilage; then bone and periosteum, and thus, finally, the osseous labyrinth. By a peculiar process of regressive metamorphosis most of the mucous connective tissue later disappears. In the adult it is replaced by the perilymphatic spaces of the labyrinth.

TECHNIC.

In the treatment of the external and middle ear the usual methods are employed. For the study of the epithelium in conjunction with the adjacent bone the tissue is fixed and then decalcified, or subjected to those fixing methods which accomplish both processes at the same time. The latter method, however, can be applied only to very small objects.

The manipulation of the membranous labyrinth, especially that of the adult, is a very difficult technical problem. Its isolation from the petrous portion of the temporal bone without injury can be accomplished only in well-advanced fetuses and in children, and even here a thorough knowledge of the situation of the parts in the petrous portion of the temporal bone is essential. Smaller animals, especially rodents, afford better specimens. In the latter, the semicircular canals and cochlea give rise to more or less distinct projections into the tympanic cavity. If the latter be opened, the situation of the parts may be ascertained from without. In the rabbit and guinea-pig, the entire cochlea projects into the tympanic cavity, and may be easily removed in toto with a strong knife, and, as the bony cochlea in these animals has very thin walls, it offers very little resistance to the decalcifying fluid (use, for instance, 3% nitric acid).

According to Ranvier's method (89), the cochlea is opened with a scalpel in a 2% solution of osmic acid in normal salt solution. After twelve hours the cochlea is placed for decalcification in 2% chromic acid, which is frequently changed. In guinea-pigs, for instance, decalcification is accomplished in a week.

According to the method of Retzius (84), the opened cochlea is treated for half an hour with a 0.5% aqueous solution of osmic acid, and then for the same length of time with a 0.5% aqueous solution of gold chlorid. The organ of Corti is then dissected out and examined as a whole, or cut after carefully removing the bone.

The labyrinth of the human adult is usually prepared as follows: The apex of the petrous portion of the temporal bone is removed and the upper semicircular canal, together with the cochlea, opened in Müller's fluid; in this solution the pyramid is left for three weeks; during the first week the fluid is changed daily, and every two days during the following weeks. The specimen is then washed for twenty-four hours in running water, placed in 80% alcohol for two weeks, and finally in 96% alcohol for two days. The preparation is now ready for decalcification. This is done with 5% nitric acid, which is to be changed daily (ten days to two weeks). Then follows washing for two days in running water, carrying over into 80% alcohol for twenty-four hours, then into 96% alcohol for from six to eight days, and, finally, infiltration and imbedding in celloidin (A. Scheibe).

The following method may also be employed with good results: The isolated pyramid with opened semicircular canal and cochlea is treated with Müller's fluid for two days at room-temperature, and then for three weeks in a thermostat at 23° C. During the latter period, the fluid should be changed. The specimen is then washed for forty-eight hours in running water, treated for fourteen days with 80% alcohol, then for eight days with 96% alcohol, decalcified, and further treated as in the preceding method.

Up to the present time it has been customary to cut sections in celloidin; but the combined celloidin-paraffin method may also be employed with good results, and even the paraffin method, if great care be exercised in imbedding the tissue.

The nerve-fibers and nerve-endings of the cochlea may be stained with the chrome-silver method. For this purpose it is recommended to employ embryos or young fetuses.

X. THE ORGAN OF SMELL.

The nasal cavity consists of the vestibule, the respiratory region with the accessory cavities, and the olfactory region.

The **vestibule** is lined by stratified squamous epithelium. In the region of the anterior nares are hairs, the sebaceous glands of which are markedly developed, while at the level of the cartilage mucous glands are also present. The stratified squamous epithelium ceases at the anterior end of the inner turbinate bone and at the inferior nasal duct.

The **respiratory region** possesses a simple pseudostratified, ciliated epithelium having two strata of nuclei and provided with goblet cells; the direction of the ciliate movement is toward the posterior nares. Numerous leucocytes are usually found in the epithelium and in the underlying mucosa. Branched alveolar glands, having mucous and serous alveoli, are here present. Within the mucosa are highly developed vascular plexuses, more especially of a venous character. The *accessory cavities* are likewise lined by ciliated epithelium, the ciliate movement being directed externally.

The **olfactory region** is principally confined to the superior turbinate bone and to the nasal septum lying opposite, although in the immediate vicinity of the olfactory region a few small islands of the same epithelial type are found, either entirely isolated or connected with the principal region by narrow bridges. In a fresh condition the olfactory region may be differentiated from the surrounding tissue by its color, which is distinctly yellow in man. Its pigment is contained within the sustentacular cells described on the next page.

The epithelium of the olfactory region is of the columnar pseudostratified type, with several strata of nuclei, and consequently closely simulates a stratified columnar epithelium. Here we distinguish olfactory cells and sustentacular cells.

The **olfactory cells** occupy a peculiar position among the cells of special sense in that they represent true ganglion cells (Schultze, Golgi, Ehrlich, Ramón y Cajal). Within the epithelial layer they appear as spindle-shaped cells, with a spheric nucleus provided with a large nucleolus lying in the thickest portion of each cell. The nuclei of the different cells lie at varying levels in the middle stratum

of the epithelial layer. Toward the nasal cavity, the cells terminate in blunt cones, upon each of which are several stiff hairs, the *olfactory hairs.* The basilar ends form true centripetal nerve-processes, neuraxes, which end in the peculiar telodendria constituting the glomeruli of the olfactory bulb. (See p. 422.)

The nuclei of the sustentacular cells are more oval and are situated at nearly the same level. These cells present the appearances of long columnar cells, which toward the basement membrane terminate in one or several processes. Between the basilar ends of these cells we find a layer of elements the broad nucleated bodies of which rest on the basement membrane, while their upper extremities terminate in short superficial processes.

The mucosa contains a large number of leucocytes as well as

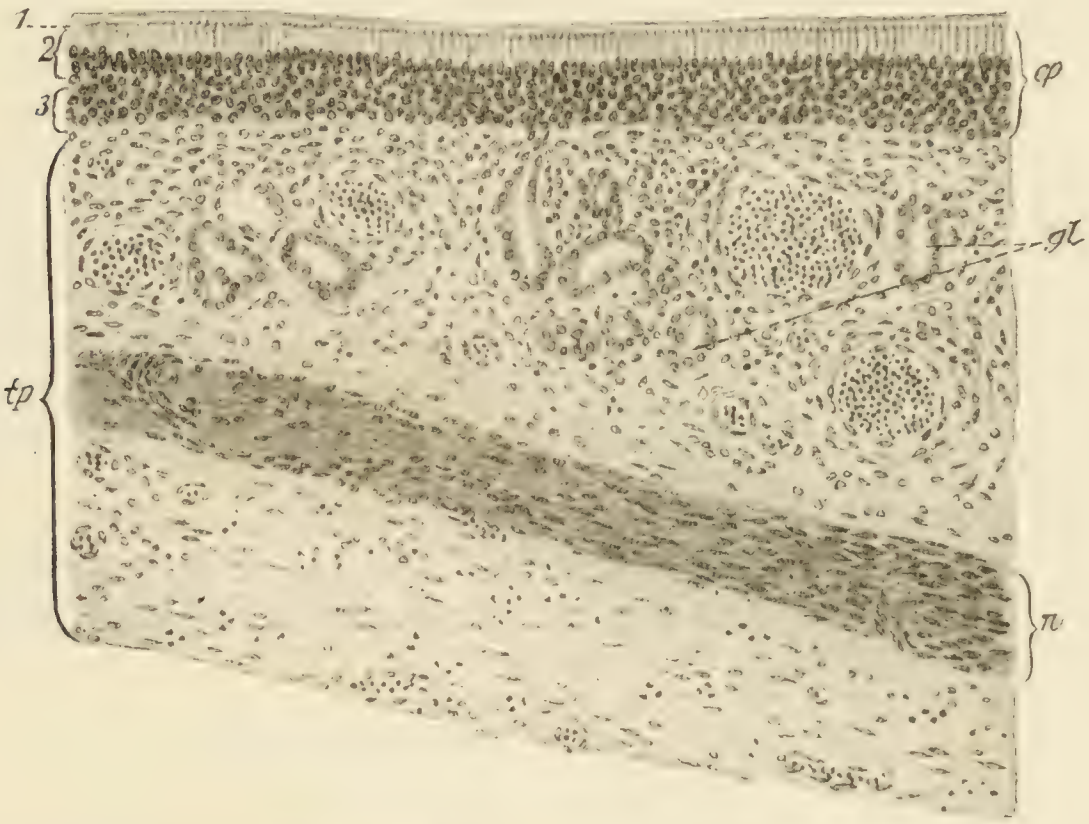

Fig. 377.—Portion of transverse section of the olfactory region of man; × 150: *1*, zone of olfactory hairs; *ep*, epithelium; *2*, zone of oval nuclei; *3*, zone of round nuclei; *gl*, olfactory or Bowman's glands; *n*, branch of olfactory nerve; *tp*, mucosa or tunica propria with blood-vessels (Sobotta, "Atlas and Epitome of Histology").

numerous branched tubular glands, the so-called olfactory glands or the *glands of Bowman.* In man these are albuminous (serous) glands, and their cells sometimes contain pigment.

Jacobson's organ consists of blindly ending tubes, situated at the lower portion and at the outer side of the nasal septum. It is lined by an olfactory mucous membrane and receives a branch of the nasal nerve. This organ is rudimentary in man.

The capillaries spread out immediately beneath the basement membrane of the epithelium. In the submucous connective tissue, we find a relatively well developed vascular plexus, rich in venous vessels; this plexus is especially marked at the posterior portion of the inferior turbinate bone, forming here a tissue which resembles erectile tissue.

A dense network of lymphatics ramifies throughout the mucous membrane, carrying the lymph to the pharynx and palate. These lymph-vessels may be injected through the subarachnoid space (Key and Retzius).

The nerves (trigeminal) are widely distributed in the epithelium, ramifying through both the respiratory and olfactory regions. After repeated divisions these nerves lose their medullary sheaths, and end in telodendria which are usually provided with terminal nodules, although some are found which end in mere filaments.

TECHNIC.

The nasal mucous membrane is fixed *in situ* with osmic acid or one of its mixtures, after which small pieces are removed. It should be mentioned that the nonmedullated fibers of the olfactory nerve assume a brownish color under this treatment, while the fibers of Remak do not (Ranvier, 89).

In order to isolate the epithelial elements, pieces of the mucous membrane are treated with the ⅓ alcohol of Ranvier. But since the prolongations of the olfactory cells (neuraxes) shrivel and curl in this fluid, Ranvier recommends that, after the epithelial cells have been macerated in ⅓ alcohol for one or two hours, they be treated with 1% osmic acid for a quarter of an hour. If shreds be now placed in water and teased, the cells, together with their prolongations, may be isolated without the curling of the latter.

The chrome-silver method applied to the nasal mucous membrane of young animals and fetuses has been the means of establishing the important fact that the olfactory cells of the olfactory region are in reality peripherally situated ganglion cells.

INDEX.

Abbe's apparatus, 19
Absorption of fat by intestine, 288
  method of studying, 306
Accessory disc of Engelman, 139
  lacrimal glands, 470
  thread of spermatosome, 361
Acervulus, 423
Acetic acid, effect on connective tissue, 128
  on red blood-corpuscles, 188
  sublimate solution as fixing fluid, 25
Achromatic portion of nucleus, 63
  spindle, 68
Acidophile granules, technic for, 227
Adenoid connective tissue, 196
Adipose tissue, 107
  stain for, 130
Agminated lymph-nodules, 197
Air-cells, 314
Air-spaces, ultimate, 313
Akrosome, 377
Alcohol as fixing solution, 23
  as macerating solution, 22
Alcoholic borax-carmin solution as stain, 41
  in bulk, 46
Alkalies, effect on red blood-corpuscles, 189
Altmann's method of demonstrating granules in cells, 77
  of mounting, 78
  process, 55
Alum-carmin as stain, 42
  in bulk, 46
Alveolar ducts, 314, 315
  glands, 91
    compound branched, 91
    simple, 91
      branched, 91
  periosteum, 242
Alveoli, 88
  lung, 314
  of mammary gland, epithelium of, 401
Amacrine cells, 464
Amitosis, 64, 70
Amitotic cell-division, 70
Amphiaster, 68
Amphipyrenin, 63
Amphophile granules, technic for, 228
Ampullæ of Thoma, 204
Anaphases, 65, 69
Anastomoses, 222
Anilin stains, 44
Animals, injection of, 54
Anisotropic transverse disc, 138
Annulospiral nerve-ending, 178
Annulus fibrosus, 477
  atrioventricularis, 214
Anterior epithelium of crystalline lens 468
  ground bundle, 411
  hyaloid artery, 468
  lymph-channels of eye, 469
  superior vertical canal, 480
Anterolateral columns, ascending, 411
  descending, 411
Antrum of ovary, 347
Anus, 281
Apáthy's method for demonstration of fibrillar elements of nervous system, 442
Apochromatic lens, 19
Aponeuroses, 105
Aqueous borax carmin solutions as stain, 41
  humor, 446
Arachnoid, 437
Arches of Corti, 490
Arcuate fibers of cornea, 450
Area cribrosa, 332
  vasculosa, 186
Areas of Langerhans, 301
Arrectores pilorum, 393
Arteriæ arciformes, 332
  capsulares glomeruliferæ, 334
Arterial circle of Zinn, 465
  retia mirabilia, 333
Arteries, 216
  coronary, 214
  hyaloid, anterior, 468
    posterior, 468
  interlobular, of kidney, 332
  medium-sized, 218
  of choroid, 455
  of retina, 466
  precapillary, 218
Arteriolæ rectæ spuriæ, 333
    veræ, 334
Artery, auditory, internal, 494
  central, of retina, 465
  hepatic, 293
  nasal, inferior, of retina, 466
    superior, of retina, 466
  papillary, inferior, of retina, 466
    superior, of retina, 466
  renal, 332

Artery, temporal, inferior, of retina, 466
superior, of retina, 466
Ascending anterolateral columns, 411
Association fibers of cerebral cortex, 420
Astrocytes, 435
Atresia of ovarian follicles, 353
Atria, 314
Attraction-sphere, 62
Auditory artery, internal, 494
cells, outer, 491
hairs, 490
nerve, 494
ossicles, 478
teeth, 488
Auerbach's plexus, 286
Auriculoventricular valves of heart, 213
Axial canals of small intestine, 285
cords, 157, 160
fibrils of, demonstration of, 181
sheath, 176
thread of spermatosome, 361
sheath of, 361
Axillary glands, 398
Axis-cylinder, 159
naked, 160
Axis-fibrils, 157
Axolemma, 157

Baillarger's striation, 421
Balsam, Canada, as mounting medium, 52
Bardeen's table for drawing of portions of sections to be reconstructed, 57
Bars of intercellular cement, 86
Bartholin's ducts, 253
glands, 360
Basement membrane, 81, 88
of small intestine, 278
Basic stains, 41
Basichromatin granules, 62
Basilar membrane, 488
Basket cells, 254
Baskets, fiber, of retina, 462
Basophile granules, 193
cells with, 209
technic for, 228
Bechtereff and Kaes' striation, 421
Benda's chromatoid accessory nucleus, 377
method for demonstration of medullary sheath, 442
selective neuroglia staining method, 445
Berkley's method of demonstrating nerves of liver, 308
Berlin blue as injection fluid, 55
Bertini, columns of, 324, 330
Bethe's method of fixing methylene-blue for nerve-fibers, 184
of staining neurofibrils and Golgi-nets, 443
Bile capillaries, 290, 291, 292
demonstration of, 306
impregnation of, 307
effect on red blood-corpuscles, 188
Bile-ducts, 296
Bioblasts, 60
Biondi-Heidenhain triple stain, 46
Bipolar cells of cone-visual cells, 463
of rod-visual cells, 463
Bismarck brown as stain, 44
Bladder, 336
nerves of, 339
technic of, 343
Blastema, 64
Blastodermic layers, primary, 79
Blastomeres, 70, 79
Blood, 186
coagulation of, 195
Blood, cover-glass preparations, 227
current, behavior of blood-cells in, 196
demonstration of, through vessels, 231
elements of, method of examining, 227
films, Wright's method of staining, 229
formation of, 186
islands, 186
plasma, 187
platelets, 194
fixation of, 227
shadows, 188
sinus, 222
supply of bronchi, 316
of Fallopian tubes, 355
of heart, 214
of intestine, 283
of lymph-glands, 200
of salivary glands, 259
of spleen, 203
of thymus gland, 212
of thyroid gland, 320
of uterus, 357
technic of, 226
Blood-cells, behavior of, in blood current, 196
counting, 232
red, nucleated, containing hemoglobin, 208
staining of, 227
Blood-corpuscles, cover-glass preparations, 226
red, 187. See also *Erythrocytes*.
technic of, 226
white, 191. See also *Leucocytes*.
Blood-counting apparatus, Thoma-Zeiss, 232
Blood-forming organs, 186
technic of, 226
Blood-plaeques, 194
Blood-vessels, 186, 216
fetal, of eye, 468
in striated muscular tissue, 143
nerve supply of, 223
of bone-marrow, 210
of central nervous system, 439
of eyelid, 473
of kidney, 332
of liver, distribution of, demonstration, 306
examination of, 343

Blood-vessels of lung, 316
of membranous labyrinth, 494
of mucosa of large intestine, 284
of pelvis of kidney, 338
of small intestine, 284
of nasal cavity, 499
of optic nerve, 465
of ovary, 354
of pancreas, 302
of prostate, 370
of retina, 465
of sclera, 449
of stomach, 284
of suprarenal glands, 341
of teeth, 242
of testis, 367
Blutlymphdrüsen, 200
Body-cell, 71
Böhmer's hematoxylin as stain for bulk, 46
hematoxylon, 42
Bone, 112
breakers, 120
calcium carbonate in, alkaline purpurin as stain for, 132
canaliculi, 113
compact, of shaft, development of, 124
corpuscles, 113
Schmorl's method of staining, 133
Virchow's method of isolating, 134
decalcification of, 132
fluids used for, 132
v. Ebner's method, 133
development of, 116
endochondral, 116
intramembranous, 122
endochondral, 116
intracartilaginous, 116
intramembranous, 116, 122
lacunæ of, 112, 113
lamellæ, 113
composition, 114
method of examining, 131
lime-salts in, hematoxylin as stain for, 132
isolation of, 132
soft and hard parts, relation of, method of studying, 132
spaces in, Ranvier's method for demonstrating, 132
structure of, 112
undecalcified, microscopic preparation of, 131
Bone-cells, 112, 115
Bone-marrow, 207
blood-vessels of, 210
gelatinous, 210
red, 207
technic of, 234
yellow, 207, 210
Bony cochlea, 484
labyrinth, 480
Borax-carmin, alcoholic, 41
in bulk, 46
aqueous, 41
Born's method of construction by plates, 56
Böttcher's cells, 491
Boundary zone, choroid, 453
Bowman's capsule, 323
glands, 499
membrane, 449
Box for imbedding tissues, 28
Bronchi, 311
blood supply of, 316
branches of, 311
nerves of, 317
terminal branches of, 313
Bronchioles, 311
respiratory, 313
terminal, 314, 315
Brownian movement of cells, 61
Brücker's lines, 137
Brunner's glands, 265, 277
Budding, 64
Bulb hairs, 393
Bulbus oculi, 446
Burdach's column, 411
Bütschli's foam-structure, staining for, 79

Cæcum cupolare, 485
vestibulare, 485
Calcification of cartilages, 111
Camera lucida, 20
Canada balsam as mounting medium, 52
Canalicular system in cartilage, method of demonstrating, 131
lymph, 102
Canaliculi of bone, 113
Canalis communis, 480
Capillaries, 220
bile, 290, 291, 292
demonstration of, 306
impregnation of, 307
demonstrating distribution of, 235
lymph, 224
of cerebellar cortex, 440
of cerebral cortex, 440
of sweat-glands, 397
Capsule, Bowman's, 323
lens, 468
of cartilage, gold chlorid as stain for, 131
of glands, 92
of Glisson, 289
of lymph-glands, 198
of Tenon, 448
suprarenal, demonstration of, 343
Carmin as stain, 41
mass, cold, as injection fluid, 54
Carmin-bleu de Lyon, 45
Carnoy's acetic acid-alcohol-chloroform mixture, 23
acetic-alcohol mixture, 23
Carotid gland, 225
Cartilage, 108
calcification of, 111
canalicular system in, method of demonstrating, 131

Cartilage, capsules of, gold chlorid as stain for, 131
connective tissue in, picrocarmin as stain for, 131
corrosive sublimate as fixative for, 130
cuneiform, 310
elastic fibers in, picrocarmin as stain for, 131
fibro-elastic, 110
glycogen in, iodo-iodid of potassium stain to demonstrate, 131
ground-substance of, change in, 111
hyaline, 108
of larynx, 310
of Wrisberg, 310
osmic acid a fixative for, 130
ossification of, 111
Caustic potash as macerating solution, 22
Cell, 58
absence of membrane, 62
air-, 314
amacrine, 464
auditory, outer, 491
basket, 254
blood, behavior of, in blood current, 196
counting of, 232
red, nucleated, containing hemoglobin, 208
staining of, 227
body-, 71
bone-, 112, 115
Brownian movement of, 61
centro-acinal, 300
chief, of acini of thyroid gland, 320
of hypophysis, 423
chromophilic, of hypophysis, 423
ciliated, 60
colloid, of acini of thyroid gland, 320
commissural, 408
cone-visual, 459
bipolar cell of, 463
connective-tissue, fat producing, 97
fixed, 103
cortical, small, of cerebellar cortex, 415
crystals of, 61
cuneate, 301
definition of, 58
Deiter's, 491
demilunar, 257
diagram of, 59
diffuse, of retina, 464
double staining of, 76
enamel, 243
endothelial, 80, 94
and mesothelial, method of studying relations, 95
demonstration of, 95
technic for, 233
epithelial, in small intestine, 275
isolated, examination of, 95
fat of, 61
fat-, scheme of, 107
fixing of chromic acid for, 75
corrosive sublimate for, 75
Cell, Flemming's solution for, 75
picric acid for, 75
flagellated, 60
follicular, 372
ganglion, 149
demonstration of, 182
of Dogiel, in spinal ganglia, 426
giant, 209
glandular, 61
glycogen of, 61
goblet, 87, 265
granular, of cerebellar cortex, 416
granules in, Altmann's method of demonstrating, 77, 78
hair-, of utriculus, 483
hepatic, cords of, 290
horizontal, of retina, 464
liver-, examination of, 306
glycogen in, demonstration of, 306
lutein, 353
marrow-, 208
mast-, 104
granules of, technic for, 228
mesameboid, 80
mesothelial, 80
and endothelial, method of studying relations, 95
migratory, 103, 104, 193
mitosis of, demonstration of, 75
mitral, 421
of olfactory bulb, 421
molecular movement of, 61
monostratified, of retina, 464
mother, 374
mucus-secreting, 87
muscle-, cardiac, demonstration of, 148
nonstriated, 134
of fibers of Purkinje, 147
nerve-, 149. See also *Ganglion cell.*
neuro-epithelial, 92
neurogliar, 434
of Böttcher, 492
of Cladius, 492
of column of Clark, 408
of Golgi, 408, 418, 419
of Hensen, 491, 492
of Langerhans, 300
of Leydig, 470
of Martinotti, 418, 419
of pancreas, inner and outer zones, methods of differentiating, 308
of Purkinje, 153
of cerebellar cortex, 415
of reticular connective tissue, 100
of Sertoli, 364
olfactory, 498
parareticular, 464
pigment, 61, 77, 104
pillar, 490
heads of, 490
inner, 490
outer, 490
plasma, 104
plurifunicular, 408
polarity of, 81

Cell, polygonal, of cerebral cortex, 417
polymorphous, of cerebral cortex, 418
polynuclear, 70
polystratified, of retina, 464
pyramidal, large, of cerebral cortex, 417
of cerebral cortex, 153
small, of cerebral cortex, 417
rod-visual, 458
bipolar cell of, 463
seminal, primitive, 372
sense, 81
sexual, fertilization of, 71
male, development of, 72
matured, 71
somatic, 71
spider, 435
spindle-shaped, of cerebral cortex, 417
staining of, 76
stellate, large, of cerebellar cortex, 416
of cerebellar cortex, 415
of cerebral cortex, 417
of liver, 295
sustentacular, 92, 250, 372, 483
tendon, from tail of rat, 107
visual, 458
wandering, 60, 103, 104
with basophilic granules, 209
with eosinophile granules, 209
Cell-bodies of neurones, 149
Cell-body, 59
Cell-division, 64
amitotic, 70
direct, 64, 70
indirect, 64
karyokinetic, heterotypic, 374
homeotypic, 374
mitotic, of fertilized whitefish eggs, 66, 67
ten stages of, 65
Cell-masses, intertubular, of pancreas, 301
Cell-microsomes, 59
Celloidin imbedding, 30
diagram for, 32
infiltration, 30
diagram for, 32
sections, cutting of, with sliding microtome, 36
dextrin method of fixing, 40
Celloidin-paraffin imbedding, 32
infiltration, 32
Cell-plate, 70
Cell-spaces of areolar connective tissue, 102
Cellular elements of areolar connective tissue, 103
Cement lines, 146
Cementum, 241, 246
Centers of ossification, 116
Central artery of retina, 465
gray nuclei of cerebellar cortex, 416
nervous system, 406
blood-vessels of, 439
fibrillar elements of, Apáthy's method of demonstrating, 442
Central nervous system, lymph-vessels of, 440
membranes of, 436
technic of, 440
spindle, 68
vein of retina, 465
Centripetal fibers of cerebral cortex, 420
Centro-acinal cells, 300
Centrosomes, 62, 427
Centrospheres, 62, 427
Cerebellar columns, direct, 411
cortex, 413
capillaries of, 440
central gray nuclei of, 416
granular layer of, 416
granular cells of, 416
large stellate cells of, 416
medullary substance of, 416
climbing fibers of, 416
mossy fibers of, 416
molecular layer of, 413
cells of Purkinje of, 415
small cortical cells of, 415
stellate cells of, 415
Cerebral cortex, 416
capillaries of, 440
medullary substance of, 419
association fibers of, 420
centripetal fibers of, 420
commissural fibers of, 420
projection fibers of, 419
stellate cells of, 417
molecular layer of, 417
polygonal cells of, 417
spindle-shaped cells of, 417
polymorphous cells of, 418
pyramidal cell of, 153
large, 417
small, 417
Ceruminous glands, 398, 476
Cervical canal, islands of ciliated epithelium in, 356
Chemotaxis, 61, 276
Chemotropism, 61
Chief cells of acini of thyroid gland, 320
of hypophysis, 423
Chlorate of potassium and nitric acid as macerating solution, 23
Chondrin, method of obtaining, 112
Choroid, 446, 452
arteries of, 455
boundary zone of, 453
glassy layer of, 452, 453
lamina vasculosa Halleri of, 452
plexus, 439
Choroidal fissure, 447
Chromatin, 63
Chromatoid accessory nucleus of protoplasm of spermatid, 377
Chromatolysis, 74
technic, 74
Chromatophile granules, 149
Chromic acid as fixing solution, 26
as macerating solution, 22
for fixing cells, 75
Chromophilic cells of hypophysis, 423

Chromosomes, 67
daughter, 68
Chrzonszczewsky's physiologic auto-injection, 306
Chyle-vessels, 285
Cilia, 81, 470
movement of, method of observing, 95
Ciliary body, 446, 452, 453
nerve supply of, 456
glands, 398, 454
of Moll, 470
muscle, 454
meridional division, 454
middle division, 454
third or inner division, 454
processes, 453
Ciliated cells, 60
epithelium, islands of, in cervical canal, 356
Circulation of hypophysis, 424
Circulatory system, 212
technic of, 235
Circulus arteriosus iridis major, 455
minor, 456
Circumanal glands, 398
of Gay, 282
Circumferential lamellæ, inner, 113
outer, 113
Circumvallate papillæ, 249
Clark's column, 408
cells of, 408
Claudius, cells of, 492
Clearing fluids, 52
Climbing fibers of cerebellar cortex, 416
Clitoris, 360
Cloquet's canal, 468
Club hairs, 393
Coagulation of blood, 195
Coal-tar stains, 44
Cochlea, 484
bony, 484
perilymph of, 496
spiral ganglion of, 494
technic for, 297
Cochlear duct, 484, 485
Cohnheim's fields, 140
method of impregnation, 48
Coil-glands, 396
Collective lens, 19
Colloid cells of acini of thyroid gland, 320
Colostrum, 402
corpuscles, 402
Columns, anterolateral, ascending, 411
descending, 411
cerebellar, direct, 411
lateral, 408
mixed, 411
of Bertini, 324, 330
of Burdach, 411
of Clark, 408
cells of, 408
of Goll, 411
of Gower, 411
of Sertoli, 364
pyramidal, crossed, 411
ventrolateral, 408
Columns, ventromesial, 408
Columnæ rectales Morgagni, 282
Commissural cells, 408
fibers of cerebral cortex, 420
Commissures of spinal cord, 412
Compound microscope, 17
Concentric lamellæ, 113
Concretions of prostate, 370
Condensers, 19
Cone-fibers of retina, 459
Cone-visual cells, 459
bipolar cells of, 463
Coni vasculosi Halleri, 364
Conjunctiva, 469
scleral, 448
Conjunctival portion of eyelids, 470
Connective tissue, 96
action of acetic acid on, 128
of hydrochloric acid on, 128
of potassium hydrate on, 128
adenoid, 196
areolar, 101
cell-spaces of, 102
cellular elements of, 103
ground-substance of, 102
matrix of, 102
development of, schematic diagram of, 98
effect of pepsin on, 128
of trypsin digestion on, 127
fibrous, 101
white, 99
in cartilage, picrocarmin as stain for, 131
magenta red as stain for, 128
mucous, 100
of liver, 294
orcein as stain for, 128
Ranvier's method for examination of, 126
reticular, 100
cells of, 100
slide digestion of, 129
technic of, 126
Connective-tissue cells, fat producing, 97
fixed, 103
corpuscles, 103
fibrillæ and reticulum, differential stain for, 128
framework of organs and tissues, digestion method for demonstrating, 129
Contraction-ring, 158
Conus medullaris, 406
Convoluted tubules of testes, 363
Cord, spinal, 406 See also *Spinal cord.*
Cords, axial, 157, 160
fibrils of, demonstration of, 181
hepatic, 290
medullary, 199
of hepatic cells, 290
pulp, 204
Corium, 379, 382
Cornea, 446, 449
anterior elastic membrane of, 449
arcuate fibers of, 450

Cornea, epithelium of, 449
ground plexus of, 451
nerves of, 451
technic, 474
perforating fibers of, 450
posterior elastic membrane of, 450
subepithelial plexus of, 451
substantia propria of, 449
technic, 474
superficial plexus of, 451
Corneal corpuscles, 450
epithelium, technic of, 474
spaces, 450
technic of, 474
Corona radiata, 347
Coronary arteries, 214
Corpora amylacea of prostate, 370
lutea spuria, 353
Corpus albicans, 353
Highmori, 363
luteum, 353
verum, 353
Corpuscles, blood-, red, 187. See also *Erythrocytes*.
blood-, white, 191. See also *Leucocytes*.
bone, 113
Schmorl's method of staining, 133
Virchow's method of isolating, 134
colostrum, 402
connective-tissue, 103
corneal, 450
genital, 171
Golgi-Mazzoni, 388
Grandry's technic of, 405
Hassal's, 212
Herbst's, 174, 389
technic of, 405
Malpighian, 202, 203, 323, 324
Meissner's, 170
technic of, 405
Pacinian, 388
technic of, 405
tactile, 387
Vater-Pacinian, 173
distribution of, 174
Corrosive sublimate as fixative for cartilage, 130
as fixing solution, 24
for fixing cells, 75
Cortex, cerebellar, 413. See also *Cerebellar cortex*.
cerebral, 416. See also *Cerebral cortex*.
of ovary, 344
Cortical cells, small, of cerebellar cortex, 415
layer of hair, 389
nodules, 198
substance of kidney, 323, 324
Corti's arches, 490
membrane, 489, 493
organ, 481, 489
spiral organ, 489
Cover-slips, 20
fixing of large number of paraffin sections to, 39
Cowper's glands, 370
Cox's method of impregnation, 51
Crescents of Gianuzzi, 256
Crista basilaris, 488
Cristæ, 481
Crossed pyramidal columns, 411
Crosses, Ranvier's, demonstration of, 180
Crypts, Lieberkühn's, 276
of stomach, 266
Crystalline lens, 467
anterior epithelium of, 468
Crystals, hematoidin, 231
hemin, method of obtaining, 230
hemoglobin, method of obtaining, 230
of cell, 61
Teichmann's, 188
method of obtaining, 230
Cuneate cells, 301
Cuneiform cartilages, 310
Cup, optic, 447
Cupola, 484
Cupula, 484
Currents of diffusion, 29
Cutaneous layer of tympanic membrane, 476
epidermis of, 476
Cuticle, 379
of hair, 389
inner, 389
Cuticula, 62, 81, 274
dentis, 238
Cuticular portion of eyelids, 470
ridge, 477
structures, 81
Cutis, 379. See also *Skin*.
Cylindric end-bulb of Krause, 172
Czermak's interglobular spaces, 241
Czocor's cochineal solution, 42

Damar as mounting medium, 52
Daughter chromosomes, 68
nuclei, 64
stars, 374
Decalcification, 132
v. Ebner's method, 133
Decalcifying fluids, 132
aqueous solution of nitric acid, 133
hydrochloric acid, 132
Deiter's cells, 491
Delafield's hematoxylin, 43
Demilunar cells, 257
Demilunes of Heidenhain, 256
Dendrites, 149, 150
function of, 154
Dendritic fibrous structures of Gruber, 478
Dental sac, 244
Dentin, 239
development of, 244
fibrils of, demonstration of, 303
Dentinal fibers, 240
papillæ, 243
tubules, 240
Dermis, 379, 382

Descemet's membrane, 450
endothelium of, 451
technic of, 474
Descending anterolateral columns, 411
limb of Henle's loop, 327
Deutoplastic granules, 349
Dextrin method of fixing celloidin sections, 40
paraffin sections, 40
Diapedesis, 193
Diaphragm, 17
iris, 18
Diaster, 69, 374
Diffuse cells of retina, 464
spongiblasts, 464
Diffusion, currents of, 29
Digestion method for demonstrating connective-tissue framework of organs and tissues, 129
slide, for connective tissue, 129
Digestive organs, 235
technic of, 303
tract, glands of, technic for, 304
Dilator muscle of pupil, 455
Direct cerebellar columns, 411
pyramidal tract, 411
Discus proligerus, 347
Dispirem, 69
Distilled water for fixing paraffin sections to slide, 39
Dorsal utriculus, 496
Double knife, 21
staining, 44
of cells, 76
Doyère's elevation, 162
Duct, alveolar, 314, 315
Bartholin's, 253
bile-, 296
cochlear, 484, 485
ejaculatory, 368
excretory, 367
Gärtner's, 360
intralobular, of pancreas, 300
nasal, 474
pancreatic, 298
Steno's, 253
utriculosaccular, 481
Wharton's, 253
Wirsungian, 298
Wolffian, 360
Ductus endolymphaticus, 476
Dura mater, nerves of, 437
spinal, 436

Ear, 476
external, 476
technic for, 497
internal, 480
middle, 478
technic for, 497
technic for, 497
vestibule of, 480
Ectoderm, 79
tissues derived from, 79
Egg tubes, primary, of Pflüger, 345
Ehrlich-Biondi-Heidenhain three-color mixture, 229
Ehrlich's granulations, 227
hematoxylin, 43
for nuclei and granules, 228
leucocytic granules, 192
methylene-blue stain for nervous tissues, 182
neutrophile mixture, 229
Ejaculatory ducts, 368
Elastic elements, technic for, 235
fibers, 100
in cartilage, picrocarmin as stain for, 131
respiratory, demonstration of, 322
membrane, anterior, of cornea, 449
posterior, of cornea, 450
tissue, effect of trypsin digestion on, 127
method of obtaining, 127
Enamel, 238
cells, 243
germs, 243
prisms, 238
technic of, 303
Encoche d'ossification, 121
End-brush, 162, 167, 237
End-bulbs of Krause, 170, 388
cylindric, 172
Endocardium, 213
lymphatic networks in, 215
Endochondral bone, 116
bone-development, 116
Endolymph, 495
Endomysium, 143
Endoneurium, 160
Endoplasm, 62, 98, 210
End-organ of Ruffini, 388
Endosteum, 207
Endothelial cells, 80, 94
and mesothelial cells, method of studying relations, 95
demonstration of, 95
technic for, 233
Endothelium, 92
anterior, of iris, 455
of Descemet's membrane, 451
of intima, technic for, 235
End-piece of Retzius, 361
End-plate, motor, 163
Engelman, accessory disc of, 139
Entoderm, 58, 79
tissues derived from, 80
Eosin as stain for blood-cells, 227
Eosinophile granules, 193
cells with, 209
technic for, 227
Epicardium, 214
Epidermis, 379
nerves of, technic of, 405
of cutaneous layer of tympanic membrane, 476
technic of, 403
Epidural space, 437
Epilamellar plexus, 261, 397
Epimysium, 143
Epiphyses, development of, 121

Epiphysis, 422
Epithelial cells in small intestine, 275
isolated, examination of, 95
processes, interpapillary, 85
Epithelium, anterior, of crystalline lens, 468
ciliated, islands of, in cervical canal, 356
classification, 81, 82
columnar, pseudostratified, 83
simple, 83
stratified, 85
corneal technic of, 474
germinal, examination of, 378
of ovary, 345
glandular, 87
neuro-, 92
of alveoli of mammary gland, 401
of cornea, 449
of kidney, demonstration of, 343
of mucous membrane of intestine, 274
leucocytes in, 275
of vagina, 358
of olfactory region, 498
of urethra, 371
of vestibule of vagina, 360
posterior, of iris, 455
respiratory, 315
examination, of, 322
simple, 82
columnar, 83
cubic, 82
squamous, 82
stratified, 83
columnar, 85
squamous, 84
technic of, 94
transitional, 85
Eponychium, 395
Epoöphoron, 344, 360
Erlicki's fluid, 26
Erythroblasts, 208
Erythrocytes, 187
diameter of, 190
effect of acetic acid on, 188
of alkalies on, 189
of bile on, 188
of fluids on, 188
of tannic acid on, 189
of water on, 188
examination of, 226
fresh, fixation of, 226
method of counting, 232, 233
size of, 190
stroma of, 187
technic for, 226
Esophagus, 262
method of examining, 305
Eustachian tube, 479
mucous membrane of, 479
Excavation, physiologic, of retina, 460
Excretory ducts, 367
Exoplasm, 62, 98, 210
External ear, 476
technic for, 497
External limiting membrane of retina, 459, 462
External semicircular canal, 480
Extra-epithelial glands, 88
Eye, 446
anterior lymph-channels of, 469
development of, 446
fetal blood-vessels of, 468
general structure of, 446
pigment membrane of, 446, 447, 457
protective organs of, 469
technic for, 474
tunica externa of, 446
fibrosa of, 446, 448
interna of, 446, 457
vasculosa of, 446, 452
tunics of, 446
Eyeball, 446
interchange of fluids in, 469
Eyelids, 469
blood-supply of, 473
conjunctival portion of, 470
cuticular portion of, 470
middle layer of, 471
third, 473

Fallopian tubes, 354
blood-supply of, 355
mucous membrane of, 354
muscular coat of, 355
treatment of, 378
Farrant's gum glycerin, 53
Fasciculus gracilis, 411
Fat, absorption of, by intestine, 288
method of studying, 306
lobules, 107
of cells, 61
Sudan III as stain for, 130
Fat-cell, scheme of, 107
Fat-marrow, 207
Female genital organs, 344
pronucleus, 74
Fenestra cochleæ, 479
rotunda, 479
vestibuli, 478
Fenestrated membranes, 107
Ferrein, pyramids of, 324
Fertilization, process of, 71
diagrams of, 72, 73
Fetal blood-vessels of eye, 468
Fiber-baskets of retina, 462
Fiber-layer, Henle's, 461
outer of, retina, 461
Fibers, arcuate, of cornea, 450
association, of cerebral cortex, 420
centripetal, of cerebral cortex, 420
climbing, of cerebellar cortex, 416
commissural, of cerebral cortex, 420
cone-, of retina, 459
dentinal, 240
elastic, 100
in cartilage, picrocarmin as stain for, 131
respiratory, demonstration of, 322
heart-muscle, MacCallum's nitric acid mixture for isolating, 23

Fibers, lens, 468
mantle, 69
mossy, of cerebellar cortex, 416
motor, 162
Müller's, 454, 462
muscle-, intrafusal, 175
nonstriated, demonstration of, 148
striated, technic of, 147
striped, 136
voluntary, development of, 144
nerve-, 157
ending in muscular tissue, 162
medullated, demonstration of, 180
of teeth, 242
methylene-blue stain for, 184
nonmedullated, 160
demonstration of, 182
of hair follicles, 393
of utriculus, 483
neuroglia, Benda's method of staining, 445
Mallory's methods of staining, 445
of olfactory nerve, staining of, 182
perforating, of cornea, 450
peripheral, of olfactory bulb, 421
projection, of cerebral cortex, 419
Purkinje's 213
isolated demonstration of, 148
muscle-cells of, 147
Remak's, 160
demonstration of, 182
reticular, of liver, demonstration of, 308
rod-, of retina, 458
Sharpey's, 115
method of isolating, 134
sustentacular, 492
terminal, of cerebral cortex, 420
tunnel-, 494
white, 99
rami, 429, 456
Fibræ circulares, 454
Fibril bundles, 140
Fibrillar elements of nervous system, Apáthy's method for demonstration of, 442
Fibrils, axis-, 157
of axial cord, demonstration of, 181
of dentin, demonstration of, 303
Fibrin, demonstration of, 231
Fibrocartilage, white, 110
Fibro-elastic cartilage, 110
Fibrous connective tissue, 101
tissue elastic, 106
Filiform papillæ, 248
Films, blood, Wright's method of staining, 229
Filum terminale, 406
Fimbriæ linguæ, 249
Fissure, choroidal, 447
Fixing methods, 23
solutions, 23
acetic sublimate, 25
alcohol, 23
Bütschli's foam-structure, for cells, 79
Fixing solutions, Carnoy's acetic-alcohol, 23
Carnoy's acetic acid-alcohol-chloroform, 23
chromic acid, 26
for cells, 75
corrosive sublimate, 24
for cartilage, 130
for cells, 75
Erlicki's, 26
Flemming's 24
for cells, 75
Fol's, 24
formalin, 27
formol, 27
Hayem's, 226
Hermann's, 24
Müller's, 26
nitric acid, 26
osmic acid, 24
for cartilage, 130
picric acid, 25
for cells, 75
picric-nitric acid, 25
picric-osmic-acetic acid, 25
picric-sublimate-osmic acid, 25
picrosulphuric acid, 25
potassium bichromate and formalin 27
Rabl's, 25
Tellyesnicky's, 26
vom Rath's, 25
Zenker's, 26
Flagellate cells, 60
Flagellum of spermatosome, 361
Flemming's germ centers, 194
solution, 24
for fixing cells, 75
Flower-like nerve-ending, 178
Fold, semilunar, 484
Foliate papillæ, 249
Follicles, Graafian, 347
bursting of, 352
hair, 389
nerve-fibers of, 393
lymph-, germ centers of, technic for, 234
of mucosa of vermiform appendix, 281
of tongue, 251
of tonsils, 251
solitary, 197
technic for, 306
ovarian, atresia of, 353
simple, 197
Follicular cells, 372
glands, 91
Folliculi linguales, 251
Fol's solution, 24
Fontana's spaces, 455
Foramen apicis dentis, 238
Foramina nervosa, 488
papillaria, 330
Formalin as fixing solution, 27
Formol as fixing solution, 27
Fovea centralis, 460

Foveolæ of stomach, 266
Fragmentation, direct, of nucleus, 71
Freezing apparatus for sliding microtome, 36
Friedländer's glycerin-hematoxylin, 43
Front lens, 19
Fuchsin-resorcin elastic fibers stain, 128
Fundamental lamellæ, 113
Fundus glands of stomach, 268
of fovea centralis, 460
Fungiform papillæ, 248
Funiculi, of nerve-trunk, 160
compound, 162
Funnels, pial, 439
Future periosteum, 116

GANGLIA, 424
spinal, 424
sympathetic, 427
Ganglion cell, 149
demonstration of, 182
layer of retina, 459, 464
of Dogiel, in spinal ganglia, 426
spiral, of cochlea, 494
Gärtner's duct, 360
Gastric mucous membrane, 266
Gastrulation, 79
Gay's circumanal glands, 282, 398
Gelatin-Berlin blue as injection fluid, 54
Gelatin-carmin as injection fluid, 54
Gelatinous bone-marrow, 210
substance of Rolando, 408
Genital corpuscles, 171
organs, female, 344
male, 361
Genito-urinary organs, 323
technic of, 342
Gerlach's method of impregnation, 48
Germ center, 197
of Flemming, 194
of lymph-follicles, technic for, 234
enamel, 243
hair, 389
layers, 58
primary, 79
Germinal epithelium, examination of, 378
of ovary, 345
vesicle, 71
Giant cells, 209
Gianuzzi, crescents of, 256
Giraldès, organ of, 367
Gitterfasern, 301
Glands, alveolar, 91. See also *Alveolar glands*.
axillary, 398
capsule of, 92
carotid, 225
ceruminous, 389, 476
ciliary, 398, 454
Moll's, 470
circumanal, 282, 398
coil-, 396
extra-epithelial, 88
follicular, 91
hemal, 200
Glands, hemolymph, 200
structure of, 201
injection of, 55
intra-epithelial, 88
lacrimal, 473
accessory, 470
nerve supply of, 473
lenticular, 271
lymph-, 196, 197
blood supply of, 200
capsule of, 198
hilum of, 197
lymph-sinuses of, 199
marrow, 201, 202
technic for, 233
trabeculæ of, 198
with blood-sinuses, 200
mammary, 400. See also *Mammary gland*.
Meibomian, 472
mixed, 258
mucous, 255
multicellular, 88
classification, 91
of Bartholin, 360
of Bowman, 499
of Brunner, 265, 277
of Cowper, 370
of digestive tract, technic for, 304
of Gay, 282, 398
of Lieberkühn's, 88, 276
of Moll, 398, 470
of Montgomery, 402
of mouth, small, 259
of oral cavity, 253
of skin, 396
of stomach, 267
cardiac, 267
fundus, 268
of Tyson, 372
parathyroid, 321
parotid, 255
peptic, 268
pineal, 422
prostate, 368. See also *Prostate*.
pyloric, 269
salivary, 253, 255
blood supply of, 259
nerve supply of, 260
sebaceous, 398
serous, 255
splenolymph, 201
structure and classification, 88
sublingual, 255
submaxillary, 258
sudoriparous, 396. See also *Sweat-glands*.
suprarenal, 339. See also *Suprarenal glands*.
sweat-, 396. See also *Sweat-glands*.
tarsal, 472
thymus, 210
blood supply of, 212
thyroid, 319. See also *Thyroid gland*.
tubular, 89. See also *Tubular glands*.
tubulo-alveolar, 90

Glands, unicellular, 87
Glandula carotica, 225
Glandulæ buccales, 236
duodenales, 265
labiales, 236
Glandular cells, 61
epithelium, 87
Glassy layer of choroid, 452, 453
membrane of hair, 391
Glisson's capsule, 289
Glomerular layer of olfactory bulb, 421
Glomeruli arteriosi cochleæ, 495
Glomerulus, 323
Glomus caroticum, 225
Glycerin, Farrant's gum, mounting in, 53
mounting in, 53
Glycerin-albumen for fixing paraffin sections to slide, 38
Glycogen in cartilage, iodo-iodid of potassium stain to demonstrate, 131
in liver-cells, demonstration of, 306
of cells, 61
Goblet cells, 87, 265
Gold chlorid as stain for capsules of cartilage, 131
method of impregnation, 48
Golgi-Mazzoni corpuscle, 388
Golgi-nets, Bethe's method of staining, 443
Golgi's cells, 408, 418, 419
chromsilver or chromsublimate method of impregnation, 49
gold chlorid method of impregnation, 48
methods of impregnation, 49, 50
mixed method of impregnation, 50
potassium bichromate and bichlorid of mercury method of impregnation, 50
method of impregnation, 49
preparations, Huber's method of permanently mounting under coverglass, 51
rapid method of impregnation, 50
slow method of impregnation, 50
Goll's column, 411
Gower's column, 411
Graafian follicle, 347
bursting of, 352
Grandry's corpuscles, technic of, 405
Granular cells of cerebellar cortex, 416
layer of cerebellar cortex, 416
of olfactory bulb, 421
Tomes', 246
sole plate, 163
Granulations of leukocytes, 227
Granules, acidophile, technic for, 227
amphophile, technic for, 228
basichromatin, 63
basophile, 193
cells with, 209
technic of, 228
chromatophile, 149
deutoplastic, 349
eosinophile, 193
cells with, 209
technic for, 227
Granules, in cells, Altmann's method of demonstrating, 77, 78
indulinophile, technic for, 228
interstitial, Kölliker's, 141
leukocytic, Ehrlich's, 192
neutrophile, 193
technic of, 228
oxychromatin, 63
Schrön's, 344
tigroid, 149
zymogen, in pancreas, demonstration of, 308
Gray nuclei, central, of cerebellar cortex, 416
substance of spinal cord, 406, 409
Grenacher's alum-carmin, 42
as stain for bulk, 46
Ground bundle, anterior, 411
plexus of cornea, 451
Ground-substance interfascicular, 105
of areolar connective tissue, 102
of cartilage, changes, in, 111
Gruber's dendritic fibrous structure, 478
Gscheidtlen's method of obtaining hemoglobin crystals, 230
Gum glycerin, Farrant's mounting in, 53

Hair, 389
auditory, 490
bulb, 389, 393
club, 393
cortical layer of, 389
cuticle of, 389
inner, 390
follicle, 389
nerve-fibers of, 393
germ, 389
glassy membrane of, 391
growth of, 392
medullary substance of, 390
olfactory, 499
papilla, 389
root, 389
root-sheaths of, 389
inner, 390
outer, 390
shaft, 389
shedding of, 393
technic for, 404
Hair-cells of utriculus, 483
Hamulus, 484
Hassal's corpuscles, 212
Haversian canals, 112
spaces, 120
Hayem's solution, 226
for diluting blood, 232
Hearing, organ of, 476. See also *Ear.*
Heart, 186, 213
auriculoventricular valves of, 213
blood supply of, 214
elastic tissue of, 214
muscle, 145
motor nerve-supply of, 166
muscle-cells, demonstration of, 148
muscle-tissue, development of, 146

Heart, nerve supply of, 215
Heart-muscle fibers, MacCallum's nitric acid mixture for isolating, 23
Heidenhain's demilunes, 256
iron hematoxylin, 43
as stain for bulk, 46
median membrane, 137
Helicotrema, 485
Heliotropism, 61
Heller's plexus, 283
Hemal glands, 200
Hemalum, acid, as stain, 43
as stain, 43
in bulk, 46
Hematin, 187
Hematoblasts, 194
Hematoidin crystals, 231
Hematoxylin as stain, 42. See also *Stains*.
Hematoxylin-eosin as stain, 45
Hematoxylin-safranin as stain, 46
Hemin, 188
crystals, method of obtaining, 230
Hemocytometer, Thoma-Zeiss, 232
Hemoglobin, 187
crystals, method of obtaining, 230
demonstration of, 230
nucleated red blood-cells containing, 208
Hemokonia, 195
Hemolymph glands, 200
structure of, 201
Henle's fiber layer, 461
layer, 390
loop, 323
descending limb of, 327
sheath, 162
Hensen's cells, 491, 492
median disc, 137
Hepatic artery, 293
cells, cords of, 290
cords, 290
Herbst's corpuscles, 174, 389
technic of, 405
Hermann's solution, 24
Heterotypic mitosis, 70
Hilum of lymph-glands, 197
Histology, general, 58
special, 186
Homeotypic mitosis, 70
Honing microtome knife, 37
Horizontal cells of retina, 464
semicircular canal, 480
Horns of spinal cord, 408
Howship's lacunæ, 120
Hoyer's yellow gelatin mass, 54
Huber's method of permanently mounting Golgi's preparations under coverglass, 51
Humor, aqueous, 446
Huschke's auditory teeth, 488
Huxley's layer, 390
Hyaline cartilage, 108
Hyaloid arteries, anterior, 468
posterior, 468
canal, 468
Hyaloid membrane of vitreous body, 467
Hydatids of Morgagni, 360
Hydrochloric acid, action of, on connective tissue, 128
as decalcifying fluid, 132
as macerating solution, 23
Hydrotropism, 61
Hymen, 359
Hypolamellar plexus, 261
Hypophysis, 423
chief cells of, 423
chromophilic cells of, 423
circulation of, 424

Imbedding, 27
celloidin, 30
diagram for, 32
celloidin-paraffin, 32
paraffin, 27
diagram for, 30
Immersion lens, 19
Impregnation, Cohnheim's method, 48
Cox's method 51
Gerlach's method, 48
gold chlorid method, 48
Golgi's chromsilver or chromsublimate method, 49
gold chlorid method, 48
methods, 49
mixed method, 50
potassium bichromate and bichlorid of mercury method, 50
potassium bichromate method, 49
rapid method, 50
slow method, 50
Kopsch's method, 52
Kühne's method, 48
Löwit's method, 48
methods of, 47
of bile capillaries, 307
Ranvier's method, 48
silver nitrate method, 47
Indifferent fluids, 21, 22
Kronecker's, 22
physiologic saline solutions, 22
Ranvier's solution of iodin and potassium iodid, 22
Ripart and Petit's, 22
Schultze's iodized serum, 22
Indulinophile granules, technic for, 228
Inferior nasal artery of retina, 466
vein of retina, 466
papillary artery of retina, 466
vein of retina, 466
vertical semicircular canal, 480
Infiltration, 27
celloidin, 30
diagram for, 32
celloidin-paraffin, 32
paraffin, 27
diagram for, 30
Injection fluids, 53
Altman's, 55
Berlin blue, 53
carmin mass, cold, 54

Injection fluids, gelatin-Berlin blue, 54
gelatin-carmin, 54
silver nitrate, 55
yellow gelatin mass, 54
Injection method for demonstration of bile capillaries, 306
of distribution of hepatic blood-vessels, 306
methods of, 53
of animals, 54
of glands, 55
of lymph-channels, 55
of lymph-spaces, 55
of lymph-vessels, 55
of organs, 55
Inner molecular layer of retina, 464
nuclear layer of retina, 459, 462
scleral sulcus, 449
Intercellular bridges, 81, 380
demonstration of, 96
spaces, 81
substance, 79
Interfascicular ground-substance, 105
Interglobular spaces of Czermak, 241
Interlobular arteries of kidney, 332
veins of kidney, 334
of liver, 293
Intermediate tubule of pancreas, 300
Internal auditory artery, 494
ear, 480
limiting membrane of retina, 462
Interpapillary epithelial processes, 85
Interstitial granules of Kölliker, 141
Intertubular cell-masses of pancreas, 301
Intestine, 264
absorption of fat by, 288
blood supply of, 283
large, 281
blood-vessels of mucosa of, 284
lymph-vessels of, 284
lymph supply of, 283
mucous membrane of, general structure, 264
nerves of, demonstration of, 306
muscularis mucosæ of, 265
nerve supply of, 283
secretion of, 288
small, 274
axial canals of, 285
basement membrane of, 278
epthelial cells in, 275
lymphatics of, 285
lymph-nodules of, 279
mucous membrane of, 274, 277
blood-vessels of, 284
epithelium of, 274
leucocytes in, 275
lymph-nodules of, 279
villi of, 274
muscularis mucosæ of, 279
villi of, lacteals of, 285
with villi, fixation of, 305
stratum circulare of, 266
fibrosum of, 265
longitudinale of, 266
submucosa of, 265
Intestine, tunica mucosa of, 265
Intima, endothelium of, technic for, 235
Intracapsular plexuses, 429
Intracartilaginous bone, 116
Intra-epithelial glands, 88
Intrafusal muscle-fibers, 175
Intralobular duct of pancreas, 300
Intramembranous bones, 116, 122
bone-development, 122
Iodo-iodid of potassium stain to demonstrate glycogen in cartilage, 131
Iris, 446, 452, 455
anterior endothelium of, 455
diaphragm, 18
nerve supply of, 456
posterior epithelium of, 455
stroma of, 455
Islands of ciliated epithelium in cervical canal, 356
Isotropic intermediary disc, 138

Jacobson's organ, 499
Japanese method of fixing paraffin sections to slide, 39
Jelly, Wharton's, 100

Kaes and Bechtereff's striation, 421
Karyokinesis, 64
Karyokinetic cell-division, heterotypic, 374
homeotypic, 374
Karyolysis, 74
Karyosomes, 63
Keratohyalin, 380
technic for, 403
Kidney, 323
arched collecting portion of tubules, 323, 329
blood-vessels of, 332
cortical substance of, 323, 324
distal convoluted portion of tubules, 323, 329
epithelium of, demonstration of, 343
intercalated portion of tubules, 323, 329
interlobular arteries of, 332
veins of, 334
lymphatics of, 334
medullary substance of, 323
nerves of, 334, 335
pelvis of, 336
mucosa of, 337
blood-vessels of, 338
proximal convoluted portion of tubules, 323, 325
secretory processes of, 335
straight collecting tubules of, 323
technic of, 342
tubules of, demonstration of, 342
vasa afferentia of, 332
Knife, double, 21
microtome, honing of, 37
sharpening of, 37
Kölliker's interstitial granules, 141
muscle-columns, 140

Kölliker's neuropodia, 151
Kollmann's cold carmin mass, 54
Kolossow's method of demonstrating intercellular bridges, 96
Kopsch's method of impregnation, 52
Krause, end-bulbs of, 170, 388
  cylindric, 172
  membrane of, 137
Kronecker's fluid, 22
Kühne's method of impregnation, 48
Kupffer's stellate cells, 295
Kytoblastema, 64

Labium tympanicum, 487
  vestibulare, 487
Laboratory microtome, 33
Labyrinth, bony, 480
  development of, 496
  membranous, 480, 481
    blood-vessels of, 494
    technic for, 497
  osseous, 480
  technic for, 497
Lacrimal apparatus, 473
  glands, 473
    accessory, 470
    nerve supply of, 473
  sac, 474
Lacteals of villi of small intestine, 285
Lacunæ, Howship's, 120
  of bone, 112, 113
Lamellæ, 105
  bone, 113
    compostion of, 114
    method of examining, 131
  circumferential, inner, 113
    outer, 113
  concentric, 113
  fundamental, 113
  periosteal, 113
Lamina basilaris propria, 489
  choriocapillaris, 452, 453
  cribrosa, 448, 465
  elastica interna, 218
  fusca, 448
  propria of oral cavity, 236
    of tympanic membrane, 477
  reticularis, 489, 493
  spiralis membranacea, 485
    ossea, 484, 486
  suprachoroidea, 448, 452
  vasculosa Halleri of choroid, 452
Langerhans, areas of, 301
  cells of, 300
Large intestine, 281. See also *Intestine, large.*
Larynx, 309
  cartilages of, 310
  demonstration of, 322
  mucous membrane of, 309
  nerves of, 311
  vascular supply of, 310
Lateral column, 408
    mixed, 411
Ledges, terminal, 86
Lens, 446
  apochromatic, 19
  capsule, 468
  collective, 19
  crystalline, 467
    anterior epithelium of, 468
  fibers, 468
  front, 19
  immersion, 19
  ocular, 19
  suspensory ligament of, 467
  technic of, 475
Lenticular glands, 271
Leucocyte-nucleus, polymorphism of, 193
Leucocytes, 191
  granulations of, 227
  in epithelium of mucous membrane of small intestine, 275
  method of counting, 232, 233
  mononuclear, 192
  motility of, 193
  size of, 192
  transitional, 192
  with polymorphous nuclei, 192
Leucocytic granules, Ehrlich's, 192
Leydig's cells, 470
Lieberkühn's glands, 88, 276
Ligament, suspensory, of lens, 467
Ligaments, 105
Ligamentum nuchæ of ox, structure of, 106
  pectinatum iridis, 454
  spirale, 485, 488
Limbus spiralis, 486, 487
Lime-salts in bone, hematoxylin as stain for, 132
  isolation of, 132
Limiting membrane, external, of retina, 459, 462
  internal, of retina, 462
Lines of Retzius, 239
  of Schräger, 239
Lingual mucous membrane, 247
    papillæ of, 247
  papillæ, 247
Linin, 63
Liquor folliculi, 347
Liver, 289
  blood-vessels of, distribution of, demonstration, 306
    examination of, 343
  connective tissue of, 294
  interlobular veins of, 293
  lobules, 289
  lymphatics of, 297
  nerves of, 298
    demonstration of, 308
  reticular fibers of, demonstration of, 308
  reticulum of, 294
  stellate cells of, 295
  technic of, 306
  tissue, technic of, 307
  trabeculæ of, 290
Liver-cells, examination of, 306
  glycogen in, demonstration of, 306
Loop, Henle's, 323

Loop, Henle's descending limb of, 327
Löwit's method of impregnation, 48
Lugol's solution to demonstrate glycogen in cartilage, 131
Lung alveoli, 314
blood-vessels of, 316
lobules of, 316
lymphatics of, 317
nerves of, 317
structure, units of, 316
tissue of, demonstration of, 322
Lunula, 395
Lutein, 353
cells, 353
Lymph, 186
canalicular system, 102
capillaries, 224
Lymphatic networks in endocardium, 215
system, 223
Lymph-channels, anterior, of eye, 469
injection of, 55
Lymph-follicles, germ centers of, technic for, 234
of mucosa of vermiform appendix, 281
of tongue, 251
of tonsils, 251
solitary, 197
technic for, 306
Lymph-glands, 196, 197
blood supply of, 200
capsule of, 198
hilum of, 197
lymph-sinuses of, 199
marrow, 201, 202
technic for, 233
trabeculæ of, 198
with blood-sinuses, 200
Lymph-nodules, 196
agminated, 197
of mucosa of small intestine, 279
Lymphocytes, 191, 194
size of, 192
Lymphoid tissue, 196
Lymph-sinus, 199
Lymph-spaces, 224
injection of, 55
periaxial, 176
perichoroidal, 452
Lymph-supply of intestine, 283
Lymph-vessels, 186, 223
injection of, 55
of central nervous system, 440
of kidney, 334
of large intestine, 284
of liver, 297
of lung, 317
of mammary glands, 402
of mouth, 260
of ovary, 354
of skin, 386
of small intestine, 285
of testes, 367
of uterus, 357

MacCallum's nitric acid mixture, 23
Macerating solutions, 22
alcohol, 22
caustic acid, 22
potash, 22
chromic acid, 22
hydrochloric acid, 23
MacCallum's, 23
nitric acid, 23
and chlorate of potassium, 23
sulphuric acid, 23
Maceration, methods of, 22
Macula acustica sacculi, 481
utriculi, 481
lutea, 460
region of, 460
Magenta red as stain for connective tissue, 128
Male genital organs, 361
pronucleus, 73
Mallory's differential stain for connective-tissue fibrillæ and reticulum, 128
selective neuroglia fiber-staining methods, 445
Malpighian corpuscles, 202, 203, 323, 324
pyramid, 323
Mammary gland, 400
alveoli of, epithelium of 401
lymphatics of, 402
nerves of, 402
Mantle fibers, 69
Marginal thread of spermatosome, 361
zone, 81
Marrow, bone-, 207. See also *Bone-marrow.*
fat-, 207
lymph-glands, 102, 202
spaces, primary, 118
secondary, 120
Marrow-cells, 208
Martinotti's cells, 418, 419
Mast-cells, 104
granules, technic of, 228
Matrix of areolar connective tissue, 102
of nail, 394
sulcus of, 394
Mature ovum, 351
Mayer's solutions for staining mucin, 305
Median disc of Hensen, 137
membrane of Heidenhain, 137
Mediastinum testis, 363
Medullary cords, 199
rays, 323
sheath, 157
technic, 440
Benda's, 442
Pal's, 442
Weigert's, 440, 441
substance of cerebellar cortex, 416
of cerebral cortex, 419
of hair, 390
of kidney, 323
of ovary, 344
Meibomian gland, 472
Meissner's corpuscles, 170, 387
technic of, 405

Meissner's plexus, 287
Membrana capsulopupillaris, 468
præformativa, 244
prima, 81
propria, 88, 92
of pancreas, 301
of uriniferous tubules, 330
pupillaris, 468
tectoria Cortii, 489, 493
Membrane, basement, 81, 88
of small intestine, 278
basilar, 488
Bowman's, 449
cell, absence of, 62
Corti's, 489, 493
Descemet's, 450
endothelium of, 451
technic of, 474
elastic, anterior, of cornea, 449
posterior, of cornea, 450
external limiting, of retina, 459, 462
fenestrated, 107
glassy, of choroid, 452, 453
of hair, 391
Heidenhain's, 137
hyaloid, of vitreous body, 467
internal limiting, of retina, 462
Krause's, 137
median, of Heidenhain, 137
mucous. See also *Mucous membrane.*
Nasmyth's, 238
nuclear, 63
of central nervous system, 436
oral mucous, fixation of, 303
otolithic, 483
peridental, 242
pigment, of eye, 446, 447, 457
Reissner's, 485, 489
rudder, of spermatosome, 361
tympanic, 476. See also *Tympanic membrane.*
undulating, of spermatosome, 361
vestibular (Reissner's), 485, 489
vitreous, 452, 453
Meninges of central nervous system, 436
Menisci, tactile, 387
technic of, 405
Merkel's terminal disc, 139
Mesameboid cells, 80
Mesenchymatous tissue, 97
Mesenchyme, 80
Mesoderm, 58, 79
cells of, 80
Mesothelial cells, 80
and endothelial cells, method of studying relations, 95
Mesothelium, 80, 92
Metakinesis, 68
Metaphases, 65, 68
Methylene-blue stain, Ehrlich's, for nervous tissues, 182
for nerve-fibers, 184
Methyl-green as stain, 44
Metschnikoff's phagocytes, 60
Meyer's method of staining nerve-fibers, 184
Microcentrum, 191
Microscope and its accessories, 17
coarse adjustment of, 18
compound, 17
description of, 17
fine adjustment of, 18
parts of, 17
simple, 17
Microscopic preparation, 21
preparations of undecalcified bone, 131
technic, introduction to, 17
Microtome, 32
knife, honing of, 37
sharpening of, 37
laboratory, 33
Minot automatic precision, 33, 34
rotary, 34, 35
precision, 33
rocking, 33
rotary, 35
sliding, 33
cutting celloidin sections with, 36
paraffin sections with, 35
freezing apparatus for, 36
Middle ear, 478
technic for, 497
Migratory cells, 103, 104, 193
Milk, 402
secretion, 401
Minot automatic precision microtome 33, 34
rotary microtome, 34, 35
Mitochondria, 60
Mitosis, 64
demonstration of, 75
heterotypic, 70
homeotypic, 70
Mitotic cell-division of fertilized white-fish eggs, 66, 67
ten stages of, 65
Mitral cells, 421
of olfactory bulb, 421
Mixed gland, 258
lateral column, 411
Modified sweat-glands, 398
Modiolus, 484
Molecular layer, inner, of retina, 464
of cerebellar cortex, 413
of cerebral cortex, 417
of olfactory bulb, 421
outer, of retina, 45, 462
movement of cells, 61
Moll's glands, 398, 470
Monaster, 68
Mononuclear leucocytes, 192
Monostratified cells of retina, 464
Montgomery's glands, 402
Morgagni, hydatids of, 360
Morula mass, 79
Mossy fibers of cerebellar cortex, 416
Mother cell, 374
nucleus, 64
skein, 67
Motor end-plate, 163
fibers, 162
nerve-endings, 162

Motor nerve-endings, staining of, 182
neurones. 153
peripheral, 162
diagram of, 163
Mounting, 21, 52
Mouth, glands of, small, 259
lymphatics of, 269
Muchematein, 305
Mucicarmin, 305
Mucin, demonstration of, 304, 305
staining of, 305
Mucous connective tissue, 100
gland, 255
layer of tympanic membrane, 478
membrane, gastric, 266
intestinal, general structure of, 264
nerves of, demonstration of, 306
nasal, technic of, 500
of Eustachian tube, 479
of Fallopian tubes, 354
of larynx, 309
of oral cavity, 236
of pelvis of kidney, 337
blood-vessels of, 338
of small intestine, 274, 277
blood-vessels of, 284
epithelium of, 274
leucocytes in, 275
lymph-nodules of, 279
villi of, 274
of stomach, fixation of, 305
of tongue, 247
of uterus, 355
of vagina, 358
epithelium of, 358
of vermiform appendix, lymph-follicles in, 281
oral, fixation of, 303
Mucus-secreting cell, 87
Müller's fibers, 454
of retina, 462
fluid, 26
Multicellular glands, 88
classification, 91
Muscle and tendon, relation of, method of studying, 148
ciliary, 454
dilator, of pupil, 455
heart, 145
fibers of, MacCallum's nitric acid mixture for isolating, 23
motor nerve-supply of, 166
nonstriated, motor nerve-supply of, 166
red, 141
sphincter, of pupil, 455
striated, nerve-endings in, Sihler's method of demonstrating, 184
white, 141
Muscle-cells, cardiac, demonstration of, 148
nonstriated, 134
of fibers of Purkinje, 147
Muscle-columns of Kölliker, 140
Muscle-fibers, intrafusal, 175
nonstriated, demonstration of, 148
Muscle-fibers, striated, technic of, 147
striped, 136
voluntary, development of, 144
Muscular coat of Fallopian tubes, 355
of uterus, 356
of vagina, 359
tissue, 134
destruction of, 144
development of, 144
heart, development of, 146
nerve-fibers ending in, 162
striated, blood-vessels in, 143
technic of, 147
Muscularis mucosæ of intestine 265
of small intestine, 279
of stomach, 271
Musculus ciliaris Riolani, 471
orbicularis oculi, 471
palpebralis superior, 472
Myelin sheath, 157
Myelocytes, 208
Myeloplaxes, 209
Myoblasts, 144
Myocardium, 213

Nail, 394
bed, 394
sulcus of, 394
body of, 394
lunula of, 395
matrix, 394
sulcus of, 394
root, 394
walls, 394
Nasal artery, inferior, of retina, 466
superior, of retina, 466
cavity, 498
blood-vessels of, 499
nerves of, 500
technic of, 500
vestibule of, 498
duct, 474
mucous membrane, technic of, 500
vein, inferior, of retina, 466
superior, of retina, 466
Nasmyth's membrane, 238
Nerve end-organs, neuromuscular, 174
neurotendinous, 178
Nerve-cells, 149. See also *Ganglion cell*.
Nerve-endings, annulospiral, 178
flower-like, 178
in striated muscle, Sihler's method of demonstrating, 184
motor, 162
staining of, 182
peripheral, 162
Ruffini's, 387
sensory, 166
encapsulated, 169
free, 168, 169
staining of, 182
Nerve-fibers, 157
ending in muscle tissue, 162
layer of retina, 464

Nerve-fibers, medullated, demonstration of, 180
of teeth, 242
methylene-blue stain for, 184
nonmedullated, 160
demonstration of, 182
of hair follicles, 393
of utriculus, 483
Nerves, auditory, 494
in taste-buds, demonstration of, 304
of bladder, 339
of bronchi, 317
of ciliary body, 456
of cornea, 451
technic, 474
of dura mater, 437
of epidermis, technic of, 405
of heart, 215
of intestine, 283
of intestinal mucous membrane, demonstration of, 306
of iris, 456
of kidney, 334, 335
of lacrimal gland, 473
of larynx, 311
of liver, 298
demonstration of, 308
of lung, 317
of mammary glands, 402
of nasal cavity, 500
of ovary, 354
of pancreas, 302
of penis, 372
of pia mater, 439
of prostate, 370
of salivary glands 260
of sclera, 451
of skin, 387
of suprarenal glands, 342
of tongue, 252
of sweat-glands, 397
of testes, 367
of thyroid gland, 320
of trachea, 311
of ureter, 339
of uterus, 358
of vagina, 360
olfactory, staining fibers of, 182
optic, 446, 464
pilomotor, 394
supplying blood-vessels, 223
Nerve-trunk, funiculi of, 160
compound, 162
Nervous system, central, 406
blood-vessels of, 439
fibrillar elements of, Apáthy's method of demonstrating, 442
lymph-vessels of, 440
membranes of, 436
technic of, 440
tissue, 148
Ehrlich's methylene-blue stain for, 182
fixation of, 183
technic of, 180
tunic of eye, 446, 457
Net-knots, 63
Networks, technic for, 235
Neura, 149
Neuraxes, 148, 151
Neurilemma, 158
Neurilemma-nuclei, 158
Neuroblasts, 148
Neurodendron, 149
Neuro-epithelial cells, 92
Neuro-epithelium, 92
Neurofibrils, Bethe's method of staining, 443
Neuroglia, 434
fibers, Benda's method of staining 445
Mallory's methods of staining, 445
staining of, 444
Neurogliar cells, 434
Neurokeratin, 157
Neuromuscular nerve end-organs, 174
Neurones, 149
cell-bodies of, 149
independence of, theory of, 156
motor, 153
peripheral, 162
diagram of, 163
relationship of, 431
sensory, peripheral, diagram of, 167
Neuroplasm, 157
Neuropodia, 151
Neurotendinous nerve end-organ, 178
Neutrophile granules, 193
technic for, 228
mixture Ehrlich's, 229
Nitric acid and chlorate of potassium as macerating solution, 23
aqueous solution, as decalcifying fluid, 133
as fixing solution, 26
as macerating solution, 23
MacCallum's, 23
Nodes of Ranvier, 158
demonstration of, 180
Nodules, 197
cortical, 198
lymph-, 196
agminated, 197
of mucosa of small intestine, 279
secondary, 197
terminal, of spermatosome, 361
Normoblasts, 208
Nuclear division, 64
layer, inner, of retina, 459, 462
membrane, 63
stains, 41
Nuclein, 63
Nucleolus, 58
true, 63
Nucleus, 58, 62
achromatic portion of, 63
chromatoid accessory, of Benda, 377
contents of, 62
daughter, 64
direct fragmentation of, 71
dorsalis, 408
gray, central, of cerebellar cortex, 416

Nucleus, leucocyte-, polymorphism of, 193
mother, 64
of spermatid, 377
resting, 63
segmentation, 71
sole, 163
telolemma, 163
Nuel's space, 492

Ocular lens, 19
Odontoblasts, 240, 241, 244
Odontoclasts, 247
Olfactory bulb, 421
glomerular layer of, 421
granular layer of, 421
mitral cells of, 421
molecular layer of, 421
peripheral fibers of, 421
cells, 498
hairs, 499
region, 498
epithelium of, 498
nerve, fibers of, staining of, 182
Oocytes, 350
Optic cup, 447
nerve, 446, 464
blood-vessels of, 465
papilla, 460
region of, 460
stalks, 446
vesicles, primary, 446
secondary, 447
Ora serrata, 461
Oral cavity, 235
glands of, 253
mucous membrane of, 236
fixation of, 303
submucosa of, 236
Orbiculus ciliaris, 453
Orcein as stain for connective tissue, 128
Osmic acid as fixative for cartilage, 130
as fixing solution, 24
as stain for adipose tissue, 130
Osseous labyrinth, 480
Ossicles, auditory, 478
Ossification, centers of, 116
groove, 121
of cartilage, 111
ridge, 121
Osteoblasts, 118
Osteoclasts, 120
Otolithic membrane, 483
Otoliths, 483
Outer fiber layer of retina, 461
molecular layer of retina, 459, 462
Ovarian tissue, fixation of, 378
Ovary, 344
antrum of, 347
blood-vessels of, 354
cortex of, 344
germinal epithelium of, 345
lymphatics of, 354
medullary substance of, 344
nerves of, 354
Ovary, stratum granulosum of, 345
stroma of, 344
technic of, 378
Ovula Nabothi, 356
Ovum, 71, 344
changes in, during development, 350
mature, 351
primitive, 345, 350
ripe, 350
technic for, 378
vacuole of, 344
Oxychromatin granules, 63

Pacchionian bodies, 438
Pacinian corpuscles, 388
technic of, 405
Pal's method for demonstration of medullary sheath, 442
Pancreas, 298
blood-vessels of, 302
cells of, inner and outer zones, methods of differentiating, 308
intermediate tubule of, 300
intertubular cell-masses of, 301
intralobular duct of, 300
membrana propria of, 301
nerves of, 302
technic of, 308
zymogen granules in, demonstration of, 308
Pancreatic duct, 298
Panniculus adiposus, 384
Papilla, 84
circumvallate, 249
dentinal, 243
filiform, 248
foliate, 249
fungiform, 248
hair, 389
lingual, 247
optic, 460
region of, 460
spiralis cochlea, 481
tactile, 383
vascular, 383
Papillary artery, inferior, of retina, 466
superior, of retina, 466
vein, inferior, of retina, 466
superior, of retina, 466
Paracarmin as stain, 42
in bulk, 46
Paradidymis, 367
Paraffin imbedding, 27
diagram for, 30
infiltration, 27
diagram for, 30
removal of, 40
sections, cutting of, with sliding microtome, 35
dextrin method of fixing, 40
distilled water for fixing of, to slide, 39
fixing of large numbers to cover-slips, 39

Paraffin sections, glycerin-albumen for fixing of, to slide, 38
Japanese method of fixing to slide, 39
Paralinin, 63
Paranuclein, 63
Paraplasm, 60
Parareticular cells, 464
Parathyroid glands, 321
Paroöphoron, 360
Parotid gland, 255
Pars ciliaris retinæ, 453, 461
iridica retinæ, 461
papillaris, 382
reticularis, 382
Partsch's cochineal solution, 42
Pellicula, 62
Pelvis of kidney, 336
mucosa of, 337
blood-vessels of, 338
renal, 336
Penis, 370
erectile tissue of, 371
nerves of, 372
Pepsin, effect of, on connective tissue, 128
Peptic glands, 268
Perforating fibers of cornea, 450
Periaxial lymph-space, 176
Pericardium, 214
Pericellular plexuses, 428
Perichondrium, 109
Perichoroidal lymph-spaces, 452
Peridental membrane, 242
Perilymph of cochlea, 496
Perilymphatic spaces, 224
Perimysium, 143
Perineurium, 161
Periosteal lamellæ, 113
Periosteum, 112
alveolar, 242
future, 116
Peripheral fibers of olfactory bulb, 421
motor neurones, 162
diagram of, 163
nerve terminations, 162
sensory neurone, diagram of, 167
Peritendineum, 105
Perivascular spaces, 224
Petit's canal, 467
Petit and Ripart's solution, 22
Peyer's patches, 265
technic for, 306
Pflüger's egg tubes, 345
Phagocytes, 193, 194
Metschnikoff's, 60
Phalangeal plate, 491, 492
process, 491
Pharyngeal tonsils, 252
Pharynx, 262
Physiologic excavation of retina, 460
Pia intima, 438
mater, 438
nerves of, 439
Pial funnels, 439
Picric acid as fixing solution, 25
as stain, 45
Picric acid for fixing cells, 75
Picric-nitric acid as a fixing solution, 25
Picric-osmic-acetic acid solution as fixing fluid, 25
Picric-sublimate-osmic solution as fixing fluid, 25
Picrocarmin as stain for connective tissue in cartilage, 131
for elastic fibers in cartilage, 131
of Ranvier, 44
of Weigert, 45
Picrosulphuric acid as fixing solution, 25
Pigment, 97
cells, 77, 104
membrane of eye, 446, 447, 457
of cells, 61
of skin, 384
technic of, 404
Pillar cells, 490
heads of, 490
inner, 490
outer, 490
Pilomotor nerves, 394
Pineal gland, 422
Pituitary body, 423. See also *Hypophysis*.
Plasma, blood, 187
cells, 104
Plate, phalangeal, 491, 492
Platelets, blood, fixation of, 227
Plates, technic for, 235
Pleura, visceral and parietal layer of, 319
Plexus, choroid, 439
epilamellar, 261, 397
ground, of cornea, 451
Heller's, 283
hypolamellar, 261
intracapsular, 429
myentericus, 286
of Auerbach, 286
of Meissner, 287
pericellular, 428
subepithelial, of cornea, 451
superficial, of cornea, 451
Plicæ palmatæ, 356
semilunares, 282, 473
sigmoideæ, 266
transversales recti, 282
Plural staining, 44
Plurifunicular cells, 408
Polar body, 72
field, 70
rays, 68
Polarity of cells, 81
Polygonal cells of cerebral cortex, 417
Polykaryocyte, 193
Polymorphism of leucocyte-nucleus, 193
Polymorphous cells of cerebral cortex, 418
Polynuclear cells, 70
Polystratified cells of retina, 464
Portal vein, 292
Posterior hyaloid arteries, 468
vertical semicircular canal, 480

Potash, caustic, as macerating solution, 22
Potassium bichromate and formalin as fixing fluid, 27
chlorate of, nitric acid and, as macerating solution, 23
hydrate, action of, on connective tissue, 128
Precapillary arteries, 218
veins, 220
Precision microtome, 33
Prepuce, 372
Primary blastodermic layers, 79
egg tubes of Pflüger, 345
germ layers, 79
marrow spaces, 118
optic vesicles, 446
tendon bundles, 105
Primitive ova, 345, 350
seminal cells, 372
Primordial ova, 345
Prisms, enamel, 238
Projection fibers of cerebral cortex, 419
Prominentia spiralis, 488
Pronucleus, female, 74
male, 73
Prophases, 64, 66
Prostate, 368
blood-vessels of, 370
concretions of, 370
corpora amylacea of, 370
nerves of, 370
secretion of, 370
Prostatic bodies, 370
Protoplasm, 58, 59
of spermatids, chromatoid accessory nucleus of, 377
sphere substance of, 376
Protoplasmic currents, 75
stains, 41
Protozoa, 58
Pseudopodia, 60
Pulp cords, 204
splenic, structure of, 205
tooth-, 241
Pupil, dilator muscle of, 455
sphincter muscle of, 455
Purkinje's cells, 153
of cerebellar cortex, 415
fibers, 213
isolated, demonstration of, 148
muscle-cells of, 147
vesicle, 344
Purpurin, alkaline, as stain for calcium carbonate in bone, 132
Pyloric glands, 269
Pyramidal cells of cerebral cortex, 153
large, of cerebral cortex, 417
small, of cerebral cortex, 417
columns, crossed, 411
tract, direct, 411
Pyramids of Ferrein, 324
of Malpighian, 323

Quintuple hydroquinon developer, 51

Rabl's hematoxylin-safranin, 46
solutions, 25
Rami cochleares, 494
vestibulares, 494
Ramón y Cajal's technic for retina, 475
Ranvier's crosses, demonstration of, 180
method for examination of connective tissue, 126
of demonstrating glycogen in liver-cells, 306
spaces in bone, 132
of impregnation, 48
nodes, 158
demonstration of, 180
picrocarmin, 44
solution of iodin and potassium iodid, 22
Recessus cameræ posterioris, 467
cochleæ, 496
Rectum, 281
Red bone-marrow, 207
muscles, 141
Red-blood corpuscles, 187. See also *Erythrocytes*.
Reissner's membrane, 485, 489
Remak's fibers, 160
demonstration of, 182
Renal artery, 332
lobes, 323
pelvis, 336
Renflement bicônique, 158
Respiration, organs of, 309
technic of, 322
Respiratory bronchioles, 313
elastic fibers, demonstration of, 322
epithelium, 315
examination of, 322
region, 498
Resting nucleus, 63
Rete testis, 363
canals of, 365
Retia mirabilia, 222
arterial, 333
Reticular connective tissue, 100
cells of, 100
fibers of liver, demonstration of, 308
tissue, demonstration of, 234
Reticulum of liver, 294
Retina, 446, 447, 457
arteries of, 466
blood-vessels of, 465
central artery of, 465
vein of, 465
cone-fibers of, 459
external limiting membrane of, 459, 462
fiber-baskets of, 462
ganglion-cell layer of, 459, 464
inferior nasal artery of, 466
vein of, 466
papillary vein of, 466
inner molecular layer of, 464
nuclear layer of, 459, 462
internal limiting membrane of, 462
macula lutea of, 460
Müller's fibers of, 462

Retina, nerve-fiber layer of, 464
optic papilla of, 460
ora serrata of, 461
outer fiber layer of, 461
molecular layer of, 459, 462
pars ciliaris retinæ, 461
iridica retinæ, 461
physiologic excavation of, 460
relation of elements of, to one another, 462
rod-fibers of, 458
superior nasal artery of, 466
vein of, 466
papillary artery of, 466
vein of, 466
technic of, 475
Retinaculæ cutis, 384
Retzius, end-piece of, 361
lines of, 239
Ring, contraction-, 158
Ripart and Petit's solution, 22
Ripe ovum, 350
Rocking microtome, 33
Rod-fibers of retina, 458
Rod-visual cells, 458
bipolar cells of, 463
Rolando's gelatinous substance, 408
Root-sheaths of hair, 389. See also *Hair, root-sheaths of.*
Röse's carmin-bleu de Lyon, 45
Rouleaux, 187
Rudder membrane of spermatosome, 361
Ruffini end-organ, 388

Sabin's modification of Mallory's differential stain for connective-tissue fibrillæ and reticulum, 129
Sacculus, 481, 482
ventral, 496
Saccus endolymphaticus, 481, 496
Safranin as stain, 44
Salivary glands, 253, 255
blood supply of, 259
nerve supply of, 260
Salts, lime-, in bone, hematoxylin as stain for, 132
isolation of, 132
Sarcolemma, 135, 137
Sarcolytes, 144
Sarcomeres, 138
Sarcoplasm, 135, 137
Sarcous elements, 141
Scala media, 485
tympani, 485
vestibuli, 485
Schachowa's spiral segment, 327
Schlemm's canal, 448
Schmidt-Lantermann-Kuhnt's segments, 157
Schmorl's method of staining bone corpuscles, 133
Schräger's lines, 239
Schrön's granule, 344
Schultze's iodized serum, 22
Schwann, sheath of, 158
Sclera, 446, 448
blood-vessels of 449
nerve supply of, 451
technic of, 475
Scleral conjunctiva, 448
sulcus, inner, 449
Sebaceous glands, 398
Secondary marrow spaces, 120
optic vesicle, 447
tendon bundles, 105
Secretion, milk, 401
of intestine, 288
of prostate, 370
process of, 92
vacuoles, 291
Secretory processes of kidney, 335
Sectioning, 32
Sections, 21
staining of, 41
Sectionwork, appropriate stains for, 235
Segmentation nucleus, 71
Segments, Schmidt-Lantermann-Kuhnt's, 157
spiral, of Schachowa, 327
Selective stains, 41
Semicircular canal, 483
anterior superior vertical, 480
external, 480
horizontal, 480
posterior inferior vertical, 480
Semilunar fold, 484
Seminal cells, primitive, 372
fluid, examination of, 378
vesicles, 368
Sense cells, 81
Sensory nerve-endings, 166
encapsulated, 169
free, 168, 169
staining of, 182
neurone, peripheral, diagram of, 167
Septa renis, 324
Septum posticum, 438
Serous cavities, 224
gland, 255
Sertoli's cells, 364
Sexual cells, fertilization of, 71
male, development of, 72
matured, 71
Sharpening microtome knife, 37
Sharpey, fibers of, 115
method of isolating, 134
Sheath, axial, 176
Henle's, 162
medullary, 157
technic, 440
Benda's, 442
Pal's, 442
Weigert's, 440, 441
myelin, 157
of axial thread of spermatosome, 361
of Schwann, 158
Shedding hair, 393
Sihler's method of demonstrating nerve-endings in striated muscle, 184
Silver nitrate as injection fluid, 55
method of impregnation, 47

Simple epithelium, 82. See also *Epithelium, simple.*
microscopes, 17
Sinus, blood, 222
lactiferus, 400
lymph-, 199
pocularis, 370
Sinuses, 222
Sinusoids, 221
Skein, mother, 67
Skin, 379
and appendages, 379
technic of, 403
glands of, 396
lymph-vessels of, 386
nerves of, 387
pigment of, 384
technic for, 404
structure of, technic for, 404
true, 379
vascular system of, 386
Slide digestion for connective tissue, 129
Slides, 20
Sliding microtome, 33. See also *Microtome, sliding.*
Small intestine, 274. See also *Intestine, small.*
Smell, organ of, 498
Sole nuclei, 163
plate, granular, 163
Somatic cell, 71
Specimens, permanent, preparation of, 52
Spermatids, 72, 374
develoment of, into spermatosomes, 374, 376
nucleus of, 377
protoplasm of, chromatoid accessory nucleus of, 377
sphere substance of, 376
Spermatoblast, 376
Spermatocytes, 70, 72
of first order, 374
of second degree, 374
of third degree, 374
Spermatogenesis, 372
schematic diagrams of, 373
technic of, 378
Spermatogones, 72
Spermatogonia, 372
Spermatosome, 361
accessory thread of, 361
axial thread of, 361
sheath of, 361
development of, from spermatids 374 376
flagellum of, 361
head of, 361
marginal thread of, 361
middle piece of, 361
rudder membrane of, 361
tail of, 361
terminal nodule of, 361
undulating membrane of, 361
Spermatozoa, 60, 71, 73
Spermatozoon, 361. See also *Spermatosome.*
Sphere substance of protoplasm of spermatids, 376
Sphincter muscle of pupil, 455
Spider cells, 435
Spinal cord, 406
anterior median fissure of, 406
commissures of, 412
gray substance of, 406, 409
horns of, 408
posterior median septum of, 406
white substance of, 406, 409
ganglia, 424
ganglion cell of Dogiel, 426
Spindle, achromatic, 68
central, 68
Spindle-shaped cells of cerebral cortex, 417
Spiral ganglion of cochlea, 494
organ of Corti, 489
segment of Schachowa, 327
Spirem, 67
Spleen, 202
blood supply of, 203
lobules, 204
diagram of, 205
trabeculæ of, 203
Splenic pulp, structure of, 206
tissue, demonstration of, 234
Splenolymph glands, 201
Spongioblasts, 434
diffuse, 464
stratum, 464
Spongioplasm, 60, 274
Spot, Wagner's, 344
Staining, 41
blood-cells, 227
blood films, Wright's method, 229
bone corpuscles, Schmorl's method, 133
double, 44
of cells, 76
fibers of olfactory nerve, 182
in bulk, 46
diagram for, 47
in sections, diagram for, 47
motor nerve-endings, 182
neurofibrils and Golgi-nets, Bethe's method, 443
neuroglia, 444
fibers, Benda's method, 445
Mallory's methods, 445
plural, 44
section, 41
sensory nerve-endings, 182
Stains, 41
acid, 41
fuchsin-picric acid solution, van Gieson's, 45
hemalum, 43
alkaline purpurin, for calcium carbonate in bone, 132
alum-carmin, 42
for bulk, 46
anilin, 44
basic, 41
Biondi-Heidenhain triple, 46

Stains, Bismarck brown, 44
borax-carmin, alcoholic, 41
for bulk, 46
aqueous, 41
carmin, 41
carmin-bleu de Lyon, 45
coal-tar, 44
Czocor's cochineal solution, 42
differential, for connective-tissue fibrillæ and reticulum, 128
Ehrlich's methylene-blue, for nervous tissues, 182
eosin, for blood-cells, 227
for adipose tissue, 130
for canalicular system in cartilage, 131
for mucin, 305
for sectionwork, 235
fuchsin-resorcin elastic fibers, 128
gold chlorid, for capsules of cartilage, 131
Heidenhain's iron, for bulk, 46
hemalum, 43
acid, 43
for bulk, 46
hematoxylin, Böhmer's, 42
for bulk, 46
Delafield's, 43
Ehrlich's, 43
for nuclei and granules, 228
for lime-salts in bone, 132
Friedländer's glycerin-, 43
hematoxylin-eosin, 45
hematoxylin-safranin, 46
hematoxylon, 42
Heidenhain's iron, 43
iodo-iodid of potassium, to demonstrate glycogen in cartilage, 131
magenta red, for connective tissue, 128
methylene-blue, for nerve-fibers, 184
methyl-green, 44
nuclear, 41
orcein, for connective tissue, 128
paracarmin, 42
for bulk, 46
Partsch's cochineal solution, 42
picric acid, 45
picrocarmin, Ranvier's, 44
Weigert's, 45
protoplasmic, 41
safranin, 44
selective, 41
Sudan III, for fat, 130
triple, 46
Stars, daughter, 374
Stellate cells of cerebellar cortex, 415
large, of cerebellar cortex, 416
of cerebral cortex, 417
of liver, 295
Stellulæ vasculosæ, 453
Steno's ducts, 253
Stomach, 264, 266
blood-vessels of, 284
crypts of, 266
epithelium and secretory cells of, changes in, during secretion, 271
foveolæ of, 266
Stomach, glands of, 267
cardiac, 267
fundus, 268
pyloric, 269
mucous membrane of, 266
fixation of, 305
muscularis mucosæ of, 271
Stomach-pits, 266
Straight tubules of testes, 363
Stratified epithelium, 83. See also *Epithelium, stratified.*
Stratum circulare, 477
of intestine, 266
corneum, 379, 381
fibrosum of intestine, 265
germinativum, 379
granulosum, 379
of ovary, 347
longitudinale of intestine, 266
lucidum, 381
technic for, 403
Malpighii, 379
technic of, 403
proprium of oral cavity, 236
radiatum, 477
spongioblasts, 464
submucosum of oral cavity, 236
Stria vascularis, 488
Striated muscle, nerve-endings in, Sihler's method of demonstrating, 184
muscle-fibers, technic of, 147
muscular tissue, blood-vessels in, 143
Striation of Baillarger, 421
of Bechtereff and Kaes, 421
of iris, 455
of ovary, 344
of red blood-corpuscles, 187
Subarachnoid space, 437
Subdural space, 437
Subepithelial plexus of cornea, 451
Sublingual gland, 255
Submaxillary gland, 258
Submucosa of intestine, 265
of oral cavity, 236
of urethra, 372
Substantia propria of cornea, 449
technic for, 474
Succus prostaticus, 370
Sudan III as stain for fat, 130
Sudoriparous glands, 396. See also *Sweat-glands.*
Sulcus of matrix of nail, 394
spiralis internus, 487
Sulphuric acid as macerating solution, 23
Superficial plexus of cornea, 451
Superior nasal artery of retina, 466
vein of retina, 466
papillary artery of retina, 466
vein of retina, 466
Suprarenal capsule, demonstration of, 343
glands, 339
blood-vessels of, 341
nerves of, 342
Suspensory ligament of lens, 467
Sustentacular cells, 92, 250, 372, 483

Sustentacular fiber, 492
Sweat-glands, 396
  capillaries of, 397
  coiled portion of, 396
  modified, 398
  nerves of, 397
Sympathetic ganglia, 427
Syncytium, 97
  development and differentiation, 98

Tactile corpuscles, Meissner's, 387
    technic of, 405
  menisci, 387
    technic of, 405
  papillæ, 383
Tæniæ coli, 266
  semilunares, 282
Tannic acid, effect on red blood-corpuscles, 189
Tapetum cellulosum, 453
  fibrosum, 453
Tarsal gland, 472
Taste-buds, 249
  nerves in, demonstration of, 304
  technic for, 303
Taste-pore, 250
Teasing, 21
Teeth, 238
  adult, structure of, 238
  auditory, 488
  blood-vessels of, 242
  development of, 243
    method of studying, 303
  medullated nerve-fibers of, 242
  pulp of, 241
  technic for, 303
Teichmann's crystals, 188
    method of obtaining, 230
Tela submucosa, 236
Tellyesnicky's fluid, 26
Telodendria, 150, 162
Telolemma nuclei, 163
Telophases, 65, 70
Temperature, high, effect on tissues, 29
Temporal artery, inferior, of retina, 466
    superior, of retina, 466
  vein, inferior, of retina, 466
    superior of retina, 466
Tendon, 105
  and muscle, relation of, method of studying, 148
  bundles, primary, 105
    secondary, 105
  cells from tail of rat, 107
  fasciculi, 105
Tenon's capsule, 448
Terminal bronchioles, 314, 315
  fibers of cerebral cotex, 420
  ledges, 86
  nodule of spermatosome, 361
Testes, 362
  blood-vessels of, 367
  convoluted tubules of, 363
  examination of, 378
  lymph-vessels of, 367
Tests, nerves of, 367
  straight tubules of, 363
  vasa efferentia of, 363, 365
Theca folliculi, 347
Third eyelid, 473
Thoma's ampullæ, 204
  Zwischenstück, 204
Thoma-Zeiss hemocytometer, 232
Thread-granules, 60
Thrombocytes, 194
Thymus gland, 210
    blood supply of, 212
Thyroid gland, 319
    acini of, chief cells of, 320
      colloid cells of, 320
    blood supply of, 320
    demonstration of, 322
    nerves of, 320
  granules, 149
Tissue, 79
  adipose, 107
    stain for, 130
  connective, 96. See also *Connective tissue*.
  effect of high temperature on, 29
  elastic, effect of trypsin digestion on, 127
    method of obtaining, 127
  epithelial, 80
  erectile, 371
  fibrous, elastic, 106
  liver, technic of, 307
  lymphoid, 196
  mesenchymatous, 97
  muscular, 134
    destruction of, 144
    development of, 144
    heart, development of, 146
    nerve-fibers ending in, 162
    striated, blood-vessels in, 143
    technic of, 147
  nervous, 148
    Ehrlich's methylene-blue stain for, 182
    fixation of, 183
    technic of, 180
  ovarian, fixation of, 378
  pulmonary, demonstration of, 322
  reticular, demonstration of, 234
  splenic, demonstration of, 234
Toison's fluid for diluting blood, 232
Tomes' granular layer, 246
  processes, 244
Tongue, 247
  lymph-follicles of, 251
  mucous membrane of, 247
  nerve supply of, 252
  papillæ of, 247
Tonsils, lymph-follicles of, 251
  pharyngeal, 251
Trabeculæ of liver, 290
  of lymph-glands, 198
  of spleen, 203
Trachea, 310
  demonstration of, 322
  nerves of, 311

Transitional epithelium, 85
leucocytes, 192
Triple stains, 46
Trophoplasts, 385
Trypsin digestion, effect on connective and elastic tissues, 127
Tubular glands, 89
coiled, 90
compound branched, 90
reticulated, 90
simple branched, 90
Tubules, convoluted, of testes, 363
dentinal, 240
intermediate, of pancreas, 300
of kidney, demonstration of, 342
straight collecting, of kidney, 323
of testes, 363
uriniferous, 323
membrana propria of, 330
Tubuli recti, 363
Tubulo-alveolar gland, 90
Tunica albuginea, 92, 344, 362
dartos, 384
externa of eye, 446
fibrosa of eye, 446, 448
interna of eye, 446, 457
mucosa of intestine, 265
propria of oral cavity, 236
sclerotica, 446, 448. See also *Sclera*.
vaginalis, 362
vasculosa, 362
of eye, 446, 452
Tunics of eye, 446
Tunnel-fibers, 494
Tympanic investing layer, 489
membrane, 476
cutaneous layer of, 476
epidermis of, 476
lamina propria of, 477
mucous layer of, 478
Tympanum, 478
Tyson, glands of, 372

UNDECALCIFIED bone, microscopic preparations of, 131
Undulating membrane of spermatosome, 361
Unicellular glands, 87
Unna's orcein stain for connective tissue, 128
Ureter, 336
nerves of, 339
technic of, 343
Urethra, epithelium of, 371
submucosa of, 372
Urinary organs, 323
Uriniferous tubules, 323
membrana propria of, 330
Uterus, 355
blood supply of, 357
lymphatics of, 357
mucous membrane of, 355
muscular coat of, 356
nerves of, 358
Utriculosaccular duct, 481
Utriculus, 481, 482
dorsal, 496
nerve-fibers of, 483
wall of, 482

VACUOLE of ovum, 344
Vacuoles, 61
secretion, 291
Vagina, 358
mucous membrane of, 358
epithelium of, 358
muscular coat of, 359
nerves of, 360
vestibule of, epithelium of, 360
Valves, auriculoventricular, of heart, 213
of veins, 220
Valvulæ conniventes, 265, 274
Van Gieson's acid fuchsin-picric acid solution, 45
Vas aberrans Halleri, 366
deferens, 367
epididymidis, 364, 366
spirale, 489
Vasa afferentia, 197
of kidney, 332
efferentia, 197
of testes, 363, 365
recta spuria, 334
Vascular canals, 112
papillæ, 383
supply of larynx, 310
system, 213
of skin, 386
tunic of eye, 446, 452
Vater-Pacinian corpuscles, 173
distribution of, 174
Veins, 219
central, of retina, 465
interlobular, of kidney, 334
of liver, 293
nasal, inferior, of retina, 466
superior, of retina, 466
papillary, inferior, of retina, 466
superior, of retina, 466
portal, 292
precapillary, 220
small, 220
temporal, inferior, of retina, 466
superior, of retina, 466
valves of, 220
Venæ arciformes, 334
stellatæ, 334
vorticosæ, 452
Ventral sacculus, 496
Ventrolateral column, 408
Ventromesial column, 408
Venulæ rectæ, 334
Vermiform appendix, mucosa of, lymph-follicles of, 281
Vesicles, germinal, 71
optic, primary, 446
secondary, 447
Purkinje's, 344
seminal, 368
(Reissner's), 485, 489

Vestibule of ear, 480
of nasal cavity, 498
of vagina, epithelium of, 360
Villi of mucous membrane of small intestine, 274
of small intestine, lacteals of, 285
Virchow's bone corpuscles, method of isolating, 134
Visual cells, 458
Vitreous body, 446, 467
hyaloid membrane of, 467
membrane, 452, 453
Volkmann's canals, 115
vom Rath's solutions, 25
von Ebner's method of decalcification, 133
von Koch's technic for bone, 132

Wagner's spot, 344
Wandering cells, 60, 103, 104
Water, distilled, for fixing paraffin sections to slide, 39
effect on red blood-corpuscles, 188
Wax plates, 56
apparatus for making, 56
reconstruction by, 55
Born's method, 56
cutting out parts to be reconstructed, and completing model, 57
drawing apparatus, 56
serial sections, 56
Weigert's fuchsin-resorcin elastic fibers stain, 128
Weigert's methods for demonstration of medullary sheath, 440, 441
picrocarmin, 45
Wharton's ducts, 253, 254
jelly, 100
White blood-corpuscles, 191. See also *Leucocytes*.
fibers, 99
fibrocartilage, 110
muscles, 141
rami communicantes, 429
fibers, 429, 456
substance of spinal cord, 406, 409
Wirsungian duct, 298
Wolffian duct, 360
Wright's method of staining blood films, 229
Wrisberg, cartilages of, 310

Yellow bone-marrow, 207, 210
gelatin mass as injection fluid, 54

Zenker's fluid, 26
Zinn's arterial circle, 465
zonule, 467
Zona pellucida, origin of, 350
Zone, boundary, of choroid, 453
marginal, 81
Zonula ciliaris, 446, 467
Zonule of Zinn, 467
Zymogen, 255
granules in pancreas, demonstrating, 308

WELLCOME LIBRARY INSTITUTE

SAUNDERS' BOOKS

on

SURGERY

and

ANATOMY

W. B. SAUNDERS & COMPANY

9, HENRIETTA ST., COVENT GARDEN, LONDON

PHILADELPHIA
925 Walnut Street

NEW YORK
Fuller Building, Fifth Ave. and 23d St.

SAUNDERS' REMARKABLE SUCCESS

WE are often asked to account for our extraordinary success. We can but point to modern business methods, carefully perfected business machinery, and unrivalled facilities for distribution of books. Every department is so organized that the greatest possible amount of work is produced with the least waste of energy. The representatives of the firm are men with life-long experience in the sale of medical books. Then, too, we must not overlook that major force in the modern business world—advertising. We have a special department devoted entirely to the planning, writing, and placing of advertising matter; and we might mention that the money annually spent in advertising now far exceeds the entire annual receipts of the House during its earlier years. These extraordinary facilities for disposing of large editions enable us to devote a large amount of money to the perfecting of every detail in the manufacture of books.

A Complete Catalogue of our Publications will be Sent upon Request

Howard A. Kelly on the Vermiform Appendix

JUST ISSUED—AN AUTHORITATIVE WORK

The Vermiform Appendix and Its Diseases. By HOWARD A. KELLY, M. D., Professor of Gynecology in the Johns Hopkins University, Baltimore; and E. HURDON, M. D., Assistant in Gynecology in the Johns Hopkins University, Baltimore. Handsome octavo volume of about 800 pages, containing 400 superb original illustrations and several lithographic plates.

WITH 400 SUPERB ORIGINAL ILLUSTRATIONS

This work is one of the most magnificent medical books ever published, containing over four hundred beautiful illustrations, in the preparation of which the artists of the Johns Hopkins Hospital have spent many years. Each beautifully and accurately portrays the condition represented, and together they form a magnificent collection unequaled by those in any other work on the subject ever placed upon the market. A large amount of original work has been done for the anatomic chapter, for which over one hundred original illustrations have been made. Appendicitis naturally receives the fullest consideration. The pathology is not only amply and clearly described, but it is beautifully illuminated with an abundance of illustrations depicting the pathologic conditions with rare fidelity. Diagnosis and treatment, by far the most important sections to the practitioner and surgeon, are elaborately discussed and profusely illustrated. Special chapters are devoted to the peculiarities of appendicitis in children, and to the characteristics of the vermiform appendix in typhoid fever. An unusual chapter, but one of the greatest value to both the medical and legal professions, is that on the medicolegal status of appendicitis. A valuable contribution to the study of the relative frequency of diseases of the appendix consists in the presentation of the results of several thousand autopsies.

Bickham's Operative Surgery

JUST ISSUED, SECOND EDITION—TWO EDITIONS IN SIX MONTHS

A Text-Book of Operative Surgery. Covering the Surgical Anatomy and Operative Technic involved in the Operations of General Surgery. For Students and Practitioners. By WARREN STONE BICKHAM, M.D., Assistant Instructor in Operative Surgery, Columbia University (College of Physicians and Surgeons), New York. Handsome octavo of about 1000 pages, with 559 beautiful illustrations, nearly all original. Beautifully bound in Cloth, 25*s.* net.

WITH 559 BEAUTIFUL ILLUSTRATIONS, NEARLY ALL ORIGINAL

This absolutely new work completely covers the surgical anatomy and operative technic involved in the operations of general surgery. Constructed on thoroughly new lines, the discussion of the subject is remarkably systematized and arranged in a manner entirely original. Being the work of a teacher of extensive experience who, as such, is thoroughly familiar with the wants of students and general practitioners, the book is eminently practical and the subject treated in such a manner as to render its comprehension most easy. This practicability of the work is particularly emphasized in the numerous magnificent illustrations which form a useful and striking feature. There are some 559 of them. All have been drawn especially for this book, and they depict the pathologic conditions and the progressive steps in the various operations detailed with unusual fidelity, their artistic and mechanical excellence being of the highest standard. The text has been brought precisely down to the present day, all the recent advances along the line of technic having been fully discussed, and elucidated with many illustrations. A distinguishing and extremely useful feature is the treatment of the anatomic side of the subject in connection with the operative technic. Anatomy of the human body is of the utmost importance in the practical application of operative surgery, for unless the surgeon know the exact location of the various muscles, bones, etc., he will cause unnecessary destruction of tissue, and perhaps irreparable injury.

NICHOLAS SENN, M. D.

Professor of Surgery, Rush Medical College, in Affiliation with the Univ. of Chicago.

"A SOMEWHAT CAREFUL EXAMINATION OF THE TEXT AND ILLUSTRATIONS OF DR. BICKHAM'S BOOK ON OPERATIVE SURGERY HAS SATISFIED ME OF ITS MERITS. THE BOOK WILL MEET WITH FAVOR ON THE PART OF TEACHERS, STUDENTS, AND PRACTITIONERS."

Eisendrath's Clinical Anatomy

A NEW WORK—JUST ISSUED

A Text-Book of Clinical Anatomy. By DANIEL N. EISENDRATH, A.B., M.D., Professor of Clinical Anatomy, Medical Department of the University of Illinois (College of Physicians and Surgeons), Chicago; Attending Surgeon to the Cook County Hospital, etc. Handsome octavo of 515 pages, beautifully illustrated with entirely original illustrations. Beautifully bound in Cloth, *21s.* net.

WITH MANY BEAUTIFUL ORIGINAL ILLUSTRATIONS

The subject of anatomy, and especially clinical anatomy, is so closely allied to practical medicine and surgery that it is absolutely impossible for a physician or surgeon to practice his profession successfully unless he have an intimate knowledge of the human structure. This work is intended to serve as a guide and reference book to the general practitioner as well as a text-book for the student. It treats of practical anatomy—anatomy which it is necessary for the physician to have at his certain command at the bedside, in the clinic, and in the operating room. The entire subject is discussed with the thoroughness and preciseness that spring from experience, and the author's style is clear and concise. The method of illustrating the subject is novel, especial attention being given to surface anatomy. The illustrations themselves are the result of a great deal of painstaking study, the great majority of them being from new and original drawings and photographs. They are reproduced in the highest style of art, and show far better than those in any similar work the relation of anatomic structures from a clinical standpoint, presenting to the student a picture of anatomy as he meets it at the bedside, with the skin covering the tissue. A portion of each chapter is devoted to the examination of the living through palpation and marking of surface outlines of landmarks, vessels, nerves, thoracic and abdominal viscera. For the student and practitioner alike, the work will be found unrivaled.

Medical Record, New York

"THE THOROUGHLY PRACTICAL MANNER IN WHICH THE AUTHOR HAS PERFORMED HIS TASK WILL MEET WITH GENERAL APPROBATION. . . . A SPECIAL RECOMMENDATION FOR THE FIGURES IS THAT THEY ARE MOSTLY ORIGINAL AND WERE MADE FOR THE PURPOSE IN VIEW. THE SECTIONS OF JOINTS AND TRUNKS ARE THOSE OF FORMALINIZED CADAVERS AND ARE UNIMPEACHABLE IN ACCURACY."

International Text-Book of Surgery

SECOND EDITION, THOROUGHLY REVISED AND ENLARGED

The International Text-Book of Surgery. In two volumes. By British and American authors. Edited by A. PEARCE GOULD, M.S., F.R.C.S., of London, England; and J. COLLINS WARREN, M.D., LL.D., F.R.C.S. (Hon.), Professor of Surgery, Harvard Medical School.—Vol. I. *General and Operative Surgery.* Royal octavo, 975 pages, 461 illustrations, 9 full-page colored plates.—Vol. II. *Special or Regional Surgery.* Royal octavo, 1122 pages, 499 illustrations, and 8 full-page colored plates.

Per volume: Beautifully bound in cloth, 21*s.* net.

ADOPTED BY THE U. S. ARMY

In this new edition the entire book has been carefully revised, and special effort has been made to bring the work down to the present day. The chapters on Military and Naval Surgery have been very carefully revised and extensively rewritten in the light of the knowledge gained during the recent wars. The articles on the effect upon the human body of the various kinds of bullets, and the results of surgery in the field are based on the latest reports of the surgeons in the field. The chapter on Diseases of the Lymphatic System has been completely rewritten and brought up to date; and of special interest is the chapter on the Spleen. The already numerous and beautiful illustrations have been greatly increased, constituting a valuable feature, especially so the seventeen colored lithographic plates.

OPINIONS OF THE MEDICAL PRESS

Annals of Surgery

"It is the most valuable work on the subject that has appeared in some years. The clinician and the pathologist have joined hands in its production, and the result must be a satisfaction to the editors as it is a gratification to the conscientious reader."

Boston Medical and Surgical Journal

"The articles as a rule present the essentials of the subject treated in a clear, concise manner, They are systematically written. The illustrations are abundant, well chosen, and enhance greatly the value of the work. The book is a thoroughly modern one."

The Medical Record, New York

"The arrangement of subjects is excellent, and their treatment by the different authors is equally so. . . . The work is up to date in a very remarkable degree, many of the latest operations in the different regional parts of the body being given in full details. There is not a chapter in the work from which the reader may not learn something new."

Keen and White's Text-Book of Surgery

A Text-Book of Surgery. Edited by WILLIAM W. KEEN, M.D., LL.D., F.R.C.S. (Hon.), Professor of the Principles of Surgery and of Clinical Surgery in the Jefferson Medical College, Philadelphia; and J. WILLIAM WHITE, M.D., PH.D., John Rhea Barton Professor of Surgery, University of Pennsylvania. Two handsome octavos, 1363 pages, with 551 text-cuts and 39 colored and half-tone plates. Beautifully bound in Cloth, 30*s.* net.

FOURTH EDITION, REVISED AND ENLARGED — JUST ISSUED

Of the three former editions of this book there have been sold over 40,000 copies. In this present edition every chapter has been extensively modified, and many of them have been partially, and some entirely, rewritten. The most recent researches of Monks on the Intestines, Crile and Cushing on Shock and Blood Pressure, Matas on Neural Infiltration and Aneurysm, Edebohls on Renal Decortication, etc., have been included. The use of paraffine in nasal deformities, the methods of spinal and local anesthesia, and the newer anesthetics have also been described. Six entirely new chapters appear in this edition: *Military Surgery*, by Brigadier-General R. W. O'Reilly, Surgeon-General, U. S. Army, and Major W. C. Borden, Surgeon, U. S. Army; *Naval Surgery*, by Admiral P. M. Rixey, Surgeon-General, U. S. Navy; *Tropical Surgery*, by Captain Charles F. Kieffer, Assistant Surgeon, U. S. Army; *Examination of the Blood*, by Dr. Richard C. Cabot; *Immunity*, by Dr. Arthur K. Stone; and *Surgery of the Pancreas*.

PERSONAL AND PRESS OPINIONS

Edmund Owen, F.R.C.S.,

Member of the Board of Examiners of the Royal College of Surgeons, England.

"Personally, I should not mind it being called **The** Text-Book (instead of **A** Text-Book), for I know of no single volume which contains so readable and complete an account of the science and art of surgery as this does."

The Lancet, London

"If this text-book is a fair reflex of the present position of American surgery, we must admit it is of a very high order of merit, and that English surgeons will have to look very carefully to their laurels if they are to preserve a position in the van of surgical practice."

Boston Medical and Surgical Journal

"This book marks an epoch in book-making. All in all, the book is distinctly the most satisfactory work on modern surgery with which we are familiar. It is thorough, complete, and condensed."

Scudder's Treatment of Fractures

WITH NOTES ON DISLOCATIONS

The Treatment of Fractures: with Notes on a few Common Dislocations. By CHARLES L. SCUDDER, M.D., Surgeon to the Massachusetts General Hospital, Boston. Octavo volume of 534 pages, with 688 original illustrations. Cloth, 21s. net.

JUST READY—NEW (4th) EDITION, ENLARGED
FOUR LARGE EDITIONS IN LESS THAN FOUR YEARS

Four large editions of this work have been called for in less than four years. In this edition the author has added some useful matter on Dislocations, illustrating it in that practical manner which has made the work so valuable. X-ray plates of the epiphyses at different ages have been arranged, and will be found of value not only as an anatomic study, but also in the appreciation of epiphyseal lesions. The text has been brought precisely down to date, containing the surgeons' reports on the late wars and the important facts regarding fractures produced by the small-caliber bullet. A large number of new illustrations have also been added. In the treatment the reader is not only told but is *shown* how to apply the apparatus, for, as far as possible, all the details are illustrated.

PERSONAL AND PRESS OPINIONS

William T. Bull, M.D.,

Professor of Surgery, College of Physicians and Surgeons, New York City.

"The work is a good one, and I shall certainly recommend it to students."

Joseph D. Bryant, M.D.,

Professor of the Principles and Practice of Surgery, University and Bellevue Hospital Medical College, New York City.

"As a practical demonstration of the topic it is excellent, and as an example of bookmaking it is highly commendable."

American Journal of the Medical Sciences

"The work produces a favorable impression by the general manner in which the subject is treated. Its descriptions are concise and clear, and the treatment sound. The physical examination of the injured part is well described, and . . . the method of making these examinations is illustrated by a liberal use of cuts."

Senn's Practical Surgery

Practical Surgery. A Work for the General Practitioner. By NICHOLAS SENN, M.D., PH.D., LL.D., Professor of Surgery in Rush Medical College, Chicago; Professor of Surgery in the Chicago Polyclinic; Attending Surgeon to the Presbyterian Hospital, etc. Handsome octavo volume of 1133 pages, with 650 illustrations, many of them in colors. Beautifully bound in cloth, 26*s*. net.

DR. SENN'S GREAT WORK

Based on His Operative Experience for 25 Years

This book deals with practical subjects, and its contents are devoted to those branches of surgery that are of special interest to the general practitioner. Special attention is paid to emergency surgery. Shock, hemorrhage, and wound treatment are fully considered. The section on Military Surgery is based on the author's experience as chief of the operating staff in the field during the Spanish-American war, and on his observations during the Greco-Turkish war.

Annals of Surgery

"It is of value not only as presenting comprehensively the most advanced teachings of modern surgery in the subjects which it takes up, but also as a record of the matured opinions and practice of an accomplished and experienced surgeon."

Griffith's Manual of Surgery

A Manual of Surgery. By FREDERIC GRIFFITH, M. D., Surgeon to the Bellevue Dispensary, New York City. Handsome 12mo of 579 pages, with 417 illustrations. Flexible leather, 10s. net.

JUST ISSUED

This work is a brief outline of the practice and principles of surgery, giving the essential details of the subject in the briefest possible manner consistent with clearness. The entire subject of surgery is covered, including all the specialties, as Diseases of the Eye, Ear, Nose, and Throat, Genito-Urinary Diseases, Diseases of Women, etc. This useful work will be to Surgery what Dr. Stevens' Manual is to Practice.

McClellan's Art Anatomy

Anatomy in its Relation to Art. An exposition of the Bones and Muscles of the Human Body, with Reference to their Influence upon its Actions and external Form. By GEORGE MCCLELLAN, M.D., Professor of Anatomy, Pennsylvania Academy of the Fine Arts. Handsome quarto volume, 9 by 11½ inches. Illustrated with 338 original drawings and photographs, with 260 pages of text.

Beautifully bound in Dark Blue Vellum, 42*s.* net.

This is an exhaustive work on the structure of the human body as it affects the external form, and although especially prepared for students and lovers of art, it will prove very valuable to all interested in the subject of anatomy. It will be of especial value to the physician, because nowhere else can he find so complete a consideration of surface anatomy. Those interested in athletics and physical training will find reliable information in this book.

British Medical Journal

"The idea of contrasting, on opposite pages, photographs of well-known statues and of living adults assuming similar positions is excellent, and the results obtained must be very valuable for teaching purposes."

McClellan's Regional Anatomy

Regional Anatomy in its Relations to Medicine and Surgery. By GEORGE MCCLELLAN, M.D., Professor of Anatomy, Pennsylvania Academy of the Fine Arts. Two handsome quartos, 884 pages of text; 97 full-page chromolithographic plates, reproducing the author's original dissections. Special price: Beautifully bound in cloth, 60*s.* net.

Fourth Revised Edition

This well-known work stands without a parallel in anatomic literature, and its remarkably large sale attests its value to the practitioner. By a marvelous series of colored lithographs the exact appearances of the dissected parts of the body are reproduced, enabling the reader to examine the anatomic relations with as much accuracy and satisfaction as if he had the actual subject before him.

British Medical Journal

"The illustrations are perfectly correct anatomical studies, and do not reproduce the inaccuracies which experience has taught us to look for in works of a similar kind. Some of the plates, especially those of the anatomy of the chest, are of great excellence."

DaCosta's Modern Surgery

Modern Surgery—GENERAL AND OPERATIVE. By JOHN CHALMERS DACOSTA, M.D., Professor of the Principles of Surgery and of Clinical Surgery in the Jefferson Medical College, Philadelphia; Surgeon to Philadelphia Hospital and to St. Joseph's Hospital, Philadelphia. Handsome octavo volume of 1099 pages, with 707 illustrations.

Beautifully bound in Cloth, 21*s.* net.

FOURTH EDITION—JUST ISSUED

Thoroughly Revised, Entirely Reset, and Greatly Enlarged

The progress of surgery in every department is one of the most notable phenomena of the present day. So many improvements, discoveries, and observations have been made since the appearance of the last edition of this work that the author found it necessary to rewrite it entirely. In this new fourth edition the book has undergone a thorough and careful revision, and there has been added much new matter. There have also been added over two hundred excellent and practical illustrations, greatly increasing the value of the work. Because of the great amount of new matter it has been deemed advisable in this present edition to adopt a larger type page. This is a great improvement, rendering as it does the work less cumbersome. The book will be found to express the latest advances in the art and science of surgery.

OPINIONS OF THE MEDICAL PRESS

The Lancet, London

"We may congratulate Dr. DaCosta in the success of his attempt. . . . We can recommend the work as a text-book well suited to students."

The Medical Record, New York

"The work throughout is notable for its conciseness. Redundance of language and padding have been scrupulously avoided, while at the same time it contains a sufficient amount of information to fulfil the object aimed at by its author—namely, a text-book for the use of the student and the busy practitioner."

American Journal of the Medical Sciences

"The author has presented concisely and accurately the principles of modern surgery. The book is a valuable one, which can be recommended to students, and is of great value to the general practitioner."

Helferich and Bloodgood's Fractures and Dislocations

Atlas and Epitome of Traumatic Fractures and Dislocations. By PROFESSOR DR. H. HELFERICH, Professor of Surgery at the Royal University, Greifswald, Prussia. Edited, with additions, by JOSEPH C. BLOODGOOD, M.D., Associate in Surgery, Johns Hopkins University, Baltimore. *From the Fifth Revised and Enlarged German Edition.* With 216 colored illustrations on 64 lithographic plates, 190 text-cuts, and 353 pages of text. Cloth, 13*s.* net. *In Saunders' Atlas Series.*

A New Volume—Recently Issued

A book accurately portraying the anatomic relations of the fractured parts, together with the diagnosis and treatment of the condition, has become an absolute necessity. This work is intended to meet all requirements. As complete a view as possible of each case has been presented, thus equipping the physician for the manifold appearances that he will meet with in practice. The illustrations are unrivaled for accuracy and clearness of portrayal of the conditions represented, showing the visible external deformity, the X-ray shadow, the anatomic preparation, and the method of treatment.

Zuckerkandl and DaCosta's Operative Surgery

ADOPTED BY THE U. S. ARMY

Atlas and Epitome of Operative Surgery. By DR. O. ZUCKERKANDL, of Vienna. Edited, with additions, by J. CHALMERS DACOSTA, M.D., Professor of the Principles of Surgery and Clinical Surgery, Jefferson Medical College, Philadelphia. 40 colored plates, 278 text-cuts and 410 pages of text. Cloth, 15*s.* net. *In Saunders' Atlas Series.*

SECOND EDITION, THOROUGHLY REVISED AND GREATLY ENLARGED

In this new edition the work has been brought precisely down to date. A number of chapters have been practically rewritten, and of the newer operations, all those of special value have been described. Sixteen valuable lithographic plates in colors and sixty-one text figures have been added, thus greatly enhancing the value of the work.

New York Medical Journal

"We know of no other work upon the subject in which the illustrations are as numerous or as generally satisfactory."

GET THE BEST

Dorland's Illustrated Dictionary

THE NEW STANDARD

THIRD REVISED EDITION—JUST ISSUED

Dorland's Illustrated Medical Dictionary. A New and Complete Dictionary of the terms used in Medicine, Surgery, Dentistry, Pharmacy, Chemistry, and the kindred branches; together with new and elaborate tables of Arteries, Muscles, Nerves, Veins, etc.; of Bacilli, Bacteria, Micrococci, etc.; Eponymic Tables of Diseases, Operations, Signs and Symptoms, Stains, Tests, Methods of Treatment, etc. By W. A. NEWMAN DORLAND, M.D. Large octavo, 798 pages. Flexible leather, 19*s.* net; with thumb index, 21*s.* net.

THREE EDITIONS IN THREE YEARS—WITH 1500 NEW TERMS

In this edition the book has been subjected to a thorough revision. The author has also added nearly fifteen hundred important new terms that have appeared in medical literature during the past few months.

Howard A. Kelly, M.D.,

Professor of Gynecology, Johns Hopkins University, Baltimore.

"Dr. Dorland's Dictionary is admirable. It is so well gotten up and of such convenient size. No errors have been found in my use of it."

Roswell Park, M.D.,

Professor of Principles and Practice of Surgery and of Clinical Surgery, University of Buffalo.

"I must acknowledge my astonishment at seeing how much he has condensed within relatively small space. I find nothing to criticise, very much to commend, and was interested in finding some of the new words which are not in other recent dictionaries."

Saunders' Year-Book

Saunders' Year-Book of Medicine and Surgery. A yearly Digest of Scientific Progress and Authoritative Opinion in all branches of Medicine and Surgery, drawn from journals, monographs, and text-books of the leading English and foreign authors and investigators. Arranged, with critical editorial comments, by eminent specialists, under the editorial charge of GEORGE M. GOULD, A.M., M.D. In two volumes: Vol. I—*General Medicine*, octavo, 715 pages, illustrated; Vol. II—*General Surgery*, octavo, 684 pages, illustrated.

Per volume: Beautifully bound in cloth, 13*s.* net.

In these volumes the reader obtains not only a yearly digest, but also the invaluable annotations and criticisms of the editors. As usual, this issue of the Year-Book is amply illustrated.

The Lancet, London

"It is much more than a mere compilation of abstracts, for, as each section is entrusted to experienced and able contributors, the reader has the advantage of certain critical commentaries and expositions . . . proceeding from writers fully qualified to perform these tasks."

Sultan and Coley's Abdominal Hernias

Atlas and Epitome of Abdominal Hernias. By PRIVATDOCENT DR. GEORG SULTAN, of Göttingen. Edited, with additions, by WILLIAM B. COLEY, M.D., Clinical Lecturer on Surgery, Columbia University (College of Physicians and Surgeons). With 119 illustrations, 36 of them in colors, and 277 pages of text. Cloth, 13*s.* net.

In Saunders' Hand-Atlas Series.

During the last decade the operative side of this subject has been steadily growing in importance, until now it is absolutely essential to have a book treating of its surgical aspect. This present atlas does this to an admirable degree. The illustrations are not only very numerous, but they portray most accurately the conditions represented.

Robert H. M. Dawbarn, M.D.,

Professor of Surgery and of Surgical Anatomy, New York Polyclinic.

"I have spent several interesting hours over it to-day, and shall willingly recommend it to my classes at the Polyclinic College and elsewhere."

Robson and Moynihan on the Pancreas

Diseases of the Pancreas and Their Surgical Treatment. By A. W. MAYO ROBSON, F.R.C.S., Senior Surgeon, Leeds General Infirmary; Emeritus Professor of Surgery, Yorkshire College, Victoria University, England; and B. G. A. MOYNIHAN, M.S. (Lond.), F.R.C.S., Assistant Surgeon, Leeds General Infirmary; Consulting Surgeon to the Skipton and to the Mirfield Memorial Hospitals, England. Octavo of 293 pages, illustrated. Cloth, 12*s.* net.

RECENTLY ISSUED

This work, dealing with the surgical aspect of pancreatic disease, has been written with a two-fold object: to record and to review the work done in the past, and to indicate, so far as possible, the scope and trend of future research. Besides containing a very commendable exposition of the various diseases and injuries of the pancreas, the volume includes an accurate account of the anatomy, abnormalities, development, and structure of the gland.

Golebiewski and Bailey's Accident Diseases

Atlas and Epitome of Diseases Caused by Accidents. By DR. ED. GOLEBIEWSKI, of Berlin. Edited, with additions, by PEARCE BAILEY, M.D., Consulting Neurologist to St. Luke's Hospital and the Orthopedic Hospital, New York. With 71 colored figures on 40 plates, 143 text-cuts, and 549 pages of text. Cloth, 16*s.* net. *In Saunders' Hand-Atlas Series.*

The Medical Record, New York

"This volume is upon an important and only recently systematized subject, which is growing in extent all the time. The pictorial part of the book is very satisfactory."

Warren's Pathology and Therapeutics

Surgical Pathology and Therapeutics. By J. COLLINS WARREN, M.D., LL.D., F.R.C.S. (Hon.), Professor of Surgery, Harvard Medical School. Octavo, 873 pages; 136 illustrations, 33 in colors. With an Appendix on Surgical Diagnosis and Regional Bacteriology. Beautifully bound in Cloth, 21*s.* net.

SECOND EDITION, WITH AN APPENDIX

Roswell Park, M.D.,

In the Harvard Graduate Magazine.

"I think it is the most creditable book on surgical pathology, and the most beautiful medical illustration of the bookmakers' art that has ever been issued from the American press."

Senn's Tumors

Pathology and Surgical Treatment of Tumors. By NICHOLAS SENN, M.D., PH.D., LL.D., Professor of Surgery, Rush Medical College, Chicago. Handsome octavo, 718 pages, with 478 engravings, including 12 full-page colored plates.

Beautifully bound in Cloth, 21*s.* net.

SECOND EDITION, REVISED

Journal of the American Medical Association

"The most exhaustive of any recent book in English on this subject. It is well illustrated, and will doubtless remain as the principal monograph on the subject in our language for some years. The author has given a notable and lasting contribution to surgery."

Beck's Surgical Asepsis

A Manual of Surgical Asepsis. By CARL BECK, M.D., Professor of Surgery, New York Post-graduate Medical School and Hospital. 306 pages ; 65 text-illustrations and 12 full-page plates. Cloth, 5*s.* net.

"The book is well written. The data are clearly and concisely given. The facts are wel arranged."—*Boston Medical and Surgical Journal.*

Senn's Syllabus of Surgery

A Syllabus of Lectures on the Practice of Surgery. Arranged in conformity with "A Text-Book of Surgery." By NICHOLAS SENN, M.D., PH.D., LL.D., Professor of Surgery, Rush Medical College, Chi. 6*s.* net.

"The author has evidently spared no pains in making his Syllabus thoroughly comprehensive, and has added new matter and alluded to the most recent authors and operations."—*British Medical Journal.*

Keen's Operation Blank, Second Edition, Revised Form

An Operation Blank, with Lists of Instruments, etc., Required in Various Operations. Prepared by WM. W. KEEN, M.D., LL.D., F.R.C.S. (Hon.), Professor of the Principles of Surgery and of Clinical Surgery, Jefferson Medical College, Philadelphia. Price per pad, blanks for fifty operations, 2*s.* net.

"Will serve a useful purpose for the surgeon in reminding him of the details of preparation for the patient and the room as well as for the instruments, dressings, and antiseptics needed."—*New York Medical Record.*

Keen on the Surgery of Typhoid

The Surgical Complications and Sequels of Typhoid Fever. By WM. W. KEEN, M.D., LL.D., F.R.C.S. (Hon.), Professor of the Principles of Surgery and of Clinical Surgery, Jefferson Medical College, Philadelphia, etc. Octavo volume of 386 pages, illustrated. Cloth, 12*s.* 6*d.* net.

"Every surgical incident which can occur during or after typhoid fever is amply discussed and fully illustrated by cases. Will be useful to surgeon and physician."—*The Practitioner, Lond.*

Moore's Orthopedic Surgery

A Manual of Orthopedic Surgery. By JAMES E. MOORE, M.D., Professor of Clinical Surgery, University of Minnesota, College of Medicine and Surgery. Octavo of 356 pages, handsomely illustrated. Cloth, 10*s.* 6*d.* net.

"The book is eminently practical. It is a safe guide in the understanding and treatment of orthopedic cases. Should be owned by every surgeon and practitioner."—*Annals of Surgery.*

Nancrede's Principles of Surgery

Lectures on the Principles of Surgery. By CHAS. B. NANCREDE, M.D., LL.D., Professor of Surgery and of Clinical Surgery, University of Michigan, Ann Arbor. Octavo, 398 pages, illustrated. Cloth, 10*s.* 6*d.* net.

"We can strongly recommend this book to all students and those who would see something of the scientific foundation upon which the art of surgery is built."—*Quarterly Med. Jour., Eng.*

Barton and Wells' Medical Thesaurus — Just Issued

A Thesaurus of Medical Words and Phrases. By WILFRED M. BARTON, M. D., Assistant to Professor of Materia Medica and Therapeutics, and Lecturer on Pharmacy, Georgetown University, Washington, D. C. ; and WALTER A. WELLS, M. D., Demonstrator of Laryngology, Georgetown University, Washington, D. C. 12mo of 534 pages. Flexible leather, 12s. net ; with thumb index, 14s. net.

Haynes' Anatomy

A Manual of Anatomy. By IRVING S. HAYNES, M.D., Professor of Practical Anatomy, Cornell University Medical College. Octavo, 680 pages, with 42 diagrams and 134 full-page half-tones. Cloth, 10*s*. net.

"This book is the work of a practical instructor—one who knows by experience the requirements of the average student, and is able to meet these requirements in a very satisfactory way."—*The Medical Record, New York.*

Dorland's Pocket Dictionary

Just Issued
Fourth Revised Edition

Dorland's Pocket Medical Dictionary. Edited by W. A. NEWMAN DORLAND, A.M., M.D., Assistant Obstetrician, Hospital of the University of Pennsylvania, etc. 566 pages. Full leather, limp, with gold edges, 5*s*. net; with patent thumb index, 6*s*. net.

"I am struck at once with admiration at the compact size and attractive exterior. I can recommend it to our students without reserve."—JAMES W. HOLLAND, M.D., *Professor of Medical Chemistry and Toxicology, and Dean, Jefferson Medical College, Philadelphia.*

Beck's Fractures

Fractures. By CARL BECK, M.D., Professor of Surgery, New York Postgraduate Medical School and Hospital. With an Appendix on the Practical Use of the Röntgen Rays. 335 pages, 170 illustrations. Cloth, 15*s*. net.

"The use of the rays with its technic is fully explained, and the practical points are brought out with a thoroughness that merits high praise."—*The Medical Record, New York.*

Macdonald's Diagnosis and Treatment

A Clinical Text-Book of Surgical Diagnosis and Treatment. By J. W. MACDONALD, M.D. Edin., F.R.C.S. Edin., Professor Emeritus of the Practice of Surgery and of Clinical Surgery in Hamline University, Minneapolis, Minn. Octavo, 798 pages, illustrated. Cloth, 21*s*. net.

"The most advanced and approved methods of clinical investigation in surgical practice are fully described."—*British Medical Journal.*

Stoney's Surgical Technic

Just Issued
Second Revised Edition

Bacteriology and Surgical Technic for Nurses. By EMILY A. M. STONEY, Superintendent of the Training School for Nurses at the Carney Hospital, South Boston, Mass. 12mo, 200 pages, illustrated.

"These subjects are treated most accurately and up to date, without the superfluous reading which is so often employed. . . . Nurses will find this book of the greatest value."—*Trained Nurse and Hospital Review.*

Grant on Face, Mouth, and Jaws

A Text-Book of the Surgical Principles and Surgical Diseases of the Face, Mouth, and Jaws. For Dental Students. By H. HORACE GRANT, A.M., M.D., Professor of Surgery and of Clinical Surgery, Hospital College of Medicine. Octavo of 231 pages, with 68 illustrations. Cloth, 11*s*. net.

"The language of the book is simple and clear. . . . We recommend the work to those for whom it is intended."—*Philadelphia Medical Journal.*

Blood Films

Cleanslides; make film as thin as possible; dry by waving in air.

Stains (1) Jenner 2–4 mins covered stain
20 secs differentiate distilled H_2O
Dry blotting paper
Mount in Damar.

(2) Leishman 30 secs stain x drops
2x drops 5–8 mins differentiate distilled
Wash again aq dist 60 secs
Wash again aq dist
Dry with blotting paper
Mount in Damar.

(3) Giemsa

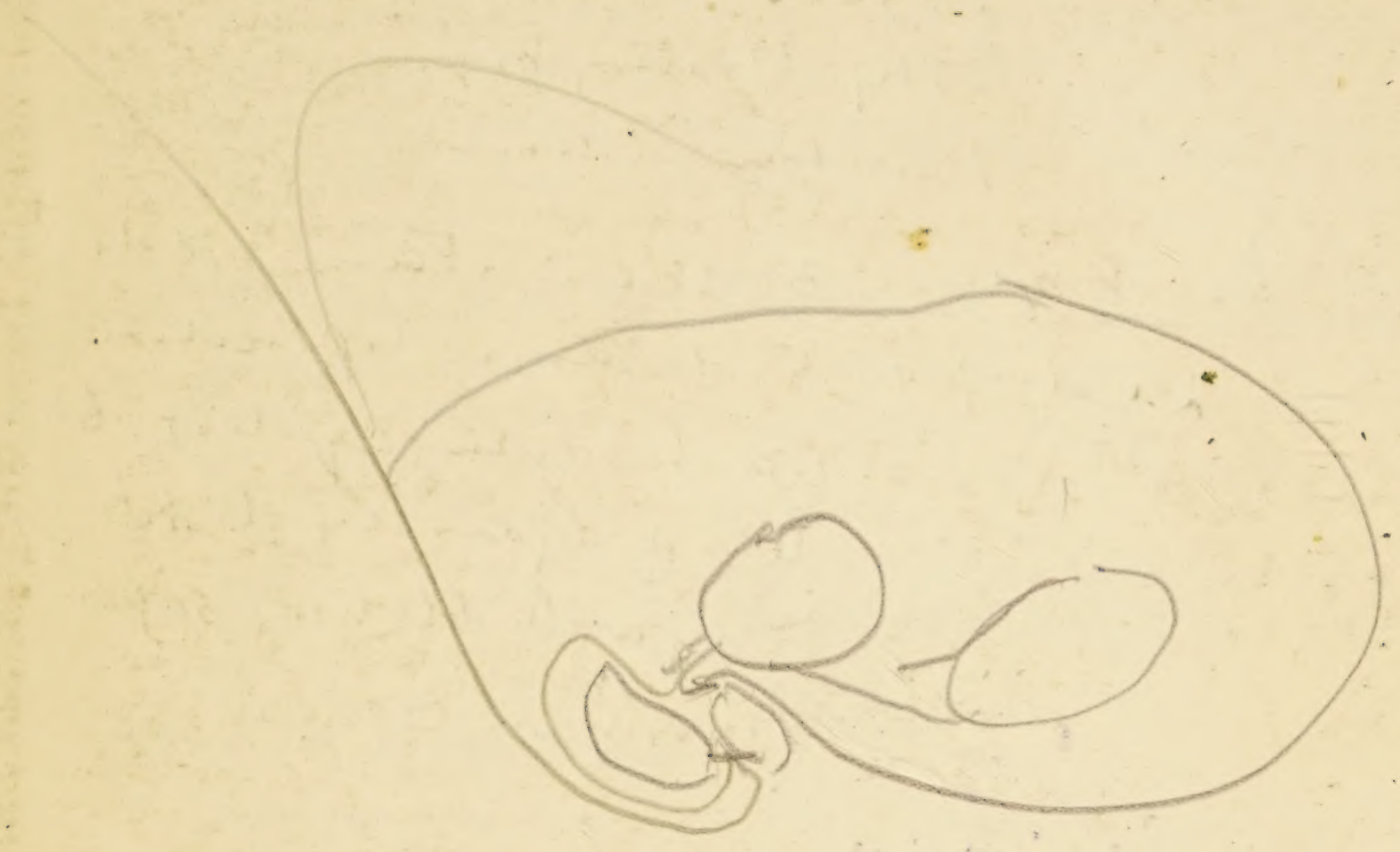

KING'S COLLEGE HOSPITAL
LIBRARY
MEDICAL SCHOOL